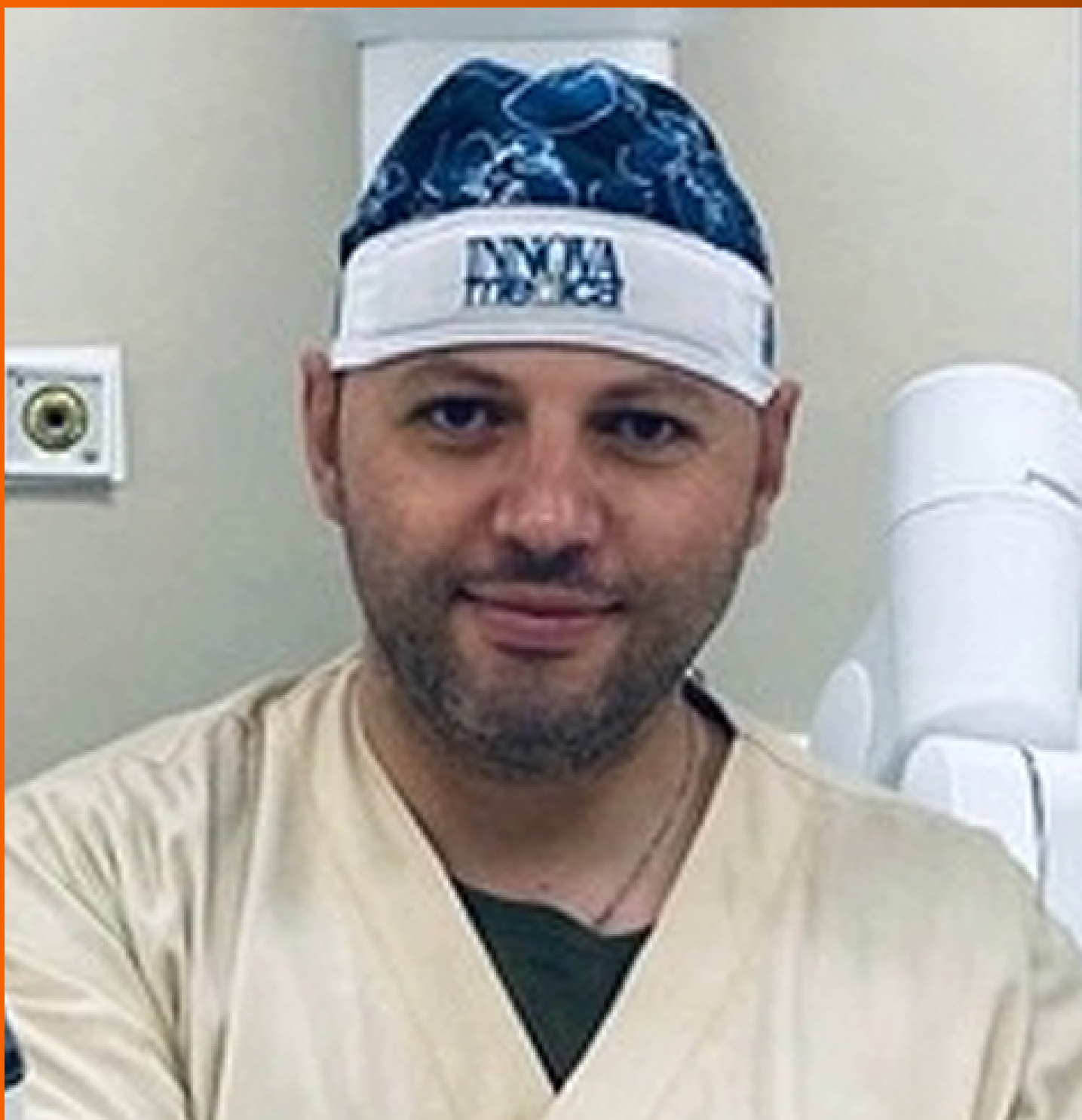

World Journal of *Gastrointestinal Oncology*

World J Gastrointest Oncol 2023 December 15; 15(12): 2049-2241



EDITORIAL

- 2049 Dual primary gastric and colorectal cancer: A complex challenge in surgical oncology
Marano L

MINIREVIEWS

- 2053 Identification of genes associated with gall bladder cell carcinogenesis: Implications in targeted therapy of gall bladder cancer
Ghosh I, Dey Ghosh R, Mukhopadhyay S

ORIGINAL ARTICLE

Clinical and Translational Research

- 2064 Transient receptor potential-related risk model predicts prognosis of hepatocellular carcinoma patients
Mei XC, Chen Q, Zuo S

Retrospective Cohort Study

- 2077 Cohort study to assess geographical variation in cholangiocarcinoma treatment in England
Jose S, Zalin-Miller A, Knott C, Paley L, Tataru D, Morement H, Toledano MB, Khan SA

Retrospective Study

- 2093 Effect of ultrasound-guided lumbar square muscle block on stress response in patients undergoing radical gastric cancer surgery
Wang XR, Xu DD, Guo MJ, Wang YX, Zhang M, Zhu DX

- 2101 Application of remimazolam transversus abdominis plane block in gastrointestinal tumor surgery
Liu J, Tian JM, Liu GZ, Sun JN, Gao PF, Zhang YQ, Yue XQ

- 2111 The efficacy of full-thickness endoscopic resection of subepithelial tumors in the gastric cardia
Xu EP, Qi ZP, Li B, Ren Z, Cai MY, Cai SL, Lyv ZT, Chen ZH, Liu JY, Shi Q, Zhong YS

Basic Study

- 2120 Hsa_circ_0136666 mediates the antitumor effect of curcumin in colorectal carcinoma by regulating CXCL1 via miR-1301-3p
Chen S, Li W, Ning CG, Wang F, Wang LX, Liao C, Sun F
- 2138 Combined TIM-3 and PD-1 blockade restrains hepatocellular carcinoma development by facilitating CD4+ and CD8+ T cell-mediated antitumor immune responses
Zhang XS, Zhou HC, Wei P, Chen L, Ma WH, Ding L, Liang SC, Chen BD

- 2150** Association between heat shock factor protein 4 methylation and colorectal cancer risk and potential molecular mechanisms: A bioinformatics study
Zhang WJ, Yue KL, Wang JZ, Zhang Y
- 2169** Evaluating the causal relationship between human blood metabolites and gastroesophageal reflux disease
Hu JY, Lv M, Zhang KL, Qiao XY, Wang YX, Wang FY
- 2185** Paired-related homeobox 1 induces epithelial-mesenchymal transition in oesophageal squamous cancer
Guo JB, Du M, Wang B, Zhong L, Fu ZX, Wei JL

META-ANALYSIS

- 2197** Intensive follow-up *vs* conventional follow-up for patients with non-metastatic colorectal cancer treated with curative intent: A meta-analysis
Cui LL, Cui SQ, Qu Z, Ren ZQ
- 2212** Prognostic value of T cell immunoglobulin and mucin-domain containing-3 expression in upper gastrointestinal tract tumors: A meta-analysis
Yan JJ, Liu BB, Yang Y, Liu MR, Wang H, Deng ZQ, Zhang ZW
- 2225** Association of MBOAT7 rs641738 polymorphism with hepatocellular carcinoma susceptibility: A systematic review and meta-analysis
Lai M, Qin YL, Jin QY, Chen WJ, Hu J

CASE REPORT

- 2237** Conversion immunotherapy for deficient mismatch repair locally unresectable colon cancer: A case report
Sun Z, Liu H, Zhang GN, Xiao Y

ABOUT COVER

Editorial Board Member of *World Journal of Gastrointestinal Oncology*, Luigi Marano, MD, PhD, Professor, Department of Medicine, Academy of Medical and Social Applied Sciences-AMiSNS: Akademia Medycznych i Społecznych Nauk Stosowanych-2 Lotnicza Street, Elbląg 82-300, Poland. l.marano@amisns.edu.pl

AIMS AND SCOPE

The primary aim of *World Journal of Gastrointestinal Oncology* (WJGO, *World J Gastrointest Oncol*) is to provide scholars and readers from various fields of gastrointestinal oncology with a platform to publish high-quality basic and clinical research articles and communicate their research findings online.

WJGO mainly publishes articles reporting research results and findings obtained in the field of gastrointestinal oncology and covering a wide range of topics including liver cell adenoma, gastric neoplasms, appendiceal neoplasms, biliary tract neoplasms, hepatocellular carcinoma, pancreatic carcinoma, cecal neoplasms, colonic neoplasms, colorectal neoplasms, duodenal neoplasms, esophageal neoplasms, gallbladder neoplasms, *etc.*

INDEXING/ABSTRACTING

The WJGO is now abstracted and indexed in PubMed, PubMed Central, Science Citation Index Expanded (SCIE, also known as SciSearch®), Journal Citation Reports/Science Edition, Scopus, Reference Citation Analysis, China Science and Technology Journal Database, and Superstar Journals Database. The 2023 edition of Journal Citation Reports® cites the 2022 impact factor (IF) for WJGO as 3.0; IF without journal self cites: 2.9; 5-year IF: 3.0; Journal Citation Indicator: 0.49; Ranking: 157 among 241 journals in oncology; Quartile category: Q3; Ranking: 58 among 93 journals in gastroenterology and hepatology; and Quartile category: Q3. The WJGO's CiteScore for 2022 is 4.1 and Scopus CiteScore rank 2022: Gastroenterology is 71/149; Oncology is 197/366.

RESPONSIBLE EDITORS FOR THIS ISSUE

Production Editor: Xiang-Di Zhang; Production Department Director: Xu Guo; Editorial Office Director: Jia-Ru Fan.

NAME OF JOURNAL

World Journal of Gastrointestinal Oncology

ISSN

ISSN 1948-5204 (online)

LAUNCH DATE

February 15, 2009

FREQUENCY

Monthly

EDITORS-IN-CHIEF

Monjur Ahmed, Florin Burada

EDITORIAL BOARD MEMBERS

<https://www.wjgnet.com/1948-5204/editorialboard.htm>

PUBLICATION DATE

December 15, 2023

COPYRIGHT

© 2023 Baishideng Publishing Group Inc

INSTRUCTIONS TO AUTHORS

<https://www.wjgnet.com/bpg/gerinfo/204>

GUIDELINES FOR ETHICS DOCUMENTS

<https://www.wjgnet.com/bpg/GerInfo/287>

GUIDELINES FOR NON-NATIVE SPEAKERS OF ENGLISH

<https://www.wjgnet.com/bpg/gerinfo/240>

PUBLICATION ETHICS

<https://www.wjgnet.com/bpg/GerInfo/288>

PUBLICATION MISCONDUCT

<https://www.wjgnet.com/bpg/gerinfo/208>

ARTICLE PROCESSING CHARGE

<https://www.wjgnet.com/bpg/gerinfo/242>

STEPS FOR SUBMITTING MANUSCRIPTS

<https://www.wjgnet.com/bpg/GerInfo/239>

ONLINE SUBMISSION

<https://www.f6publishing.com>



Conversion immunotherapy for deficient mismatch repair locally unresectable colon cancer: A case report

Zhen Sun, He Liu, Guan-Nan Zhang, Yi Xiao

Specialty type: Oncology

Provenance and peer review:

Unsolicited article; Externally peer reviewed.

Peer-review model: Single blind

Peer-review report's scientific quality classification

Grade A (Excellent): 0

Grade B (Very good): B

Grade C (Good): 0

Grade D (Fair): D, D

Grade E (Poor): 0

P-Reviewer: Rizzo A, Italy; Shalaby MN, Egypt

Received: October 26, 2023

Peer-review started: October 26, 2023

First decision: October 30, 2023

Revised: October 31, 2023

Accepted: November 5, 2023

Article in press: November 5, 2023

Published online: December 15, 2023



Zhen Sun, Guan-Nan Zhang, Yi Xiao, Division of Colorectal Surgery, Department of General Surgery, Peking Union Medical College Hospital, Chinese Academy of Medical Sciences and Peking Union Medical College, Beijing 100730, China

He Liu, Department of Gastrointestinal Surgery, The People's Hospital of Huangdao District, Qingdao 266400, Shandong Province, China

Corresponding author: Yi Xiao, PhD, Chief Doctor, Division of Colorectal Surgery, Department of General Surgery, Peking Union Medical College Hospital, Chinese Academy of Medical Sciences and Peking Union Medical College, No. 1 Shuai Fu Yuan, Dongcheng District, Beijing 100730, China. xiaoy@pumch.cn

Abstract

BACKGROUND

Owing to the special features of biologics, deficient mismatch repair (dMMR) in patients with colon cancer has achieved little treatment efficacy from chemoradiotherapy. Immunotherapy has shown promising results for the treatment of colon cancer. The high response rate observed suggests a great option for patients presenting with unresectable tumors, as it allows for better oncological resection. Here, we aimed to highlight the significant effects of immunotherapy on dMMR in colon cancer.

CASE SUMMARY

A 54-year-old man diagnosed with locally unresectable dMMR colon cancer received preoperative immunotherapy (three cycles of pembrolizumab) and achieved a pathological complete response after surgery.

CONCLUSION

Immunotherapy can be used as a conversion treatment for locally unresectable colon cancer with dMMR.

Key Words: Colon cancer; Immunotherapy; Pathological complete response; Case report

©The Author(s) 2023. Published by Baishideng Publishing Group Inc. All rights reserved.

Core Tip: Surgery remains the primary radical therapy for colon cancer and resection radicality is one of the most important predictors for survival. Preoperative chemotherapy has been proven to ameliorate resection radicality and survival. Due to the special features of biologics, deficient mismatch repair (dMMR) colon cancer patients achieved little treatment efficacy from chemoradiotherapy. Up to now, immunotherapy has shown promising responses in colon cancer. We aim to draw attention to the significant effect of immunotherapy on dMMR colon cancer.

Citation: Sun Z, Liu H, Zhang GN, Xiao Y. Conversion immunotherapy for deficient mismatch repair locally unresectable colon cancer: A case report. *World J Gastrointest Oncol* 2023; 15(12): 2237-2241

URL: <https://www.wjgnet.com/1948-5204/full/v15/i12/2237.htm>

DOI: <https://dx.doi.org/10.4251/wjgo.v15.i12.2237>

INTRODUCTION

Surgery remains the primary radical therapy for colon cancer[1,2], and resection radicality is an important predictor of local recurrence and overall survival[3]. Owing to the delayed administration of adjuvant chemotherapy, postoperative complications can cause poor oncological outcomes in patients with colorectal cancer (CRC)[4]. Hence, resection radicality should be improved, and the incidence of surgical complications should be reduced. Preoperative chemotherapy improves resection radicality and survival[5-8]. However, owing to the special features of biologics, patients with deficient mismatch repair (dMMR) colon cancer have achieved little treatment efficacy with chemoradiotherapy[9]. Immunotherapy has previously shown promising results for colon cancer[10-13]. Hence, we aimed to draw attention to its significant effect on dMMR in colon cancer. This study was written in compliance with the SCARE Guideline[14].

CASE PRESENTATION

Chief complaints

A 54-year-old man presented to the hospital with difficulty in defecating.

History of present illness

Symptoms started 2 mo before the patient was diagnosed with colon cancer in May 2023.

History of past illness

The patient had undergone colectomy twice owing to a poorly-differentiated adenocarcinoma of the splenic flexure colon (unknown pTNM stage) in 2007 and a moderate- to poorly-differentiated adenocarcinoma of the cecum (pT4aN2a) in 2008. Postoperative adjuvant chemotherapy was administered after both surgeries.

Personal and family history

The patient denied any family history of malignant tumors.

Physical examination

Physical examination revealed normal vital signs. The digital anal examination result was also normal.

Laboratory examinations

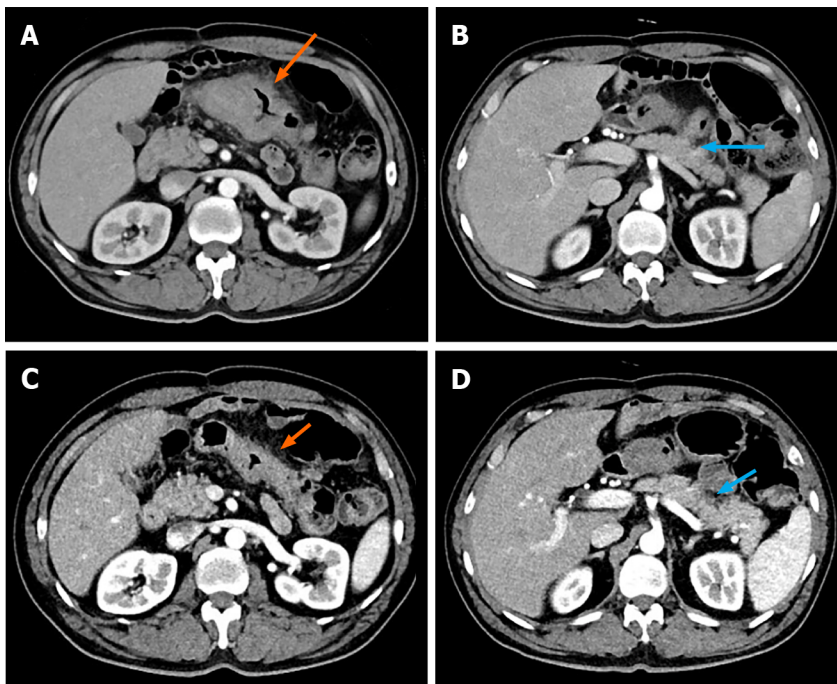
Laboratory results showed normal carcinoembryonic antigen and carbohydrate antigen 19-9. No abnormality was found in routine blood analyses.

Imaging examinations

Colonoscopy revealed a large, cauliflower-like mass in the transverse colon. Histopathological examination of the biopsy specimen revealed a poorly-differentiated adenocarcinoma with dMMR. Contrast-enhanced abdominal computed tomography (CT) demonstrated a bulky tumor measuring > 10 cm in the transverse colon (Figure 1A), and several enlarged lymph nodes in the mesentery. CT did not reveal metastases to distant sites.

FINAL DIAGNOSIS

Considering the invasion of the pancreatic capsule (Figure 1B), negative margins were not ascertained intraoperatively.



DOI: 10.4251/wjgo.v15.i12.2237 Copyright ©The Author(s) 2023.

Figure 1 Computed tomography scans taken before and after immunotherapy. A and B: Before immunotherapy (arrows); C and D: After immunotherapy. The orange arrows showed the location and range of the tumor, while the blue arrows showed invasion of the pancreatic capsule.

TREATMENT

Preoperative immunotherapy is recommended for conversion to resection. The patient received three cycles of pembrolizumab immunotherapy without complaints. Post-treatment CT showed significant regression of the tumor (Figure 1C and D), as assessed by our team.

Thus, the patient underwent open transverse colectomy with D2 lymph node dissection two weeks after the end of immunotherapy. The previous ileocolonic anastomosis was resected during surgery.

As shown in Figure 2A, gross examination revealed invasion of the serosal surface by the tumor. Interestingly, pathological examination showed that the tumor regression grade was 0, indicating complete regression with no residual tumor cells, including the lymph nodes (Figure 2B). The final stage in this patient was a pathologic complete response (pCR).

OUTCOME AND FOLLOW-UP

Delayed gastric emptying (DGE) occurred, and a transnasal feeding tube was placed for nutritional support. The patient was discharged from the hospital on the 39th day after surgery, when the DGE was alleviated.

DISCUSSION

To the best of our knowledge, this case is the first to provide evidence of the efficacy of immunotherapy as a conversion regimen for locally unresectable colon cancer with dMMR.

The hallmark of dMMR is the inability to repair spontaneous mutations during DNA replication, leading to hypermutation and increased tumor mutation burden[15]. Currently, dMMR is one of the major predictive biomarkers of the benefits of immune checkpoint inhibitor (ICI) benefit[16]. Thus, MMR status should be regularly tested for colon cancer to guide personalized treatment. ICI therapy aims to overcome tumor immune escape by targeting immune inhibitory molecules expressed on the surfaces of the tumor and immune cells.

Since numerous questions remain regarding dMMR and its impact on the efficacy of immunotherapy, several clinical trials have been launched to determine the optimal treatment for patients with colon cancer. NICHE-1 was the first neoadjuvant immunotherapy study to show pathological responses in 100% of dMMR tumors[10]. The PICC trial[12] reported a pCR rate of 65% in patients with locally advanced dMMR CRC who received immunotherapy. Pei *et al*[17] reported that 90.9% of patients with locally advanced dMMR CRC achieved pCR after neoadjuvant immunotherapy. The NICHE-2 study subsequently reported that the rates of major pathological response and pCR for locally advanced dMMR colon cancer were 95% and 67%, respectively[11]. It also reported the first survival data in which none of the patients had

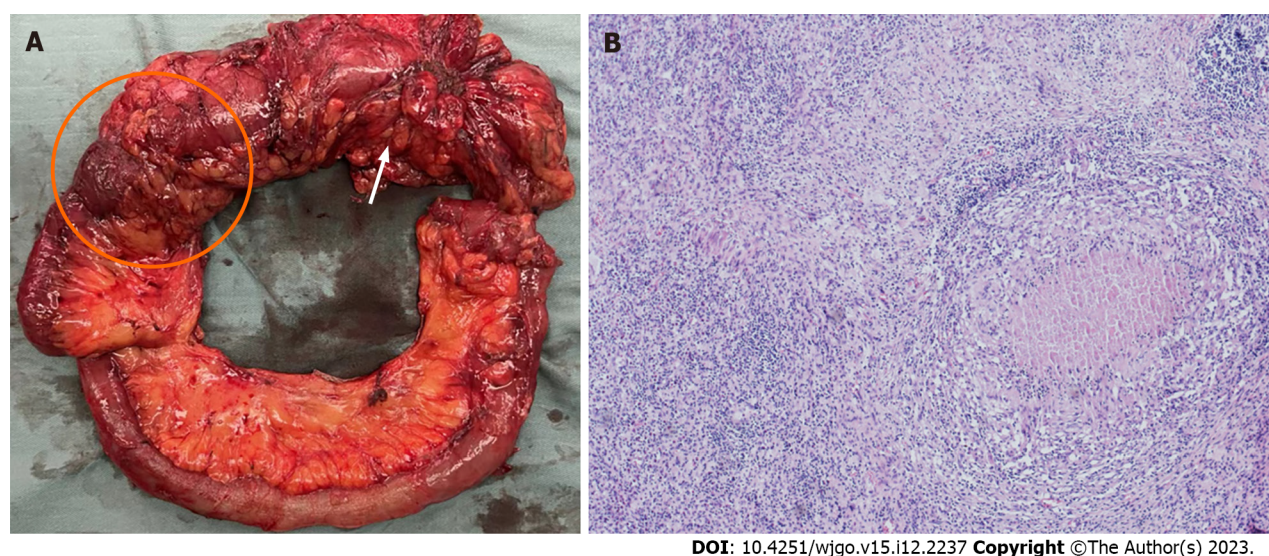


Figure 2 Gross pathological examination and hematoxylin and eosin staining. A: Gross pathological examination showed the tumor (orange arrow) and previous ileocolonic anastomosis (orange circle); B: Hematoxylin and eosin staining slide (magnification: $\times 40$) showed that the lesion was tumor-free.

recurrence at a median follow-up of 13 mo, suggesting the advantage of neoadjuvant immunotherapy. More than the potential survival benefit of immunotherapy, Han *et al*[18] reported that neoadjuvant immunotherapy significantly reduced open surgery (83.3% *vs* 72.2%, $P < 0.001$) and multi-visceral resection rate ($P = 0.025$) for CRC patients. Hence, this therapy could minimize the extent of surgery and improve postoperative recovery.

The high response rate observed in patients suggests that surgery combined with neoadjuvant immunotherapy is a promising option for CRC surgeons to use in dMMR colon cancers which appear unresectable. This method is also likely to achieve better oncologic resection and organ-sparing strategies. However, the optimal duration of immunotherapy and the timing of surgery remain to be determined. Moreover, a long-term follow-up is required to assess the effects of immunotherapy on the survival of a selected subset of patients with dMMR colon cancer.

CONCLUSION

Immunotherapy can be used as a conversion treatment for locally unresectable dMMR colon cancer. However, further evidence from clinical trials is required to confirm these findings.

FOOTNOTES

Author contributions: Sun Z and Liu H collected data and drafted the manuscript; Zhang GN participated in data acquisition and interpretation; Xiao Y revised and finalized the manuscript; all authors have read and approved the final manuscript.

Supported by National High Level Hospital Clinical Research Funding, No. 2022-PUMCH-C-027.

Informed consent statement: Written informed consent was obtained from the patient for publication of this report and any accompanying images.

Conflict-of-interest statement: Written informed consent was obtained from the patient for publication of this report and any accompanying images.

CARE Checklist (2016) statement: The authors read the CARE Checklist (2016) and the manuscript was prepared and revised according to this checklist.

Open-Access: This article is an open-access article that was selected by an in-house editor and fully peer-reviewed by external reviewers. It is distributed in accordance with the Creative Commons Attribution NonCommercial (CC BY-NC 4.0) license, which permits others to distribute, remix, adapt, build upon this work non-commercially, and license their derivative works on different terms, provided the original work is properly cited and the use is non-commercial. See: <https://creativecommons.org/licenses/by-nc/4.0/>

Country/Territory of origin: China

ORCID number: Zhen Sun 0000-0001-7430-8081; Guan-Nan Zhang 0000-0001-8685-5015; Yi Xiao 0000-0002-4309-1227.

S-Editor: Yan JP

L-Editor: A

P-Editor: Yu HG

REFERENCES

- Vogel JD, Felder SI, Bhama AR, Hawkins AT, Langenfeld SJ, Shaffer VO, Thorsen AJ, Weiser MR, Chang GJ, Lightner AL, Feingold DL, Paquette IM. The American Society of Colon and Rectal Surgeons Clinical Practice Guidelines for the Management of Colon Cancer. *Dis Colon Rectum* 2022; **65**: 148-177 [PMID: 34775402 DOI: 10.1097/DCR.0000000000002323]
- Argilés G, Tabernero J, Labianca R, Hochhauser D, Salazar R, Iveson T, Laurent-Puig P, Quirke P, Yoshino T, Taieb J, Martinelli E, Arnold D; ESMO Guidelines Committee. Localised colon cancer: ESMO Clinical Practice Guidelines for diagnosis, treatment and follow-up. *Ann Oncol* 2020; **31**: 1291-1305 [PMID: 32702383 DOI: 10.1016/j.annonc.2020.06.022]
- Chang H, Yu X, Xiao WW, Wang QX, Zhou WH, Zeng ZF, Ding PR, Li LR, Gao YH. Neoadjuvant chemoradiotherapy followed by surgery in patients with unresectable locally advanced colon cancer: a prospective observational study. *Onco Targets Ther* 2018; **11**: 409-418 [PMID: 29398921 DOI: 10.2147/OTT.S150367]
- Miyamoto Y, Hiyoshi Y, Tokunaga R, Akiyama T, Daitoku N, Sakamoto Y, Yoshida N, Baba H. Postoperative complications are associated with poor survival outcome after curative resection for colorectal cancer: A propensity-score analysis. *J Surg Oncol* 2020; **122**: 344-349 [PMID: 32346880 DOI: 10.1002/jso.25961]
- de Gooyer JM, Verstegen MG, 't Lam-Boer J, Radema SA, Verhoeven RHA, Verhoef C, Schreinemakers MJ, de Wilt JHW. Neoadjuvant Chemotherapy for Locally Advanced T4 Colon Cancer: A Nationwide Propensity-Score Matched Cohort Analysis. *Dig Surg* 2020; **37**: 292-301 [PMID: 31661689 DOI: 10.1159/000503446]
- Yuan Y, Xiao WW, Xie WH, Cai PQ, Wang QX, Chang H, Chen BQ, Zhou WH, Zeng ZF, Wu XJ, Liu Q, Li LR, Zhang R, Gao YH. Neoadjuvant chemoradiotherapy for patients with unresectable radically locally advanced colon cancer: a potential improvement to overall survival and decrease to multivisceral resection. *BMC Cancer* 2021; **21**: 179 [PMID: 33607964 DOI: 10.1186/s12885-021-07894-6]
- Niu SQ, Li RZ, Yuan Y, Xie WH, Wang QX, Chang H, Lu ZH, Ding PR, Li LR, Wu XJ, Zeng ZF, Xiao WW, Gao YH. Neoadjuvant chemoradiotherapy in patients with unresectable locally advanced sigmoid colon cancer: clinical feasibility and outcome. *Radiat Oncol* 2021; **16**: 93 [PMID: 34030722 DOI: 10.1186/s13014-021-01823-4]
- Laursen M, Dohrn N, Gögenur I, Klein MF. Neoadjuvant chemotherapy in patients undergoing colonic resection for locally advanced nonmetastatic colon cancer: A nationwide propensity score matched cohort study. *Colorectal Dis* 2022; **24**: 954-964 [PMID: 35285992 DOI: 10.1111/codi.16116]
- Morton D, Seymour M, Magill L, Handley K, Glasbey J, Glimelius B, Palmer A, Seligmann J, Laurberg S, Murakami K, West N, Quirke P, Gray R; FOCOT Collaborative Group. Preoperative Chemotherapy for Operable Colon Cancer: Mature Results of an International Randomized Controlled Trial. *J Clin Oncol* 2023; **41**: 1541-1552 [PMID: 36657089 DOI: 10.1200/JCO.22.00046]
- Chalabi M, Fanchi LF, Dijkstra KK, Van den Berg JG, Aalbers AG, Sikorska K, Lopez-Yurda M, Grootcholten C, Beets GL, Snaebjornsson P, Maas M, Mertz M, Veninga V, Bounova G, Broeks A, Beets-Tan RG, de Wijkerslooth TR, van Lent AU, Marsman HA, Nuijten E, Kok NF, Kuiper M, Verbeek WH, Kok M, Van Leerdam ME, Schumacher TN, Voest EE, Haanen JB. Neoadjuvant immunotherapy leads to pathological responses in MMR-proficient and MMR-deficient early-stage colon cancers. *Nat Med* 2020; **26**: 566-576 [PMID: 32251400 DOI: 10.1038/s41591-020-0805-8]
- Chalabi M, Verschoor YL, van den Berg JG, Sikorska K, Beets G, Lent AV, Grootcholten MC, Aalbers A, Buller N, Marsman H, Hendriks E, Burger PWA, Aukema T, Oosterling S, Beets-Tan R, Schumacher TN, van Leerdam M, Voest EE, Haanen JBAG. LBA7 Neoadjuvant immune checkpoint inhibition in locally advanced MMR-deficient colon cancer: The NICHE-2 study. *Ann Oncol* 2022; **33** Suppl 7: S808-S869 [DOI: 10.1016/j.annonc.2022.08.016]
- Hu H, Kang L, Zhang J, Wu Z, Wang H, Huang M, Lan P, Wu X, Wang C, Cao W, Hu J, Huang Y, Huang L, Shi L, Cai Y, Shen C, Ling J, Xie X, He X, Dou R, Zhou J, Ma T, Zhang X, Luo S, Deng W, Ling L, Liu H, Deng Y. Neoadjuvant PD-1 blockade with toripalimab, with or without celecoxib, in mismatch repair-deficient or microsatellite instability-high, locally advanced, colorectal cancer (PICC): a single-centre, parallel-group, non-comparative, randomised, phase 2 trial. *Lancet Gastroenterol Hepatol* 2022; **7**: 38-48 [PMID: 34688374 DOI: 10.1016/S2468-1253(21)00348-4]
- Verschoor YL, Van den Berg JE, Beets G, Sikorska K, Aalbers A, van Lent A, Grootcholten C, Huibregtse I, Marsman H, Oosterling S, van de Belt M, Kok M, Schumacher T, van Leerdam ME, Haanen JBAG, Voest EE, Chalabi M. Neoadjuvant nivolumab, ipilimumab, and celecoxib in MMR-proficient and MMR-deficient colon cancers: Final clinical analysis of the NICHE study. *J Clin Oncol* 2022; **40**: 3511-3511 [DOI: 10.1200/JCO.2022.40.16_suppl.3511]
- Agha RA, Franchi T, Sohrabi C, Mathew G, Kerwan A; SCARE Group. The SCARE 2020 Guideline: Updating Consensus Surgical Case Report (SCARE) Guidelines. *Int J Surg* 2020; **84**: 226-230 [PMID: 33181358 DOI: 10.1016/j.ijsu.2020.10.034]
- Kavun A, Veselovsky E, Lebedeva A, Belova E, Kuznetsova O, Yakushina V, Grigoreva T, Mileyko V, Fedyanin M, Ivanov M. Microsatellite Instability: A Review of Molecular Epidemiology and Implications for Immune Checkpoint Inhibitor Therapy. *Cancers (Basel)* 2023; **15** [PMID: 37190216 DOI: 10.3390/cancers15082288]
- Llora NJ, Cruise M, Tam A, Wicks EC, Hechenbleikner EM, Taube JM, Blosser RL, Fan H, Wang H, Lubner BS, Zhang M, Papadopoulos N, Kinzler KW, Vogelstein B, Sears CL, Anders RA, Pardoll DM, Housseau F. The vigorous immune microenvironment of microsatellite instable colon cancer is balanced by multiple counter-inhibitory checkpoints. *Cancer Discov* 2015; **5**: 43-51 [PMID: 25358689 DOI: 10.1158/2159-8290.CD-14-0863]
- Pei F, Wu J, Zhao Y, He W, Yao Q, Huang M, Huang J. Single-Agent Neoadjuvant Immunotherapy With a PD-1 Antibody in Locally Advanced Mismatch Repair-Deficient or Microsatellite Instability-High Colorectal Cancer. *Clin Colorectal Cancer* 2023; **22**: 85-91 [PMID: 36528470 DOI: 10.1016/j.clcc.2022.11.004]
- Han K, Tang JH, Liao LE, Jiang W, Sui QQ, Xiao BY, Li WR, Hong ZG, Li Y, Kong LH, Li DD, Zhang XS, Pan ZZ, Steele SR, Ding PR. Neoadjuvant Immune Checkpoint Inhibition Improves Organ Preservation in T4bM0 Colorectal Cancer With Mismatch Repair Deficiency: A Retrospective Observational Study. *Dis Colon Rectum* 2023; **66**: e996-e1005 [PMID: 35485833 DOI: 10.1097/DCR.0000000000002466]



Published by **Baishideng Publishing Group Inc**
7041 Koll Center Parkway, Suite 160, Pleasanton, CA 94566, USA

Telephone: +1-925-3991568

E-mail: bpgoffice@wjgnet.com

Help Desk: <https://www.f6publishing.com/helpdesk>

<https://www.wjgnet.com>

