

# World Journal of *Gastroenterology*

*World J Gastroenterol* 2024 March 7; 30(9): 994-1260



## EDITORIAL

- 994 Role of exosomal circular RNAs as microRNA sponges and potential targeting for suppressing hepatocellular carcinoma growth and progression  
*Papadopoulos N, Trifylli EM*
- 999 Role of albumin-bilirubin score in non-malignant liver disease  
*Xu SX, Yang F, Ge N, Guo JT, Sun SY*
- 1005 Early prediction and prevention of infected pancreatic necrosis  
*Lv C, Zhang ZX, Ke L*
- 1011 Impact of microplastics and nanoplastics on liver health: Current understanding and future research directions  
*Chiang CC, Yeh H, Shiu RF, Chin WC, Yen TH*

## GUIDELINES

- 1018 National guidelines for the diagnosis and treatment of hilar cholangiocarcinoma  
*Dar FS, Abbas Z, Ahmed I, Atique M, Aujla UI, Azeemuddin M, Aziz Z, Bhatti ABH, Bangash TA, Butt AS, Butt OT, Dogar AW, Farooqi JI, Hanif F, Haider J, Haider S, Hassan SM, Jabbar AA, Khan AN, Khan MS, Khan MY, Latif A, Luck NH, Malik AK, Rashid K, Rashid S, Salih M, Saeed A, Salamat A, Tayyab GUN, Yusuf A, Zia HH, Naveed A*

## REVIEW

- 1043 Diseases of bile duct in children  
*Eiamkulbutr S, Tubjareon C, Sanpavat A, Phewplung T, Srisan N, Sintusek P*
- 1073 From liver to hormones: The endocrine consequences of cirrhosis  
*Quiroz-Aldave JE, Gamarra-Osorio ER, Durand-Vásquez MDC, Rafael-Robles LDP, Gonzáles-Yovera JG, Quispe-Flores MA, Concepción-Urteaga LA, Román-González A, Paz-Ibarra J, Concepción-Zavaleta MJ*

## MINIREVIEWS

- 1096 Prediction, prevention and management of gastroesophageal reflux after per-oral endoscopic myotomy: An update  
*Nabi Z, Inavolu P, Duvvuru NR*

## ORIGINAL ARTICLE

## Clinical Trials Study

- 1108 Clinical manifestation, lifestyle, and treatment patterns of chronic erosive gastritis: A multicenter real-world study in China  
*Yang YY, Li KM, Xu GF, Wang CD, Xiong H, Wang XZ, Wang CH, Zhang BY, Jiang HX, Sun J, Xu Y, Zhang LJ, Zheng HX, Xing XB, Wang LJ, Zuo XL, Ding SG, Lin R, Chen CX, Wang XW, Li JN*

- 1121** Detachable string magnetically controlled capsule endoscopy for the noninvasive diagnosis of esophageal diseases: A prospective, blind clinical study

*Yang YL, Qin HW, Chen ZY, Fan HN, Yu Y, Da W, Zhu JS, Zhang J*

- 1132** Melanocortin 3,5 receptors immunohistochemical expression in colonic mucosa of inflammatory bowel disease patients: A matter of disease activity?

*Gravina AG, Panarese I, Trotta MC, D'Amico M, Pellegrino R, Ferraraccio F, Galdiero M, Alfano R, Grieco P, Federico A*

### Observational Study

- 1143** Double-nylon purse-string suture in closing postoperative wounds following endoscopic resection of large ( $\geq 3$  cm) gastric submucosal tumors

*Wang SS, Ji MY, Huang X, Li YX, Yu SJ, Zhao Y, Shen L*

- 1154** Recent trends in the epidemiology and clinical outcomes of inflammatory bowel disease in South Korea, 2010-2018

*Kim S, Lee HJ, Lee SW, Park S, Koh SJ, Im JP, Kim BG, Han KD, Kim JS*

### Prospective Study

- 1164** Staging liver fibrosis with various diffusion-weighted magnetic resonance imaging models

*Jiang YL, Li J, Zhang PF, Fan FX, Zou J, Yang P, Wang PF, Wang SY, Zhang J*

- 1177** sTREM-1 as promising prognostic biomarker for acute-on-chronic liver failure and mortality in patients with acute decompensation of cirrhosis

*Yu SM, Li H, Deng GH, Wang XB, Zheng X, Chen JJ, Meng ZJ, Zheng YB, Gao YH, Qian ZP, Liu F, Lu XB, Shi Y, Shang J, Chen RC, Huang Y*

### Basic Study

- 1189** Uridine diphosphate glucuronosyltransferase 1A1 prevents the progression of liver injury

*Jiang JL, Zhou YY, Zhong WW, Luo LY, Liu SY, Xie XY, Mu MY, Jiang ZG, Xue Y, Zhang J, He YH*

### SYSTEMATIC REVIEWS

- 1213** Treatment of *Helicobacter pylori* with potassium competitive acid blockers: A systematic review and meta-analysis

*Kanu JE, Soldera J*

### SCIENTOMETRICS

- 1224** Telomerase-related advances in hepatocellular carcinoma: A bibliometric and visual analysis

*Li HY, Zheng LL, Hu N, Wang ZH, Tao CC, Wang YR, Liu Y, Aizimuaji Z, Wang HW, Zheng RQ, Xiao T, Rong WQ*

### CASE REPORT

- 1237** PRaG 3.0 therapy for human epidermal growth factor receptor 2-positive metastatic pancreatic ductal adenocarcinoma: A case report

*Kong YH, Xu ML, Zhang JJ, Chen GQ, Hong ZH, Zhang H, Dai XX, Ma YF, Zhao XR, Zhang CY, Chen RZ, Xing PF, Zhang LY*

**LETTER TO THE EDITOR**

- 1250** Genetic risk stratification of inflammatory bowel disease-associated venous thromboembolism: An Asian perspective  
*Huang JG*
- 1253** Risk of hepatitis B virus reactivation in oncological patients treated with tyrosine kinase inhibitors: A case report and literature analysis  
*Colapietro F, Pugliese N, Voza A, Aghemo A, De Nicola S*
- 1257** Exploring non-curative endoscopic submucosal dissection: Current treatment optimization and future indication expansion  
*Zhu YN, Yuan XL, Liu W, Zhang YH, Mou Y, Hu B, Ye LS*



**ABOUT COVER**

Editorial Board Member of *World Journal of Gastroenterology*, Pal Miheller, MD, PhD, Assistant Professor, Department of Surgery, Transplantation and Gastroenterology, Head of Gastroenterology, Semmelweis University, Budapest H-1088, Pest, Hungary. [miheller.pal@semmelweis.hu](mailto:miheller.pal@semmelweis.hu)

**AIMS AND SCOPE**

The primary aim of *World Journal of Gastroenterology* (WJG, *World J Gastroenterol*) is to provide scholars and readers from various fields of gastroenterology and hepatology with a platform to publish high-quality basic and clinical research articles and communicate their research findings online. WJG mainly publishes articles reporting research results and findings obtained in the field of gastroenterology and hepatology and covering a wide range of topics including gastroenterology, hepatology, gastrointestinal endoscopy, gastrointestinal surgery, gastrointestinal oncology, and pediatric gastroenterology.

**INDEXING/ABSTRACTING**

The WJG is now abstracted and indexed in Science Citation Index Expanded (SCIE), MEDLINE, PubMed, PubMed Central, Scopus, Reference Citation Analysis, China Science and Technology Journal Database, and Superstar Journals Database. The 2023 edition of Journal Citation Reports® cites the 2022 impact factor (IF) for WJG as 4.3; Quartile category: Q2. The WJG's CiteScore for 2021 is 8.3.

**RESPONSIBLE EDITORS FOR THIS ISSUE**

Production Editor: Hua-Ge Yu; Production Department Director: Xu Guo; Editorial Office Director: Jia-Ru Fan.

**NAME OF JOURNAL**

*World Journal of Gastroenterology*

**ISSN**

ISSN 1007-9327 (print) ISSN 2219-2840 (online)

**LAUNCH DATE**

October 1, 1995

**FREQUENCY**

Weekly

**EDITORS-IN-CHIEF**

Andrzej S Tarnawski

**EXECUTIVE ASSOCIATE EDITORS-IN-CHIEF**

Xian-Jun Yu (Pancreatic Oncology), Jian-Gao Fan (Chronic Liver Disease), Hou-Bao Liu (Biliary Tract Disease)

**EDITORIAL BOARD MEMBERS**

<http://www.wjgnet.com/1007-9327/editorialboard.htm>

**PUBLICATION DATE**

March 7, 2024

**COPYRIGHT**

© 2024 Baishideng Publishing Group Inc

**PUBLISHING PARTNER**

Shanghai Pancreatic Cancer Institute and Pancreatic Cancer Institute, Fudan University  
Biliary Tract Disease Institute, Fudan University

**INSTRUCTIONS TO AUTHORS**

<https://www.wjgnet.com/bpg/gerinfo/204>

**GUIDELINES FOR ETHICS DOCUMENTS**

<https://www.wjgnet.com/bpg/GerInfo/287>

**GUIDELINES FOR NON-NATIVE SPEAKERS OF ENGLISH**

<https://www.wjgnet.com/bpg/gerinfo/240>

**PUBLICATION ETHICS**

<https://www.wjgnet.com/bpg/GerInfo/288>

**PUBLICATION MISCONDUCT**

<https://www.wjgnet.com/bpg/gerinfo/208>

**POLICY OF CO-AUTHORS**

<https://www.wjgnet.com/bpg/GerInfo/310>

**ARTICLE PROCESSING CHARGE**

<https://www.wjgnet.com/bpg/gerinfo/242>

**STEPS FOR SUBMITTING MANUSCRIPTS**

<https://www.wjgnet.com/bpg/GerInfo/239>

**ONLINE SUBMISSION**

<https://www.f6publishing.com>

**PUBLISHING PARTNER's OFFICIAL WEBSITE**

<https://www.shca.org.cn>  
<https://www.zs-hospital.sh.cn>



## PRaG 3.0 therapy for human epidermal growth factor receptor 2-positive metastatic pancreatic ductal adenocarcinoma: A case report

Yue-Hong Kong, Mei-Ling Xu, Jun-Jun Zhang, Guang-Qiang Chen, Zhi-Hui Hong, Hong Zhang, Xiao-Xiao Dai, Yi-Fu Ma, Xiang-Rong Zhao, Chen-Yang Zhang, Rong-Zheng Chen, Peng-Fei Xing, Li-Yuan Zhang

**Specialty type:** Oncology

**Provenance and peer review:**

Unsolicited article; Externally peer reviewed.

**Peer-review model:** Single blind

**Peer-review report's scientific quality classification**

Grade A (Excellent): 0

Grade B (Very good): B

Grade C (Good): 0

Grade D (Fair): 0

Grade E (Poor): 0

**P-Reviewer:** Cochior D, Romania

**Received:** December 6, 2023

**Peer-review started:** December 6, 2023

**First decision:** January 4, 2024

**Revised:** January 6, 2024

**Accepted:** February 4, 2024

**Article in press:** February 4, 2024

**Published online:** March 7, 2024



Yue-Hong Kong, Mei-Ling Xu, Jun-Jun Zhang, Yi-Fu Ma, Xiang-Rong Zhao, Chen-Yang Zhang, Rong-Zheng Chen, Peng-Fei Xing, Li-Yuan Zhang, Center for Cancer Diagnosis and Treatment, The Second Affiliated Hospital of Soochow University, Suzhou 215000, Jiangsu Province, China

Yue-Hong Kong, Mei-Ling Xu, Jun-Jun Zhang, Yi-Fu Ma, Xiang-Rong Zhao, Chen-Yang Zhang, Rong-Zheng Chen, Peng-Fei Xing, Li-Yuan Zhang, Department of Radiotherapy & Oncology, The Second Affiliated Hospital of Soochow University, Suzhou 215000, Jiangsu Province, China

Yue-Hong Kong, Mei-Ling Xu, Jun-Jun Zhang, Yi-Fu Ma, Xiang-Rong Zhao, Chen-Yang Zhang, Rong-Zheng Chen, Peng-Fei Xing, Li-Yuan Zhang, Institution of Radiotherapy & Oncology, Soochow University, Suzhou 215000, Jiangsu Province, China

Guang-Qiang Chen, Department of Radiology, The Second Affiliated Hospital of Soochow University, Suzhou 215000, Jiangsu Province, China

Zhi-Hui Hong, Department of Nuclear Medicine, The Second Affiliated Hospital of Soochow University, Suzhou 215000, Jiangsu Province, China

Hong Zhang, Department of Clinical Laboratory, The Second Affiliated Hospital of Soochow University, Suzhou 215000, Jiangsu Province, China

Xiao-Xiao Dai, Department of Pathology, The Second Affiliated Hospital of Soochow University, Suzhou 215000, Jiangsu Province, China

**Corresponding author:** Li-Yuan Zhang, PhD, Chief Physician, Center for Cancer Diagnosis and Treatment, The Second Affiliated Hospital of Soochow University, No. 1055, Sanxiang Road, Suzhou 215000, Jiangsu Province, China. [zhangliyuan@suda.edu.cn](mailto:zhangliyuan@suda.edu.cn)

### Abstract

#### BACKGROUND

Pancreatic ductal adenocarcinoma (PDAC) is a highly fatal disease with limited effective treatment especially after first-line chemotherapy. The human epidermal growth factor receptor 2 (HER-2) immunohistochemistry (IHC) positive is associated with more aggressive clinical behavior and shorter overall survival in PDAC.

#### CASE SUMMARY

We present a case of multiple metastatic PDAC with IHC mismatch repair proficient but HER-2 IHC weakly positive at diagnosis that didn't have tumor regression after first-line nab-paclitaxel plus gemcitabine and PD-1 inhibitor treatment. A novel combination therapy PRaG 3.0 of RC48 (HER2-antibody-drug conjugate), radiotherapy, PD-1 inhibitor, granulocyte-macrophage colony-stimulating factor and interleukin-2 was then applied as second-line therapy and the patient had confirmed good partial response with progress-free-survival of 6.5 months and overall survival of 14.2 month. She had not developed any grade 2 or above treatment-related adverse events at any point. Percentage of peripheral CD8<sup>+</sup>Temra and CD4<sup>+</sup>Temra were increased during first two activation cycles of PRaG 3.0 treatment containing radiotherapy but deceased to the baseline during the maintenance cycles containing no radiotherapy.

## CONCLUSION

PRaG 3.0 might be a novel strategy for HER2-positive metastatic PDAC patients who failed from previous first-line approach and even PD-1 immunotherapy but needs more data in prospective trials.

**Key Words:** Pancreatic ductal adenocarcinoma; PRaG 3.0 therapy; Human epidermal growth factor receptor 2; Novel combination therapy; Case report

©The Author(s) 2024. Published by Baishideng Publishing Group Inc. All rights reserved.

**Core Tip:** Pancreatic ductal adenocarcinoma (PDAC) is the fourth leading cause of cancer-related death worldwide. Herein, we present a case of multiple metastatic PDAC with immunohistochemistry (IHC) mismatch repair proficient but human epidermal growth factor receptor 2 (HER-2) IHC weakly positive at diagnosis that didn't have tumor regression after first-line nab-paclitaxel plus gemcitabine and PD-1 inhibitor treatment. A novel combination therapy PRaG 3.0 of RC48 (HER2-antibody-drug conjugate), radiotherapy, PD-1 inhibitor, granulocyte-macrophage colony-stimulating factor and interleukin-2 was then applied as second-line therapy and the patient had confirmed good partial response with progress-free-survival of 6.5 months. We proposed that PRaG 3.0 might be a good therapeutic strategy for HER2-positive metastatic PDAC patients who failed from previous first-line approach and even PD-1 immunotherapy.

**Citation:** Kong YH, Xu ML, Zhang JJ, Chen GQ, Hong ZH, Zhang H, Dai XX, Ma YF, Zhao XR, Zhang CY, Chen RZ, Xing PF, Zhang LY. PRaG 3.0 therapy for human epidermal growth factor receptor 2-positive metastatic pancreatic ductal adenocarcinoma: A case report. *World J Gastroenterol* 2024; 30(9): 1237-1249

**URL:** <https://www.wjgnet.com/1007-9327/full/v30/i9/1237.htm>

**DOI:** <https://dx.doi.org/10.3748/wjg.v30.i9.1237>

## INTRODUCTION

Pancreatic ductal adenocarcinoma (PDAC) accounts for more than 90% of pancreatic tumors. Due to it is typically diagnosed at an advanced stage and the tumor metastasis has been happened, the prognosis of PDAC is very poor with average survival time less than one year[1]. Modified FOLFIRINOX (fluorouracil, folinic acid, irinotecan, and oxaliplatin) or AG (gemcitabine and albumin-bound paclitaxel) was recommended as first-line therapy for metastatic PDAC. However, PDAC demonstrated significant resistance to these chemotherapies. Besides, the effectiveness of novel immunotherapies has been limited to certain tumor types classified as highly "immunogenic", such as lung cancer and melanoma; while PDAC with a unique immunosuppressive microenvironment and a low tumor mutational burden[2], has typically resisted to immunotherapies, as demonstrated in majority of phase I and II clinical trials.

The human epidermal growth factor receptor 2 (HER-2) protein regulates cell proliferation, apoptosis, differentiation and angiogenesis. HER-2 overexpression is linked to tumorigenesis, more aggressive clinical behavior, and shorter overall survival (OS) in a variety of human malignancies. About 7% to 58% of pancreatic tumors exhibit an overexpression of the HER-2 gene[3]. Although HER-2 targeting therapy showed efficacy in diverse malignancies, including breast, gastric, and lung cancers, the clinical trials of targeted HER-2 therapy, including trastuzumab, did not improve OS nor progress-free-survival (PFS) in metastatic PDAC[4]. New combination treatment approaches for HER2-positive metastatic PDAC are thus needed.

Here, we present a case of liver multiple metastatic PDAC patient with immunohistochemistry (IHC) microsatellite stability (MSS) and HER-2 positive. She failed from first-line AG chemotherapy and PD-1 inhibitor, but received a notable response after changing to a novel combination treatment of HER-2 antibody-drug conjugate (ADC), PD-1 inhibitor, hypofractionated radiotherapy, sequential granulocyte-macrophage colony-stimulating factor (GM-CSF) and interleukin-2 (IL-2), which was named as PRaG 3.0 therapy.

## CASE PRESENTATION

### Chief complaints

A 53-year-old Chinese woman presented with abdominal pain and diagnosed with advanced pancreatic cancer.

### History of present illness

The patient was diagnosed with metastatic pancreatic cancer in October 2021. She was initially treated with nab-paclitaxel plus gemcitabine and tislelizumab. She received two cycles of therapy and enhanced computed tomography (CT) was evaluated to find no decrease in both pancreatic tumor and hepatic metastases, leading to overall response as stable disease. Allergic reaction occurred with severe rash and itching in the second cycle of therapy, which was considered to be related to chemotherapy.

### History of past illness

The patient had a history of pancreatitis in 2020, no history of hypertension, diabetes, or heart disease.

### Personal and family history

No personal and family history of tumors.

### Physical examination

Slight tenderness in the left abdomen.

### Laboratory examinations

Liver mass puncture pathology showed pancreaticobiliary tumor, with IHC: HER-2(+), Hepar1(-), GPC3(-), CD34(+), CK19(+), CK(+), CK8/18(+), EGFR(1+), Ki67(+20%), MLH1(+), MSH2(+), PMS2(+), MSH6(+) (Figure 1A).

### Imaging examinations

Mass shadow in the pancreatic tail with splenic artery invasion was shown in CT scan. Multiple liver abnormal signal focus and multiple enlarged retroperitoneal lymph nodes were observed, which were considered as metastases.

## FINAL DIAGNOSIS

Based on the above clinical history and findings, the patient was diagnosed with HER-2 positive metastatic PDAC.

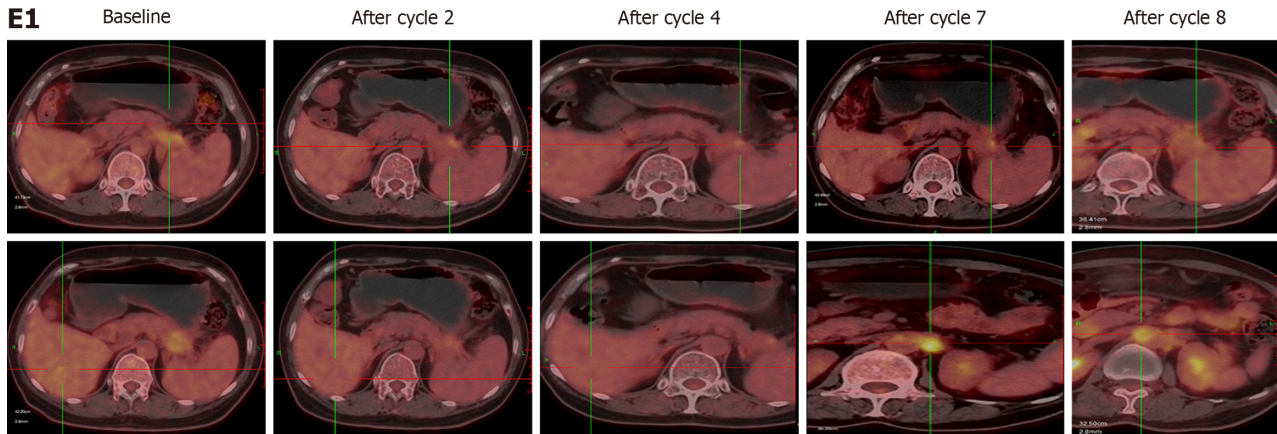
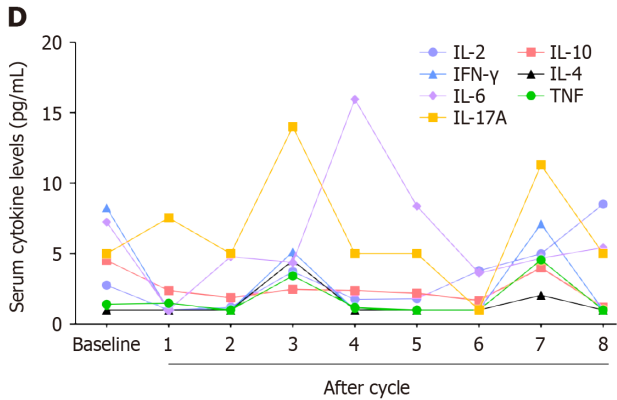
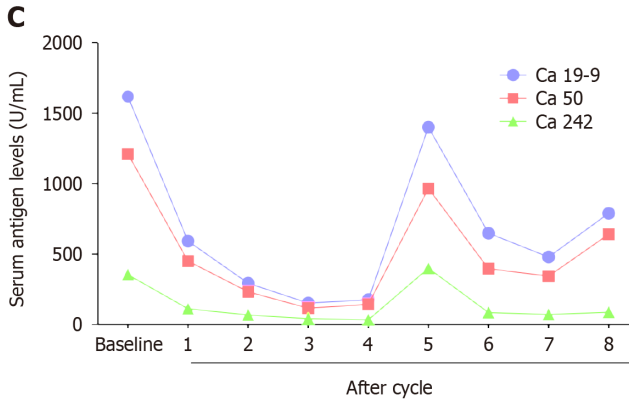
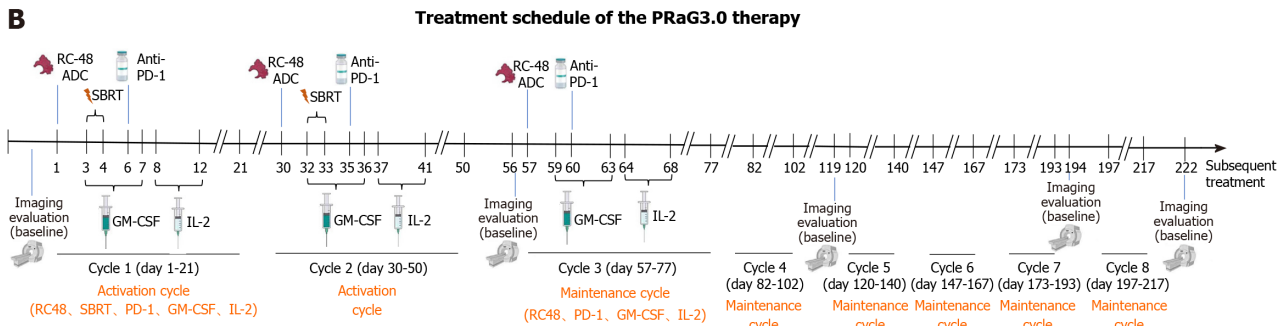
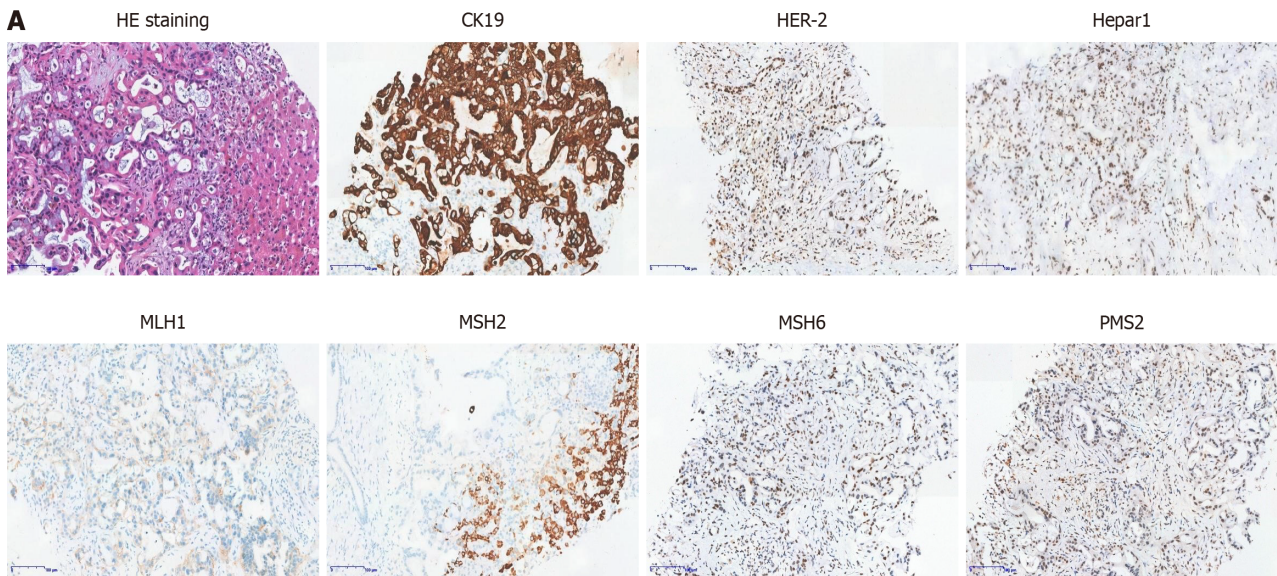
## TREATMENT

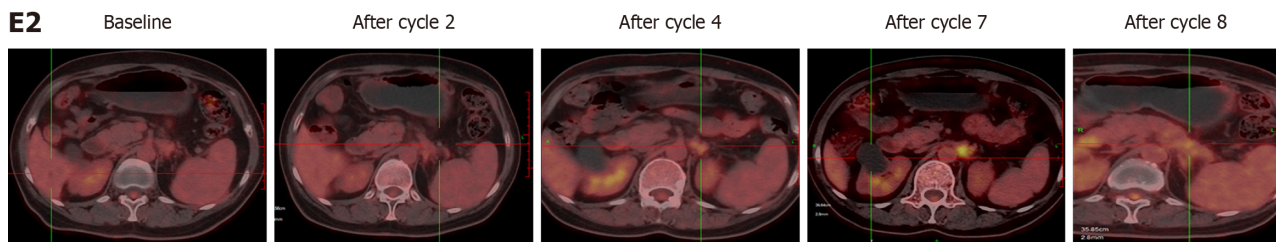
The patient came to started PRaG 3.0 therapy (NCT05115500) from 12-17-2021. Disitamab vedotin (RC48, a HER2-ADC) 110 mg (2 mg/kg) was intravenously administered on day 1, and then stereotactic body radiotherapy (SBRT) (8 Gy × 2 fractions) was delivered to the pancreatic lesion on day 3 and 4. GM-CSF (molgramostim) 200 µg was injected subcutaneously daily for five days concurrently with SBRT (day 3-7), and then recombinant human IL-2 200 million IU was injected subcutaneously daily for five days sequential after GM-CSF (day 8-12). Anti-PD-1 antibody penpulimab was intravenously administered within one week after completion of SBRT. The PRaG 3.0 therapy was repeated every 21 d for a cycle (the protocol of PRaG 3.0 is shown in Figure 1B). After two activation cycles, she received maintenance cycle. In each maintenance cycle, RC48 (2 mg/kg) was intravenously administered on day 1, GM-CSF (molgramostim) 200 µg was injected subcutaneously daily for five days (day 3-7) and then recombinant human IL-2 200 million IU was injected subcutaneously daily for five days sequential after GM-CSF (day 8-12). Anti-PD-1 antibody penpulimab was intravenously administered every 21 d for a cycle.

## OUTCOME AND FOLLOW-UP

After two activation cycles of PRaG 3.0, the unirradiated liver metastatic lesions had a radiographic response of partial response (PR), and fluorodeoxyglucose (FDG) metabolism was significantly lower than before. The unirradiated paraaortic lymph nodes had no significant changes in size but decreased in FDG metabolism. The irradiated primary tumor reduced in size markedly and decreased in FDG metabolism (Figure 1E). Serum carbohydrate antigen 19-9 (Ca 19-9) decreased from 1617 to 176 U/mL, Ca 50 decreased from 1210 to 116 U/mL, Ca 242 decreased from 353.5 to 33.4 U/mL (Figure 1C). After four cycles, the radiographic evaluation confirmed good PR with further shrinkage of liver lesions. The paraaortic lymph nodes had no significant changes in size but increased in FDG metabolism (Figure 1E). After seven cycles, the paraaortic lymph nodes were slightly larger and higher in standard uptake value (SUV) metabolism. After eight cycles, new lesions of paraaortic lymph nodes were found with high SUV metabolism (Figure 1E) and the patient was evaluated progressive disease (PD) with PFS of 6.5 months and overall survival (OS) of 14.2 months. The serum Ca 19-9, Ca 50 and Ca 242 levels rebounded suddenly after the fifth cycle, and then decreased after six and seven cycles.







**Figure 1 Treatment schedule of the PRaG3.0 therapy and treatment efficacy evaluation of the patient.** A: Hematoxylin and eosin staining and immunohistochemistry assay for CK19, human epidermal growth factor receptor 2 (HER-2), Hepar1, MLH1, MSH2, MSH6 and PMS2 of liver lesions. CK19 was expressed in tumor cells but Hepar1 was not expressed. HER-2 was weakly expressed in tumor cell membranes. MLH1, MSH2, MSH6 and PMS2 were expressed in tumors indicating mismatch repair proficient; B: Treatment schedule of the PRaG3.0 therapy. The patient received two activation cycle and six maintenance cycle. The time of positron emission tomography-computed tomography (PET-CT) was also indicated; C: Serum carbohydrate antigen 19-9 (Ca 19-9), Ca 50 and Ca 242 levels of the patient during the treatment; D: Peripheral cytokines [interleukin (IL)-2, IL-4, IL-6, IL-10, IL-17A, tumor necrosis factor and interferon- $\gamma$ ] levels changes of the patient during the treatment. E: The PET-CT evaluation of the patient at baseline and after cycle 2, 4, 7 and 8. ADC: Antibody-drug conjugate; Ca: Carbohydrate antigen; GM-CSF: Granulocyte-macrophage colony-stimulating factor; HE: Hematoxylin and eosin; HER-2: Human epidermal growth factor receptor 2; IFN: Interferon; IL: Interleukin; SBRT: Stereotactic body radiotherapy; TNF: Tumor necrosis factor.

(Figure 1C). The patient got grade 1 fatigue, alopecia, and transient hyperthyroidism, which was self-recovered without medication. There were no grade 2 or above treatment-related adverse events at any point during PRaG 3.0 treatment.

## DISCUSSION

PDAC is the fourth leading cause of cancer-related death worldwide. AG and FOLFIRINOX have been established as standard first-line treatment in metastatic PDAC. First-line AG chemotherapy was reported to lead to a more prolonged OS than single-agent gemcitabine (median OS, 8.5 months *vs* 6.7 months;  $P < 0.001$ ) in metastatic PDAC in the phase III MPACT trial[5]. Our case failed from first-line AG chemotherapy with grade 3 toxicity. She also received PD-1 treatment meanwhile with no satisfactory response. Indeed, MSS PDAC has little response to single-agent anti-PD-1 therapy, while the results of the combination of anti-PD-1 with anti-CTLA-4 were also disappointing. In a phase II trial, durvalumab (a PD-L1 inhibitor) alone or in combination with tremilumab (a CTLA-4 inhibitor) was given to 65 patients with refractory metastatic PDAC[6]. The results showed that the median OS was 3.6 months *vs* 3.1 months. It is considered that PDAC's immune-quiescent and -suppressive tumor microenvironment is responsible for its resistance to immune checkpoint inhibitors. Therapies that can convert its immunological "cold" to "hot" status may be effective for improving treatments outcomes.

PRaG therapy was an innovative oncology treatment modality that was first proposed in 2019, which consisted of a combination of PD-1 inhibitor (P), radiotherapy (Ra), and GM-CSF (G), for the treatment of chemo-refractory patients with metastatic solid tumors. In our previous study, PRaG therapy showed continuously synergistic anti-tumor immune effect[7]. Thus, for HER-2 IHC positive metastatic solid tumor patients, we proposed PRaG 3.0 therapy (NCT05115500) this time.

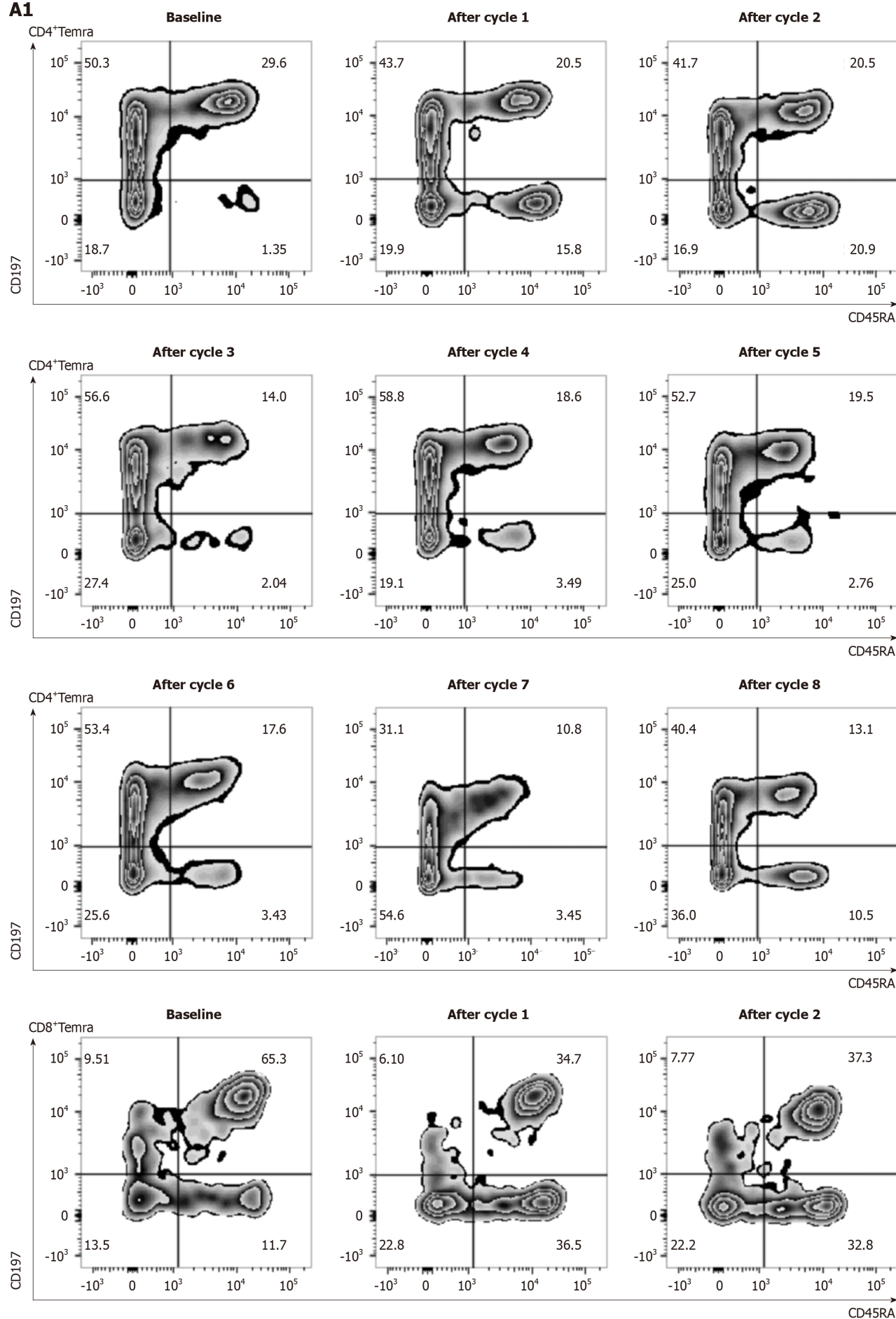
Reprogramming the tumor microenvironment, radiotherapy may enhance the anti-PD-1 effects by inducing both anti-tumor immune and immunosuppressive cells. For example, SBRT treatment can increase the percentage of PD-1<sup>+</sup>T effectors in PDAC tumors, however, the amount and function of these effectors are likely constrained by overwhelming myeloid suppressor burden[8], suggesting that more comprehensive therapies are necessary for best benefit. In PRaG therapy, GM-CSF is important for the maturation of dendritic cells and enhancing tumor antigens presentation to the immune system. Additionally, GM-CSF increases IL-2-activated killer activity and antibody-dependent cytotoxicity[9].

In PRaG 3.0, we added HER2 ADC (RC48) and IL-2 to the original PRaG regimen. RC48 (Disitamab vedotin) is a novel ADC with a humanized monoclonal antibody targeting HER-2 conjugated to a small molecule toxin monomethyl auristatin E, a synthetic antineoplastic agent. RC48 has revealed a promising efficacy with acceptable safety in patients with HER-2 positive advanced tumors[10]. IL-2 can further activate natural killer cells to kill PDAC cells. The five components in PRaG 3.0 cooperate with each other to form a multi-target therapeutic system. The combination of RC48 and PD-1/PD-L1 demonstrated synergistic efficacy and exerted long-lasting anti-tumor immunity in pre-clinical study [11]. SBRT can release tumor antigens and convert tumors into an in-situ vaccine, synergizing with PD-1/PD-L1 inhibitors. GM-CSF and IL-2 are immunomodulatory cytokines, promoting antigen-presenting cell activities and amplifying T cell immune response. In our case, the patient failed from previous first-line AG and anti-PD-1 treatment. The HER-2 was weakly expressed in tumor tissues of this patient, which indicated that she might benefit from combination therapy. Actually, she received indeed an exerted favorable response from the novel combination therapy with mild adverse reactions. It indicated that PRaG 3.0 therapy had altered the patient's responsiveness to PD-1 inhibitor.

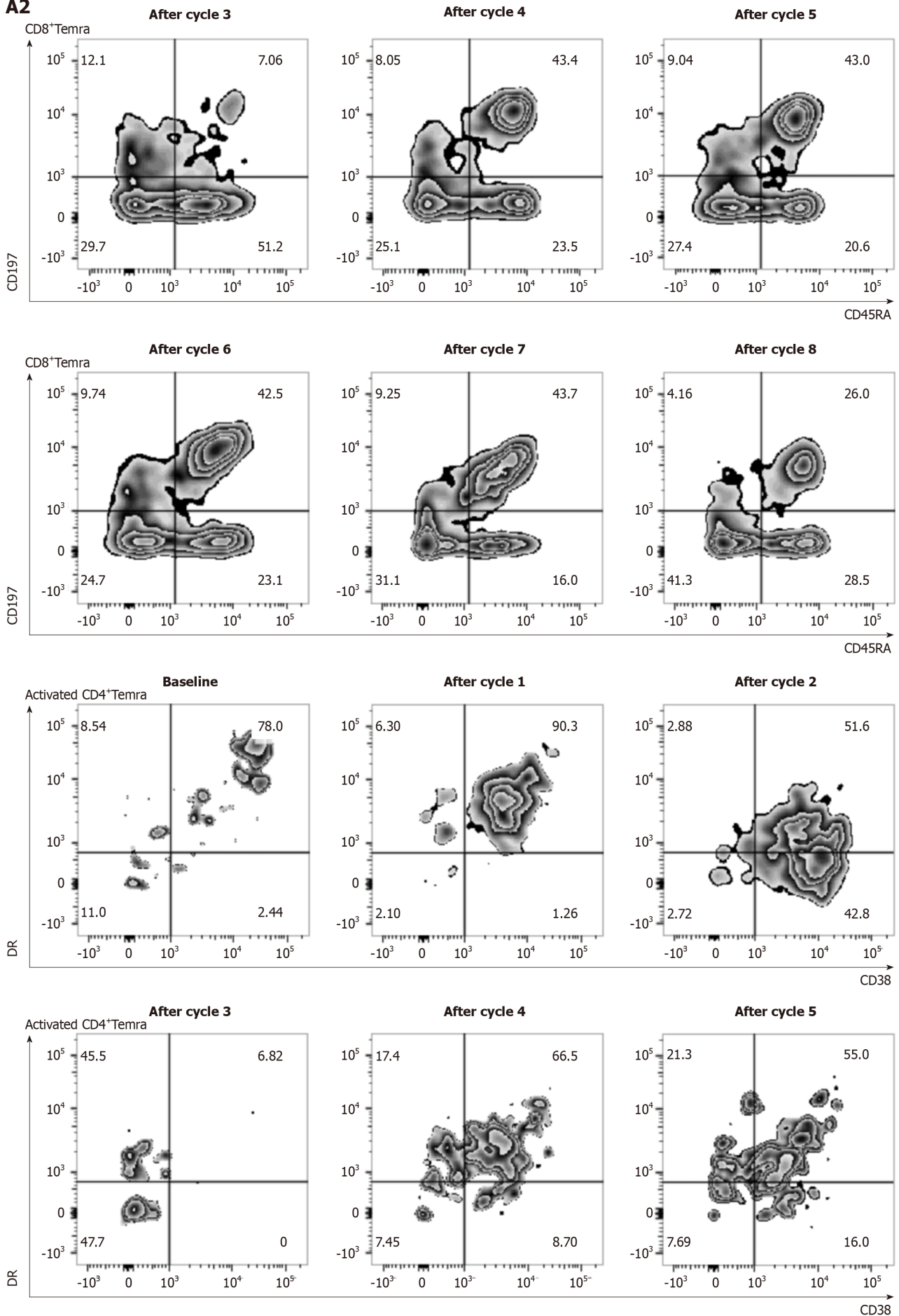
The levels of cytokines like IL-2, IL-4, IL-6, IL-10, IL-17A, tumor necrosis factor and interferon- $\gamma$  in peripheral blood were evaluated but no changes related to treatment efficacy were observed (Figure 1D). The percentage of peripheral effector memory CD3<sup>+</sup>CD197<sup>+</sup>CD45RA<sup>+</sup>CD8<sup>+</sup>T cells (Temra) (Figure 2A) and CD4<sup>+</sup>Temra in peripheral blood were increased after first two treatment cycles which contain radiotherapy but decreased to the baseline during the maintenance cycles without radiotherapy. The activated human leukocyte antigens (HLA)-DR<sup>+</sup>CD38<sup>+</sup>CD4<sup>+</sup>Temra, activated HLA-DR<sup>+</sup>

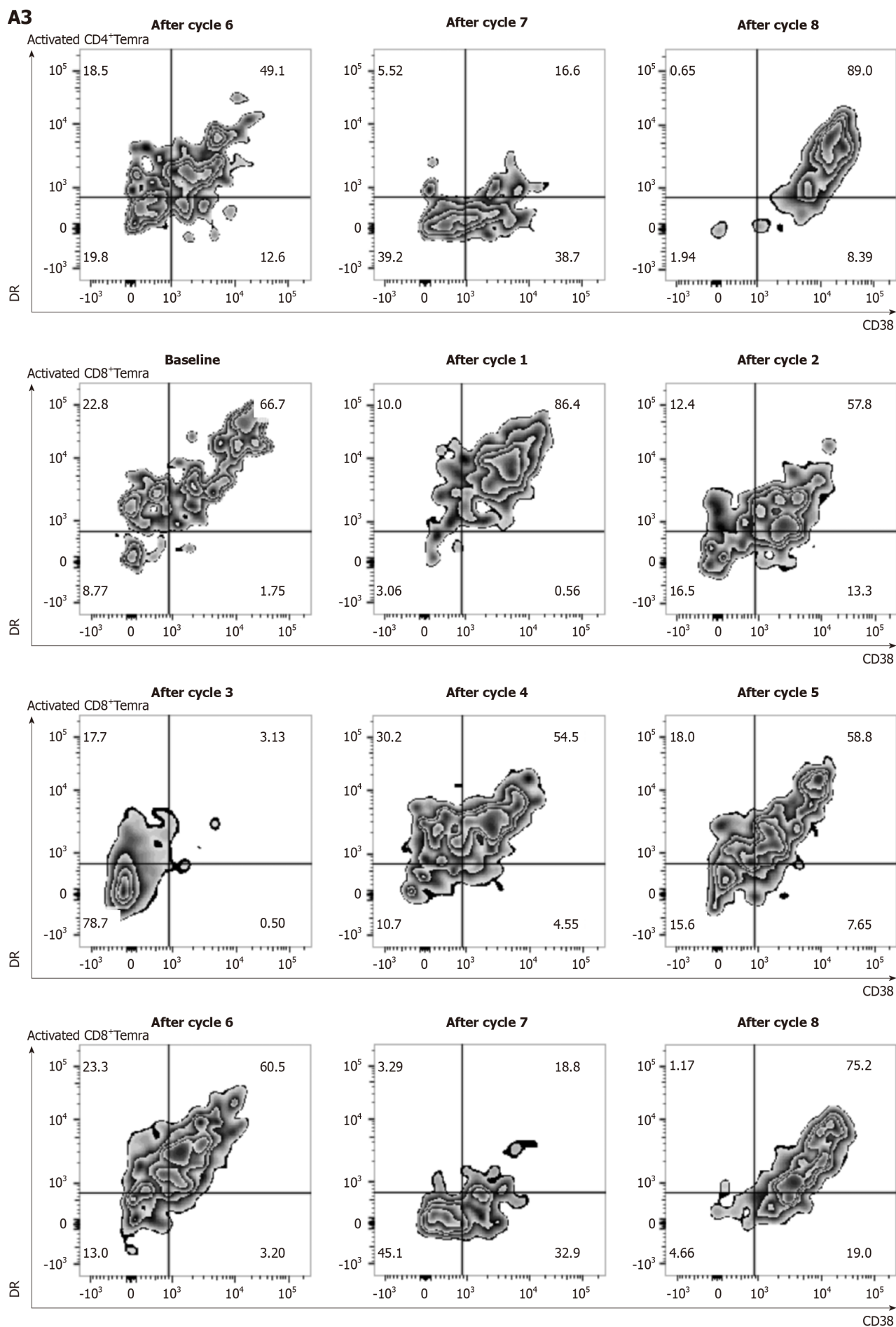


**A1**

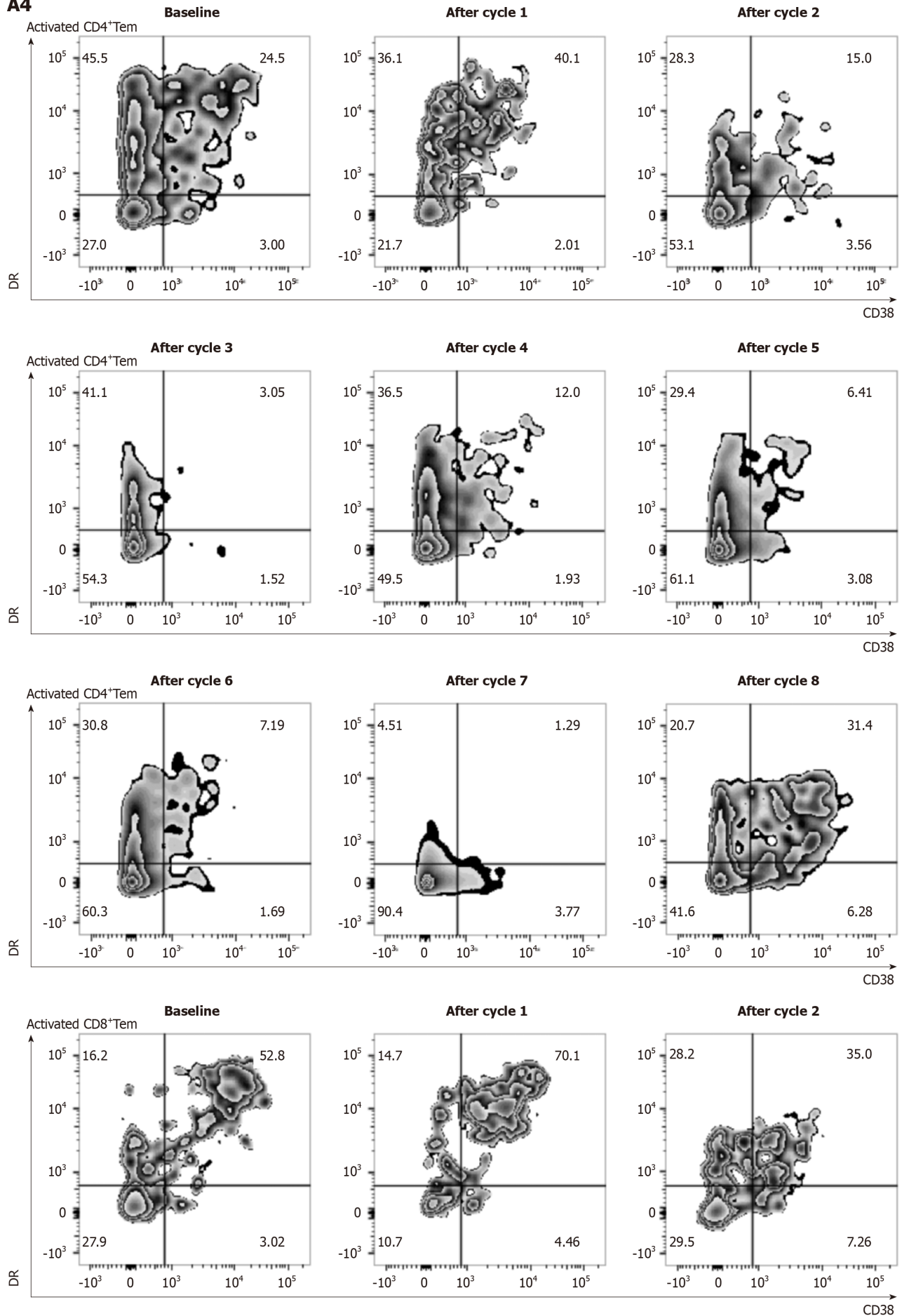


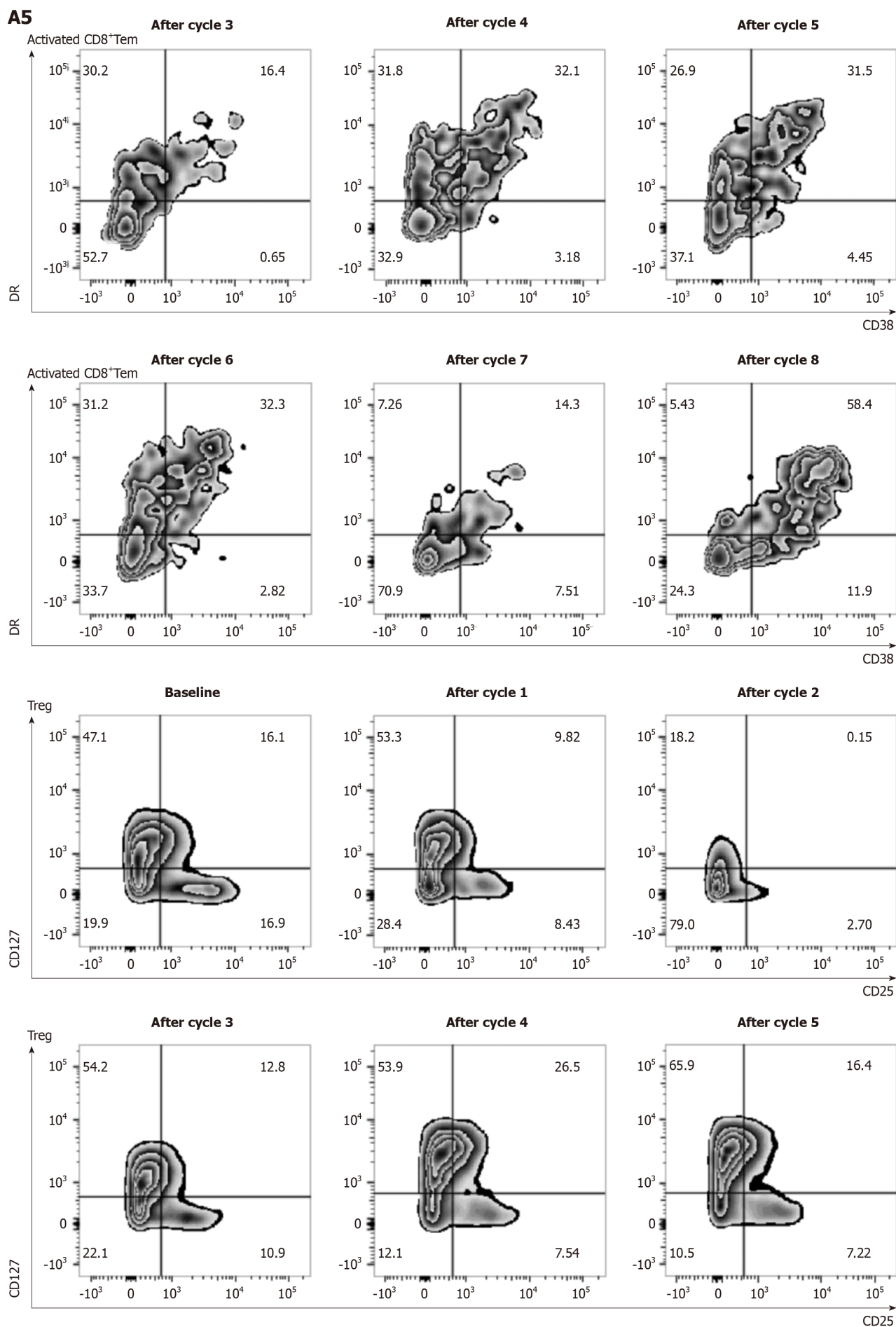
**A2**



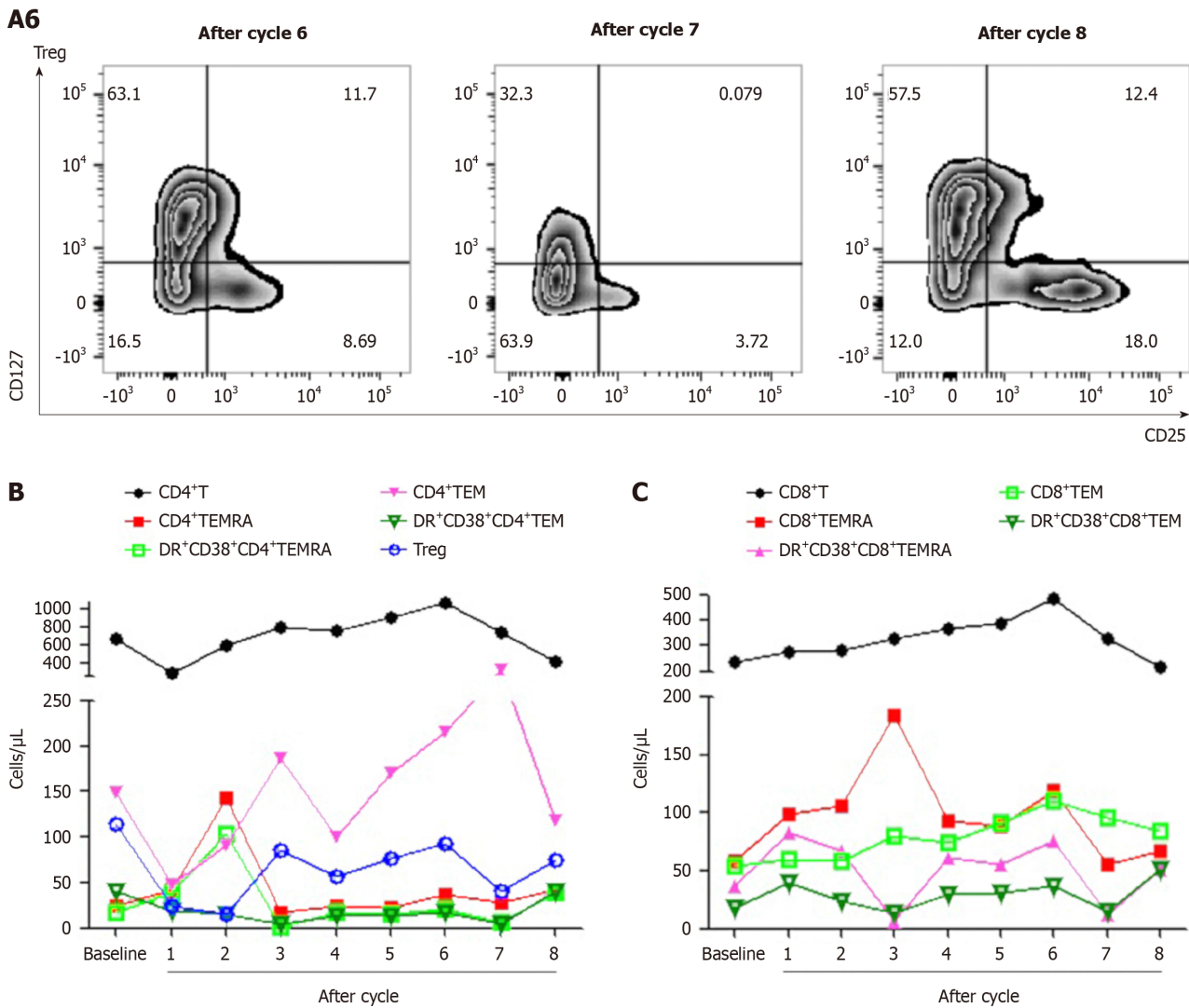


**A4**









**Figure 2** The percentage and absolute numbers of lymphocyte subsets at baseline and after each cycle. A: The percentage of peripheral lymphocytes, including CD4<sup>+</sup>Temra, CD8<sup>+</sup>Temra, activated CD4<sup>+</sup>Tem, activated CD8<sup>+</sup>Temra, activated CD4<sup>+</sup>Tem, activated CD8<sup>+</sup>Tem and Tregs at baseline and after each cycle; B and C: Absolute numbers of peripheral lymphocytes subsets at baseline and after each cycle.

CD38<sup>+</sup>CD8<sup>+</sup>Temra, the CD3<sup>+</sup>CD8<sup>+</sup>CD45RA<sup>+</sup>CD197<sup>+</sup>HLA-DR<sup>+</sup>CD38<sup>+</sup> activated memory effector T cells (Tem) and activated CD3<sup>+</sup>CD4<sup>+</sup>CD45RA<sup>+</sup>CD197<sup>+</sup>HLA-DR<sup>+</sup>CD38<sup>+</sup> Tem increased after the first treatment cycle but fell back afterwards. T cells cloned rapidly when activated and differentiated toward the shortly-lived effector cells or the memory progenitor cells (MPECs). MPECs then differentiated toward the central memory T cells and Tem, for a long-lasting immune response. Some subsets expressed CD45RA and become effector memory CD45RA re-expressing T cells (Temra), which were terminally differentiated. With high cytotoxicity and low proliferation, Temra's function was still controversial[12]. Tregs' percentage decreased significantly after treatment, which may predict a good treatment effect. The changing of peripheral blood of T cell subsets was displayed in Figure 2B and C, which were more easily obtained than tissue samples but it was challenging for analysis due to their complexities. The exact relationship between the lymphocyte subsets and treatment response and their specific mechanism needs further investigation.

## CONCLUSION

To our knowledge, it was the first time to combine RC48 with radiotherapy and anti-PD-1 therapy, which showed a significant reduction in irradiated and unirradiated lesions with PFS for 6.5 months after PRaG 3.0 therapy on a HER-2 positive metastatic PDAC patient who failed from previous first-line AG and PD-1 treatment. The efficacy and safety of this treatment pattern and its potential effects on peripheral lymphocyte subsets need further analyzed and confirmed in the open-label prospective study (NCT05115500).



## ACKNOWLEDGEMENTS

We are grateful to patient and her family.

## FOOTNOTES

**Co-first authors:** Yue-Hong Kong and Mei-Ling Xu.

**Co-corresponding authors:** Peng-Fei Xing and Li-Yuan Zhang.

**Author contributions:** Kong YH and Xu ML contributed to study conception and design, enrolled and took care of the patient, collected clinical data, performed the experiments and analyzed the data, wrote and revised the manuscript and figure; Zhang JJ and Chen GQ enrolled and took care of the patient; Hong ZH, Zhang H, Dai XX, Ma YF, Zhao XR, Zhang CY and Chen RZ collected clinical data, performed the experiments and analyzed the data; Chen GQ and Hong ZH performed imaging analysis; Dai XX and Zhao XR conducted pathological analysis; Zhang H, Ma YF and Zhang JJ helped flow cytometry data analysis; Xing PF and Zhang LY contributed to study conception and design, project administration, funding acquisition, re-vise the manuscript and figure. Kong YH and Xu ML contributed equally to this work as co-first authors. Xing PF and Zhang LY contributed efforts of equal substance throughout the research process as co-corresponding authors, the designation of co-corresponding authorship accurately reflects the distribution of responsibilities and burdens associated with the time and effort required to complete the study and the resultant paper, we believe that designating Xing PF and Zhang LY as co-corresponding authors is appropriate. All authors reviewed and approved the final version of the manuscript.

**Supported by** the Suzhou Medical Center, No. Szlcyxzx202103; the National Natural Science Foundation of China, No. 82171828; the Key R&D Plan of Jiangsu Province (Social Development), No. BE2021652; the Subject Construction Support Project of The Second Affiliated Hospital of Soochow University, No. XKTJHRC20210011; Wu Jieping Medical Foundation, No. 320.6750.2021-01-12; the Special Project of “Technological Innovation” Project of CNNC Medical Industry Co. Ltd, No. ZHYLTD2021001; Suzhou Science and Education Health Project, No. KJXW2021018; Foundation of Chinese Society of Clinical Oncology, No. Y-pierrefabre202102-0113; Beijing Bethune Charitable Foundation, No. STLKY0016; Research Projects of China Baoyuan Investment Co., No. 270004; Suzhou Gusu Health Talent Program, No. GSWS2022028; Open Project of State Key Laboratory of Radiation Medicine and Protection of Soochow University, No. GZN1202302.

**Informed consent statement:** Written informed consent has been obtained from the patient to publish this paper.

**Conflict-of-interest statement:** Authors declare that there were no competing interests.

**CARE Checklist (2016) statement:** The authors have read the CARE Checklist (2016), and the manuscript was prepared and revised according to the CARE Checklist (2016).

**Open-Access:** This article is an open-access article that was selected by an in-house editor and fully peer-reviewed by external reviewers. It is distributed in accordance with the Creative Commons Attribution NonCommercial (CC BY-NC 4.0) license, which permits others to distribute, remix, adapt, build upon this work non-commercially, and license their derivative works on different terms, provided the original work is properly cited and the use is non-commercial. See: <https://creativecommons.org/licenses/by-nc/4.0/>

**Country/Territory of origin:** China

**ORCID number:** Li-Yuan Zhang 0000-0002-2710-1245.

**S-Editor:** Zhang H

**L-Editor:** A

**P-Editor:** Zheng XM

## REFERENCES

- 1 Singh RR, O'Reilly EM. New Treatment Strategies for Metastatic Pancreatic Ductal Adenocarcinoma. *Drugs* 2020; **80**: 647-669 [PMID: 32306207 DOI: 10.1007/s40265-020-01304-0]
- 2 Wu J, Cai J. Dilemma and Challenge of Immunotherapy for Pancreatic Cancer. *Dig Dis Sci* 2021; **66**: 359-368 [PMID: 32140943 DOI: 10.1007/s10620-020-06183-9]
- 3 Feng K, Liu Y, Guo Y, Qiu J, Wu Z, Dai H, Yang Q, Wang Y, Han W. Phase I study of chimeric antigen receptor modified T cells in treating HER2-positive advanced biliary tract cancers and pancreatic cancers. *Protein Cell* 2018; **9**: 838-847 [PMID: 28710747 DOI: 10.1007/s13238-017-0440-4]
- 4 Mao T, Zhang X, Xu H, Ge W, Li S, Ma J, Yue M, Xue S, Cui J, Wang L. HDACs/mTOR inhibitor synergizes with pyrotinib in HER2-positive pancreatic cancer through degradation of mutant P53. *Cancer Cell Int* 2022; **22**: 380 [PMID: 36457011 DOI: 10.1186/s12935-022-02807-4]
- 5 Von Hoff DD, Ervin T, Arena FP, Chiorean EG, Infante J, Moore M, Seay T, Tjuland SA, Ma WW, Saleh MN, Harris M, Reni M, Dowden S, Laheru D, Bahary N, Ramanathan RK, Tabernero J, Hidalgo M, Goldstein D, Van Cutsem E, Wei X, Iglesias J, Renschler MF. Increased

- survival in pancreatic cancer with nab-paclitaxel plus gemcitabine. *N Engl J Med* 2013; **369**: 1691-1703 [PMID: [24131140](#) DOI: [10.1056/NEJMoa1304369](#)]
- 6 **O'Reilly EM**, Oh DY, Dhani N, Renouf DJ, Lee MA, Sun W, Fisher G, Hezel A, Chang SC, Vlahovic G, Takahashi O, Yang Y, Fitts D, Philip PA. Durvalumab With or Without Tremelimumab for Patients With Metastatic Pancreatic Ductal Adenocarcinoma: A Phase 2 Randomized Clinical Trial. *JAMA Oncol* 2019; **5**: 1431-1438 [PMID: [31318392](#) DOI: [10.1001/jamaoncol.2019.1588](#)]
  - 7 **Kong Y**, Zhao X, Xu M, Pan J, Ma Y, Zou L, Peng Q, Zhang J, Su C, Xu Z, Zhou W, Peng Y, Yang J, Zhou C, Li Y, Guo Q, Chen G, Wu H, Xing P, Zhang L. PD-1 Inhibitor Combined With Radiotherapy and GM-CSF (PRaG) in Patients With Metastatic Solid Tumors: An Open-Label Phase II Study. *Front Immunol* 2022; **13**: 952066 [PMID: [35874780](#) DOI: [10.3389/fimmu.2022.952066](#)]
  - 8 **Mills BN**, Qiu H, Drage MG, Chen C, Mathew JS, Garrett-Larsen J, Ye J, Uccello TP, Murphy JD, Belt BA, Lord EM, Katz AW, Linehan DC, Gerber SA. Modulation of the Human Pancreatic Ductal Adenocarcinoma Immune Microenvironment by Stereotactic Body Radiotherapy. *Clin Cancer Res* 2022; **28**: 150-162 [PMID: [34862242](#) DOI: [10.1158/1078-0432.CCR-21-2495](#)]
  - 9 **Palameta S**, Manrique-Rincón AJ, Toscaro JM, Semionatto IF, Fonseca MC, Rosa RSM, Ruas LP, Oliveira PSL, Bajgelman MC. Boosting antitumor response with PSMA-targeted immunomodulatory VLPs, harboring costimulatory TNFSF ligands and GM-CSF cytokine. *Mol Ther Oncolytics* 2022; **24**: 650-662 [PMID: [35284623](#) DOI: [10.1016/j.omto.2022.02.010](#)]
  - 10 **Sheng X**, Yan X, Wang L, Shi Y, Yao X, Luo H, Shi B, Liu J, He Z, Yu G, Ying J, Han W, Hu C, Ling Y, Chi Z, Cui C, Si L, Fang J, Zhou A, Guo J. Open-label, Multicenter, Phase II Study of RC48-ADC, a HER2-Targeting Antibody-Drug Conjugate, in Patients with Locally Advanced or Metastatic Urothelial Carcinoma. *Clin Cancer Res* 2021; **27**: 43-51 [PMID: [33109737](#) DOI: [10.1158/1078-0432.CCR-20-2488](#)]
  - 11 **Huang L**, Wang R, Xie K, Zhang J, Tao F, Pi C, Feng Y, Gu H, Fang J. A HER2 target antibody drug conjugate combined with anti-PD-(L)1 treatment eliminates hHER2+ tumors in hPD-1 transgenic mouse model and contributes immune memory formation. *Breast Cancer Res Treat* 2022; **191**: 51-61 [PMID: [34657203](#) DOI: [10.1007/s10549-021-06384-4](#)]
  - 12 **Verma K**, Ogonek J, Varanasi PR, Luther S, Bunting I, Thomay K, Behrens YL, Mischak-Weissinger E, Hambach L. Human CD8+ CD57- TEMRA cells: Too young to be called "old". *PLoS One* 2017; **12**: e0177405 [PMID: [28481945](#) DOI: [10.1371/journal.pone.0177405](#)]



Published by **Baishideng Publishing Group Inc**  
7041 Koll Center Parkway, Suite 160, Pleasanton, CA 94566, USA

**Telephone:** +1-925-3991568

**E-mail:** [office@baishideng.com](mailto:office@baishideng.com)

**Help Desk:** <https://www.f6publishing.com/helpdesk>

<https://www.wjgnet.com>

