

World Journal of *Clinical Cases*

World J Clin Cases 2024 May 6; 12(13): 2138-2292



Contents

Thrice Monthly Volume 12 Number 13 May 6, 2024

EDITORIAL

- 2138 Parenteral iron therapy in children with iron deficiency anemia
Roganovic J
- 2143 Treatment-induced neuroendocrine prostate cancer and *de novo* neuroendocrine prostate cancer: Identification, prognosis and survival, genetic and epigenetic factors
Wishahi M
- 2147 Perioperative cardiac risks in myasthenia gravis
Nag DS, Chatterjee A, Mahanty PR, Sam M, Bharadwaj MK
- 2151 Management of geriatric acetabular fractures: Contemporary treatment strategies
Tosounidis T, Chalidis B
- 2157 Pioneering role of machine learning in unveiling intensive care unit-acquired weakness
Dragonieri S

ORIGINAL ARTICLE

Case Control Study

- 2160 Detection and analysis of serum bile acid profile in patients with colonic polyps
Ji X, Chen H
- 2173 Clinical analysis of colistin sulfate in the treatment of pneumonia caused by carbapenem-resistant Gram-negative bacteria
Xu HC, Cui Y, Wang XY, Wu HB, Li W, Wang D, Lin N, Lin L, Zhang YH

Retrospective Cohort Study

- 2182 Establishment and evaluation of a prognostic model for patients with unresectable gastric cancer liver metastases
Chang ZY, Gao WX, Zhang Y, Zhao W, Wu D, Chen L

Retrospective Study

- 2194 Therapeutic effect of Wendan Decoction combined with mosapride on gastroesophageal reflux disease after esophageal cancer surgery
Zhang YJ, Wu SP

Clinical Trials Study

- 2201 Yiwei Xiaoyu granules for treatment of chronic atrophic gastritis with deficiency syndrome of the spleen and stomach
Chen WQ, Fan QF, He YJ, Li F, Wu X, Li YP, Yang XJ

Observational Study

- 2210** Relationship between clinical belonging, professional identity, and nursing information ability among nursing interns: Model construction
Zhang G, Huang SJ, Li SF

META-ANALYSIS

- 2218** Efficacy and safety of Yangxinshi tablet for chronic heart failure: A systematic review and meta-analysis
Lu SH, Yu YF, Dai SS, Hu YQ, Liu JH

CASE REPORT

- 2231** Intra-thyroid esophageal duplication cyst: A case report
Lin HG, Liu M, Huang XY, Liu DS
- 2237** Magnetic resonance imaging findings of radiation-induced breast angiosarcoma: A case report
Wu WP, Lee CW
- 2243** Rim ¹⁸F-fluorodeoxyglucose uptake of hepatic cavernous hemangioma on positron emission tomography/computed tomography: A case report
Hu YA, Guo YX, Huang QF
- 2248** Recovering from prolonged cardiac arrest induced by electric shock: A case report
Zhang J, Qiao YR, Yang YD, Pan GZ, Lv CQ
- 2254** Young patient with a giant gastric bronchogenic cyst: A case report and review of literature
Lu XR, Jiao XG, Sun QH, Li BW, Zhu QS, Zhu GX, Qu JJ
- 2263** Airway management of a patient with linear immunoglobulin A bullous dermatosis: A case report
Nin OC, Hutnik R, Chheda NN, Hutchinson D
- 2269** Deferred revascularization in diabetic patient according to combined invasive functional and intravascular imaging data: A case report
Al Nooryani A, Aboushokka W, Beleslin B, Nedeljkovic-Beleslin B
- 2275** Thymic carcinoid with multiple bone metastases: A case report
Chen CQ, Huang MY, Pan M, Chen QQ, Wei FF, Huang H
- 2281** Atypical presentation of a posterior fossa tumour: A case report
Narotam A, Archary M, Naidoo P, Naidoo Y, Naidu V
- 2286** Refractory autoimmune hemolytic anemia in a patient with systemic lupus erythematosus and ulcerative colitis: A case report
Chen DX, Wu Y, Zhang SF, Yang XJ

ABOUT COVER

Peer Reviewer of *World Journal of Clinical Cases*, Konosuke Nakaji, FACP, MD, Doctor, Endoscopy Center, Aishinkai Nakae Hospital, Wakayama-shi 640-8461, Japan. parupurikopui@yahoo.co.jp

AIMS AND SCOPE

The primary aim of *World Journal of Clinical Cases* (WJCC, *World J Clin Cases*) is to provide scholars and readers from various fields of clinical medicine with a platform to publish high-quality clinical research articles and communicate their research findings online.

WJCC mainly publishes articles reporting research results and findings obtained in the field of clinical medicine and covering a wide range of topics, including case control studies, retrospective cohort studies, retrospective studies, clinical trials studies, observational studies, prospective studies, randomized controlled trials, randomized clinical trials, systematic reviews, meta-analysis, and case reports.

INDEXING/ABSTRACTING

The WJCC is now abstracted and indexed in Science Citation Index Expanded (SCIE, also known as SciSearch®), Journal Citation Reports/Science Edition, Current Contents®/Clinical Medicine, PubMed, PubMed Central, Reference Citation Analysis, China Science and Technology Journal Database, and Superstar Journals Database. The 2023 Edition of Journal Citation Reports® cites the 2022 impact factor (IF) for WJCC as 1.1; IF without journal self cites: 1.1; 5-year IF: 1.3; Journal Citation Indicator: 0.26; Ranking: 133 among 167 journals in medicine, general and internal; and Quartile category: Q4.

RESPONSIBLE EDITORS FOR THIS ISSUE

Production Editor: Si Zhao; Production Department Director: Xiang Li; Cover Editor: Jin-Lei Wang.

NAME OF JOURNAL

World Journal of Clinical Cases

ISSN

ISSN 2307-8960 (online)

LAUNCH DATE

April 16, 2013

FREQUENCY

Thrice Monthly

EDITORS-IN-CHIEF

Bao-Gan Peng, Salim Surani, Jerzy Tadeusz Chudek, George Kontogeorgos, Maurizio Serati

EDITORIAL BOARD MEMBERS

<https://www.wjgnet.com/2307-8960/editorialboard.htm>

PUBLICATION DATE

May 6, 2024

COPYRIGHT

© 2024 Baishideng Publishing Group Inc

INSTRUCTIONS TO AUTHORS

<https://www.wjgnet.com/bpg/gerinfo/204>

GUIDELINES FOR ETHICS DOCUMENTS

<https://www.wjgnet.com/bpg/GerInfo/287>

GUIDELINES FOR NON-NATIVE SPEAKERS OF ENGLISH

<https://www.wjgnet.com/bpg/gerinfo/240>

PUBLICATION ETHICS

<https://www.wjgnet.com/bpg/GerInfo/288>

PUBLICATION MISCONDUCT

<https://www.wjgnet.com/bpg/gerinfo/208>

ARTICLE PROCESSING CHARGE

<https://www.wjgnet.com/bpg/gerinfo/242>

STEPS FOR SUBMITTING MANUSCRIPTS

<https://www.wjgnet.com/bpg/GerInfo/239>

ONLINE SUBMISSION

<https://www.f6publishing.com>



Airway management of a patient with linear immunoglobulin A bullous dermatosis: A case report

Olga C Nin, Robert Hutnik, Neil N Chheda, David Hutchinson

Specialty type: Anesthesiology

Provenance and peer review:

Unsolicited article; Externally peer reviewed.

Peer-review model: Single blind

Peer-review report's scientific quality classification

Grade A (Excellent): 0

Grade B (Very good): B

Grade C (Good): 0

Grade D (Fair): D

Grade E (Poor): 0

P-Reviewer: Esch M, Germany

Received: December 19, 2023

Peer-review started: December 19, 2023

First decision: January 10, 2024

Revised: January 24, 2024

Accepted: March 26, 2024

Article in press: March 26, 2024

Published online: May 6, 2024



Olga C Nin, Robert Hutnik, David Hutchinson, Department of Anesthesiology, University of Florida College of Medicine, Gainesville, FL 32610, United States

Neil N Chheda, Department of Otolaryngology, University of Florida College of Medicine, Gainesville, FL 32610, United States

Corresponding author: Olga C Nin, MD, Associate Professor, Department of Anesthesiology, University of Florida College of Medicine, 1600 SW Archer Road, PO Box 100254, Gainesville, FL 32610, United States. onin@anest.ufl.edu

Abstract

BACKGROUND

There is limited literature on managing the airway of patients with linear immunoglobulin A (IgA) bullous dermatosis, a rare mucocutaneous disorder that leads to the development of friable bullae. Careful clinical decision making is necessary when there is a risk of bleeding into the airway, and a multidisciplinary team approach may lead to decreased patient morbidity during these high-risk scenarios, especially when confronted with an unusual cause for bleeding.

CASE SUMMARY

A 45-year-old African American female presented to our ambulatory surgical center for right corneal transplantation due to corneal perforation after blunt trauma in the setting of cicatricial conjunctivitis and diffuse corneal neovascularization from linear IgA bullous dermatosis. The diagnosis of IgA dermatosis was recent, and the patient had been lost to follow-up. The severity of the disease and extent of airway involvement was unknown at the time of the surgery. Significant airway bleeding was noticed upon intubation and the otorhinolaryngology team had to be called to the operating room. The patient required transfer to the intensive care unit where a multidisciplinary team was involved in her case. The patient was extubated on postoperative day 4.

CONCLUSION

A multidisciplinary approach to treating this disease is the best course of action before a surgical procedure. In our case, key communication between the surgery, anesthesia, and dermatology teams led to the quick and safe treatment of our patient's disease. Ambulatory surgery should not be considered for these cases unless they are in full remission and there is no mucous membrane involvement.

Key Words: Airway management; Bleeding risk; Linear immunoglobulin A bullous dermatosis; Multidisciplinary approach; Outpatient procedure; Case report

©The Author(s) 2024. Published by Baishideng Publishing Group Inc. All rights reserved.

Core Tip: Linear immunoglobulin A bullous dermatosis, a rare mucocutaneous disorder, can lead to significant airway bleeding due to the presence of friable bullae. Airway emergencies in ambulatory surgical centers can be very high risk. A multidisciplinary discussion of the disease and patient optimization needs to be performed before the day of surgery. These cases should be treated in the inpatient setting where resources are most easily accessible, and an ear, nose, and throat team should be available.

Citation: Nin OC, Hutnik R, Chheda NN, Hutchinson D. Airway management of a patient with linear immunoglobulin A bullous dermatosis: A case report. *World J Clin Cases* 2024; 12(13): 2263-2268

URL: <https://www.wjgnet.com/2307-8960/full/v12/i13/2263.htm>

DOI: <https://dx.doi.org/10.12998/wjcc.v12.i13.2263>

INTRODUCTION

Linear immunoglobulin A (IgA) bullous dermatosis (LABD) is an autoimmune mucocutaneous disease involving disruption of the dermoepidermal junction, resulting in the formation of blisters or bullae[1]. IgA autoantibodies attach to antigens in the skin's basement membrane and mucosa, causing these clinical findings. Lesions typically appear as clear or hemorrhagic bullae with an urticarial base on the face, trunk, buttocks, and skin overlying joint sites. In 60% to 80% of cases, mucosal membranes, including the eyes and oral cavity, are also affected[2]. Patients with mucosal involvement can experience morbidity related to corneal scarring and pharyngeal or esophageal stricture formation, requiring surgical intervention. There is limited literature on the intraoperative management of these patients, especially regarding airway instrumentation.

CASE PRESENTATION

Chief complaints

Decreased vision in the right eye.

History of present illness

A 45-year-old African American female presented to our ambulatory surgical center for right corneal transplantation due to corneal perforation in the setting of cicatricial conjunctivitis, as well as diffuse corneal neovascularization from LABD. At the time of the surgery, the severity of the disease was unknown. The patient had been lost to follow-up with dermatology and was not taking any medications for her LABD. The severity of the patient's history of LABD diagnosis was only discovered after the operating room case and an in-depth conversation with her dermatologist. The patient's LABD was considered idiopathic per her dermatologist, given the absence of any inciting medication or infection. She began experiencing skin rashes and blisters in 2017. In June 2019, she sought medical attention due to mucosal membrane involvement, but at that time no medical therapy was initiated. In January 2021, she developed visual problems with her right eye and, following a confirmatory skin biopsy, was officially diagnosed with LABD in February 2021. Dapsone therapy was initiated in April 2021. She was hospitalized in May 2021 for a corneal ulcer of the right eye and was treated with one dose of intravenous immunoglobulin (IVIG), rituximab infusions, and 25 mg of oral dapsone twice each day. The patient received 4 doses of rituximab and was lost to follow-up until August 2021. This case was emergent due to the risk of permanent visual loss. The surgery was scheduled at the freestanding outpatient surgical center due to the presence of necessary equipment, personnel, and materials.

History of past illness

The patient's medical history consisted of anxiety, depression, chronic benzodiazepine dependence, chronic back pain, hypertension, constipation, genital herpes, prior cocaine abuse, and LABD.

Personal and family history

The patient had a strong family history of autoimmune disease, with paternal cousins having sarcoidosis, systemic lupus erythematosus, and multiple sclerosis. The patient was married and lived a few hours away from our hospital location. She was of a lower socioeconomic background and had trouble affording medications for her treatment.

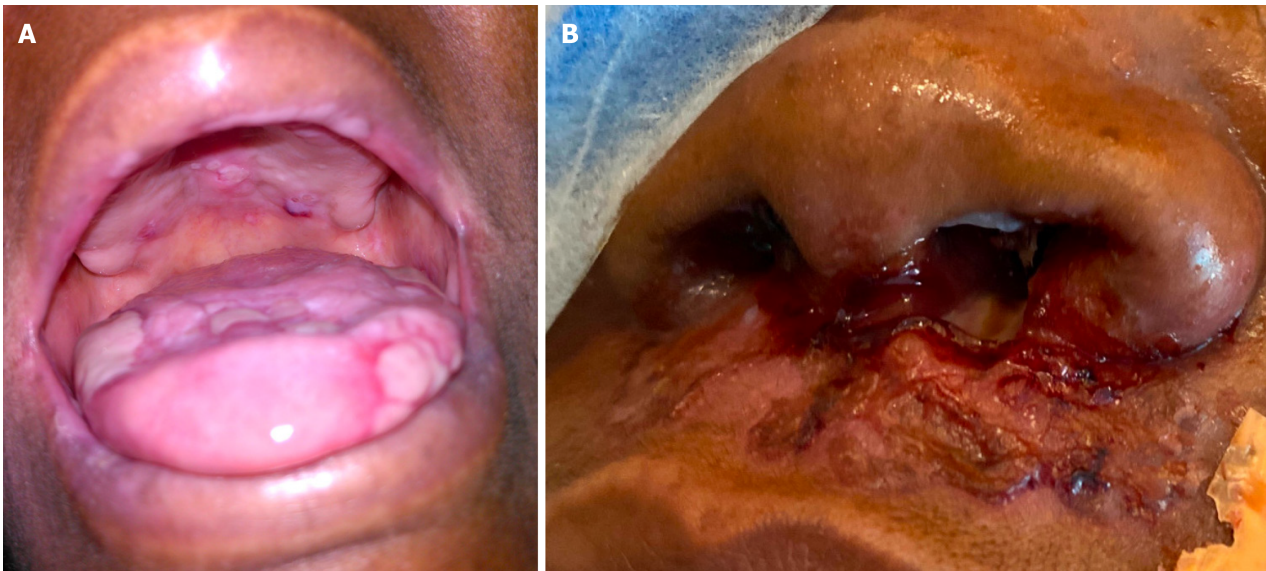


Figure 1 Preoperative tongue and nasal lesions. A: Preoperative tongue lesions; B: Preoperative nasal lesions.

Physical examination

The patient had visible nasal ulcers and some white ulcers on her tongue (**Figure 1**). There was no history of bleeding in her mouth or of previous anesthetic complications. The rest of the physical exam was normal.

Laboratory examinations

No laboratories were needed for preoperative evaluation before this emergent case.

Imaging examinations

Figure 1 shows the preoperative oral and nasal lesions.

MULTIDISCIPLINARY EXPERT CONSULTATION

On August 10, 2021, the patient presented to the free-standing ambulatory surgical center for a corneal transplant of the right eye under general anesthesia. On the day of surgery, an anesthetic preoperative evaluation and a focused physical examination were performed. The patient had visible clear nasal ulcers and white ulcers on her tongue (**Figure 1**). There was no history of bleeding in her mouth or of previous anesthetic complications. General anesthesia was indicated, given the type of surgery; therefore, airway manipulation was required. The decision was made to intubate using a C-MAC for optimal airway visualization due to the unknown extent of mucosal involvement of her disease, and complete visualization of the oropharynx was desirable. A peripheral intravenous catheter was placed, and 2 mg of intravenous midazolam was administered before proceeding to the operating room. She received a standard intravenous anesthesia induction with propofol, fentanyl, lidocaine, and rocuronium.

Upon careful placement of the C-MAC Mac 3 blade, ulcerative lesions were observed throughout the oropharynx, epiglottis, and vallecula. There was spontaneous and diffuse bleeding from lesions in the vallecula, even with minimal manipulation, and the airway was quickly secured using a wire-reinforced 7.0 endotracheal tube. A wire-reinforced tube was chosen so the endotracheal tube could be taped to the chin for surgical exposure. The ear, nose, and throat (ENT) team was called to the operating room to evaluate the bleeding, where they performed a visual examination by C-MAC, suctioned, and placed five epinephrine-soaked (0.1 mg/mL) cottonoids in the oropharynx. After a discussion between the ENT and ophthalmology teams, the decision was made to proceed with the surgery and transfer the patient intubated after surgery to our institution's main hospital surgical intensive care unit under the care of the ENT team. This hospital is located 20 min from our free-standing outpatient facility. Upon successful completion of the surgical procedure, the patient was transferred intubated to the surgical intensive care unit *via* ambulance.

The patient was transferred in stable condition to the main hospital by ambulance under the direct supervision of the attending anesthesiologist. To assess the extent of the ulcerative lesions before trial extubation, a bedside bronchoscopy was performed that revealed no ulcerative lesions in the trachea or bronchi. Ventilator weaning commenced, and extubation was planned in the operating room when clinically indicated. On postoperative day 1, the patient was taken to the operating room where a micro-suspended direct laryngoscopy was performed. Despite minimal manipulation, diffuse mucosal bleeding in the oral cavity and oropharynx was observed. The oral cavity was packed for hemostasis, and the patient remained intubated (**Figure 2**).

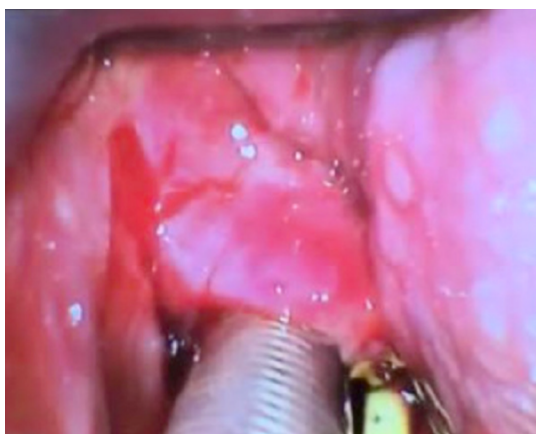

Figure 2 Hypopharynx of the airway in the operating room on postoperative day 1.

Due to the severity and extent of the disease, the dermatology team re-initiated dapsone therapy and prescribed a course of intravenous methylprednisolone and a single dose of both cyclophosphamide and IVIG. Overnight, the patient was observed to have a few isolated episodes of agitation that resulted in spontaneous bleeding; therefore, the oropharynx was repacked with epinephrine- and tranexamic acid-soaked Kerlix. On postoperative day 3, the ENT team removed the oral packing. On postoperative day 4, the patient returned to the operating room and was successfully extubated to cool, humidified air *via* a face mask. She received a dose of intravenous cyclophosphamide and was discharged 2 d later with a course of prednisone daily and dapsone with a follow-up for a second intravenous cyclophosphamide infusion planned in 1 mo. A timeline of this case can be seen in [Figure 3](#).

FINAL DIAGNOSIS

Right corneal perforation due to cicatricial conjunctivitis and diffuse corneal neovascularization from LABD.

TREATMENT

Patient was treated with dapsone and a course of prednisone. In the hospital the patient was given a course of intravenous methylprednisolone and a single dose of both cyclophosphamide and IVIG. She subsequently received monthly IV cyclophosphamide home infusions.

OUTCOME AND FOLLOW-UP

The patient continues on monthly cyclophosphamide infusions and daily oral prednisone and dapsone. She is seeing her dermatologist monthly.

DISCUSSION

LABD is a markedly rare disease, so very few anesthesiologists have experience managing these patients. In Europe, the incidence is approximately 0.1 per million. It presents in a bimodal age distribution: children aged six months to 10 years old (mean age five years old, rarely persisting past puberty) and adults over 60 years old. LABD is typically triggered by infection but can also be drug-induced by exposure to antibiotics (most notably vancomycin), antihypertensives, and nonsteroidal anti-inflammatory drugs. While some LABD presentations are idiopathic, associations with other systemic diseases have been demonstrated, such as ulcerative colitis, systemic lupus erythematosus, and lymphoproliferative disorders. Up to 5% of reported cases of LABD have been associated with lymphoid malignancies including Hodgkin's or B-cell lymphoma. Idiopathic LABD may persist for decades with episodes of relapse/remission. In our patient, LABD was diagnosed in February 2021 and deemed idiopathic[3].

Diagnosis is confirmed by clinical, histopathological, and immunological data. Treatment varies depending on the degree of severity of disease and the potential inciting event. In suspected drug-induced LABD, removal of the offending medication may result in gradual resolution. The mainstay of treatment in LABD is dapsone (50-150 mg daily in adults), which can begin resolution of lesions within 72 h. Per a collection of case reports, median length of dapsone treatment is 26 mo[4]. Common side effects of dapsone include hemolytic anemia (G6PD deficiency), methemoglobinemia, motor

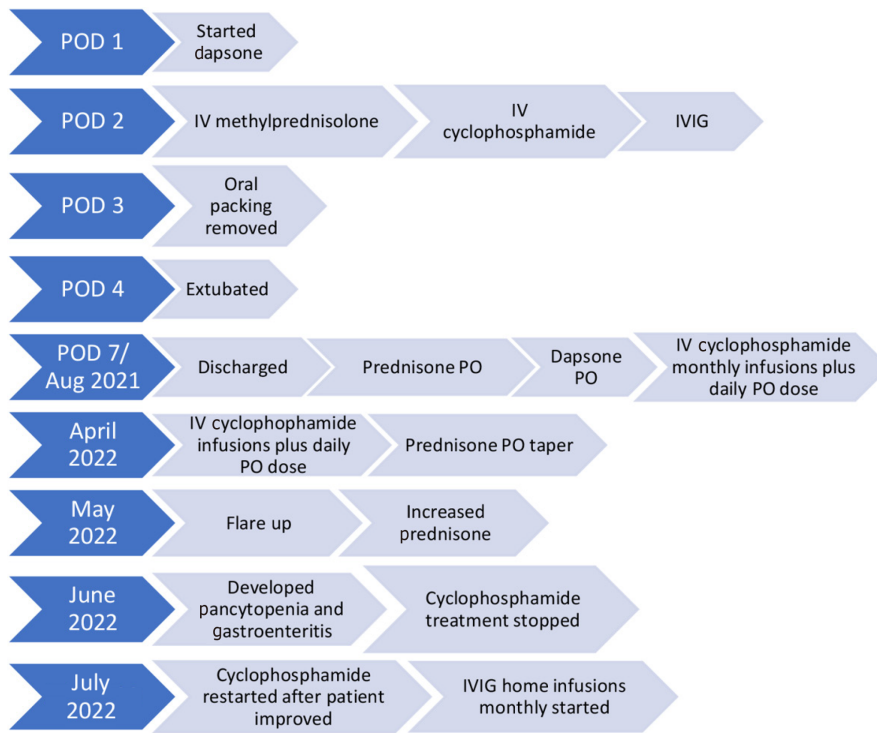


Figure 3 Timeline of case. IV: Intravenous; IVIG: Intravenous immunoglobulin; PO: By mouth.

neuropathy, hepatitis, cholestatic jaundice, and hypoalbuminemia. Routine complete blood count, liver function tests, and G6PD levels should be checked while on dapsone therapy. Immunosuppressants (azathioprine, methotrexate, mycophenolate mofetil, and cyclophosphamide) and corticosteroids are other modalities used for treatment. Chronic use of cyclophosphamide can lead to the onset of malignancies, such as bladder cancer[5]. Other treatment options include colchicine, tetracyclines, sulfonamides, nicotinamides, and IVIG.

Dermatology input and medication management were key to improving our patient's outcome. She continued on dapsone and was also given intravenous methylprednisolone, IVIG, and a dose of cyclophosphamide to treat her mucous membrane lesions and allow for extubation.

For an anesthesiologist caring for patients with LABD, the most critical information needed is the presence of mucous membrane involvement and airway compromise. In the event of airway bleeding with this disease, ENT intervention to control bleeding with epinephrine and tranexamic acid is necessary to protect the airway as medical treatment begins to take effect. Our ambulatory surgical center and the ENT clinics are all in the same building, helping our team initiate treatment quickly.

For our case, the severity and details of the disease were unknown at the time of the surgery. The surgery was emergent and needed to proceed to try to save vision in her eye. In our health system, corneal transplants are only done at our ambulatory center; necessary supplies and equipment are not present in the hospital. The patient did not report as scheduled to the anesthesia preoperative clinic so the first time the patient was evaluated by the anesthesia team was on the day of her surgery. Given the emergent need to preserve her vision, the necessity of performing the surgery at our ambulatory center, and the absence of any history of airway bleeding, the decision was made to proceed. Going forward, such cases must be completed in the inpatient setting; our system now has plans in place to transfer necessary equipment and staff to the inpatient setting as necessary.

CONCLUSION

To our knowledge, this is the first case report of the anesthetic implications of LABD[4] involving the mucous membranes of the nasal cavities and oropharynx. Given the lack of information on this disease and its extent in this patient, our anesthesia team was unaware of the lesions we would encounter throughout both the oropharynx and hypopharynx. Upon intubation, we understood the extent of the lesions and their friability. In retrospect, we should have consulted the ENT team preoperatively for a preoperative nasopharyngoscopy to determine the extent of the lesions. Had the patient attended her preoperative clinic appointment, our team may have had more information available.

A multidisciplinary approach to treating this disease is the best course of action before a surgical procedure. Ambulatory surgery should not be considered for these cases unless they are in full remission and there is no mucous membrane involvement. In our case, key communication between the surgical services, anesthesia, and dermatology teams occurred after the surgery and led to quick and safe treatment. We present this case to bring forward important anesthetic considerations for this rare disease.

This manuscript was prepared in compliance with the Health Insurance Portability and Accountability Act (HIPAA) of 1996 privacy regulations and adheres to applicable Enhancing the Quality and Transparency of Health Research guidelines (CARES [for CAse REportS] checklist). Written patient consent and written HIPAA authorization for the publication of this case report were obtained using a standardized consent form. Institutional Review Board consent was not required.

Learning points: (1) Mucous lesions in the oropharynx and hypopharynx can be extremely friable and cause bleeding upon minimal manipulation; (2) Early dermatology intervention and medication administration is key to a quick recovery from an acute exacerbation; and (3) Proper planning of operating room intervention in a hospital setting is vital to mitigate potential airway complications. These cases should not be done in an ambulatory setting.

ACKNOWLEDGEMENTS

The authors thank Bryan Penberthy, MFA, of the University of Florida College of Medicine Department of Anesthesiology's Communications & Publishing office for his editorial assistance with this manuscript.

FOOTNOTES

Author contributions: Chheda NN and Hutchinson D critically reviewed and revised the manuscript; Nin OC wrote the original draft and critically reviewed and revised the manuscript.

Informed consent statement: Written informed consent was obtained from the patient for publication of this case report and any accompanying images.

Conflict-of-interest statement: All authors declare that they have no conflict of interest to disclose.

CARE Checklist (2016) statement: The authors have read the CARE Checklist (2016), and the manuscript was prepared and revised according to the CARE Checklist (2016).

Open-Access: This article is an open-access article that was selected by an in-house editor and fully peer-reviewed by external reviewers. It is distributed in accordance with the Creative Commons Attribution NonCommercial (CC BY-NC 4.0) license, which permits others to distribute, remix, adapt, build upon this work non-commercially, and license their derivative works on different terms, provided the original work is properly cited and the use is non-commercial. See: <https://creativecommons.org/licenses/by-nc/4.0/>

Country/Territory of origin: United States

ORCID number: Olga C Nin 0009-0008-9490-8197.

S-Editor: Liu JH

L-Editor: A

P-Editor: Xu ZH

REFERENCES

- 1 **Chen S**, Mattei P, Fischer M, Gay JD, Milner SM, Price LA. Linear IgA bullous dermatosis. *Eplasty* 2013; **13**: ic49 [PMID: 23882302]
- 2 **Guide SV**, Marinkovich MP. Linear IgA bullous dermatosis. *Clin Dermatol* 2001; **19**: 719-727 [PMID: 11705681 DOI: 10.1016/s0738-081x(00)00185-1]
- 3 **Lammer J**, Hein R, Roenneberg S, Biedermann T, Volz T. Drug-induced linear IgA bullous dermatosis: a case report and review of the literature. *Acta Derm Venereol* 2019; **99**: 508-515 [PMID: 30809685 DOI: 10.2340/00015555-3154]
- 4 **Lings K**, Bygum A. Linear IgA bullous dermatosis: a retrospective study of 23 patients in Denmark. *Acta Derm Venereol* 2015; **95**: 466-471 [PMID: 25350667 DOI: 10.2340/00015555-1990]
- 5 **Vale ECSD**, Dimatos OC, Porro AM, Santi CG. Consensus on the treatment of autoimmune bullous dermatoses: dermatitis herpetiformis and linear IgA bullous dermatosis - Brazilian Society of Dermatology. *An Bras Dermatol* 2019; **94**: 48-55 [PMID: 31166403 DOI: 10.1590/abd1806-4841.2019940208]



Published by **Baishideng Publishing Group Inc**
7041 Koll Center Parkway, Suite 160, Pleasanton, CA 94566, USA

Telephone: +1-925-3991568

E-mail: office@baishideng.com

Help Desk: <https://www.f6publishing.com/helpdesk>

<https://www.wjgnet.com>

