

# World Journal of *Clinical Cases*

*World J Clin Cases* 2024 April 26; 12(12): 2000-2137



## Contents

Thrice Monthly Volume 12 Number 12 April 26, 2024

## EDITORIAL

- 2000** Protein C deficiency with venous and arterial thromboembolic events  
*Zhang N, Sun DK, Tian X, Zheng XY, Liu T*
- 2004** Indication and surgical approach for reconstruction with endoprosthesis in bone-associated soft tissue sarcomas: Appropriate case management is vital  
*Öztürk R*
- 2009** Comprehensive and personalized approach is a critical area for developing remote cardiac rehabilitation programs  
*Pepera G, Antoniou V, Su JJ, Lin R, Batalik L*
- 2016** Pain management in chronic pancreatitis  
*Nag DS, Swain BP, Anand R, Barman TK, Vatsala*
- 2023** Predicting intensive care unit-acquired weakness: A multilayer perceptron neural network approach  
*Ardila CM, González-Arroyave D, Zuluaga-Gómez M*

## MINIREVIEWS

- 2031** Autoantibodies related to ataxia and other central nervous system manifestations of gluten enteropathy  
*Velikova T, Vasilev G, Shumnalieva R, Chervenkov L, Miteva DG, Gulinac M, Priftis S, Lazova S*

## ORIGINAL ARTICLE

## Retrospective Study

- 2040** Enhanced recovery after surgery in elderly patients with non-small cell lung cancer who underwent video-assisted thoracic surgery  
*Sun MH, Wu LS, Qiu YY, Yan J, Li XQ*

## Clinical Trials Study

- 2050** Transient elastography with controlled attenuation parameter for the diagnosis of colorectal polyps in patients with nonalcoholic fatty liver disease  
*Wang L, Li YF, Dong LF*

## META-ANALYSIS

- 2056** Systematic review and network meta-analysis of different non-steroidal anti-inflammatory drugs for juvenile idiopathic arthritis  
*Zeng T, Ye JZ, Qin H, Xu QQ*

## CASE REPORT

- 2065** Human immunodeficiency virus-associated dementia complex with positive 14-3-3 protein in cerebrospinal fluid: A case report  
*He YS, Qin XH, Feng M, Huang QJ, Zhang MJ, Guo LL, Bao MB, Tao Y, Dai HY, Wu B*
- 2074** Multiorgan dysfunction syndrome due to high-dose cantharidin poisoning: A case report  
*Xu WL, Tang WJ, Yang WY, Sun LC, Zhang ZQ, Li W, Zang XX*
- 2079** Overlapping infections of *Mycobacterium canariense* and *Nocardia farcinica* in an immunocompetent patient: A case report  
*Huang HY, Bu KP, Liu JW, Wei J*
- 2086** Basilic vein variation encountered during surgery for arm vein port: A case report  
*Hu CD, Lv R, Zhao YX, Zhang MH, Zeng HD, Mao YW*
- 2092** Early embryonic failure caused by a novel mutation in the *TUBB8* gene: A case report  
*Zhang XY, Zhang XX, Wang L*
- 2099** Thoracic spine infection caused by *Pseudomonas fluorescens*: A case report and review of literature  
*Li L, Zhang BH, Cao JF, Zhang LJ, Guo LL*
- 2109** Bone block from lateral window - correcting vertical and horizontal bone deficiency in maxilla posterior site: A case report  
*Wang YL, Shao WJ, Wang M*
- 2116** Small intestine angioleiomyoma as a rare cause of perforation: A case report  
*Hou TY, Tzeng WJ, Lee PH*
- 2122** Crossed renal ectopia with rectal cancer: A case report  
*Tang ZW, Yang HF, Wu ZY, Wang CY*
- 2128** Systemic lupus erythematosus in a 15-year-old female with multiple splenic nodules: A case report  
*Kang MI, Kwon HC*

## LETTER TO THE EDITOR

- 2134** Machine learning in liver surgery: Benefits and pitfalls  
*Calleja R, Durán M, Ayllón MD, Ciria R, Briceño J*

**ABOUT COVER**

Peer Reviewer of *World Journal of Clinical Cases*, Eugen Javor, PharmD, Chief Pharmacist, Lecturer, Pharmacy Department, General Hospital Bjelovar, Bjelovar 43000, Croatia. eugen.javor@gmail.com

**AIMS AND SCOPE**

The primary aim of *World Journal of Clinical Cases* (WJCC, *World J Clin Cases*) is to provide scholars and readers from various fields of clinical medicine with a platform to publish high-quality clinical research articles and communicate their research findings online.

WJCC mainly publishes articles reporting research results and findings obtained in the field of clinical medicine and covering a wide range of topics, including case control studies, retrospective cohort studies, retrospective studies, clinical trials studies, observational studies, prospective studies, randomized controlled trials, randomized clinical trials, systematic reviews, meta-analysis, and case reports.

**INDEXING/ABSTRACTING**

The WJCC is now abstracted and indexed in Science Citation Index Expanded (SCIE, also known as SciSearch®), Journal Citation Reports/Science Edition, Current Contents®/Clinical Medicine, PubMed, PubMed Central, Reference Citation Analysis, China Science and Technology Journal Database, and Superstar Journals Database. The 2023 Edition of Journal Citation Reports® cites the 2022 impact factor (IF) for WJCC as 1.1; IF without journal self cites: 1.1; 5-year IF: 1.3; Journal Citation Indicator: 0.26; Ranking: 133 among 167 journals in medicine, general and internal; and Quartile category: Q4.

**RESPONSIBLE EDITORS FOR THIS ISSUE**

Production Editor: Hua-Ge Yin, Production Department Director: Xu Guo, Cover Editor: Jin-Lai Wang.

**NAME OF JOURNAL**

*World Journal of Clinical Cases*

**ISSN**

ISSN 2307-8960 (online)

**LAUNCH DATE**

April 16, 2013

**FREQUENCY**

Thrice Monthly

**EDITORS-IN-CHIEF**

Bao-Gan Peng, Salim Surani, Jerzy Tadeusz Chudek, George Kontogeorgos, Maurizio Serati

**EDITORIAL BOARD MEMBERS**

<https://www.wjgnet.com/2307-8960/editorialboard.htm>

**PUBLICATION DATE**

April 26, 2024

**COPYRIGHT**

© 2024 Baishideng Publishing Group Inc

**INSTRUCTIONS TO AUTHORS**

<https://www.wjgnet.com/bpg/gerinfo/204>

**GUIDELINES FOR ETHICS DOCUMENTS**

<https://www.wjgnet.com/bpg/GerInfo/287>

**GUIDELINES FOR NON-NATIVE SPEAKERS OF ENGLISH**

<https://www.wjgnet.com/bpg/gerinfo/240>

**PUBLICATION ETHICS**

<https://www.wjgnet.com/bpg/GerInfo/288>

**PUBLICATION MISCONDUCT**

<https://www.wjgnet.com/bpg/gerinfo/208>

**ARTICLE PROCESSING CHARGE**

<https://www.wjgnet.com/bpg/gerinfo/242>

**STEPS FOR SUBMITTING MANUSCRIPTS**

<https://www.wjgnet.com/bpg/GerInfo/239>

**ONLINE SUBMISSION**

<https://www.f6publishing.com>



## Small intestine angioleiomyoma as a rare cause of perforation: A case report

Teng-Yuan Hou, Wei-Juo Tzeng, Pei-Hang Lee

**Specialty type:** Medicine, research and experimental

**Provenance and peer review:** Unsolicited article; Externally peer reviewed.

**Peer-review model:** Single blind

**Peer-review report's scientific quality classification**

Grade A (Excellent): 0  
Grade B (Very good): 0  
Grade C (Good): C, C  
Grade D (Fair): 0  
Grade E (Poor): 0

**P-Reviewer:** Ikura Y, Japan

**Received:** January 8, 2024

**Peer-review started:** January 8, 2024

**First decision:** January 23, 2024

**Revised:** February 13, 2024

**Accepted:** March 25, 2024

**Article in press:** March 25, 2024

**Published online:** April 26, 2024



**Teng-Yuan Hou, Wei-Juo Tzeng,** Department of General Surgery, Kaohsiung Chang Gung Memorial Hospital, Kaohsiung 833, Taiwan

**Pei-Hang Lee,** Department of Anatomical Pathology, Kaohsiung Chang Gung Memorial Hospital, Kaohsiung 833, Taiwan

**Corresponding author:** Wei-Juo Tzeng, MD, Surgeon, Surgical Oncologist, Department of General Surgery, Kaohsiung Chang Gung Memorial Hospital, No. 123 Dapi Road, Niasong District, Kaohsiung 833, Taiwan. [Jbkim22004@gmail.com](mailto:Jbkim22004@gmail.com)

### Abstract

#### BACKGROUND

Angioleiomyoma is a rare and benign stromal tumor typically found in subcutaneous tissue. It rarely occurs in the gastrointestinal tract. Among the reported cases, the most common complication was gastrointestinal bleeding. Perforation has only been reported as a complication in the last few decades.

#### CASE SUMMARY

This case report detailed the discovery of intestinal angioleiomyoma in a 47-year-old male presenting with abdominal pain that had persisted for 3 d. After suspecting hollow organ perforation, surgical intervention involving intestinal resection and anastomosis was performed.

#### CONCLUSION

The report underscores the significance of early surgical intervention in effectively treating angioleiomyoma while emphasizing the pivotal role of timely and appropriate measures for favorable outcomes.

**Key Words:** Angioleiomyoma; Intestinal perforation; Abdomen; Acute; Diarrhea; Case report

©The Author(s) 2024. Published by Baishideng Publishing Group Inc. All rights reserved.



**Core Tip:** Here we report the first case of angioleiomyoma in the small intestine with a complication of perforation. This type of complication is extremely rare as the last published report of a perforation complication related to angioleiomyoma was published 30 years ago in Russian.

**Citation:** Hou TY, Tzeng WJ, Lee PH. Small intestine angioleiomyoma as a rare cause of perforation: A case report. *World J Clin Cases* 2024; 12(12): 2116-2121

**URL:** <https://www.wjgnet.com/2307-8960/full/v12/i12/2116.htm>

**DOI:** <https://dx.doi.org/10.12998/wjcc.v12.i12.2116>

## INTRODUCTION

Angioleiomyomas are a vascular subtype of leiomyomas, categorized as benign smooth muscle tumors. The tumor itself is characterized by inclusion of vessel and smooth muscle cells[1]. Angioleiomyomas mostly arise from the wall of a vein. The majority of cases occur at 30 years to 60 years of age, with female predominance and location in a lower extremity[2]. Although, angioleiomyomas have been found in different organs[3-5]. Within the gastrointestinal tract, occurrences of angioleiomyomas are exceptionally rare[6]. This case report presents the inaugural instance documented in the English literature and details a patient who exhibited hollow organ perforation attributable to angioleiomyoma.

## CASE PRESENTATION

### Chief complaints

A 47-year-old male presented with lower abdominal pain and diarrhea.

### History of present illness

The patient reported that his symptoms started 3 d prior to presentation, with both gradually progressing over that period. He also reported having a fever that would go up to 39 °C for 1 wk.

### History of past illness

The patient had a medical history of controlled hypertension for many years.

### Personal and family history

The patient's personal and family history was unremarkable.

### Physical examination

The physical examination revealed the following: Body temperature, 36.7 °C; heart rate, 105 beats/min; respiratory rate, 18 breaths/min; and blood pressure, 125/80 mmHg. The skin and mucous membranes were free of yellow staining, rash, bleeding spots, liver palms, and spider nevus. Chest breathing was normal. However, the tenderness over the low abdomen and rebounding pain was mentioned.

### Laboratory examinations

Laboratory tests indicated elevated C-reactive protein (335 mg/L; normal range: < 5 mg/L) and increased creatinine (1.81 mg/dL; normal range: 0.64 mg/dL-1.27 mg/dL).

### Imaging examinations

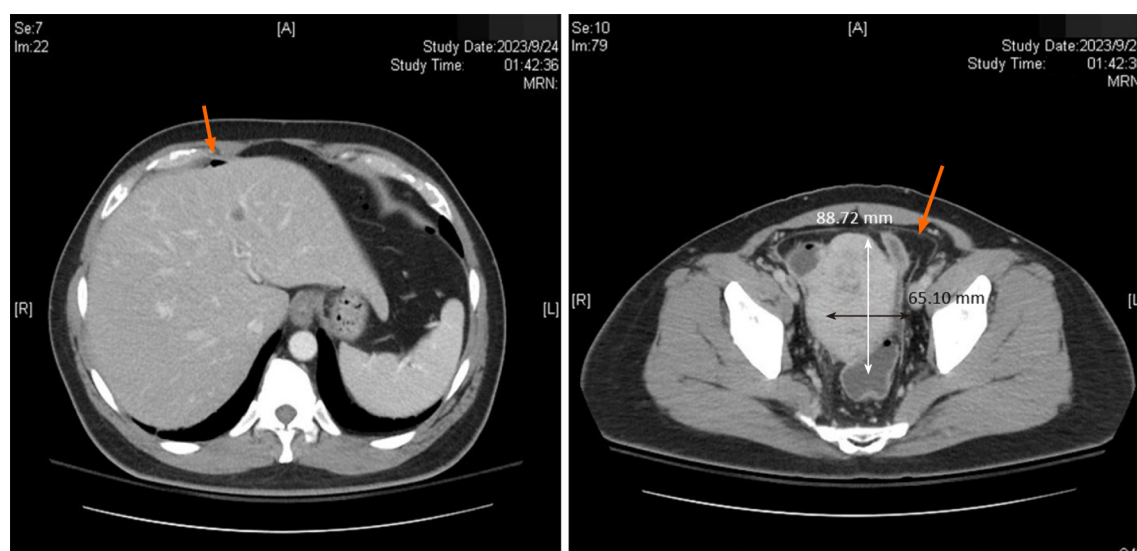
Computed tomography (CT) showed pneumoperitoneum and a mass over the pelvic area (Figure 1).

## FINAL DIAGNOSIS

Ileum angioleiomyoma with complications of perforation and pneumoperitoneum.

## TREATMENT

We initially suspected a perforation associated with sigmoid colon cancer. Therefore, surgical intervention was initiated approximately 7 h after admission. An exploratory laparotomy revealed a tumor, measuring 8 cm × 5 cm, located 70 cm from the ileocecal valve. It was surrounded by an abscess formation (Figure 2). A thorough examination of the stomach,



**Figure 1** Computed tomography before the operation. A: Pneumoperitoneum (orange arrow); B: One 6.8 cm × 6.5 cm mass over the pelvic area (orange arrow).

intestine, and colon did not reveal additional perforation. The tumor was excised followed by end-to-end anastomosis.

## OUTCOME AND FOLLOW-UP

Postoperatively, the patient was transferred to the ward for continued care and was discharged 2 wk after the operation. The patient returned to our clinic for follow-up after 2 wk without complaint of abdominal pain, nausea nor vomiting. The immunohistochemical analysis of the resected specimen corroborated the diagnosis of angioleiomyoma.

## DISCUSSION

Leiomyomas are most frequently located in the uterine myometrium (95.0%), followed by the skin (3.0%) and the gastrointestinal tract (1.5%)[6]. In 1969, the World Health Organization defined leiomyomas as well-circumscribed benign tumors composed of bundles of mature smooth muscle cells. The World Health Organization classification includes three main groups: Solid leiomyoma; vascular leiomyoma (angioleiomyoma); and epithelioid leiomyoma (leiomyoblastoma)[7]. Angioleiomyoma, initially described by Stout[8] in 1937, commonly affects the skin and subcutaneous tissue of the lower extremities. Its presence in the gastrointestinal tract is exceptionally rare. Angioleiomyomas in the gastrointestinal tract occur predominantly in the jejunum (44%), followed by the ileum (37%) and the duodenum (19%).

Four distinct subtypes of angioleiomyoma have been identified[2]. The first type is capillary or solid angioleiomyomas. They are characterized by a rich stratification of smooth muscle cells surrounding a few slit-like vascular channels. This subtype is the most common. The second type is venous angioleiomyomas, which is distinguished by more vascular channels and walls that are thicker compared to capillary angioleiomyomas. The third type is cavernous angioleiomyomas, and this subtype features widened vascular channels surrounded by a thin layer of smooth muscle cells. The fourth type is combined capillary and venous angioleiomyomas[9,10].

Our patient was diagnosed with cavernous angioleiomyoma based on histological findings. Sections showed ileal tissue with a well-circumscribed subserosal tumor composed of proliferative spindle smooth muscle cells bearing brightly eosinophilic cytoplasm and arranged in fascicles, punctuated by variable-sized vascular channels. The vessels were irregularly dilated with attenuated walls. There was also a lack of a thick muscular wall (Figure 3).

The clinical presentation of angioleiomyoma is diverse. Uncomplicated cases are typically asymptomatic. However, a limited number of reported cases exhibit rare clinical presentations. Therefore, it is challenging to establish comprehensive clinical features and complication rates. Only 10 cases of gastrointestinal angioleiomyoma have been documented in the literature. Table 1 compares these cases with our own.

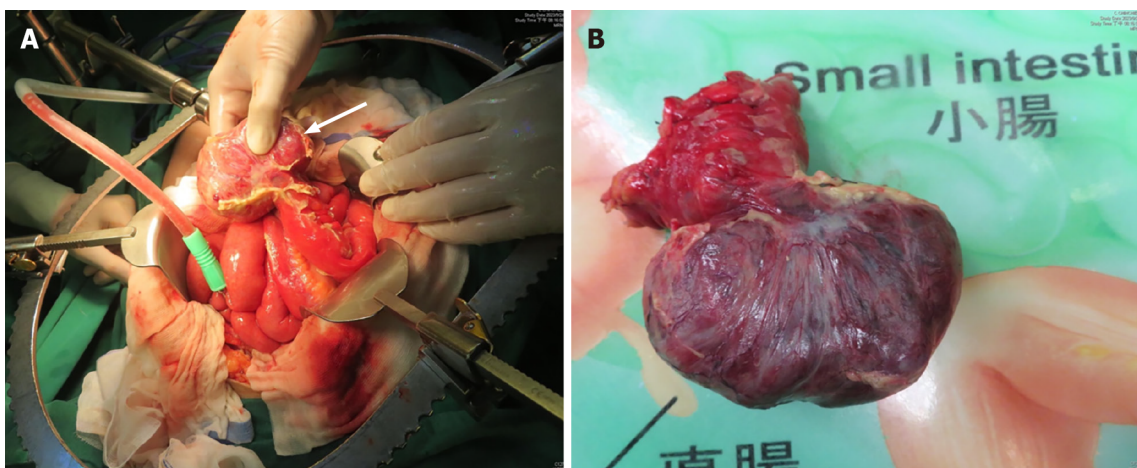
Gastrointestinal bleeding is the most commonly reported complication associated with angioleiomyoma. Past cases have reported other complications, such as intussusception and prolapse. Notably, our case represents the first reported instance of angioleiomyoma-related perforation in the English literature.

In our case, preoperative imaging, specifically CT, revealed a lesion located in the pelvic region accompanied by pneumoperitoneum. We initially suspected malignancy-related hollow organ perforation. Despite the absence of tarry or bloody stool reported by the patient, CT indicated a tumor of 9.5 cm × 6.5 cm × 6.4 cm in size that was surrounded by abscess.

**Table 1** Case list of angioleiomyoma in the gastrointestinal tract

Ref.	Age, sex	Location	Complication	Diagnosis	Treatment
Valnicek[11], 1959	NA	Small bowel	GIB	NA	NA
Gădăleanu and Popescu [12], 1988	31, female	Duodenojejunal flexure	GIB	Laparotomy	2 stages: (1) Tumor vascular pedicle ligation; and (2) Resection
Sapelkin[13], 1989	NA	Small bowel	Perforation	NA	NA
Pidoprigora <i>et al</i> [14], 1995	NA	Small bowel	GIB	NA	NA
Sadat <i>et al</i> [9], 2007	58, female	Ileum	GIB	Angiography	Resection
Nakatani <i>et al</i> [15], 2010	45, female	Ileum	GIB	Capsule endoscopy + double-balloon enteroscopy	Resection
Turan <i>et al</i> [16], 2010	Age not known, female	Ileum	Intussusception	CT	Resection
Stanojević <i>et al</i> [17], 2013	40, female	Rectum	Prolapse	Clinical	Tumor excision
Gachabayov and Mityushin [18], 2016	21, male	Jejunum	GIB	CT	Resection
Shao <i>et al</i> [19], 2018	42, male	Jejunum	GIB	Double balloon enteroscopy	Resection
Our case	47, male	Ileum	Perforation	CT	Resection

CT: Computed tomography; GIB: Gastrointestinal bleeding; NA: Not available.



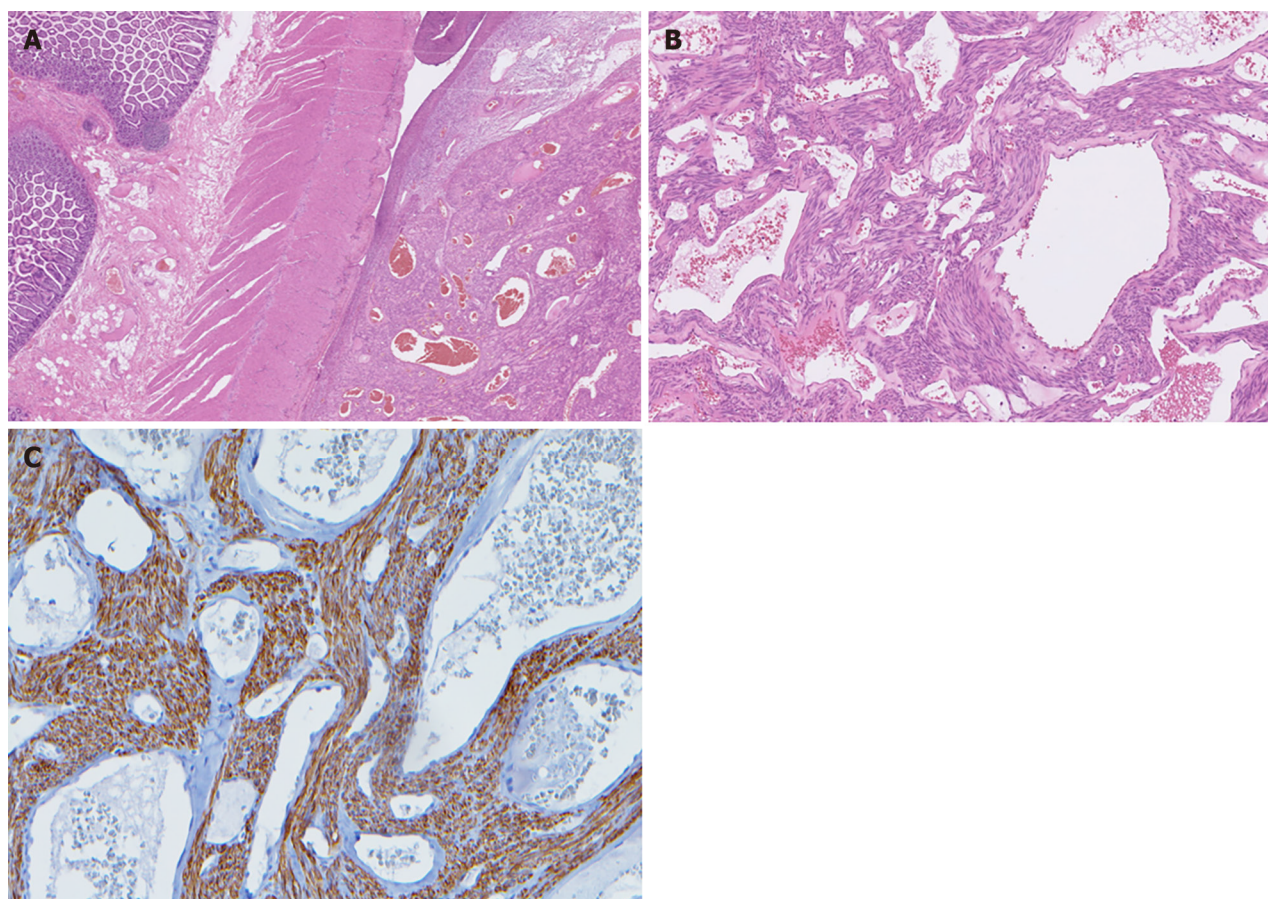
**Figure 2** Gross appearance during the operation. A: Pelvic mass surrounded by an abscess (white arrow); B: The tumor and a small section of the ileum was resected.

Surgical resection of the affected bowel segment is the typical treatment to manage the angioleiomyoma and any accompanying complications. Resection is typically followed by side-to-side anastomosis, which was also performed in our case. Given the initial suspicion of hollow organ perforation, a comprehensive inspection of the entire abdomen was essential to identify potential perforations caused by other etiologies. This thorough examination was crucial to ensure an accurate diagnosis and appropriate intervention.

## CONCLUSION

In summary, small bowel angioleiomyoma is a rare occurrence. Perforation is also a rare complication related to angioleiomyoma. Nonetheless, early surgical intervention plays a crucial role in the effective treatment of angioleiomyoma. Timely and appropriate surgical measures are pivotal for a favorable outcome in such cases.





**Figure 3 Histopathology of angioleiomyoma.** A: Ileal tissue with a well-circumscribed subserosal tumor; B: Proliferative spindle smooth muscle cells bearing brightly eosinophilic cytoplasm and arranged in fascicles, punctuated by variable-sized vascular channels. The vessels were irregularly dilated with attenuated walls; C: The proliferative smooth muscle cells were highlighted by desmin immunostaining, while the cavernous vascular channels lacked a well-formed muscular wall.

## FOOTNOTES

**Author contributions:** Hou TY designed the report; Lee PH analyzed the histological images; Tzeng WJ analyzed the data and wrote the paper; All authors read and approved the final manuscript.

**Informed consent statement:** Informed written consent was obtained from the patient for publication of this report and any accompanying images.

**Conflict-of-interest statement:** The authors declare having no conflicts of interest.

**CARE Checklist (2016) statement:** The authors have read the CARE Checklist (2016), and the manuscript was prepared and revised according to the CARE Checklist (2016).

**Open-Access:** This article is an open-access article that was selected by an in-house editor and fully peer-reviewed by external reviewers. It is distributed in accordance with the Creative Commons Attribution NonCommercial (CC BY-NC 4.0) license, which permits others to distribute, remix, adapt, build upon this work non-commercially, and license their derivative works on different terms, provided the original work is properly cited and the use is non-commercial. See: <https://creativecommons.org/licenses/by-nc/4.0/>

**Country/Territory of origin:** Taiwan

**ORCID number:** Wei-Juo Tzeng 0009-0000-2901-1502.

**S-Editor:** Che XX

**L-Editor:** A

**P-Editor:** Yu HG

## REFERENCES

- 1 **Beissert M**, Kenn W, Schultz G, Keberle M, Eck M, Hahn D. Hepatic angioleiomyoma: CT and MRI findings. *Abdom Imaging* 2002; **27**: 40-42 [PMID: 11740605 DOI: 10.1007/s00261-001-0028-5]
- 2 **Hachisuga T**, Hashimoto H, Enjoji M. Angioleiomyoma. A clinicopathologic reappraisal of 562 cases. *Cancer* 1984; **54**: 126-130 [PMID: 6722737 DOI: 10.1002/1097-0142(19840701)54:1<126::aid-cnrcr2820540125>3.0.co;2-f]
- 3 **Matsuyama A**, Hisaoka M, Hashimoto H. Angioleiomyoma: a clinicopathologic and immunohistochemical reappraisal with special reference to the correlation with myopericytoma. *Hum Pathol* 2007; **38**: 645-651 [PMID: 17270242 DOI: 10.1016/j.humpath.2006.10.012]
- 4 **Brooks JK**, Nikitakis NG, Goodman NJ, Levy BA. Clinicopathologic characterization of oral angioleiomyomas. *Oral Surg Oral Med Oral Pathol Oral Radiol Endod* 2002; **94**: 221-227 [PMID: 12221390 DOI: 10.1067/moe.2002.125276]
- 5 **Jamiyan T**, Kuroda H, Luvsan G, Munkhnyam T, Kakumoto A, Enkhbat B. Primary Hepatic Angioleiomyoma: A Case Report. *Am J Case Rep* 2023; **24**: e938645 [PMID: 36805667 DOI: 10.12659/AJCR.938645]
- 6 **Veeresh M**, Sudhakara M, Girish G, Naik C. Leiomyoma: A rare tumor in the head and neck and oral cavity: Report of 3 cases with review. *J Oral Maxillofac Pathol* 2013; **17**: 281-287 [PMID: 24250094 DOI: 10.4103/0973-029X.119770]
- 7 **Enzinger FM**, Lattes R, Torloni H. Histological typing of soft tissue tumors. International histological classification of tumors. No. 3, Geneva. World Health Organization, 1969: 42. Available from: <https://scholar.google.com/scholar?q=Enzinger+FM+Lattes+R+Torloni+H+Histological+Typing+of+Soft+Tissue+Tumours+1969+Geneva+World+Health+Organization+30+1+>
- 8 **Stout AP**. Solitary Cutaneous and Subcutaneous Leiomyoma. *Am J Cancer* 1937; **29**: 435-69 [DOI: 10.1158/ajc.1937.435]
- 9 **Sadat U**, Theivacumar NS, Vat J, Jah A. Angioleiomyoma of the small intestine - a rare cause of gastrointestinal bleeding. *World J Surg Oncol* 2007; **5**: 129 [PMID: 17996042 DOI: 10.1186/1477-7819-5-129]
- 10 **Agaimy A**, Wünsch PH. True smooth muscle neoplasms of the gastrointestinal tract: morphological spectrum and classification in a series of 85 cases from a single institute. *Langenbecks Arch Surg* 2007; **392**: 75-81 [PMID: 17021790 DOI: 10.1007/s00423-006-0092-y]
- 11 **Valnicek V**. [Angioleiomyoma of the small intestine as a cause of severe melena]. *Rozhl Chir* 1959; **38**: 848-880 [PMID: 13840923]
- 12 **Gădăleanu V**, Popescu V. Angioleiomyoma and vascular ectasia of the small bowel as a cause of intestinal bleeding. *Pathol Res Pract* 1988; **183**: 519-523 [PMID: 3263631 DOI: 10.1016/s0344-0338(88)80108-0]
- 13 **Sapelkin OS**. [Angioleiomyoma of the small intestine complicated by perforation]. *Klin Khir (1962)* 1989; 61-62 [PMID: 2724819]
- 14 **Pidoprighora AP**, Chmeruk SP, Fedorchuk LI, Shuldik SI. [Angioleiomyoma of the small intestine as a cause of recurrence of hemorrhage]. *Klin Khir* 1995; 48 [PMID: 8640514]
- 15 **Nakatani M**, Fujiwara Y, Kameda N, Okazaki H, Watanabe T, Tominaga K, Arakawa T, Noda E, Inoue T, Maeda K, Hirakawa K, Wakasa K. Angioleiomyoma of the small intestine detected by double-balloon enteroscopy. *Gastrointest Endosc* 2010; **72**: 187-8; discussion 188 [PMID: 20421103 DOI: 10.1016/j.gie.2009.12.037]
- 16 **Turan M**, Karadayi K, Duman M, Ozer H, Arici S, Yildirim C, Koçak O, Sen M. Small bowel tumors in emergency surgery. *Ulus Travma Acil Cerrahi Derg* 2010; **16**: 327-333 [PMID: 20849049]
- 17 **Stanojević GZ**, Mihailović DS, Nestorović MD, Radojković MD, Jovanović MM, Stojanović MP, Branković BB. Case of rectal angioleiomyoma in a female patient. *World J Gastroenterol* 2013; **19**: 2114-2117 [PMID: 23599634 DOI: 10.3748/wjg.v19.i13.2114]
- 18 **Gachabayov M**, Mityushin P. Recurrent Midgut Bleeding due to Jejunal Angioleiomyoma. *Case Rep Surg* 2016; **2016**: 4569781 [PMID: 27668116 DOI: 10.1155/2016/4569781]
- 19 **Shao XD**, Liang ZD, Guo XZ. A Small Jejunal Angioleiomyoma Detected by Double-Balloon Enteroscopy: A Case Report. *Am J Case Rep* 2018; **19**: 1126-1128 [PMID: 30245504 DOI: 10.12659/AJCR.910884]



Published by **Baishideng Publishing Group Inc**  
7041 Koll Center Parkway, Suite 160, Pleasanton, CA 94566, USA

**Telephone:** +1-925-3991568

**E-mail:** [office@baishideng.com](mailto:office@baishideng.com)

**Help Desk:** <https://www.f6publishing.com/helpdesk>

<https://www.wjgnet.com>

