




Microsoft Bing

国内版 国际版

Rare histological subtype of invasive micropapillary carcinoma in th



Chat with Bing

Sign in

ALL IMAGES VIDEOS

54,000 Results Any time

Invasive micropapillary carcinoma: A distinct type of ...

<https://www.ncbi.nlm.nih.gov/pmc/articles/PMC4000496>

Apr 26, 2014 · Invasive micropapillary carcinoma (IMPC) is a rare histological type of tumor, first described in invasive ductal breast cancer, then in malignancies in other organs such as lungs, urinary bladder, ovaries or salivary glands. Recent literature data shows that this histological lesion has also been found in cancers of the gastrointestinal system.

Cited by: 9 Author: Katarzyna Guzińska-Ustymowicz, Katarz...

Publish Year: 2014

Invasive micropapillary carcinoma: A distinct type of ...

[europepmc.org/articles/PMC4000496](https://www.ncbi.nlm.nih.gov/pmc/articles/PMC4000496)

Invasive micropapillary carcinoma (IMPC) is a rare histological type of tumor, first described in invasive ductal breast cancer, then in malignancies in other organs such as lungs, urinary bladder, ovaries or salivary glands. Recent literature data shows that this histological lesion has also been found in cancers of the gastrointestinal system.

Invasive micropapillary carcinoma of the ampulla of Vater ...

Search Tools

Turn off Hover Translation (关闭翻译)

等待 cn.bing.com...

国内版国际版

Microsoft Bing

Rare histological subtype of invasive micropapillary

Chat with Bing

Sign in

ALLIMAGESVIDEOS

53,000 ResultsAny timeOpen links in new tab

Invasive micropapillary carcinoma: A distinct type of ...

<https://www.ncbi.nlm.nih.gov/pmc/articles/PMC24782612>

Apr 28, 2014 · Invasive micropapillary carcinoma (IMPC) is a rare histological type of tumor, first described in invasive ductal breast cancer, than in malignancies in other organs such as lungs, urinary bladder, ovaries or salivary glands. Recent literature data shows that this histological lesion has also been found in cancers of the gastrointestinal system.

Cited by: 9

Author: Katarzyna Guzińska-Ustymowicz, Katar...

Publish Year: 2014

Invasive micropapillary carcinoma: A distinct type of ...

europepmc.org/articles/PMC4000496

Invasive micropapillary carcinoma (IMPC) is a rare histological type of tumor, first described in invasive ductal breast cancer, than in malignancies in other organs such as lungs, urinary bladder, ovaries or salivary glands. Recent literature data shows that this histological lesion has also been found in cancers of the gastrointestinal system.

Invasive micropapillary carcinoma of the ampulla of Vater ...

<https://www.ncbi.nlm.nih.gov/pubmed/21110170>

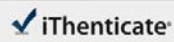
Invasive micropapillary carcinoma is characterized by extensive lymph node metastasis and a

Search Tools

Turn off Hover Translation (关闭翻译)

激活 Windows

转到“设置”以激活 Windows。



61670_Auto_Edited.docx

Quotes Included
Bibliography Included7%
SIMILARITY

Name of Journal: *World Journal of Clinical Cases*

Manuscript NO: 61670

Manuscript Type: CASE REPORT

Rare histological subtype of invasive micropapillary carcinoma in the ampulla of Vater: a case report

Ampullary invasive micropapillary carcinoma

Hirotsugu Noguchi, Michiyo Higashi, Tetsuya Idichi, Hiroshi Kurahara, Yuko Mataka, Takashi Tasaki, Ikumi Kitazono, Takao Ohtsuka, Akihide Tanimoto

Match Overview

1	Internet 25 words s3.amazonaws.com	1%
2	Internet 25 words crawled on 06-Dec-2020 synapse.koreamed.org	1%
3	Internet 24 words crawled on 20-Aug-2020 www.jstage.jst.go.jp	1%
4	Internet 24 words crawled on 22-Dec-2020 www.vgn.net.com	1%
5	Crossref 15 words W. Koizumi: "Phase II study of S-1 plus leucovorin in patients with metastatic colorectal cancer", <i>Annals of Oncology</i>	1%
6	Crossref 15 words Feng Ye, Ping Yu, Na Li, Anli Yang, Xinhua Xie, Hailin Tang, Peng Liu: "Prognosis of invasive micropapillary carcinoma"	1%

国内版 国际版

Rare histological subtype of invasive micropapillary carcinoma in the



ALL IMAGES VIDEOS

51,800 Results Anytime

Invasive micropapillary carcinoma: A distinct type of ...

<https://www.ncbi.nlm.nih.gov/pmc/articles/pmid/24782612>

Apr 28, 2014 · Invasive micropapillary carcinoma (IMPC) is a rare histological type of tumor, first described in invasive ductal breast cancer, than in malignancies in other organs such as lungs, urinary bladder, ovaries or salivary glands. Recent literature data shows that this histological lesion has also been found in cancers of the gastrointestinal system.

Cited by: 9 Author: Katarzyna Guzińska-Ustymowicz, Katarz...

Publish Year: 2014

S
Ti

Invasive micropapillary carcinoma: A distinct type of ...

europepmc.org/articles/PMC4000496

Invasive micropapillary carcinoma (IMPC) is a rare histological type of tumor, first described in invasive ductal breast cancer, than in malignancies in other organs such as lungs, urinary bladder, ovaries or salivary glands. Recent literature data shows that this histological lesion has also been found in cancers of the gastrointestinal system.

PEOPLE ALSO ASK

What are the different types of carcinoma of the ampulla?



What is an ampullary carcinoma?



What is ampulla ampulla lesion?



What are the side effects of ampulla excision?



Feedback

Invasive micropapillary carcinoma of the ampulla of Vater ...

<https://www.ncbi.nlm.nih.gov/pubmed/21110170>

Invasive micropapillary carcinoma is characterized by extensive lymph node metastasis and a poor prognosis. This histological variant was first described in breast cancer, with a few subsequent reports of it in the ampullo-pancreato-biliary region. We report a case of invasive micropapillary carcinoma of the papilla of Vater.

Cited by: 0 Author: Takao Fujita, Masaru Kozaki, Naoto Ota