



BRIEF ARTICLE

Sickle cell cholangiopathy: An endoscopic retrograde cholangiopancreatography evaluation

Hussain Issa, Ali Al-Haddad, Ahmed Al-Salem

Hussain Issa, Department of Internal Medicine, Division of Gastroenterology, King Fahad Specialist Hospital, Dammam 31444, Saudi Arabia

Ali Al-Haddad, Department of Internal Medicine, Qatif Central Hospital, Qatif 31911, Saudi Arabia

Ahmed Al-Salem, Department of Pediatric Surgery, Maternity and Children Hospital, Dammam, Qatif 31911, Saudi Arabia

Author contributions: Issa H performed the procedures, was involved in collecting the data, and in editing the manuscript; Al-Haddad A performed the procedures, was also involved in collecting the data, and in editing the manuscript; Al-Salem A designed the study, was involved in collecting the data, and in writing the manuscript.

Correspondence to: Dr. Ahmed Al-Salem, Department of Pediatric Surgery, Maternity and Children Hospital, Dammam, PO Box 61015, Qatif 31911,

Saudi Arabia. ahsalsalem@hotmail.com

Telephone: +966-505818009 Fax: +966-38630009

Received: August 14, 2009 Revised: September 18, 2009

Accepted: September 25, 2009

Published online: November 14, 2009

biliary sludge and bile duct stones in SCD, endoscopic sphincterotomy might prove helpful in these patients.

© 2009 The WJG Press and Baishideng. All rights reserved.

Key words: Sickle cell disease; Hepatobiliary; Cholestatic jaundice; Sickle cell hepatopathy; Sickle cell cholangiopathy; Endoscopic retrograde cholangiopancreatography

Peer reviewer: Zhao-Shen Li, Professor, Department of Gastroenterology, Second Military Medical University, 168 Changhai Road, Shanghai 200433, China

Issa H, Al-Haddad A, Al-Salem A. Sickle cell cholangiopathy: An endoscopic retrograde cholangiopancreatography evaluation. *World J Gastroenterol* 2009; 15(42): 5316-5320 Available from: URL: <http://www.wjgnet.com/1007-9327/15/5316.asp> DOI: <http://dx.doi.org/10.3748/wjg.15.5316>

Abstract

AIM: To evaluate the role of endoscopic retrograde cholangiopancreatography (ERCP) in patients with sickle cell disease (SCD).

METHODS: Two hundred and twenty four SCD patients with cholestatic jaundice (CJ) had ERCP. The indications for ERCP were based on clinical and biochemical evidence of CJ and ultrasound findings.

RESULTS: Two hundred and forty ERCPs were performed. The indications for ERCP were: CJ only in 79, CJ and dilated bile ducts without stones in 103, and CJ and bile duct stones in 42. For those with CJ only, ERCP was normal in 42 (53.2%), and 13 (16.5%) had dilated bile ducts without an obstructive cause. In the remaining 22, there were bile duct stones with or without dilation. For those with CJ, dilated bile ducts and no stones, ERCP was normal in 17 (16.5%), and 28 (27.2%) had dilated bile ducts without an obstructive cause. In the remaining 58, there were bile duct stones with or without dilation. For those with CJ and bile duct stones, ERCP was normal in two (4.8%), and 14 (33.3%) had dilated bile ducts without an obstructive cause. In the remaining 26, there were bile duct stones with or without dilatation.

CONCLUSION: Considering the high frequency of

INTRODUCTION

Sickle cell disease (SCD) is common in the Eastern Province of Saudi Arabia and it can affect any part of the body^[1-3]. One of the main organs to be affected by SCD is the hepatobiliary system. However, this is variable in character and severity, and can be presented as a variety of symptoms, including cholelithiasis, choledocholithiasis, and cholestatic jaundice (CJ). CJ can be caused by several diseases and one of the common intrahepatic causes is sickling of red blood cells (RBC), which is also called hepatic crisis or hepatic sequestration (sickle cell hepatopathy)^[4,5]. This can mimic extrahepatic bile ducts obstruction, which causes diagnostic and therapeutic dilemmas. There is also a high frequency of cholelithiasis and choledocholithiasis in patients with SCD^[3,6-8]. It is of paramount importance to differentiate between these causes and one of the diagnostic and therapeutic modalities in the evaluation of patients with CJ is endoscopic retrograde cholangiopancreatography. Thus, we evaluated the role of endoscopic retrograde cholangiopancreatography (ERCP) in patients with SCD, with an emphasis on SCD cholangiopathy.

MATERIALS AND METHODS

Over a period of 15 years (1993-2008), 224 patients with

Table 1 ERCP findings in patients with cholestatic jaundice only (Total No. of patients = 79)

Finding	n (%)
Normal	42 (53.2)
Dilated CBD without stones	11 (13.9)
Dilated CBD with stones	10 (12.7)
Dilated bile ducts with stones	6 (7.6)
Dilated bile ducts without stones	1 (1.3)
Dilated CHD without stones	1 (1.3)
Normal CBD with stones	1 (1.3)
Edematous inflamed papilla	4 (5.1)

ERCP: Endoscopic retrograde cholangiopancreatography; CBD: Common bile duct; CHD: Common hepatic duct.

Table 3 ERCP findings in patients with cholestatic jaundice and bile duct stones (Total No. of patients = 42)

Finding	n (%)
Normal	2 (4.8)
Dilated CBD without stones	7 (16.7)
Dilated CBD with stones	14 (33.3)
Dilated bile ducts without stones	7 (16.7)
Dilated bile ducts with stones	7 (16.7)
Normal CBD with a stone	1 (2.4)
Edematous inflamed papilla	4 (9.5)

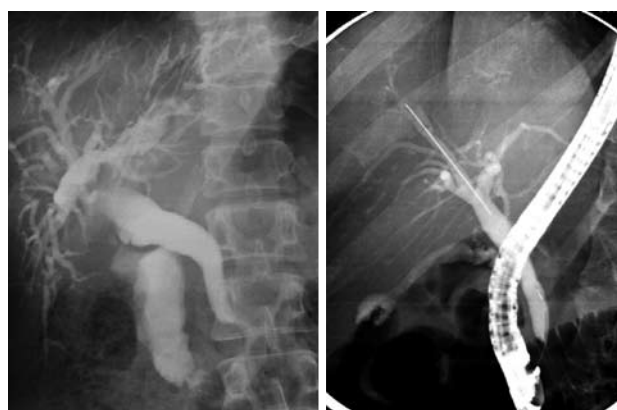
SCD underwent 240 ERCP procedures. Their medical records were reviewed and the following information was obtained: age, sex, clinical presentation, investigations, indication for ERCP, abdominal ultrasound results, ERCP findings, therapeutic procedures at the time of ERCP, complications and outcome. All had an abdominal ultrasound and the indications for ERCP were based on clinical and biochemical evidence of CJ and ultrasound findings. Based on abdominal ultrasound findings, the patients were divided into three groups as follows: (1) those with normal ultrasound, (2) Those with dilated bile ducts but no stones, and (3) Those with bile duct stones. All ERCPs were performed in the radiology department using an Olympus TJF 240 or JF 260 side-viewing duodenoscope. This was done under general anesthesia with nasotracheal intubation for children less than 10 years of age, and under sedation using meperidine (1 mg/kg) and diazepam (0.1-0.2 mg/kg) for those above 10 years of age. The ampulla of Vater was cannulated with tapered or regular catheters and the biliary ducts were deliberately visualized under fluoroscopy using Hexabrix (320 mg diluted to 50%). Appropriate radiographs were obtained and, where indicated, sphincterotomy was performed using a 5F sphincterotome (Olympus) and bile duct stones, if found, were extracted with a basket, balloon extractor, or mechanical lithotripter.

RESULTS

Two hundred and twenty four patients with SCD underwent 240 ERCP procedures. There were 144 males and 80 females. Their mean age was 22.4 years (5-70 years). Their

Table 2 ERCP findings in patients with cholestatic jaundice and dilated bile ducts on ultrasound (Total No. of patients = 103)

Finding	n (%)
Normal	17 (16.5)
Dilated CBD without stones	17 (16.5)
Dilated CBD with stones	30 (29.13)
Dilated bile ducts without stones	11 (10.7)
Dilated bile ducts with stones	17 (16.5)
Normal CBD with a stone	1 (0.98)
Choledochoduodenal fistula	2 (1.94)
Edematous inflamed papilla	8 (7.8)

**Figure 1** Endoscopic retrograde cholangiopancreatography (ERCP) showing dilated CBD and common hepatic duct without an obstruction.

mean hemoglobin S (HbS) was 76.8% (64.7%-92.3%) and their mean hemoglobin F (HbF) was 20.4% (5.1%-34.0%). Their mean total bilirubin was 224 g/L (55-395 g/L). Their mean direct bilirubin was 134 g/L (40-263 g/L). Their mean alkaline phosphatase was 486 IU/mL (81-1189 IU/mL) (Normal: 50-136 IU/mL). Their mean alanine transaminase (ALT) was 234.3 IU/mL (50-761 IU/mL) (Normal: 30-56 IU/mL) and their mean aspartate transaminase (AST) was 206.3 IU/mL (63-317 IU/mL) (Normal: 15-37 IU/mL). The indications for ERCP were: CJ only in 97, CJ and dilated bile ducts on ultrasound in 103, and CJ and bile duct stones on ultrasound in 42. The ERCP findings in each of these three groups are shown in Tables 1-3. In those with CJ only, there was a group of 13 patients (16.5%) with dilated bile ducts without an obstructive cause. In those with CJ and dilated bile ducts on ultrasound, there was a group of 28 patients (27.2%) with dilated bile ducts without an obstructive cause. In those with CJ and bile duct stones on ultrasound, there was a group of 14 patients (33.3%) with dilated bile ducts without an obstructive cause. In total 55 patients (24.6%) had dilated bile ducts without an obstructive cause or previous history of biliary duct stones (Figures 1 and 2).

The therapeutic procedures performed during ERCP are shown in Table 4. This included endoscopic sphincterotomy only in 42 out of the 55 patients (76.4%) who had dilated bile ducts without an obstructive cause. The remaining 13 patients were treated early in the study and no sphincterotomies were done. There was no mortality. Four patients developed minor bleeding from

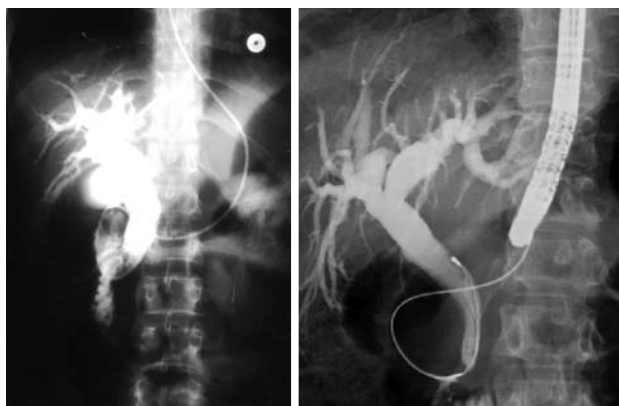

Figure 2 An ERCP showing markedly dilated bile ducts without an obstructive cause. Note the nasobiliary tube for drainage in the first image.

the sphincterotomy site. This was controlled with local adrenaline injection. Eight patients (3.3%) developed transient mild pancreatitis.

DISCUSSION

Sickle cell disease is one of the common hemoglobinopathies in the Eastern Province of Saudi Arabia, where the frequency of Sickle cell trait can reach as high as 25% in some areas^[1-3]. One of the common manifestations of SCD is jaundice, which can be caused by a variety of hepatobiliary diseases including CJ^[3-5]. There are certain causes of CJ that are SCD related. One of these causes is intrahepatic sickling of RBC^[4,5,9]. This is also called hepatic crisis or hepatic sequestration (sickle cell hepatopathy)^[4,5]. This can lead to cholestasis and a clinical picture that can resemble extrahepatic bile duct obstruction which causes diagnostic and therapeutic dilemmas. Sickle cell intrahepatic cholestasis on the other hand is a more serious condition, characterized by acute onset of hepatomegaly, hyperbilirubinemia, coagulopathy, and acute liver failure^[4,5]. Early identification of these is important as the process of sickling can be reversed by hydration and simple, or in severe cases, exchange blood transfusion. There is also a high frequency of cholelithiasis and choledocholithiasis in patients with SCD^[3,6-8]. The frequency of cholelithiasis in patients with SCD is variable, ranging from 4% to 55%, and this increases with age^[2,3,6-8]. In the general population with cholelithiasis, the incidence of common bile duct (CBD) stones has been reported to be 10%-15%, whereas in those with SCD it ranges from 18%-30%^[10,11]. Due to this high incidence, routine intraoperative cholangiography has been advocated^[10]. With the recent advances in laparoscopic cholecystectomy (LC), exclusion of CBD stones prior to LC is of great importance. ERCP has been shown to be valuable, both for the diagnosis and management of CBD stones, in patients with SCD who are undergoing or have undergone LC^[12-14]. ERCP is also of great importance in evaluating SCD patients with CJ, whether this is due to intrahepatic or extrahepatic causes. Ultrasound is a simple, non invasive imaging technique, and although gallstones and intrahepatic and

Table 4 Therapeutic procedures during ERCP

Procedure	n (%)
Endoscopic sphincterotomy only	42 (18.8)
Endoscopic sphincterotomy and stone extraction	79 (35.3)
Insertion of biliary stent	8 (3.6)
Endoscopic sphincterotomy, mechanical lithotripsy, and stone extraction	4 (1.8)
Insertion of a nasobiliary tube	4 (1.8)

extrahepatic bile duct dilatation are readily detected by ultrasound, common bile duct stones might be missed. ERCP, on the other hand, is more invasive but is the procedure of choice in suspected cases of extrahepatic bile duct obstruction. It provides direct visualization of the biliary tree and demonstrates the site and nature of the obstruction in more than 90% of patients. ERCP also provides therapeutic interventions, including endoscopic sphincterotomy and stone extraction, dilatation of strictures, and placement of stents and biliary drainage catheters^[15-19]. This was the case in our series, where we found ERCP valuable both as a diagnostic and therapeutic procedure. The majority of bile duct stones (95.4%) in our series were removed via ERCP. ERCP however was normal and unnecessary in a significant number of our patients (27%) with SCD and CJ. This was specially so in those who presented with CJ only (53.2%). These patients most likely had CJ secondary to intrahepatic sickling of RBC. Hepatic crisis and hepatic sequestration resemble each other clinically, and the only differentiating point between the two is a sudden drop in hematocrit, as well as a sudden increase in liver size in those with hepatic sequestration^[4,5]. Sickle cell intrahepatic cholestasis, on the other hand, is a more serious and often fatal complication of SCD where there is widespread intrahepatic sickling within the liver sinusoids leading to their blockage, vascular stasis with hepatic ischemia, and the striking feature is the highly elevated plasma bilirubin level^[4,5,12,13]. It is possible that our patients with CJ and normal ERCP represent a benign variant of intrahepatic cholestasis or a form of what is called benign hyperbilirubinemia^[5]. All our patients had hyperbilirubinemia, but their plasma AST, ALT and alkaline phosphatase levels were only moderately elevated. To support this, these patients subsequently recovered with conservative treatment including observation, hydration and, where indicated, blood transfusion. To overcome this and decrease the number of patients with normal ERCP, patients with CJ only should be evaluated further prior to ERCP, including endoscopic ultrasound (EUS) and magnetic resonance cholangiopancreatography (MRCP). However, these investigations are not readily available, and in these situations a period of observation and conservative management is to be advocated.

We found an interesting group of patients with SCD and CJ who had dilatation of the bile ducts without an obstructive cause (24.6%). There are several causes for bile duct dilatation, such as CBD stones, tumor of the head of pancreas or Ampulla of Vater,

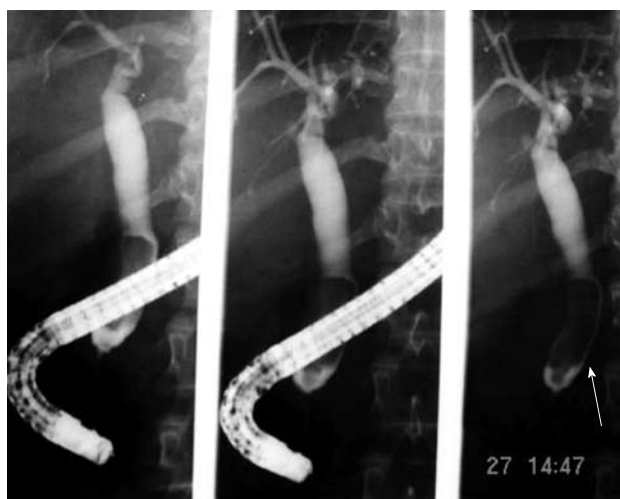

Figure 3 ERCP showing biliary sludge in a patient with SCD. An arrow indicates the site of biliary sludge.

and tumors or masses at the porta hepatis. None of our patients had an obstructive cause for the bile duct dilatation. The exact etiology of this dilatation is not known. However, we think this is a form of cholangiopathy that is a consequence of sickling in the end arteries of the biliary arterial tree leading to hypoxia and dilatation^[16,17]. The bile ducts are supplied via the hepatic arteries and ischemic bile duct injury might occur when these vessels are injured or occluded. This will ultimately result in ischemic stricture of the bile ducts. This however, depends on the extent and velocity of the occlusive process. In patients with SCD, we feel that the occlusion, which is usually not complete, is of the peribiliary vascular plexus and is a result of sickling within these vascular channels. This will ultimately lead to hypoxia of the bile ducts leading to their dilatation rather than ischemia and stricture formation. This is SCD cholangiopathy and the extent of this is also variable, as was demonstrated in our series. We found patients with bile duct dilatation limited to the common bile duct, but there were also those who had dilatation involving both extra and intrahepatic bile ducts (Figures 1 and 2). Documenting this is of great importance, as these patients need to be followed up regularly for the possibility of developing bile duct stones. Cunningham, in a study of the common hepatic duct diameter in SCD patients, found only two patients with clinically silent enlargement based on ultrasonic evaluation of 95 patients^[20]. Their patients, in contrast to our patients, were young with a mean age group of 16.8 years. Taking in consideration the high frequency of biliary sludge and the possibility of bile duct stones formation in these patients, 42 (76.4%) of our patients with dilated bile ducts without an obstructive cause had endoscopic sphincterotomy, as this could obviate the future development of bile duct stones (Figure 3). Thus, the value of endoscopic sphincterotomy in this group of patients needs to be evaluated further, as endoscopic sphincterotomy is not without complications.

COMMENTS

Background

Cholestatic jaundice (CJ) is common in patients with sickle cell disease (SCD) and can be caused by both intra and extra hepatic pathology. However, there are certain causes of CJ that are specific to patients with SCD. One of the common intrahepatic causes is sickling of red blood cells (RBC), which is also called hepatic crisis or hepatic sequestration (sickle cell hepatopathy). This can mimic extrahepatic bile ducts obstruction which causes diagnostic and therapeutic dilemmas. Endoscopic retrograde cholangiopancreatography (ERCP) is one of the diagnostic and therapeutic measures used in patients with CJ. The value of ERCP for patients with SCD needs to be evaluated.

Research frontiers

CJ is common in patients with SCD and it is of therapeutic importance to define the cause as soon as possible. Ultrasound is a valuable, non invasive, investigation but it has limitations. ERCP, on the other hand, is invasive but more valuable, both as a diagnostic and therapeutic procedure. It provides direct visualization of the biliary tree and demonstrates the site and nature of obstruction. This is of importance in excluding extrahepatic causes of CJ in patients with SCD, and once this is excluded emphasis is concentrated on intrahepatic causes.

Applications

Taking in consideration the high frequency of biliary sludge, and the possibility of bile duct stones formation in these patients, endoscopic sphincterotomy might obviate the future development of bile duct stones.

Terminology

Sickle cell disease is a form of hemoglobinopathy that results from a single amino acid substitution of valine for glutamic acid in the 6th position among the 146 amino acids of the hemoglobin-beta chain.

Peer review

This is an interesting study evaluating sickle cell cholangiopathy by ERCP.

REFERENCES

- 1 Perrine RP, Pembrey ME, John P, Perrine S, Shoup F. Natural history of sickle cell anemia in Saudi Arabs. A study of 270 subjects. *Ann Intern Med* 1978; **88**: 1-6
- 2 Pembrey ME, Perrine RP, Wood WG, Weatherall DJ. Sickle beta 0 thalassemia in Eastern Saudi Arabia. *Am J Hum Genet* 1980; **32**: 26-41
- 3 Al-Awamy BH. Sickle cell anemia, its clinical manifestations and their management. *Saudi Med J* 1987; **9**: 553-562
- 4 Banerjee S, Owen C, Chopra S. Sickle cell hepatopathy. *Hepatology* 2001; **33**: 1021-1028
- 5 Koullapis N, Kouroupi IG, Dourakis SP. Hepatobiliary manifestations of sickle cell disease. *Haema* 2005; **8**: 393-404
- 6 Al-Salem AH, Qaisarruddin S, Al-Dabbous I, Bhamidipati P, Abusair H, Amman H, Al Jam'a A. Cholelithiasis in children with sickle cell disease. *Pediatr Surg Int* 1996; **11**: 471-473
- 7 Rennels MB, Dunne MG, Grossman NJ, Schwartz AD. Cholelithiasis in patients with major sickle hemoglobinopathies. *Am J Dis Child* 1984; **138**: 66-67
- 8 Sarnaik S, Slovis TL, Corbett DP, Emami A, Whitten CF. Incidence of cholelithiasis in sickle cell anemia using the ultrasonic gray-scale technique. *J Pediatr* 1980; **96**: 1005-1008
- 9 Krauss JS, Freant LJ, Lee JR. Gastrointestinal pathology in sickle cell disease. *Ann Clin Lab Sci* 1998; **28**: 19-23
- 10 Al-Salem AH, Nangalia R, Kolar K, Qaisarruddin S, Al-Dabbous I, Al-Jam'a A. Cholecystectomy in children with sickle cell disease. Perioperative management. *Pediatr Surg Int* 1995; **10**: 472-474
- 11 Ware RE, Schultz WH, Filston HC, Kinney TR. Diagnosis and management of common bile duct stones in patients with sickle cell hemoglobinopathies. *J Pediatr Surg* 1992; **27**: 572-575
- 12 O'Callaghan A, O'Brien SG, Ninkovic M, Butcher GP, Foster CS, Walters JR, Roberts IA. Chronic intrahepatic cholestasis in sickle cell disease requiring exchange transfusion. *Gut* 1995; **37**: 144-147

- 13 **Shao SH**, Orringer EP. Sick cell intrahepatic cholestasis: approach to a difficult problem. *Am J Gastroenterol* 1995; **90**: 2048-2050
- 14 **Gholson CF**, Sittig K, McDonald JC. Recent advances in the management of gallstones. *Am J Med Sci* 1994; **307**: 293-304
- 15 **Al-Salem AH**, Nourallah H. Sequential endoscopic/laparoscopic management of cholelithiasis and choledocholithiasis in children who have sickle cell disease. *J Pediatr Surg* 1997; **32**: 1432-1435
- 16 **Issa H**, Al-Haddad A, Al-Salem AH. Diagnostic and therapeutic ERCP in the pediatric age group. *Pediatr Surg Int* 2007; **23**: 111-116
- 17 **Liu CL**, Lo CM, Lai EC, Fan ST. Endoscopic retrograde cholangiopancreatography and endoscopic endoprosthesis insertion in patients with Klatskin tumors. *Arch Surg* 1998; **133**: 293-296
- 18 **Ahmed M**, Dick M, Mieli-Vergani G, Harrison P, Karani J, Dhawan A. Ischaemic cholangiopathy and sickle cell disease. *Eur J Pediatr* 2006; **165**: 112-113
- 19 **Hillaire S**, Gardin C, Attar A, Attassi M, Terris B, Belghiti J, Degott C, Erlinger S, Valla D. Cholangiopathy and intrahepatic stones in sickle cell disease: coincidence or ischemic cholangiopathy? *Am J Gastroenterol* 2000; **95**: 300-301
- 20 **Cunningham JJ**. Sonographic diameter of the common hepatic duct in sickle cell anemia. *AJR Am J Roentgenol* 1983; **141**: 321-324

S- Editor Tian L L- Editor Stewart GJ E- Editor Ma WH