



## Exostoses of the external auditory canal

David R Lobo

David R Lobo, Department of Otolaryngology, Hospital El Escorial, San Lorenzo de El Escorial, 28200 Madrid, Spain  
David R Lobo, Instituto Antoli-Candela, 28043 Madrid, Spain  
Author contributions: Lobo DR solely contributed to this manuscript.

Conflict-of-interest: None.

Open-Access: This article is an open-access article which was selected by an in-house editor and fully peer-reviewed by external reviewers. It is distributed in accordance with the Creative Commons Attribution Non Commercial (CC BY-NC 4.0) license, which permits others to distribute, remix, adapt, build upon this work non-commercially, and license their derivative works on different terms, provided the original work is properly cited and the use is non-commercial. See: <http://creativecommons.org/licenses/by-nc/4.0/>

Correspondence to: David R Lobo, MD, PhD, Department of Otolaryngology, Hospital El Escorial, San Lorenzo de El Escorial, Ctra. M-600 de Guadarrama a San Lorenzo de El Escorial, Km. 6,255, 28200 Madrid, Spain. [dlobo28@gmail.com](mailto:dlobo28@gmail.com)  
Telephone: +34-91-8973021

Fax: +34-91-8973031

Received: November 29, 2014

Peer-review started: November 29, 2014

First decision: December 12, 2014

Revised: December 31, 2014

Accepted: January 15, 2015

Article in press: January 15, 2015

Published online: February 28, 2015

review offers an overview of the recent advances in the understanding of this condition, with a special focus on the etiology and physiopathology of this condition, the different surgical procedures and their outcomes, the risk factors for recurrence and the results of preventive measures. Finally, this review suggests the need for the otological surgeon to acquire a great deal of experience before undertaking surgical treatment of exostoses as it is a challenging operation and, besides expertise, demands great patience and extreme care in order to achieve good results.

**Key words:** Exostoses; Surfer's ear; Ear canal; Surgical procedures; Recurrence; Prevention

© **The Author(s) 2015.** Published by Baishideng Publishing Group Inc. All rights reserved.

**Core tip:** Readers interested in aquatic sports medicine, otological procedures or bone lesions will find in this review a thorough summary of the most relevant aspects of ear canal exostoses, with a special focus on the major advances achieved in the knowledge of its etiology and pathophysiology, prevention and surgical therapy, and the challenges that remain and may guide research in the next few years and beyond, so that complications are minimized and the best outcomes are achieved.

### Abstract

Ear canal exostoses are bilateral, usually symmetric multiple bony growths occurring in the medial portion of the external auditory canal. Also known as surfer's ear, exostosis is thought to be a reactive process from repeated stimulation by cold water and is much more common than external auditory osteoma. Exostoses are usually asymptomatic and discovered on routine otoscopy. Indications for surgical treatment are recurrent otitis externa, hearing loss, otalgia and other conditions in which access medial to the exostoses is required. Surgery is not risk-free and postoperative complications are the most important factor for negative impact on the patient's health-related quality of life. This

Lobo DR. Exostoses of the external auditory canal. *World J Otorhinolaryngol* 2015; 5(1): 14-20 Available from: URL: <http://www.wjgnet.com/2218-6247/full/v5/i1/14.htm> DOI: <http://dx.doi.org/10.5319/wjo.v5.i1.14>

### INTRODUCTION

Ear canal exostoses, also known as surfer's ear, are bilateral, usually symmetric multiple bony growths occurring in the medial portion of the external auditory canal, just lateral to the tympanic membrane

and medial to the sutures of the tympanic bone. Clinically, they are easily differentiated from the similar but less common external auditory osteoma, which is a unilateral, pedunculated lesion occurring mostly in the outer half of the ear canal, arising from the tympanosquamous or tympanomastoid suture lines. Histopathologically, however, there is no consensus regarding differentiation of exostoses from osteomas<sup>[1,2]</sup>. Histologic examination of exostoses reveals remodeled densely lamellar bone tissue superficially, running parallel to the periosteum, suggesting continued periodic apposition and deep to this, loosely compact and more vascular bone, less organized around fibrovascular channels<sup>[3]</sup>.

Exostoses are usually asymptomatic and discovered on routine otoscopy. They have been described as a functional physiological organ in aquatic mammals like hooded seals<sup>[4]</sup>. Their prevalence in humans has been well studied among surfing populations as well as among people involved in other water activities such as kayaking, diving, swimming or sailing<sup>[5-12]</sup>. The prevalence of exostoses in coastal inhabitants is much higher than in valley or mountain inhabitants, with men much more affected than women<sup>[8]</sup>. This susceptibility among coastal populations or those engaged in water activities has also been studied in different ancient or prehistoric populations<sup>[13-17]</sup>. Although most cases do not present to medical care, when the stenosis caused by exostosis exceeds a certain limit, defined as greater than 80%, the patient may develop conductive hearing loss due to occlusion and other symptoms, usually recurrent wax retention, recurrent otitis externa with otalgia or tinnitus<sup>[18]</sup>. When these symptoms become bothersome and cannot be managed with medical treatment, surgical excision of exostosis is warranted. Surgery may also be necessary as an access path for treating other middle ear conditions such as otosclerosis or chronic suppurative otitis media.

## ETIOLOGY

Exostoses build up in various locations in the body as new subperiosteal bone is formed as a response to increased tension on the periosteum that induces osteoblastic activity. Prolonged reflex vasodilatation occurring in the bony meatus following exposure to cold water or cold winds offers such an increase in tension, for there is no insulating layer of subcutaneous tissue between epithelium and underlying periosteum in the deep meatus. Moreover, venous congestion promotes lamellated new bone production as seen microscopically in exostoses<sup>[19]</sup>.

Early theories proposed some form of prolonged irritation to explain the origin of exostoses. For instance, chronic otitis externa, gout, syphilis, subperiosteal abscess or in individuals who routinely use stethoscopes<sup>[19-22]</sup>.

However, growing evidence suggests that prolonged

exposure to cold water, as seen most frequently in aquatic sportsmen, is the most important etiopathogenic factor<sup>[23-26]</sup>. Cold air may also be a contributing factor in the formation of exostoses. This is supported by a series of findings. First, the skeletal remains of coastal populations from areas with mild atmospheric temperatures and wind chill factor do not show high frequencies of ear canal exostoses<sup>[14]</sup>. In addition, the most affected water-sport athletes reported in a study practiced sailing, which exposes the subjects to continuous cold jets, and according to another study the prevalence of exostoses was higher among the group of patients who practiced head-above-surface aquatic sports such as surfing and sailing (and therefore were more exposed to wind chill factor) than among the group of patients who practiced head-immersed aquatic sports such as swimming or diving<sup>[12,27]</sup>. Interestingly, the prevalence and severity of exostoses in breath-hold divers, who stay longer above surface, is more similar to previously published results for surfing populations than to those for scuba-diving populations<sup>[28]</sup>. Finally, the severity of exostoses seems to correspond to the ear that is more exposed to the predominant coastal winds<sup>[29]</sup>.

Regular exposure to low air temperatures and/or cold winds could explain the development of exostoses in non-aquatic sport enthusiasts or people not engaged in long-term cold water activities.

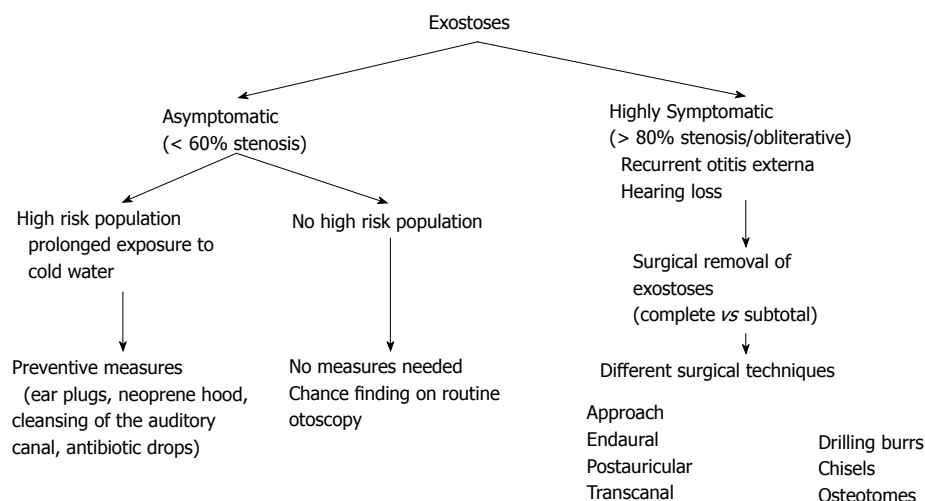
Genetic factors may also explain a higher predisposition to aural exostoses as these have not been reported in black people<sup>[30]</sup>. There might be other factors as well involved in the origin of exostoses. Half of the population did not report exposure to cold water in one study<sup>[31]</sup>. Nevertheless, most studies have focused on populations engaged in water activities for recreational, occupational or military reasons.

## DIAGNOSIS

Exostoses are discovered on routine otoscopy. Computed tomography scans are rarely performed, usually before the surgery to evaluate the extension of exostoses, but generally they are not believed to be as helpful as direct microscopic transcanal visualization of ear canal anatomy.

For ear canals that are less than obliterative, the degree of stenosis, the percentage of closure, can be estimated. This can be achieved either by outlining the approximate lumen of the ear canals in photographs taken at the start and conclusion of surgery and then measuring the respective areas using a computer program, or by taking photographs using an endoscope connected to a camera, with each print being assessed by three independent observers<sup>[19,27]</sup>. Unfortunately, in most publications authors do not report how the percentage of closure is evaluated.

Audiologic testing is mandatory, as conductive



**Figure 1** Proposed algorithm scheme for the management of exostoses and surgical options. Some studies report surgical removal of exostoses in asymptomatic patients, although this approach remains controversial and is not supported by most authors.

hearing loss is the second most frequent indication for surgery after repetitive otitis externa.

## TREATMENT

Most patients with exostoses are asymptomatic. When symptoms make their first appearance, these are due to wax accumulation in the external auditory canal, and therefore the most frequent symptom is ear fullness, which can lead to otitis externa and ultimately to conductive hearing loss if all these conditions do not improve. In these cases, the initial treatment is the clearance of the ear canal to prevent wax retention and hearing loss. Antibiotic and anti-inflammatory drops should be prescribed in the case of otitis externa. Surgical intervention should be considered only in the most severe cases with obliterative exostosis, when cleansing of the auditory canal is no longer possible, when otitis externa becomes very recurrent or when there is conductive hearing loss. This usually occurs when the degree of stenosis is more than 80%, and hardly ever when it is less than 60%<sup>[18]</sup>.

Although most authors agree that exostoses should be operated on only when the patient is symptomatic or when the exostoses prevent medial access in the ear canal for other procedures, some studies report surgical removal of exostoses in asymptomatic patients, when the degree of stenosis was assessed as minimal (< 30%) or moderate (30%-60%) or to facilitate the fitting of a hearing aid<sup>[27,32]</sup>. However, surgery has a considerable complication rate and cannot achieve excellent symptom control in all cases. This surgical procedure demands considerable patience and a variety of precautions, is difficult and tedious, and the outcome is uncertain due to a number of factors such as the proximity of the exostoses to the tympanic membrane, temporomandibular joint and facial nerve, the narrow or non-existent space between the exostoses, the inability to visualize medial ear canal

landmarks, the thin skin covering the exostoses, and the ease with which modest bleeding can obscure the surgeon's view<sup>[19]</sup>. Moreover, the patient's desire to return to aquatic sports as rapidly as possible after surgery may jeopardize the results of surgery and lead to complications or early recurrence. Thus, correct patient selection and indication for surgery is paramount. An algorithm for the surgical options and management of exostoses is provided in Figure 1.

The most frequently employed surgical techniques involve the postauricular or endaural approaches and the use of different drilling systems and drilling burrs. Transcanal approaches and the use of osteotomes, chisels, curettes and gouges have also been employed<sup>[18,19,29]</sup>. The beaver knife is used to incise the posterior meatal skin, forming a flap which is held anteriorly. This flap is usually protected by a small piece of aluminium harvested from the packing of surgical threads<sup>[32,33]</sup>.

Most authors recommend complete removal of exostoses to prevent early recurrence. However, several authors have advocated subtotal removal of exostoses so that patients are not placed at risk of injury to the ossicles, facial nerve or chorda tympani nerve<sup>[34,35]</sup>. Although facial nerve monitoring is not generally used in these procedures, the surgeon must be well aware of the course of facial nerve in the posterior inferior medial bony canal wall. In an anatomical study of the temporal bone, the facial nerve was located in a plane lateral to the tympanic membrane in the posterior-inferior quadrant of the medial bony ear canal in 70% of specimens<sup>[36]</sup>. In cases of severe narrowing, facial nerve protection becomes a priority. This is achieved by restricting blind drilling of the posterior canal wall while the tympanic membrane is not visible<sup>[32]</sup>.

When the stenosis is severe the procedure can be very demanding, especially given the absence of adequate landmarks. This is why some authors prefer the retroauricular approach for all but the mildest narrowing<sup>[32,33]</sup>. The retroauricular approach

**Table 1** Different approaches and surgical techniques

Ref.	Year	Endaural (operations)	Postauricular (operations)	Transcanal (operations)	Drilling (operations)	Osteotomes, chisels <sup>1</sup>
Altuna Mariezkurrena <i>et al</i> <sup>[33]</sup>	2004		× (52)		×	
DiBartolomeo <i>et al</i> <sup>[30]</sup>	1979			× (21)	× (21)	
Bordure <i>et al</i> <sup>[37]</sup>	1994	×	×		× (64)	
Frese <i>et al</i> <sup>[38]</sup>	1999	× (56)	× (3)		× (59)	
Hempel <i>et al</i> <sup>[31]</sup>	2012	× (33)	× (2)		NA	
Hetzler <sup>[19]</sup>	2007			× (221)	× (42) <sup>2</sup>	× (179)
Hurst <i>et al</i> <sup>[39]</sup>	2001	× (58)	× (6)		×	
King <i>et al</i> <sup>[29]</sup>	2010		× (80)		× (71) <sup>3</sup>	× (4)
Oostvogel <i>et al</i> <sup>[40]</sup>	1992	×	×		×	
Portmann <i>et al</i> <sup>[41]</sup>	1991		× (25)		× (25)	
Sanna <i>et al</i> <sup>[32]</sup>	2004		× (65)		× (65)	
Stougaard <i>et al</i> <sup>[35]</sup>	1999	× (7)	× (1)	× (16)	× (24)	
Timofeev <i>et al</i> <sup>[27]</sup>	2004	NA	NA	NA	× (46)	
Whitaker <i>et al</i> <sup>[18]</sup>	1998			× (27)		× (27)

<sup>1</sup>Hetzler<sup>[19]</sup> used osteotomes whereas King *et al*<sup>[29]</sup> and Whitaker *et al*<sup>[18]</sup> employed chisels; <sup>2</sup>Both osteotomes and drilling burrs were used in these 42 patients;

<sup>3</sup>Hand-held surgical drill and chisel were used in 61 patients whereas drill only was employed in 10 patients. NA: Not applicable.

also gives access to the temporalis fascia, which can be harvested for grafting bare areas of the external auditory canal<sup>[32]</sup>.

Sensorineural hearing loss has been reported after the removal of exostoses by drilling techniques, presumably as a result of prolonged noise exposure from drilling. The osteotome technique has the potential advantage of less risk of cochlear damage compared to the drilling technique. Moreover, osteotomes pose little risk of avulsing skin, which is really important to prevent postoperative canal stenosis<sup>[19]</sup>. Nevertheless, most surgeons are more familiar with drilling techniques than with the use of osteotomes, which has the risk of mobilizing an entire segment of bone, of traumatizing the tympanic membrane, or of exposing periosteum anterior to the anterior bony wall and thus damaging the temporomandibular joint. To minimize complications with osteotomes, incremental removal of bone is advised<sup>[19]</sup>. The different approaches and techniques employed are shown in Table 1<sup>[18,19,27,29-33,35,37-41]</sup>.

There is no consensus regarding which canal exostoses should be removed first. Some authors prefer removing the anterior exostoses first (or these are even the only exostoses removed)<sup>[34]</sup> whereas other surgeons address the posterior exostoses first<sup>[33]</sup>. Finally, other authors recommend removal the superior, inferior and anterior exostoses first, and only when the tympanic membrane position is verified do they remove the posterior wall protrusion<sup>[32]</sup>.

At the end of the procedure, the skin does not usually have the circumference necessary to cover the new canal, and several vertical incisions are, therefore, performed in the skin with small scissors in order to ensure intimate contact of the skin with the bone. If any significant amount of bone remains bare, it is covered with fascia temporalis or a split thickness skin graft, as this allows for faster healing and re-epithelialization. Finally, pieces of gelatin

sponge soaked with antibiotic and anti-inflammatory drops are inserted in the ear canal along the various skin incisions and a cotton ball is placed in the ear meatus as a dressing.

## COMPLICATIONS

Surgical removal of exostosis is not a procedure without risks and in fact the number of complications is not low when we revise the literature.

Postoperative canal stenosis is one of the most frequent complications (Table 2)<sup>[18,19,27,29-33,35,37-45]</sup>. Integrity of healthy meatal skin is a key factor in the success of the operation. Loss of skin can lead to formation of granulation tissue, fibrous stenosis and membranous atresia. This fibrous stenosis could require surgical revision with excision of the scar and relining of the external auditory meatus with a split thickness skin graft. Preoperative severe persistent external otitis should be addressed before the operation as it can be another risk factor for developing this complication<sup>[38]</sup>.

Tympanic membrane perforation is another of the most frequent complications. These tympanic membrane tears may be pinpoint and require no additional treatment, healing by the time the ear canal has healed<sup>[19]</sup>. But in other cases, repair of the defect requires an underlay tympanoplasty, which is usually performed in conjunction with removal of the exostoses.

Other less frequent but more feared complications reported in the literature are damage to the temporo-mandibular joint or the facial nerve, sensorineural hearing loss, cervical subcutaneous emphysema and petrositis<sup>[43,44,46]</sup>. Not all cases of anterior canal wall dehiscence, protrusion, prolapse, herniation of the temporomandibular joint or even exposure of the temporomandibular joint capsule are symptomatic but they could lead to chronic

**Table 2** Complications of exostoses removal

Ref.	Year	No. of patients	No. of ears	No. of operations	TM tears or perforations <sup>1</sup>	Stenosis or scarring <sup>1</sup>	SNHL	Tinnitus	TMJ entry
Altuna	2004	45	52	52					
Mariezcurrera <i>et al</i> <sup>[33]</sup>									
Di Bartolomeo <i>et al</i> <sup>[30]</sup>	1979	16	21						1 (4.7%)
Bordure <i>et al</i> <sup>[37]</sup>	1994	36	64		8 (12.5%)		3 (4.7%)	2 (3.1%)	2 (3.1%)
Fisher <i>et al</i> <sup>[42]</sup>	1994	102		127	11 (8.6%)	2 (1.5%)	1 (0.8%)		1 (0.8%)
Frese <i>et al</i> <sup>[38]</sup>	1999	48		59	3 (5%)	4 (6.8%)	4 (6.8%)	1 (1.7%)	
Hempel <i>et al</i> <sup>[31]</sup>	2012	30	35			1 (2.8%)	2 (5.7%)	1 (2.8%)	
Hetzler <sup>[19]</sup>	2007	140	221	221	1 <sup>2</sup>		3 (1.3%)	3 (1.3%)	3 (1.3%)
Hurst <i>et al</i> <sup>[39]</sup>	2001	49		64	1 (1.5%)	2 <sup>3</sup>		1 (1.5%)	2 (1.9%)
King <i>et al</i> <sup>[29]</sup>	2010	58	83	83		4 (4.8%)		7 (8.4%)	
Oostvogel <i>et al</i> <sup>[40]</sup>	1992	51			1 (2%)		3 (5.9%)		
Portmann <i>et al</i> <sup>[41]</sup>	1991		25		1 (4%)		2 (8%)		1 (4%)
Reber <i>et al</i> <sup>[43]</sup>	2000	20		22	2 (9%)	2 (9%)	4 (18.2%)		2 (9.1%)
Sanna <i>et al</i> <sup>[32]</sup>	2004	57	65	65		2 (3%)	1 (1.5%)		
Seehy <i>et al</i> <sup>[44]</sup>	1982			79	8 (10.1%)				
Stougaard <i>et al</i> <sup>[35]</sup>	1999	19	24	24	1 (4.1%)		1 (4.1%)		1 (4.1%)
Timofeev <i>et al</i> <sup>[27]</sup>	2004	31	46	46		4 (8.7%)	1 (2.2%)	1 (2.2%)	
Vasama <i>et al</i> <sup>[45]</sup>	2003	136	182	182	5 (2.7%)	2 (1.1%)	4 (2.2%)		
Whitaker <i>et al</i> <sup>[18]</sup>	1998	18	27						7 (25.9%)

<sup>1</sup>TM tears or perforations requiring underlay tympanoplasty, or stenosis or scarring requiring revision surgery; <sup>2</sup>Although only one case required tympanoplasty, there were 29 tympanic membrane pinpoint tears that required no additional treatment and were healed by the time the ear canal skin had healed; <sup>3</sup>One tympanic membrane perforation and 2 ears requiring revision surgery for removal of granulations and sequestered bone. SNHL: Sensorineural hearing loss; TM: Tympanic membrane; TMJ: Temporomandibular joint.

symptoms that do not resolve with anti-inflammatory medication, such as temporomandibular joint pain, trismus and masticatory problems, and unnecessary movement in the canal which disrupts the healing process and facilitates postoperative stenosis.

Dizziness, vertigo, worsening of the preoperative air-bone gap, tinnitus and diminished sense of taste have also been reported<sup>[19,27,29,31,32,38-40]</sup>. Interestingly, dizziness and vertigo were reported in two studies in which osteotomes were used, and were probably due to the concussive forces applied to the temporal bone<sup>[19,29]</sup>. This was resolved with canalith repositioning.

## SURGICAL FOLLOW-UP AND PROGNOSIS

Careful observation of the ear canal should be emphasized during follow-up in order to recognize and treat early infection or granuloma, and prevent the risk of restenosis. Audiometric follow-up is also important to assess post-operative air-bone gap and detect any deterioration of bone conduction and sensorineural hearing loss.

The healing rate should also be considered, as this can be a major concern for patients who are mostly water sports enthusiasts and wish to resume their normal activity as soon as possible. Postoperative healing ranges from 2 to 16 wk (average 8 wk)<sup>[18,19,30,42-44]</sup>. The best results have been achieved with the osteotome technique by maximizing ear canal skin preservation and minimizing skin disruption<sup>[19]</sup>.

Surgery for ear canal exostoses improve patients'

health-related quality of life (HRQOL)<sup>[31,45]</sup>. Ninety percent of the patients were satisfied with the result of the operation, and would decide in favor of the operation in retrospect, according to one study<sup>[31]</sup>. Complications were the most important factor for the lack of patient benefit and had a negative impact on the patient HRQOL.

With regard to prognosis it should be pointed out again that exostoses are typically a benign condition that does not usually require surgical therapy. Here our interest and comments will therefore focus on the risk factors for severe exostoses in high risk populations and for restenosis after surgery. The relation between exposure to cold water and development of exostoses has been dealt with in the section on etiology. The risk of developing exostoses and the degree of ear canal obstruction increase proportionally to the frequency of exposure according to many different studies<sup>[5-8,11,23,25]</sup>. Indeed, a surfing index has been proposed to better predict the risk of the formation of external auditory exostoses and is expressed as the product of the period (years as an active surfer) and the frequency (number of surfing days per week)<sup>[5]</sup>. Thus, subjects who have participated in water sports for longer than 10 years show some evidence of exostoses. This may be preventable since those who use earplugs are less likely to develop exostoses<sup>[9]</sup>. Similarly, individuals who postoperatively participate in aquatic sports experience recurrence of the stenosis more rapidly, and protecting the ear canals increases the recurrence-free interval<sup>[27]</sup>. Nevertheless, very few participants in water activities use these precautions



(ear plugs, neoprene hood), even among those aware of the preventability of surfer's ear<sup>[47]</sup>. One reason for this could be that wearing earplugs impairs hearing. In this respect, soft prefabricated elastomer earplugs have been shown to cause less hearing impairment than custom-fitted silicone and custom-fitted acrylic ear plugs and are therefore preferable<sup>[48]</sup>.

However, the risk of recurrence does not only depend on new exposure to cold water. Although ear plugs could protect against the development of new exostoses, recurrence has been observed even in patients who stopped water sport activity completely after surgery<sup>[27]</sup>. The age of the patient at the time of operation is also a factor associated with the recurrence rate of stenosis. According to Timofeev et al<sup>[27]</sup> the older the patient, the faster the recurrent disease develops.

## CONCLUSION

Exostosis of the auditory canal is a prevalent condition in water sports enthusiasts and in those who engage in an aquatic activity professionally or out of necessity. Most cases are asymptomatic and are chance discoveries at otoscopy. However, when they cause recurrent infections or hearing loss, surgical intervention becomes necessary. Many different surgical approaches and techniques are employed, and the outcomes seem to depend more on the experience and expertise of the surgical team than on technical aspects, although the latter should be borne in mind in order to avoid complications. The possibility of even serious complications should not be underestimated since they have a negative impact on patient quality of life. Finally, many patients wish to resume their aquatic activities as soon as possible so that it becomes even more important to maximize precautions and to avoid the bare areas of skin and prevent infections and restenosis in the postoperative period.

## REFERENCES

- Fenton JE, Turner J, Fagan PA. A histopathologic review of temporal bone exostoses and osteomata. *Laryngoscope* 1996; **106**: 624-628 [PMID: 8628093 DOI: 10.1097/00005537-199605000-00020]
- Carbone PN, Nelson BL. External auditory osteoma. *Head Neck Pathol* 2012; **6**: 244-246 [PMID: 22183765 DOI: 10.1007/s12105-011-0314-7]
- Linthicum FH, Stewart TA. Exostoses of the external auditory canal. *Otol Neurotol* 2005; **26**: 1243-1244 [PMID: 16272951 DOI: 10.1097/01.mao.0000194895.18474.6e]
- Stenfors LE, Sade J, Hellström S, Anniko M, Folkow L. Exostoses and cavernous venous formation in the external auditory canal of the hooded seal as a functional physiological organ. *Acta Otolaryngol* 2000; **120**: 940-943 [PMID: 11200588 DOI: 10.1080/0016480050218663]
- Nakanishi H, Tono T, Kawano H. Incidence of external auditory canal exostoses in competitive surfers in Japan. *Otolaryngol Head Neck Surg* 2011; **145**: 80-85 [PMID: 21493286 DOI: 10.1177/0194599811402041]
- Altuna Mariezkurrena X, Gómez Suárez J, Luqui Albisua I, Vea Orte JC, Algaba Guimerá J. [Prevalence of exostoses among surfers of the Basque Coast]. *Acta Otorrinolaringol Esp* 2004; **55**: 364-368 [PMID: 15552211 DOI: 10.1016/S0001-6519(04)78537-4]
- Hurst W, Bailey M, Hurst B. Prevalence of external auditory canal exostoses in Australian surfboard riders. *J Laryngol Otol* 2004; **118**: 348-351 [PMID: 15165308 DOI: 10.1258/002221504323086525]
- Wong BJ, Cervantes W, Doyle KJ, Karamzadeh AM, Boys P, Brauel G, Mushtaq E. Prevalence of external auditory canal exostoses in surfers. *Arch Otolaryngol Head Neck Surg* 1999; **125**: 969-972 [PMID: 10488981 DOI: 10.1001/archotol.125.9.969]
- Moore RD, Schuman TA, Scott TA, Mann SE, Davidson MA, Labadie RF. Exostoses of the external auditory canal in white-water kayakers. *Laryngoscope* 2010; **120**: 582-590 [PMID: 20066729 DOI: 10.1002/lary.20781]
- Cooper A, Tong R, Neil R, Owens D, Tomkinson A. External auditory canal exostoses in white water kayakers. *Br J Sports Med* 2010; **44**: 144-147 [PMID: 18603582 DOI: 10.1136/bjsm.2008.048157]
- Karegeannes JC. Incidence of bony outgrowths of the external ear canal in U.S. Navy divers. *Undersea Hyperb Med* 1995; **22**: 301-306 [PMID: 7580769]
- Fabiani M, Barbara M, Filipo R. External ear canal exostosis and aquatic sports. *ORL J Otorhinolaryngol Relat Spec* 1984; **46**: 159-164 [PMID: 6728438]
- Okumura MM, Boyadjian CH, Eggers S. An evaluation of auditory exostoses in 621 prehistoric human skulls from coastal Brazil. *Ear Nose Throat J* 2007; **86**: 468-472 [PMID: 17915669]
- Okumura MM, Boyadjian CH, Eggers S. Auditory exostoses as an aquatic activity marker: a comparison of coastal and inland skeletal remains from tropical and subtropical regions of Brazil. *Am J Phys Anthropol* 2007; **132**: 558-567 [PMID: 17243122 DOI: 10.1002/ajpa.20544]
- Arnay-de-la-Rosa M, Velasco-Vázquez J, González-Reimers E, Santolaria-Fernández F. Auricular exostoses among the prehistoric population of different islands of the Canary archipelago. *Ann Otol Rhinol Laryngol* 2001; **110**: 1080-1083 [PMID: 11713923 DOI: 10.1177/000348940111001117]
- Velasco-Vazquez J, Betancor-Rodriguez A, Arnay-De-La Rosa M, Gonzalez-Reimers E. Auricular exostoses in the prehistoric population of Gran Canaria. *Am J Phys Anthropol* 2000; **112**: 49-55 [PMID: 10766943 DOI: 10.1002/(SICI)1096-8644(200005)112:1<49::AID-AJPA6>3.0.CO;2-U]
- Blake CJ. On the occurrence of exostoses within the external auditory canal in prehistoric man. *Am J Otol* 1880; **2**: 81-91
- Whitaker SR, Cordier A, Kosjakov S, Charbonneau R. Treatment of external auditory canal exostoses. *Laryngoscope* 1998; **108**: 195-199 [PMID: 9473067 DOI: 10.1097/00005537-199802000-00007]
- Hetzler DG. Osteotome technique for removal of symptomatic ear canal exostoses. *Laryngoscope* 2007; **117**: 1-14 [PMID: 17220810 DOI: 10.1097/MLG.0b013e31802cbb12]
- Toynbee J. The diseases of the ear: their nature, diagnosis and treatment. Philadelphia: Blanchard and Lea, 1860: 136-147
- Cassells JP. On the Etiology of Aural Exostoses. *Br Med J* 1877; **2**: 845 [PMID: 20748713 DOI: 10.1136/bmj.2.885.845]
- Ramírez-Camacho R, Vicente J, García Berrocal JR, Ramón y Cajal S. Fibro-osseous lesions of the external auditory canal. *Laryngoscope* 1999; **109**: 488-491 [PMID: 10089981 DOI: 10.1097/00005537-199903000-00027]
- Kroon DF, Lawson ML, Derkay CS, Hoffmann K, McCook J. Surfer's ear: external auditory exostoses are more prevalent in cold water surfers. *Otolaryngol Head Neck Surg* 2002; **126**: 499-504 [PMID: 12075223 DOI: 10.1067/mhn.2002.124474]
- Mlynski R, Radeloff A, Brunner K, Hagen R. [Exostoses of the external auditory canal. Is the cold water hypothesis valid for patients in continental areas?]. *HNO* 2008; **56**: 410-416 [PMID: 17851642 DOI: 10.1007/s00106-007-1605-x]
- Chaplin JM, Stewart IA. The prevalence of exostoses in the external auditory meatus of surfers. *Clin Otolaryngol Allied Sci* 1998; **23**: 599-604

- 326-330 [PMID: 9762494 DOI: 10.1046/j.1365-2273.1998.00151.x]
- 26 **Ito M**, Ikeda M. Does cold water truly promote diver's ear? *Undersea Hyperb Med* 1998; **25**: 59-62 [PMID: 9566088]
- 27 **Timofeev I**, Notkina N, Smith IM. Exostoses of the external auditory canal: a long-term follow-up study of surgical treatment. *Clin Otolaryngol Allied Sci* 2004; **29**: 588-594 [PMID: 15533142 DOI: 10.1111/j.1365-2273.2004.00865.x]
- 28 **Sheard PW**, Doherty M. Prevalence and severity of external auditory exostoses in breath-hold divers. *J Laryngol Otol* 2008; **122**: 1162-1167 [PMID: 18346299 DOI: 10.1017/S0022215108001850]
- 29 **King JF**, Kinney AC, Iacobellis SF, Alexander TH, Harris JP, Torre P, Doherty JK, Nguyen QT. Laterality of exostosis in surfers due to evaporative cooling effect. *Otol Neurotol* 2010; **31**: 345-351 [PMID: 19806064 DOI: 10.1097/MAO.0b013e3181be6b2d]
- 30 **DiBartolomeo JR**. Exostoses of the external auditory canal. *Ann Otol Rhinol Laryngol Suppl* 1979; **88**: 2-20 [PMID: 118696]
- 31 **Hempel JM**, Forell S, Krause E, Müller J, Braun T. Surgery for outer ear canal exostoses and osteomata: focusing on patient benefit and health-related quality of life. *Otol Neurotol* 2012; **33**: 83-86 [PMID: 22143294 DOI: 10.1097/MAO.0b013e31823c91d0]
- 32 **Sanna M**, Russo A, Khrais T, Jain Y, Augurio AM. Canalplasty for severe external auditory meatus exostoses. *J Laryngol Otol* 2004; **118**: 607-611 [PMID: 15453935 DOI: 10.1258/0022215041917808]
- 33 **Altuna Mariezkurrena X**, Vea Orte JC, Camacho Arriaga JJ, Algaba Guimerá J. [Surgical treatment of exostosis in the external auditory canal]. *Acta Otorrinolaringol Esp* 2006; **57**: 257-261 [PMID: 16872100 DOI: 10.1016/S0001-6519(06)78704-0]
- 34 **Longridge NS**. Exostosis of the external auditory canal: a technical note. *Otol Neurotol* 2002; **23**: 260-261 [PMID: 11981378 DOI: 10.1097/00129492-200205000-00005]
- 35 **Stougaard M**, Tos M. Less radical drilling in surgery for exostoses of the external auditory canal. *Auris Nasus Larynx* 1999; **26**: 13-16 [PMID: 10077251 DOI: 10.1016/S0385-8146(98)00059-5]
- 36 **Adad B**, Rasgon BM, Ackerson L. Relationship of the facial nerve to the tympanic annulus: a direct anatomic examination. *Laryngoscope* 1999; **109**: 1189-1192 [PMID: 10443818 DOI: 10.1097/00005537-199908000-00002]
- 37 **Bordure PH**, Legent F, Sene JM, Runner O. Complications in surgery of the external auditory meatus exostoses. *JFORL* 1994; **43**: 336-340
- 38 **Frese KA**, Rudert H, Maune S. [Surgical treatment of auditory canal exostoses]. *Laryngorhinootologie* 1999; **78**: 538-543 [PMID: 10595337 DOI: 10.1055/s-1999-8754]
- 39 **Hurst WB**. A review of 64 operations for removal of exostoses of the external ear canal. *Aust J Oto-laryngol* 2001; **4**: 187-190
- 40 **Oostvogel CW**, Hüttenbrink KB. [Incidence of "recurrences" following surgical removal of ear canal exostoses]. *Laryngorhinootologie* 1992; **71**: 98-101 [PMID: 1571064 DOI: 10.1055/s-2007-997255]
- 41 **Portmann D**, Rodrigues E, Herman D, Lacher G, Bébéar JP, Portmann M. [Exostosis of the external auditory canal: clinical and therapeutic aspects]. *Rev Laryngol Otol Rhinol (Bord)* 1991; **112**: 231-235 [PMID: 1896697]
- 42 **Fisher EW**, McManus TC. Surgery for external auditory canal exostoses and osteomata. *J Laryngol Otol* 1994; **108**: 106-110 [PMID: 8163908 DOI: 10.1017/S0022215100126027]
- 43 **Reber M**, Mudry A. [Results and extraordinary complications of surgery for exostoses of the external auditory canal]. *HNO* 2000; **48**: 125-128 [PMID: 10663060 DOI: 10.1007/s001060050019]
- 44 **Sheehy JL**. Diffuse exostoses and osteomata of the external auditory canal: a report of 100 operations. *Otolaryngol Head Neck Surg* 1982; **90**: 337-342 [PMID: 6813807]
- 45 **Vasama JP**. Surgery for external auditory canal exostoses: a report of 182 operations. *ORL J Otorhinolaryngol Relat Spec* 2003; **65**: 189-192 [PMID: 14564090 DOI: 10.1159/000073112]
- 46 **von Blumenthal H**, Fisher EW, Adlam DM, Moffat DA. Surgical emphysema: a novel complication of aural exostosis surgery. *J Laryngol Otol* 1994; **108**: 490-491 [PMID: 8027648]
- 47 **Reddy VM**, Abdelrahman T, Lau A, Flanagan PM. Surfers' awareness of the preventability of 'surfer's ear' and use of water precautions. *J Laryngol Otol* 2011; **125**: 551-553 [PMID: 21310100 DOI: 10.1017/S0022215111000041]
- 48 **Srinivasan J**, Reddy VM, Flanagan PM. Audiological implications of earplugs used for the prevention of aural exostoses. *Eur Arch Otorhinolaryngol* 2012; **269**: 787-790 [PMID: 21822855 DOI: 10.1007/s00405-011-1730-8]

**P- Reviewer:** Abulezz T, Coskun A, Gouveris H, Unal M

**S- Editor:** Tian YL **L- Editor:** A **E- Editor:** Lu YJ





Published by **Baishideng Publishing Group Inc**

8226 Regency Drive, Pleasanton, CA 94588, USA

Telephone: +1-925-223-8242

Fax: +1-925-223-8243

E-mail: [bpgoffice@wjgnet.com](mailto:bpgoffice@wjgnet.com)

Help Desk: <http://www.wjgnet.com/esps/helpdesk.aspx>

<http://www.wjgnet.com>

