

World Journal of *Clinical Infectious Diseases*

World J Clin Infect Dis 2017 May 25; 7(2): 11-37





REVIEW

- 11 Management of periprosthetic infections

Vilchez-Cavazos F, Villarreal-Villarreal G, Peña-Martinez V, Acosta-Olivo C

ORIGINAL ARTICLE

Basic Study

- 21 Antioxidant enzyme profile of two clinical isolates of *Entamoeba histolytica* varying in sensitivity to antiamoebic drugs

Iyer LR, Banyal N, Naik S, Paul J

CASE REPORT

- 32 Disseminated cryptosporidiosis: Case report and literature review

Khalil S, Mirdha BR, Paul J, Panda A, Singh Y

Contents

World Journal of Clinical Infectious Diseases
Volume 7 Number 2 May 25, 2017

ABOUT COVER

Editorial Board Member of *World Journal of Clinical Infectious Diseases*, Maria A Moschovi, MD, PhD, Assistant Professor, Department of Pediatrics, University of Athens, Children's Oncology Unit, 11527 Goudi, Greece

AIM AND SCOPE

World Journal of Clinical Infectious Diseases (*World J Clin Infect Dis*, *WJCID*, online ISSN 2220-3176, DOI: 10.5495) is a peer-reviewed open access (OA) academic journal that aims to guide clinical practice and improve diagnostic and therapeutic skills of clinicians.

WJCID will focus on a broad spectrum of topics on infectious diseases that will cover epidemiology, immune-pathogenesis, genetic factors, host susceptibility to infection, vector control, novel approaches of treatment, molecular diagnostic and vaccines. It will provide a common stage to share the visions, new approaches, most advanced techniques, and to discuss research problems that will help everyone working in the field of various infections to exchange their views and to improve public health. *WJCID* will also focus on broad range of infections like opportunistic infections, zoonotic infections, tropical and neglected tropical diseases, emerging infections, *etc.* and following topics related to these issues: (1) Causative agents discussing various pathogens; (2) Vectors and Mode of transmission; (3) Host-pathogen interaction and immune-pathogenesis of the disease; (4) Epidemiology of the infection and vector control strategies; (5) Genetic factors covering both host and pathogen; (6) Molecular diagnostic techniques vaccines; and (7) Recent advances in cell tissue culture, lab techniques, *etc.* Various other related fields like medical microbiology, pharmacology of herbs, bioinformatics, *etc.* will be included.

We encourage authors to submit their manuscripts to *WJCID*. We will give priority to manuscripts that are supported by major national and international foundations and those that are of great basic and clinical significance.

INDEXING/ABSTRACTING

World Journal of Clinical Infectious Diseases is now indexed in China National Knowledge Infrastructure (CNKI).

FLYLEAF

I-III Editorial Board

EDITORS FOR THIS ISSUE

Responsible Assistant Editor: *Xiang Li*
Responsible Electronic Editor: *Dan Li*
Proofing Editor-in-Chief: *Lian-Sheng Ma*

Responsible Science Editor: *Fang-Fang Ji*
Proofing Editorial Office Director: *Yuan Qi*

NAME OF JOURNAL
World Journal of Clinical Infectious Diseases

ISSN
ISSN 2220-3176 (online)

LAUNCH DATE
December 30, 2011

FREQUENCY
Quarterly

EDITORS-IN-CHIEF
Shyam Sundar, MD, FRCP (London), FAMS, FNA Sc, FASc, FNA, Professor, Department of Medicine, Institute of Medical Sciences, Banaras Hindu University, Varanasi 221005, India

Lihua Xiao, DVM, PhD, Senior Scientist, Division of Foodborne, Waterborne, and Environmental Diseases, National Center for Emerging and Zoonotic Infectious Diseases, Centers for Disease Control and Prevention, Bldg 23, Rm 9-168, MS D66, 1600 Clifton Rd, Atlanta, GA 30333, United States

EDITORIAL BOARD MEMBERS
All editorial board members resources online at <http://www.wjcnct.com/2220-3176/editorialboard.htm>

EDITORIAL OFFICE
Fang-Fang Ji, Director
World Journal of Clinical Infectious Diseases
Baishideng Publishing Group Inc
7901 Stoneridge Drive, Suite 501,
Pleasanton, CA 94588, USA
Telephone: +1-925-2238242
Fax: +1-925-2238243
E-mail: editorialoffice@wjcnct.com
Help Desk: <http://www.wjcnct.com/helpdesk>
<http://www.wjcnct.com>

PUBLISHER
Baishideng Publishing Group Inc
7901 Stoneridge Drive, Suite 501,
Pleasanton, CA 94588, USA
Telephone: +1-925-2238242
Fax: +1-925-2238243
E-mail: bpgoffice@wjcnct.com
Help Desk: <http://www.wjcnct.com/helpdesk>
<http://www.wjcnct.com>

PUBLICATION DATE
May 25, 2017

COPYRIGHT
© 2017 Baishideng Publishing Group Inc. Articles published by this Open-Access journal are distributed under the terms of the Creative Commons Attribution Non-commercial License, which permits use, distribution, and reproduction in any medium, provided the original work is properly cited, the use is non commercial and is otherwise in compliance with the license.

SPECIAL STATEMENT
All articles published in journals owned by the Baishideng Publishing Group (BPG) represent the views and opinions of their authors, and not the views, opinions or policies of the BPG, except where otherwise explicitly indicated.

INSTRUCTIONS TO AUTHORS
<http://www.wjcnct.com/bpg/geninfo/204>

ONLINE SUBMISSION
<http://www.wjcnct.com>

Disseminated cryptosporidiosis: Case report and literature review

Shehla Khalil, Bijay R Mirdha, Jaishree Paul, Ashutosh Panda, Yogita Singh

Shehla Khalil, Bijay R Mirdha, Ashutosh Panda, Yogita Singh, Department of Microbiology, All India Institute of Medical Sciences, New Delhi 110029, India

Jaishree Paul, School of Life Sciences, Jawaharlal Nehru University, New Delhi 110067, India

Author contributions: Khalil S, Mirdha BR and Paul J designed the report; Khalil S, Panda A and Singh Y performed experiments; Khalil S, Panda A and Singh Y collected the patient's clinical data; Khalil S, Mirdha BR and Paul J analyzed the data and wrote the paper.

Supported by Council of Scientific and Industrial Research, Government of India.

Institutional review board statement: The study was approved by Institutional Ethics Committee of All India Institute of Medical Sciences, New Delhi, India.

Informed consent statement: All the participants were apprised about the study protocol. During the meetings, enrolled individuals (guardians/parents in case of children) were informed that their participation is voluntary and they have all the rights to withdraw from the study at any time without giving any reason.

Conflict-of-interest statement: Authors declare no conflict of interest.

Open-Access: This article is an open-access article which was selected by an in-house editor and fully peer-reviewed by external reviewers. It is distributed in accordance with the Creative Commons Attribution Non Commercial (CC BY-NC 4.0) license, which permits others to distribute, remix, adapt, build upon this work non-commercially, and license their derivative works on different terms, provided the original work is properly cited and the use is non-commercial. See: <http://creativecommons.org/licenses/by-nc/4.0/>

Manuscript source: Invited manuscript

Correspondence to: Dr. Bijay R Mirdha, MD, Professor, Department of Microbiology, All India Institute of Medical Sciences, Room No. 2078, Teaching Block, Ansari Nagar, New

Delhi 110029, India. mirdhabr2078@gmail.com
Telephone: +91-11-26594614

Received: April 18, 2016

Peer-review started: April 19, 2016

First decision: May 17, 2016

Revised: January 31, 2017

Accepted: February 20, 2017

Article in press: February 21, 2017

Published online: May 25, 2017

Abstract

Cryptosporidiosis, better known as an intestinal disease may disseminate to infect other sites including the respiratory tract. Little information however is available on respiratory cryptosporidiosis that may largely be due to lower frequency of respiratory cryptosporidiosis. Respiratory cryptosporidiosis has been majorly reported in immunocompromised individuals and children. Here we report a case of respiratory and intestinal cryptosporidiosis in a fifteen months old child with CD8+ deficiency. The patient in spite of treatment with Nitazoxanide and Azithromycin followed by Intravenous immunoglobulin and Bovine colostrum had a fatal outcome. The *Cryptosporidium* spp. isolate was subjected to molecular characterization. The *Cryptosporidium* spp. was identified both in stool specimen and Endotracheal aspirate (ETA). The blood sample was negative for *Cryptosporidium* spp. The *Cryptosporidium* spp. isolate from stool as well as ETA was identified as *Cryptosporidium hominis* (*C. hominis*) using Multiplex Allele Specific Polymerase Chain Reaction assay and was subtyped as IaA23G1R1 subtype using *gp60* gene polymerase chain reaction assay followed by sequencing.

Key words: Cryptosporidiosis; Disseminated disease; CD8+ deficiency; *Cryptosporidium hominis*; Subtyping

© **The Author(s) 2017.** Published by Baishideng Publishing Group Inc. All rights reserved.

Core tip: Disseminated cryptosporidiosis has rarely been reported because of the lower frequency as compared to intestinal cryptosporidiosis. Here we describe a case of patient who developed intestinal cryptosporidiosis followed by respiratory cryptosporidiosis. The *Cryptosporidium* isolate was identified as *Cryptosporidium hominis* subtype IaA23R2.

Khalil S, Mirdha BR, Paul J, Panda A, Singh Y. Disseminated cryptosporidiosis: Case report and literature review. *World J Clin Infect Dis* 2017; 7(2): 32-37 Available from: URL: <http://www.wjgnet.com/2220-3176/full/v7/i2/32.htm> DOI: <http://dx.doi.org/10.5495/wjcid.v7.i2.32>

INTRODUCTION

Cryptosporidium species are globally important enteric protozoan parasites with infection most commonly observed in immunocompromised individuals and children^[1]. It is mainly presented as diarrheal disease leading to significant morbidity and mortality in developing countries especially the rural areas^[2,3]. *Cryptosporidium* is one of the leading causes of infectious diarrhea in Indian children with prevalence ranging from 1.1%-18.9%^[4].

In immunocompetent individuals cryptosporidial diarrhea is transient self-limiting illness^[5]. Infections amongst immunocompromised individuals may also become extra-intestinal, spreading to other sites including the gall bladder, biliary tract, pancreas and pulmonary system^[5] and possible dissemination may occur through haematogenous route as post-mortem observation has shown the presence of *Cryptosporidium* spp. in the lumen of sub-mucosal colonic blood vessels^[6]. Respiratory cryptosporidiosis can occur in immunocompetent children suffering from cryptosporidial diarrhea with unexplained cough^[7]. In humans, it was first reported in 1984 in a patient with symptoms of chronic cough, fever, tachypnea, dyspnea with chest radiographs, findings consistent with interstitial pneumonia^[8]. Several other cases of respiratory cryptosporidiosis have been reported albeit the relative rarity of the disease. It is postulated that involvement of the respiratory tract may result in transmission of *Cryptosporidium* oocysts by aerosols and fomites.

Present report describes the detection, identification and subtyping of a *Cryptosporidium* spp. detected in the respiratory secretions [Endotracheal aspirate (ETA)] in a fifteen months old child with CD8+ immunodeficiency. Genus specific 18S rRNA gene polymerase chain reaction (PCR) assay was used to detect *Cryptosporidium* spp., where as Multiplex Allele Specific (MAS) PCR assay was used to identify the species of *Cryptosporidium*. The *gp60* gene was targeted for PCR assay followed by sequencing for subtyping.

CASE REPORT

A fifteen months old male child with the complaints of

fever and rapid breathing for at least two weeks along with cough and vomiting was admitted to the pediatric in-patient department of our tertiary care hospital. Patient had a history of recurrent fever since two and half months with each episode lasting for 10-15 d with an intermittent non-febrile stage of nearly a week. Child had decreased appetite and had lost approximately 500 g of body weight within three months. On admission the child was emaciated and severely malnourished. The patient was fourth child to a non consanguineous couple and was a follow up case of disseminated Cytomegalovirus (CMV) infection, periodic neutropenia, and Iron deficiency anaemia with CD8+ immunodeficiency. The CD4+ and CD8+ counts of child are given in Figure 1.

The patient's main clinical and laboratory findings on admission were as follows: Tachycardia (166/min), Tachypnea (52/min), fever (99 °C), severe anaemia (6.8 g/dL), neutropenia [Total Leukocyte Count (3600/μL); Neutrophils (40%)] and normal Platelet count ($5.25 \times 10^5/\mu\text{L}$). Serum biochemicals revealed normal kidney function [blood urea (15 mg/dL), Creatinine (0.2 mg/dL)]. Deranged Serum Glutamic Oxaloacetic Transaminase (99 IU) and elevated Alkaline phosphatase (565 IU) were observed. Serum immunoglobulin levels were normal (IgG-1137 mg/dL, IgA-108 mg/dL, IgM 102 mg/dL). Anthropometric measurements revealed Z-scores less than 3 [head circumference (41.5 cm); body weight (4.6 kg) and height (61 cm)] suggesting severe malnutrition. During present admission child was given prophylaxis of Fluconazole (25 mg once daily), Co-trimoxazole (20 mg/kg per day), lactose free diet as well as anti reflux measures. Urine and blood samples were sent for microbiological investigations and treatment for Severe Acute Malnutrition was started.

Urine culture was positive for *Escherichia coli* ($> 10^5$ CFU/mL) sensitive to Amikacin/Nitrofurantoin/Zosyn. Blood culture did not show growth of any pathogenic organism. Patient was started with combination of Injection (Inj) Piperacillin and Tazobactam 470 mg IV thrice a day along with Inj Amikacin 75 mg OD, Inj Vit K 2 mg, Syp cetirizine 2.5 mL (OD), Tab lanzol (Lansoprazole) 5 mg OD. In addition, Inj Magnesium sulphate 1 mL OD, Syp Zinc 2.5 mL OD, Folic acid tablets 5 mg OD then 1 mg OD, Syp Calcium carbonate and vitamin D3 2.5 mL OD, syp Atoz Multivitamin 2.5 mL OD along with the prophylaxis of Co-trimoxazole and Fluconazole.

On third day of admission patient was afebrile, there was no vomiting and was accepting the oral feed well, however, he subsequently developed diarrhea with a frequency of up to 20 stools in a day. Domperidone and Cinnarizine combination syrup at a dosage of 1 mL thrice daily was started and urine and blood samples were again sent for microbiological investigations along with the stool sample. All the clinical samples after all the microbiological investigations were negative for any pathogens except the stool sample that showed high load of *Cryptosporidium* spp. Oocysts, i.e., upto 30 oocysts present per high power field. Syrup Nitazoxanide (NTZ) at a dose of 100

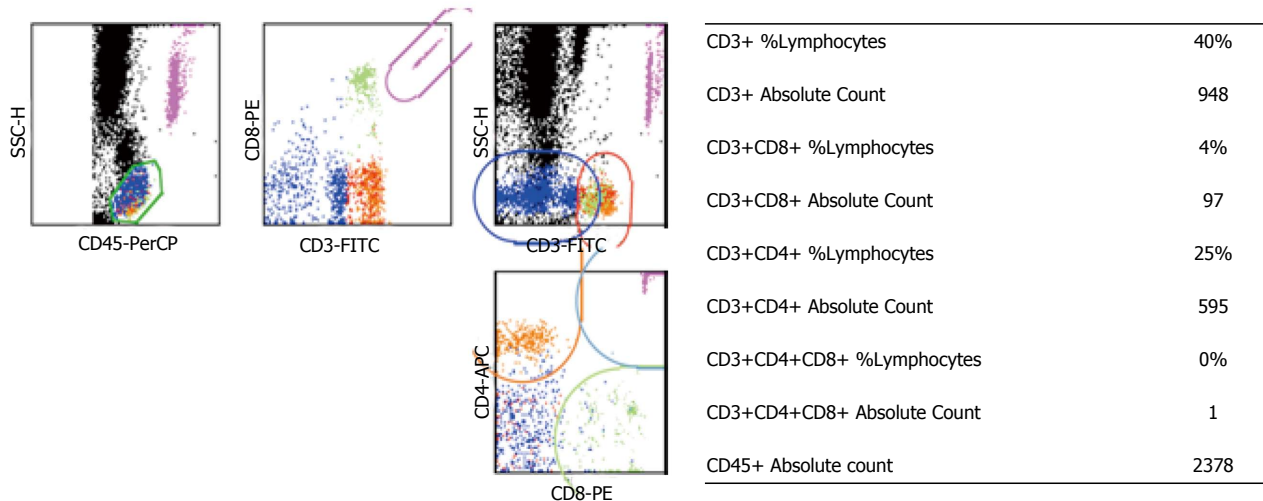


Figure 1 Immunological profile of the patient with CD8+ deficiency.

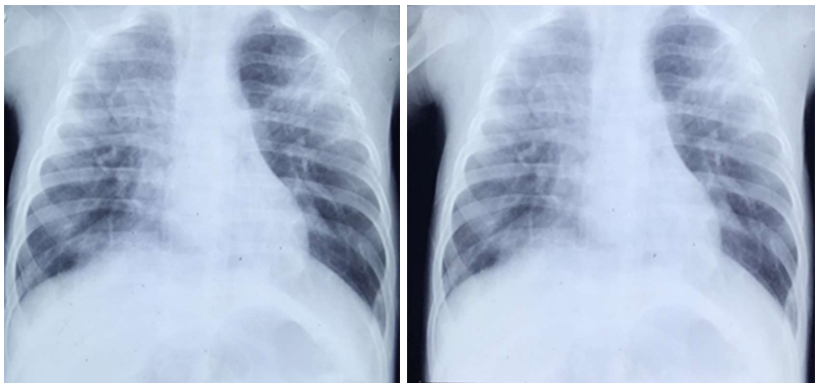


Figure 2 Chest X-ray of CD8+ deficient child showing bilateral infiltrates.

mg/5 mL twice daily and Azithromycin (AZ) at a dose of 45 mg/20 mL in normal Saline was given intravenously. However, diarrhea did not improve even after a week of continuous NTZ and AZ treatment. To circumvent this unresolving cryptosporidial diarrhea, Intravenous Immunoglobulin and Bovine Colostrum were started along with NTZ and AZ. After 24–48 h of this treatment there was no improvement in diarrheal symptoms and child began to develop respiratory distress with tachypnea and cool peripheries and further worsening. Chest X-ray showed bilateral infiltrates (Figure 2). Several causal possibilities of bilateral pneumonia were considered that included reactivation of CMV infection, *Pneumocystis jirovecii* Pneumonia, respiratory cryptosporidiosis as well as fungal sepsis. Amphotericin B was added for treatment of fungal sepsis and Co-trimoxazole dose was increased. On tenth day child had further worsening with increased heart rate (128/min), respiratory rate of 100/min along with increased frequency of voluminous diarrhea. Child was intubated and ventilated. Stool, endotracheal aspirate and blood samples were further sent for investigation with a special reference to detect presence of *Cryptosporidium* spp. oocysts. Child showed no signs of improvement and died. The primary reason leading to

death was ascribed to disseminated cryptosporidiosis, with antecedent causes including immunodeficiency, periodic neutropenia and disseminated CMV infection.

The samples of stool, blood and ETA received in our laboratory were subjected to molecular analyses using primers given in Table 1. DNA was extracted from stool sample using QIAmp DNA stool minikit (Qiagen, United States) and blood and ETA using QIAmp Easy Blood and Tissue minikit (Qiagen, United States). The DNA from these three samples was subjected to diagnostic PCR assay using genus specific *18S rRNA* gene primers. For identification of species Multiplex Allele Specific PCR assay targeting *DHFR* gene was used. For subtyping *GP60* gene was targeted. Gel based extraction of the PCR products was performed as per the manufacturer's instructions using MinElute gel extraction kit (Qiagen, United States). Sequencing for the study isolates was performed in both forward and reverse direction on ABI 3500xL Genetic Analyzer from Chromous Biotech. Consensus sequences were pairwise aligned using Clustal W and were manually refined using the BioEdit program version 7.0.4.

A band size of 435 bp was obtained from DNA extracted both from stool sample as well as ETA showing

Table 1 Primers used in the study

Gene (Ref.)	Primers	Amplicon size
18S rRNA ^[9]	CPB-DIAGF: 5'-AGCTCGTAGTTGGATTCTG-3' CPB-DIAGR: 5'-TAAGGTGCTGAAGGAGTAAGG-3'	435 bp
MAS PCR ^[10]	CINF: 5'-GTGGGGATTAACTTGATT 3' CINR: 5'-GGTATTCTGGGAAATAAGT3'	575 bp 357 bp
	1R: 5'-GCTGGAGGAAATAACGACAATTA3' 2R: 5'-TGTCGTTAATTCCTATTCCTCTA3'	190 bp
GP60 ^[11]	F1: 5'-ATAGTCICCGCTGTATTC-3' R1: 5'-GGAAGGAACGATGTATCT-3' F2: 5'-TCCGCTGTATTCTCAGCC-3' R2: 5'-GCAGAGGAACCAAGCATC-3'	800-850 bp

the presence of *Cryptosporidium* spp. oocysts in both the samples. However, there was no amplification of cryptosporidial DNA from blood sample. MAS-PCR assay showed amplification of DNA bands suggestive of *Cryptosporidium hominis* (*C. hominis*). The desired band was obtained using *gp60* gene based PCR assay and the amplified products were sequenced. The sequences of *gp60* gene from both the sample identified them as Ia subtype family and IaA23G1R1 subtype. The sequence was submitted to genbank under Accession number KU169227.

DISCUSSION

Cryptosporidium spp. affects mainly the small intestines but infections of hepatic ducts, lungs and conjunctiva has also been reported^[12,13]. However, a few case reports of respiratory cryptosporidiosis in human immunodeficiency virus (HIV)/AIDS cases are available^[13]. Respiratory cryptosporidiosis is mostly presented as cough, dyspnea, low fever and abnormal chest X-ray with interstitial pneumopathy^[14], with an unknown pathogenesis^[15].

Respiratory route of *Cryptosporidium* transmission was suggested as results of epidemiological studies in children presumed to be immunocompetent. In a study from Switzerland, children with cryptosporidial diarrhea were more likely to have respiratory symptoms compared to those who had other infections, suggesting that respiratory infection may be common but transient in healthy individuals^[16]. In a study from rural Brazil and Bangladesh, 50% and 33% of children with intestinal cryptosporidiosis had unexplained respiratory symptoms, respectively^[17,18]. In a report from Gaza, 50% of children with cryptosporidial diarrhea and 10% of children without cryptosporidial diarrhea had respiratory symptoms and were also shedding *Cryptosporidium* in feces^[19]. These findings led to the speculation that the respiratory system may serve as a viable alternative for *Cryptosporidium* propagation, transmission, and diagnosis, with or without apparent respiratory symptoms. Kumar *et al.*^[20], (2016) reported disseminated cryptosporidiosis in a 35 year old immunocompetent patient in India which was successfully treated with nitazoxanide.

In addition human respiratory cryptosporidiosis has been

observed in patients with compromised cellular immunity as well as in individuals with induced immunosuppression; hence an association between cryptosporidiosis and depleted CD4+ T-cell count was established^[6,15,21]. Disseminated cryptosporidiosis was reported in a child with nephrotic syndrome receiving immunosuppression^[15].

In the present case, intestinal cryptosporidiosis was followed by respiratory cryptosporidiosis. Earlier studies have shown disseminated cryptosporidiosis originating from the intestinal tract infection. Subsequently cases of respiratory cryptosporidiosis lacking evidence of primary gastrointestinal involvement suggest the possibility of respiratory transmission of cryptosporidiosis^[13,14]. The pathogenesis of *Cryptosporidium* spp. lung infection is still unclear. Infection can result from the inhalation of oocysts after vomiting or the hematogenous spread of the oocysts. Although intestinal *Cryptosporidium* spp. organisms are not usually invasive, oocysts have been found inside macrophages, which can have defective phagocyte killing ability^[22]. In fact, *Cryptosporidium* spp. organisms can multiply in macrophages *in vitro*^[23], suggesting that extraintestinal parasites might spread *via* circulating phagocytes. Regardless of the route of infection patients with disseminated cryptosporidiosis experience fulminant disease, fail to respond to existing therapies and have fatal outcome.

Human health risk is often compounded because there is only one Food and Drug Administration approved therapeutic agent, *i.e.*, NTZ. It reduces the duration of diarrhea and oocyst shedding in both immunocompetent and immunocompromised^[24,25]. The patient was initially treated with nitazoxanide, however no improvement was seen in diarrhea and was later started with the combination therapy. Higher doses and longer duration of therapy may be needed for HIV-positive malnourished children to derive benefit from the drug^[25]. Spiramycin, Azithromycin and Immunoglobulins have not been efficacious in controlled trials in patients with AIDS^[26].

Isolate of *Cryptosporidium* spp. in our study was identified as *Cryptosporidium hominis* (*C. hominis*). Mercado *et al.*^[14], (2007) had isolated *C. hominis* from the respiratory secretions of an HIV sero-positive patient. No reports are available on the subtypes of *Cryptosporidium* spp. causing disseminated infection and/or infection of

the tissues other than intestinal^[11].

Substantial information about which species and subtypes of *Cryptosporidium* infect humans and the pathogenic patterns of each of these is needed. *C. hominis* have the capacity to adapt to diverse environments and infect gastrointestinal as well as respiratory tract. This report supports the role of *C. hominis* as a human pathogen and the need to evaluate the importance of respiratory cryptosporidiosis as a disease in children as well as in immunocompromised host.

COMMENTS

Case characteristics

Fever, vomiting, cough and rapid breathing since 15 d and subsequent diarrhea.

Clinical diagnosis

Interstitial Pneumonia.

Differential diagnosis

Cytomegalovirus reactivation, *Pneumocystis* pneumonia, Fungal sepsis.

Laboratory diagnosis

Severe anaemia, neutropenia. Normal kidney function with deranged Serum Glutamate Oxaloacetic Transaminase and Alkaline phosphatase. Urine culture was positive for *E. coli*. Stool samples and Endotracheal aspirate were positive for *Cryptosporidium* species using PCR.

Imaging diagnosis

Bilateral infiltrates were seen on chest X-ray.

Treatment

Syp Nitazoxanide and Azithromycin along with Intravenous Ig and Bovine Colostrum were given to treat cryptosporidiosis.

Related reports

Mercado *et al* (2007) had isolated *C. hominis* from the respiratory secretions of an human immunodeficiency virus sero-positive patient. No reports are available on the subtypes of *Cryptosporidium* spp. causing disseminated infection and/or infection of the tissues other than intestinal.

Experience and lessons

Dissemination of cryptosporidiosis should be considered in patients with compromised cellular immunity as well as in individuals with induced immunosuppression.

Peer-review

It is a well written case report describing a 15 mo old child with CD8+ immunodeficiency, suffering from disseminated Cryptosporidiosis leading to death.

REFERENCES

- 1 Fayer R, Morgan U, Upton SJ. Epidemiology of *Cryptosporidium*: transmission, detection and identification. *Int J Parasitol* 2000; **30**: 1305-1322 [PMID: 11113257 DOI: 10.1016/S0020-7519(00)00135-1]
- 2 Mak JW. Important zoonotic intestinal protozoan parasites in Asia. *Trop Biomed* 2004; **21**: 39-50 [PMID: 16493397 DOI: 10.1007/s00436-008-1125-y]
- 3 Huang DB, White AC. An updated review on *Cryptosporidium* and *Giardia*. *Gastroenterol Clin North Am* 2006; **35**: 291-314, viii [PMID: 16880067 DOI: 10.1016/j.gtc.2006.03.006]
- 4 Ajampur SS, Sankaran P, Kang G. *Cryptosporidium* species in

- HIV-infected individuals in India: an overview. *Natl Med J India* 2008; **21**: 178-184 [PMID: 19267039 DOI: 10.1097/00001648-199807001-00115]
- 5 Hunter PR, Nichols G. Epidemiology and clinical features of *Cryptosporidium* infection in immunocompromised patients. *Clin Microbiol Rev* 2002; **15**: 145-154 [PMID: 11781272 DOI: 10.1128/cmr.15.1.145-154.2002]
- 6 Gentile G, Baldassarri L, Caprioli A, Donelli G, Venditti M, Avvisati G, Martino P. Colonic vascular invasion as a possible route of extraintestinal cryptosporidiosis. *Am J Med* 1987; **82**: 574-575 [PMID: 3826119 DOI: 10.1016/0002-9343(87)90474-8]
- 7 Miao YM, Awad-El-Kariem FM, Franzen C, Ellis DS, Müller A, Counihan HM, Hayes PJ, Gazzard BG. Eradication of cryptosporidia and microsporidia following successful antiretroviral therapy. *J Acquir Immune Defic Syndr* 2000; **25**: 124-129 [PMID: 11103042 DOI: 10.1097/00126334-200010010-00006]
- 8 Brady EM, Margolis ML, Korzenowski OM. Pulmonary cryptosporidiosis in acquired immune deficiency syndrome. *JAMA* 1984; **252**: 89-90 [PMID: 6427491 DOI: 10.1001/jama.252.1.89]
- 9 Johnson DW, Pieniazek NJ, Griffin DW, Misener L, Rose JB. Development of a PCR protocol for sensitive detection of *Cryptosporidium* oocysts in water samples. *Appl Environ Microbiol* 1995; **61**: 3849-3855 [PMID: 8526496 DOI: 10.1007/978-94-011-4369-1_6]
- 10 Gile M, Warhurst DC, Webster KA, West DM, Marshall JA. A multiplex allele specific polymerase chain reaction (MAS-PCR) on the dihydrofolate reductase gene for the detection of *Cryptosporidium parvum* genotypes 1 and 2. *Parasitology* 2002; **125**: 35-44 [PMID: 12166518 DOI: 10.1017/S0031182002001786]
- 11 Alves M, Xiao L, Sulaiman I, Lal AA, Matos O, Antunes F. Subgenotype analysis of *Cryptosporidium* isolates from humans, cattle, and zoo ruminants in Portugal. *J Clin Microbiol* 2003; **41**: 2744-2747 [PMID: 12791920 DOI: 10.1128/jcm.41.6.2744-2747.2003]
- 12 Uppal B, Kashyap B, Bhalla P. Enteric Pathogens in HIV/AIDS from a Tertiary Care Hospital. *Indian J Community Med* 2009; **34**: 237-242 [PMID: 20049303 DOI: 10.4103/0970-0218.55291]
- 13 Palmieri F, Cicalini S, Froio N, Rizzi EB, Goletti D, Festa A, Macri G, Petrosillo N. Pulmonary cryptosporidiosis in an AIDS patient: successful treatment with paromomycin plus azithromycin. *Int J STD AIDS* 2005; **16**: 515-517 [PMID: 16004637 DOI: 10.1258/0956462054308332]
- 14 Mercado R, Buck GA, Manque PA, Ozaki LS. *Cryptosporidium hominis* infection of the human respiratory tract. *Emerg Infect Dis* 2007; **13**: 462-464 [PMID: 17552101 DOI: 10.3201/eid1303.060394]
- 15 Shrikhande SN, Chande CA, Shegokar VR, Powar RM. Pulmonary cryptosporidiosis in HIV negative, immunocompromised host. *Indian J Pathol Microbiol* 2009; **52**: 267-268 [PMID: 19332937 DOI: 10.4103/0377-4929.48942]
- 16 Egger M, Mäusezahl D, Odermatt P, Marti HP, Tanner M. Symptoms and transmission of intestinal cryptosporidiosis. *Arch Dis Child* 1990; **65**: 445-447 [PMID: 2346340]
- 17 Weikel CS, Johnston LI, De Sousa MA, Guerrant RL. Cryptosporidiosis in northeastern Brazil: association with sporadic diarrhea. *J Infect Dis* 1985; **151**: 963-965 [PMID: 3989327]
- 18 Shahid NS, Rahman AS, Anderson BC, Mata LJ, Sanyal SC. Cryptosporidiosis in Bangladesh. *Br Med J (Clin Res Ed)* 1985; **290**: 114-115 [PMID: 3917704]
- 19 Sallon S, Deckelbaum RJ, Schmid II, Harlap S, Baras M, Spira DT. *Cryptosporidium*, malnutrition, and chronic diarrhea in children. *Am J Dis Child* 1988; **142**: 312-315 [PMID: 3344720]
- 20 Kumar H, Singh VB, Meena BL, Agrawal J, Beniwal S, Swami T. Pulmonary cryptosporidiosis in an immunocompetent host treated successfully with nitazoxanide. *Lung India* 2016; **33**: 69-71 [PMID: 26933311 DOI: 10.4103/0970-2113.173085]
- 21 Pozio E, Rezza G, Boschini A, Pezzotti P, Tamburrini A, Rossi P, Di Fine M, Smacchia C, Schiesari A, Gattei E, Zucconi R, Ballarini P. Clinical cryptosporidiosis and human immunodeficiency virus (HIV)-induced immunosuppression: findings from a longitudinal

- study of HIV-positive and HIV-negative former injection drug users. *J Infect Dis* 1997; **176**: 969-975 [PMID: 9333155 DOI: 10.1086/516498]
- 22 **Ma P**, Villanueva TG, Kaufman D, Gillooley JF. Respiratory cryptosporidiosis in the acquired immune deficiency syndrome. Use of modified cold Kinyoun and Hemacolor stains for rapid diagnoses. *JAMA* 1984; **252**: 1298-1301 [PMID: 6206247]
- 23 **Villacorta-Martinez de Maturana I**, Ares-Mazás ME, Duran-Oreiro D, Lorenzo-Lorenzo MJ. Efficacy of activated sludge in removing *Cryptosporidium parvum* oocysts from sewage. *Appl Environ Microbiol* 1992; **58**: 3514-3516 [PMID: 1482177 DOI: 10.1111/j.1365-2672.1995.tb01670]
- 24 **Rossignol JF**, Hidalgo H, Feregrino M, Higuera F, Gomez WH, Romero JL, Padierna J, Geyne A, Ayers MS. A double-'blind' placebo-controlled study of nitazoxanide in the treatment of cryptosporidial diarrhoea in AIDS patients in Mexico. *Trans R Soc Trop Med Hyg* 1998; **92**: 663-666 [PMID: 10326116 DOI: 10.1016/s0035-9203(98)90804-5]
- 25 **Amadi B**, Mwiya M, Musuku J, Watuka A, Sianongo S, Ayoub A, Kelly P. Effect of nitazoxanide on morbidity and mortality in Zambian children with cryptosporidiosis: a randomised controlled trial. *Lancet* 2002; **360**: 1375-1380 [PMID: 12423984 DOI: 10.1016/s0140-6736(02)11401-2]
- 26 **Cabada MM**, White AC. Treatment of cryptosporidiosis: do we know what we think we know? *Curr Opin Infect Dis* 2010; **23**: 494-499 [PMID: 20689422 DOI: 10.1097/qco.0b013e32833de052]

P- Reviewer: Gonzalez-Granado LI, Moschovi MA, Nagata T, Pourshafie MR

S- Editor: Ji FF **L- Editor:** A **E- Editor:** Li D





Published by **Baishideng Publishing Group Inc**
7901 Stoneridge Drive, Suite 501, Pleasanton, CA 94588, USA
Telephone: +1-925-223-8242
Fax: +1-925-223-8243
E-mail: bpgoffice@wjgnet.com
Help Desk: <http://www.f6publishing.com/helpdesk>
<http://www.wjgnet.com>

