



Analysis and monitoring of drug therapy in a patient with peptic ulcer complicated by infection: A case report

Yan-Ping Gou, Yue Huang, Li Chen, Wei Zheng, Yun-Hua Zheng

Specialty type: Medicine, research and experimental

Provenance and peer review: Unsolicited article; Externally peer reviewed.

Peer-review model: Single blind

Peer-review report's scientific quality classification

Grade A (Excellent): 0
Grade B (Very good): 0
Grade C (Good): C
Grade D (Fair): 0
Grade E (Poor): 0

P-Reviewer: Moshref L, Saudi Arabia

Received: December 21, 2023

Peer-review started: December 21, 2023

First decision: January 10, 2024

Revised: February 7, 2024

Accepted: February 21, 2024

Article in press: February 21, 2024

Published online: March 16, 2024



Yan-Ping Gou, The Second People's Hospital of Meishan City & Renshou County People's Hospital, Meishan 620500, Sichuan Province, China

Yue Huang, Li Chen, Yun-Hua Zheng, Quality Evaluation and Medical Record Management, The Affiliated Hospital of Southwest Jiaotong University & The Third People's Hospital of Chengdu, Chengdu 610000, Sichuan Province, China

Wei Zheng, Patriotic Health Campaign, Qionglai City Health Bureau, Chengdu 610000, Sichuan Province, China

Corresponding author: Yun-Hua Zheng, PharmD, Assistant Lecturer, Pharmacist, Research Scientist, Senior Statistician, Quality Evaluation and Medical Record Management, The Affiliated Hospital of Southwest Jiaotong University & The Third People's Hospital of Chengdu, No. 82 Qinglong Street, Qingyang District, Chengdu 610000, Sichuan Province, China. 13125549713@163.com

Abstract

BACKGROUND

The role of primary-level medical pharmacists in medical institutions in China is limited; therefore, it is necessary to explore the role of pharmacists in the process of drug treatment.

CASE SUMMARY

A Chinese pharmacist participated in the complete treatment of a patient with a duodenal ulcer. The rationale for drug treatment was evaluated, and adjustments were made to the antacid and anti-infective regimen, as well as the dose and frequency of administration. Body temperature, routine blood examination, and adverse drug reactions were strictly monitored. During treatment, the pharmacist recommended anti-infective therapy with ampicillin-sulbactam, which effectively controlled the infection. Additionally, the pharmacist suggested changing famotidine to lansoprazole for acid suppression and gastroprotective treatment, combined with Chinese patent medicine such as Kangfuxin Liquid. This is the first case report of a pharmacist in primary-level medical institutions adjusting drug use for patients with duodenal ulcer and pulmonary infection.

CONCLUSION

A pharmacist participated in the treatment process, provided individualized medication adjustment, and achieved good clinical results.

Key Words: Ampicillin–sulbactam; Famotidine; Lansoprazole; Kangfuxin Liquid; Chinese pharmacist; Case report

©The Author(s) 2024. Published by Baishideng Publishing Group Inc. All rights reserved.

Core Tip: Duodenal ulcer is a common digestive disease in clinical practice. The main treatment methods are to heal the ulcer, prevent recurrence and avoid complications. For the first time, we report a case of pharmacist in a medical institution participating in the treatment process of a patient with duodenal ulcer and pulmonary infection. It is worth noting that the drug combined with Kangfuxin Liquid had a good effect, which reminds us that individualized treatment is necessary and combination with Kangfuxin Liquid is a valuable research direction.

Citation: Gou YP, Huang Y, Chen L, Zheng W, Zheng YH. Analysis and monitoring of drug therapy in a patient with peptic ulcer complicated by infection: A case report. *World J Clin Cases* 2024; 12(8): 1530-1535

URL: <https://www.wjgnet.com/2307-8960/full/v12/i8/1530.htm>

DOI: <https://dx.doi.org/10.12998/wjcc.v12.i8.1530>

INTRODUCTION

Peptic ulcer is a heterogeneous disease caused by an imbalance between invasive factors and mucosal defense and repair in the gastric and duodenal mucosa, often resulting from gastric acid, drugs, *Helicobacter pylori* (*H. pylori*), and other etiological factors. It is most commonly found in the stomach and duodenum[1]. Duodenal ulcer accounts for approximately 70% of cases, gastric ulcer for approximately 25%, and combination of the two for approximately 5%[2]. Currently, the main treatment strategies for duodenal ulcer include eliminating the cause, relieving symptoms, promoting ulcer healing, preventing recurrence, and avoiding complications[3]. The primary prevention strategies involve preventing *H. pylori* infection, and reducing the use of harmful drugs and other risk factors in order to decrease the occurrence or recurrence of ulcers[4].

Ampicillin–sulbactam is composed of sulbactam, a β -lactam inhibitor, and ampicillin, a β -lactam antibiotic, which can protect β -lactam antibiotics (ampicillin) from enzymatic destruction and enhance their antibacterial action[5]. The incidence of adverse reactions to this drug is < 10%, and there are occasional gastrointestinal symptoms such as diarrhea and nausea. In addition, it may cause liver adverse reactions such as elevated aminotransferase[6]. Lansoprazole is a proton pump inhibitor (PPI) in the class of benzimidazole compounds. The activated metabolites of lansoprazole under the influence of gastric acid can specifically inhibit the H^+/K^+ -ATPase system in gastric parietal cells and block gastric acid secretion[7]. It is currently the drug of choice for the treatment of acid secretion. Common adverse reactions to lansoprazole include constipation, diarrhea, thirst, and abdominal distension[8]. Other adverse reactions include leukopenia, abnormal liver function, and allergic reactions. Studies have shown that older patients taking lansoprazole have a higher risk of adverse reactions[9]. Kangfuxin Liquid is often used to treat improper diet, emotional disorders, drug damage, spleen and stomach hormone deficiency, and promotes blood circulation and strengthens the spleen and kidneys by acting on the disease[10]. PPIs combined with Kangfuxin Liquid have a good therapeutic effect on ulcers accompanied by bleeding, and improve stomach pain[11]. Moreover, Kangfuxin Liquid in combination with PPIs for the treatment of gastric ulcer improved overall gastroscopy efficiency and effectiveness, and reduced adverse events and recurrence rates[12].

In this report, we describe a case in which a pharmacist advised a clinician to change his medication regimen and present the results of a 17 d analysis of medication use monitoring. After the intervention drug use program, the patient's nocturnal abdominal pain was significantly relieved and his condition was controlled. We also review for the first time similar case reports of Kangfuxin Liquid combined with PPIs.

CASE PRESENTATION

Chief complaints

A 68-year-old male patient was admitted to the Gastroenterology Department of our hospital on December 23, 2022, due to abdominal pain, abdominal distension, low back pain, and poor appetite accompanied by cough and phlegm for 1 wk.

History of present illness

The patient had a history of gastric disease for > 30 years. A duodenal ulcer was observed by gastroscopy.

History of past illness

One week before admission, the patient had cough and sputum, which was slightly viscous and not easy to spit out; pain in the upper abdomen, especially under the xiphoid process; obvious abdominal distension immediately after eating,

accompanied by bilateral lumbago and discomfort, fever, poor appetite, and significantly reduced food intake. After infusion treatment in the Emergency Department of our hospital, fever symptoms were relieved, but cough, sputum, and other symptoms did not improve significantly. He was admitted to the outpatient department of our hospital with abdominal pain waiting for diagnosis.

Personal and family history

The patient had a 40-year history of smoking and smoked about 20 cigarettes a day. He had a history of drinking, 500 g a day. He denied any family history.

Physical examination

The patient's temperature was 36.3 °C, heart rate was 79 bpm, respiratory rate was 21 breaths/min, blood pressure was 137/86 mmHg, and weight was 60 kg. Tenderness in the upper abdomen, especially under xiphoid process. Other measures were normal.

Laboratory examinations

Routine blood examination showed that the absolute leukocyte count was $5.36 \times 10^9/L$, the percentage of neutrophilic granulocytes was 76.7%↑, the percentage of lymphocytes was 15.3%↓, and the absolute lymphocyte count was $0.82 \times 10^9/L$ ↓. Hepatic and renal function tests showed that alanine aminotransferase was 26 IU/L, aspartate aminotransferase was 25 IU/L, total bilirubin was 14.0 μmol/L, and creatinine was 75.3 μmol/L. ^{13}C breath test was positive.

Imaging examinations

Contrast-enhanced computed tomography (CT) showed signs of double emphysema, bulla formation in both lungs, scattered inflammatory changes, and interstitial changes in both lungs.

FINAL DIAGNOSIS

The patient was discharged with a diagnosis of duodenal ulcer, chronic gastritis, pulmonary infection, acute upper respiratory tract infection, chronic bronchitis with emphysema, old rib fracture, liver cyst, and *H. pylori* infection.

TREATMENT

After admission, the relevant examinations were completed, and the patient received routine and primary care. On December 24, 2022, the patient was given a famotidine injection for acid suppression and to protect the gastric mucosa, papaverine hydrochloride injection, rotundine sulfate injection to relieve symptoms and pain, amino acid and fat milk nutritional support. The main therapeutic drugs are shown in Table 1.

OUTCOME AND FOLLOW-UP

On December 25, 2022, chest CT indicated pulmonary infection, procalcitonin (PCT) was 0.45 ng/mL, C-reactive protein was 4.2 mg/L, and the patient was given anti-infective therapy with ampicillin-sulbactam sodium injection. Sputum culture identified normal flora, routine stool examination was normal, and stool occult blood was weakly positive. The patient underwent painless gastroscopy on January 1, 2023, and the examination report showed a duodenal bulb ulcer (A1). On the same day, the patient was treated by oral administration of sucralfate suspensoid gel and zinc acexamate capsules. Famotidine was changed to lansoprazole for acid preservation. The patient's condition improved and he was discharged from hospital on January 8, 2023. Blood biochemistry and infection-related indicators at admission are shown in Table 2.

DISCUSSION

The patient had repeated symptoms of abdominal pain, abdominal distension, and lower back pain. According to the guidelines for peptic ulcer[13], middle and upper abdominal pain and acid reflux are typical symptoms of peptic ulcer disease. Treatment norms point out that for the treatment of duodenal ulcer, mainly by speeding up ulcer healing, further preventing complications and recurrence, the commonly used therapeutic drugs are mucosal protective agents, drugs to inhibit gastric acid secretion, and gastrointestinal motility drugs. PPIs are the preferred drugs, and the decrease in gastric acidity is directly related to ulcer healing. Comparison of the efficacy of the two drugs has been seen in several clinical trials. Some studies have compared the efficacy of famotidine and lansoprazole for treatment of peptic ulcer and their impact on the oxidative stress index of patients. Lansoprazole is faster-acting and more effective than famotidine for treatment of gastric ulcer[14]. Nema and Kato[15] analyzed the efficacy of PPIs and H2 receptor antagonists for treatment of gastroduodenal ulcers with sustained low-dose aspirin. In the PPI-treated group, 23 cases (88.5%) healed and three did

Table 1 Main therapeutic drugs during hospitalization

Date of administration	Name of drug	Dosage
December 23, 2022-January 3, 2023	Famotidine Injection	20 mg bid ivgtt
January 4, 2023-January 8, 2023	Lansoprazole for Injection	30 mg bid ivgtt
December 25, 2022-December 31, 2022	Ampicillin-Sulbactam	1.5 mg q8h ivgtt
December 23, 2022-January 8, 2023	Papaverine Hydrochloride Injection	60 mg qd ivgtt
December 23, 2022-January 3, 2023	Rotundine Sulfate Injection	60 mg qd im
December 23, 2022-January 8, 2023	Rotundine Sulfate Injection	1 g bid po
December 23, 2022-January 8, 2023	Kangfuxin Liquid	10 mL tid po
December 23, 2022-January 8, 2023	Zinc Acexamate Capsules	0.3 g qd po

Table 2 Blood biochemistry and infection-related indicators at admission (day 1)

Project name	Result
WBC (/μL)	5.36
TBIL (μmol/L)	14.0
AST (IU/L)	25
ALT (IU/L)	26
NEUT (%)	76.7
Na (mmol/L)	141
K (mmol/L)	4.6
CR (μmol/L)	75.3
PCT (μmol/L)	0.45
CRP (mg/L)	4.2

WBC: White blood cell; TBIL: Total bilirubin; AST: Aspartate aminotransferase; ALT: Alanine aminotransferase; NEUT: Neutrophilic granulocyte; K: Serum potassium; Na: Serum sodium; CR: Creatinine; PCT: Procalcitonin; CRP: C-reactive protein.

not. In the H₂ receptor antagonist group, 22 cases (84.6%) healed and four did not[15]. Therefore, after ward rounds, the pharmacist found that the patient had repeated symptoms. Considering that H₂ receptor antagonists have inferior acid inhibition than PPIs, and that PPIs can reduce adverse drug reactions[16], she suggested that the clinician should replace famotidine with lansoprazole 30 mg bid, which was adopted by the physician.

It is worth noting that the therapeutic effect of Kangfuxin Liquid combined with PPI is significantly better than that of PPI monotherapy, and combination of Kangfuxin Liquid and quadruple therapy is more beneficial in reducing inflammation in patients with *H. pylori*-positive gastric ulcer[12]. A study on the mechanism of action showed that this may be attributed to the enhancement of neovascularization, inhibition of inflammation, and enhancement of growth factor expression[17]. The pharmacist believed that lansoprazole combined with Kangfuxin Liquid was effective in treating ulcers accompanied by bleeding, and the combination could effectively reduce gastric pain. Therefore, she suggested that the clinician add Kangfuxin Liquid to the order when the patient was admitted to hospital, and the clinician adopted the suggestion.

According to the Guidelines to Manage Community-Acquired Pneumonia, it is crucial for a patient with community-acquired pneumonia to choose the appropriate treatment site, empirical anti-infective drugs, and adjuvant therapy according to the disease severity[18]. The patient had a risk score of 1 for confusion, urea, respiratory rate, blood pressure, age 65[19]. On December 25, 2022, the sputum culture results showed normal flora, routine stool examination was normal, and stool occult blood was weakly positive. Therefore, the pharmacist recommended that the clinician use ampicillin-sulbactam.

The adverse effects of lansoprazole include constipation, diarrhea, thirst and bloating. Therefore, after the pharmacist recommended that the clinicians changed the drug on January 4, 2023, continuous medication monitoring was conducted, during which no lansoprazole-related adverse reactions were reported, and the formulation of the protocol was considered safe and effective.

Antibiotic-associated diarrhea is most commonly caused by lincomycin, azithromycin, broad-spectrum penicillins (especially ampicillin), and second- and third-generation cephalosporins[20]. In addition, for this time-dependent antibiotic, administration according to its half-life can achieve better efficacy[21]. Therefore, in order to avoid causing

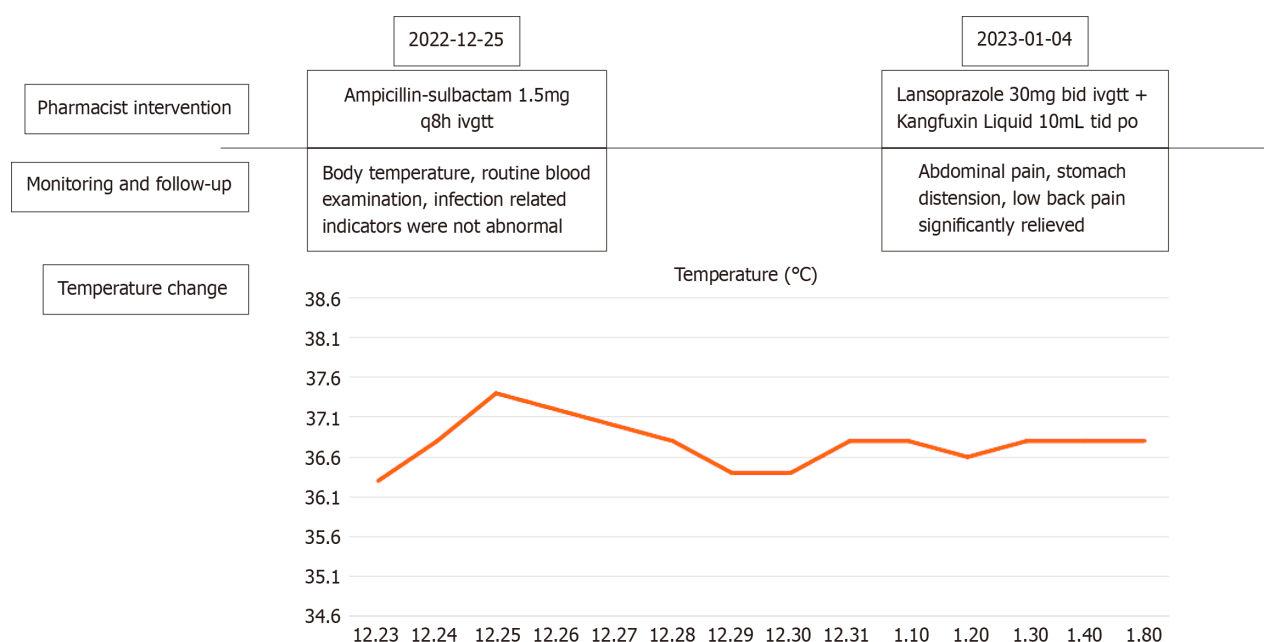


Figure 1 Pharmacist intervention and follow-up results.

diarrhea and achieve better efficacy, the dose and administration frequency of 1.5 mg q8h were selected. Pharmacists also monitored drug-related adverse reactions. Our drug monitoring showed that the patient did not have a fever during hospitalization, and there were no abnormalities in routine blood examination, PCT, and other infection indicators. The intervention and follow-up results of the pharmacist are shown in Figure 1.

It should be noted that the fecal occult blood test on day 1 of admission was weakly positive, with hemoglobin of 155 g/L and platelet count $132 \times 10^9/L$. However, after the replacement of lansoprazole and combined treatment with Kangfuxin Liquid, the fecal occult blood test on day 14 of admission was negative. Our study proves that Kangfuxin Liquid is an effective PPI combination drug and deserves further study.

There were some limitations to this study. Due to the limited medical capacity of primary medical institutions, the adjustment of drug dose based on genetic test results was not applicable in this case. In the future, we should strengthen pharmaceutical management and supervision so as to benefit more patients.

CONCLUSION

To the best of our knowledge, this is the first case report that demonstrates the important role of pharmacists in making therapeutic decisions. The experience of pharmacists can be an important aid in determining the dose of antibiotics and the use of traditional Chinese medicine such as Kangfuxin Liquid. More importantly, our case provides a clinical basis for further research on Kangfuxin Liquid combined with other drugs.

FOOTNOTES

Author contributions: Gou YP was the patient's pharmacist; Huang Y reviewed the literature and contributed to manuscript drafting; Zheng YH, Chen L and Zheng W collected the information from the patient; Zheng YH was responsible for revision of the manuscript; Gou YP and Zheng YH reviewed and edited the paper. All authors have read and approved the final version of the manuscript.

Informed consent statement: The informed consent was obtained from the patient for the entire treatment process and publication of this paper.

Conflict-of-interest statement: The authors declare no conflict of interest.

CARE Checklist (2016) statement: The authors have read the CARE Checklist (2016), and the manuscript was prepared and revised according to the CARE Checklist (2016).

Open-Access: This article is an open-access article that was selected by an in-house editor and fully peer-reviewed by external reviewers. It is distributed in accordance with the Creative Commons Attribution NonCommercial (CC BY-NC 4.0) license, which permits others to distribute, remix, adapt, build upon this work non-commercially, and license their derivative works on different terms, provided the original work is properly cited and the use is non-commercial. See: <https://creativecommons.org/licenses/by-nc/4.0/>

Country/Territory of origin: China

ORCID number: Yun-Hua Zheng 0009-0007-6398-4907.

S-Editor: Zhang L

L-Editor: A

P-Editor: Zhao YQ

REFERENCES

- Jacob TV, Doshi GM. New promising routes in peptic ulcers: Toll-like receptors and semaphorins. *Endocr Metab Immune Disord Drug Targets* 2023 [PMID: 37605412 DOI: 10.2174/1871530323666230821102718]
- Duggan JM, Duggan AE. The possible causes of the pandemic of peptic ulcer in the late 19th and early 20th century. *Med J Aust* 2006; **185**: 667-669 [PMID: 17181518 DOI: 10.5694/j.1326-5377.2006.tb00747.x]
- Alsahafi M, Mosli M, Alkhowaiter S, Donnellan F. Decision-Utility Analysis of Empiric Treatment Versus Test and Treat Strategies for Helicobacter pylori in Patients With Duodenal Ulcer. *Value Health Reg Issues* 2024; **39**: 1-5 [PMID: 37967489 DOI: 10.1016/j.vhri.2023.08.007]
- Talebi Bezzmin Abadi A. Helicobacter pylori treatment: New perspectives using current experience. *J Glob Antimicrob Resist* 2017; **8**: 123-130 [PMID: 28131855 DOI: 10.1016/j.jgar.2016.11.008]
- Fong ZV, McMillan MT, Marchegiani G, Sahora K, Malleo G, De Pastena M, Loehrer AP, Lee GC, Ferrone CR, Chang DC, Hutter MM, Drebin JA, Bassi C, Lillemoe KD, Vollmer CM, Fernández-Del Castillo C. Discordance Between Perioperative Antibiotic Prophylaxis and Wound Infection Cultures in Patients Undergoing Pancreaticoduodenectomy. *JAMA Surg* 2016; **151**: 432-439 [PMID: 26720272 DOI: 10.1001/jamasurg.2015.4510]
- LiverTox: Clinical and Research Information on Drug-Induced Liver Injury [Internet]. Bethesda (MD): National Institute of Diabetes and Digestive and Kidney Diseases; 2012– [PMID: 31643176]
- Garnett WR. Lansoprazole: a proton pump inhibitor. *Ann Pharmacother* 1996; **30**: 1425-1436 [PMID: 8968456 DOI: 10.1177/106002809603001212]
- Debsharma S, Pramanik S, Bindu S, Mazumder S, Das T, Saha D, De R, Nag S, Banerjee C, Siddiqui AA, Ghosh Z, Bandyopadhyay U. Honokiol, an inducer of sirtuin-3, protects against non-steroidal anti-inflammatory drug-induced gastric mucosal mitochondrial pathology, apoptosis and inflammatory tissue injury. *Br J Pharmacol* 2023; **180**: 2317-2340 [PMID: 36914615 DOI: 10.1111/bph.16070]
- Dipasquale V, Cicala G, Laganà F, Cutroneo P, Trimarchi G, Spina E, Romano C. Spontaneous reporting of adverse reactions related to proton pump inhibitors. *Dig Liver Dis* 2023; **55**: 595-600 [PMID: 36404233 DOI: 10.1016/j.dld.2022.10.024]
- Sun H, Yang C, Liu X, Liang J, Geng H. Effectiveness of Negative Pressure Wound Therapy of Diabetic Foot Ulcers Using Periplaneta Americana (Kangfuxin Liquid) Irrigation. *Int J Low Extrem Wounds* 2023; 15347346231176917 [PMID: 37203153 DOI: 10.1177/15347346231176917]
- Lin M, Zhang S, Zhang M, Shi J, Zhang C, Luo R, You J, Sun J, Zhang J, Gao F. Therapeutic efficacy and safety of Kangfuxin in combination with rabeprazole in the treatment of peptic ulcer: A systematic review and meta-analysis. *Medicine (Baltimore)* 2020; **99**: e23103 [PMID: 33235070 DOI: 10.1097/MD.00000000000023103]
- Zou JB, Zhang XF, Shi YJ, Tai J, Wang Y, Liang YL, Wang F, Cheng JX, Wang J, Guo DY. Therapeutic Efficacy of Kangfuxin Liquid Combined with PPIs in Gastric Ulcer. *Evid Based Complement Alternat Med* 2019; **2019**: 1324969 [PMID: 31662770 DOI: 10.1155/2019/1324969]
- Kamada T, Satoh K, Itoh T, Ito M, Iwamoto J, Okimoto T, Kanno T, Sugimoto M, Chiba T, Nomura S, Mieda M, Hiraishi H, Yoshino J, Takagi A, Watanabe S, Koike K. Evidence-based clinical practice guidelines for peptic ulcer disease 2020. *J Gastroenterol* 2021; **56**: 303-322 [PMID: 33620586 DOI: 10.1007/s00535-021-01769-0]
- Okai T, Sawabu N, Songür Y, Motoo Y, Watanabe H. Comparison of lansoprazole and famotidine for gastric ulcer by endoscopic ultrasonography: a preliminary trial. *J Clin Gastroenterol* 1995; **20** Suppl 2: S32-S35 [PMID: 7594335 DOI: 10.1097/00004836-199506002-00009]
- Nema H, Kato M. Comparative study of therapeutic effects of PPI and H2RA on ulcers during continuous aspirin therapy. *World J Gastroenterol* 2010; **16**: 5342-5346 [PMID: 21072898 DOI: 10.3748/wjg.v16.i42.5342]
- Begg M, Tarhuni M, N Fotso M, Gonzalez NA, Sanivarapu RR, Osman U, Latha Kumar A, Sadagopan A, Mahmoud A, Khan S. Comparing the Safety and Efficacy of Proton Pump Inhibitors and Histamine-2 Receptor Antagonists in the Management of Patients With Peptic Ulcer Disease: A Systematic Review. *Cureus* 2023; **15**: e44341 [PMID: 37779765 DOI: 10.7759/cureus.44341]
- Tian M, Dong J, Wang Z, Lu S, Geng F. The effects and mechanism of Kangfuxin on improving healing quality and preventing recurrence of gastric ulcer. *Biomed Pharmacother* 2021; **138**: 111513 [PMID: 33761454 DOI: 10.1016/j.biopha.2021.111513]
- Wunderink RG. Guidelines to Manage Community-Acquired Pneumonia. *Clin Chest Med* 2018; **39**: 723-731 [PMID: 30390744 DOI: 10.1016/j.ccm.2018.07.006]
- Patel S. Calculated decisions: CURB-65 score for pneumonia severity. *Emerg Med Pract* 2021; **23**: CD1-CD2 [PMID: 33529515]
- Mekonnen SA, Merenstein D, Fraser CM, Marco ML. Molecular mechanisms of probiotic prevention of antibiotic-associated diarrhea. *Curr Opin Biotechnol* 2020; **61**: 226-234 [PMID: 32087535 DOI: 10.1016/j.copbio.2020.01.005]
- Owens RC Jr, Ambrose PG. Antimicrobial stewardship and the role of pharmacokinetics-pharmacodynamics in the modern antibiotic era. *Diagn Microbiol Infect Dis* 2007; **57**: 77S-83S [PMID: 17292579 DOI: 10.1016/j.diagmicrobio.2006.12.012]



Published by **Baishideng Publishing Group Inc**
7041 Koll Center Parkway, Suite 160, Pleasanton, CA 94566, USA

Telephone: +1-925-3991568

E-mail: office@baishideng.com

Help Desk: <https://www.f6publishing.com/helpdesk>

<https://www.wjgnet.com>

