

Dear editor, Dear reviewers:

Thanks for the time and effort that you have put into reviewing the previous version of the manuscript. Your suggestions have enabled us to improve our work. We have studied comments carefully and have made correction which we hope meet with approval.

Revised portion are marked in red in the manuscript with traces of revision.

Appended to this letter is our point-by-point response to the comments raised by the reviewers. The comments are reproduced and our responses are given directly afterward in a different color (Our response and modification made in manuscript are highlighted in blue and red, respectively).

We would also like to thank you for allowing us to resubmit a revised copy of the manuscript. We hope that the revised manuscript will be accepted for publication in the *World J Clin Cases*.

Sincerely,

Zhu-shu Guo,

The Second Xiangya Hospital, Central South University

139 Renmin Middle Road, Furong District

Changsha, Hunan 410011, China

GuoZhuShu@csu.edu.cn

Reviewer #1(Comments to the Author):

1. It is an interesting case report and is well written.

Thank you for your comments!

2. There is no histopathological picture of the diagnosis of adenocarcinoma.

Thank you for your suggestion, we have added p histopathological picture of the diagnosis of adenocarcinoma. Our changes to this section are in lines 510 to 511 of the revised manuscript without traces of revision.

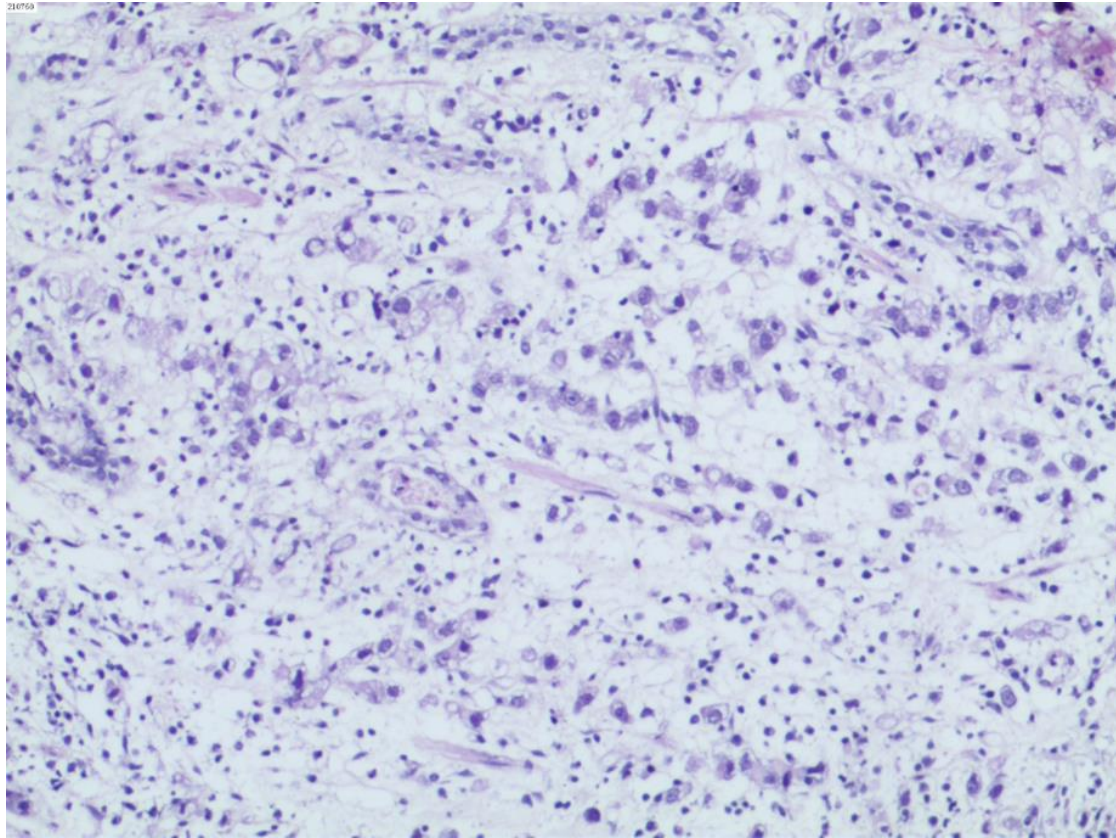


Figure1. Biopsy of the gastric body.

3. Also, there is no image of abdominal CT preoperatively.

Thank you for your valuable advice, we have added the patient's abdominal CT images. Our changes to this section are in lines 515 to 522 of the revised manuscript without traces of revision.

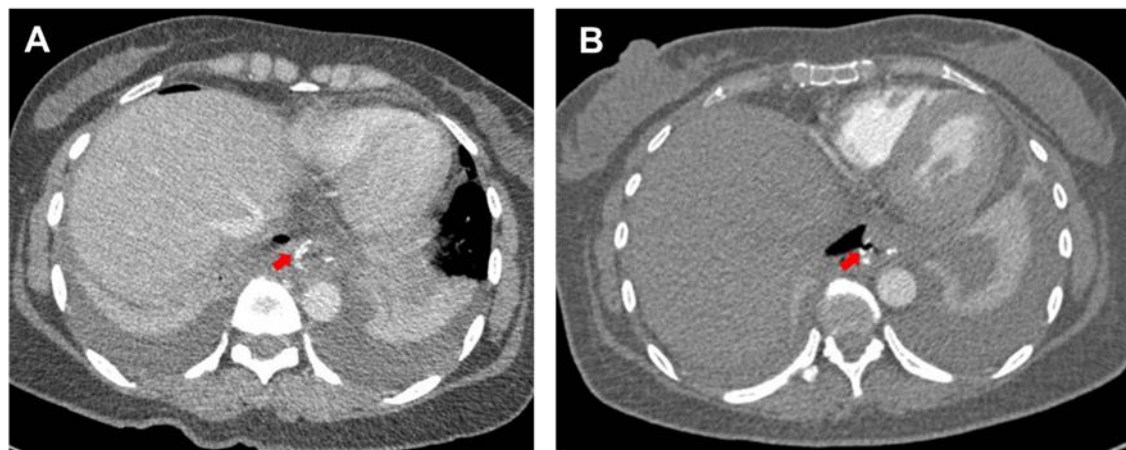


Figure3. Postoperative anastomosis CT image. (A) CT on postoperative day 6 showed changes consistent with postoperative gastrointestinal tract. The red arrow showed the position of the anastomosis. (B) CT on postoperative day 13 showed anastomosis at the lower end of the oesophagus. Red arrow showed the cystic air-containing cavity in the right mediastinum appears to be connected to the anastomosis and the possibility of an anastomotic fistula is

considered.

4. What is the definition of persistent fever after surgery? Does it mean the patient developed fever since postoperative hours, day 1? And how much did it reach? Was it in the same period of the leukocytosis at day1 postop?

Thank you for your valuable questions, and we apologize for not describing this definition clearly. We have added a description of this in the manuscript. Here, persistent postoperative fever means that the patient has had a fever since the first day after surgery and it does not come down to a normal body temperature on its own. The patient reported in this case had a temperature of 38°C on the postoperative day 1 and it coincided with the period of leukocytosis. Our changes to this section are in lines 141 to 144 of the revised manuscript without traces of revision.

She developed a persistent fever after surgery, which meant she started having a fever on t postoperative day 1 and was unable to reduce it to a normal temperature on her own.

5. No need to repeat sputum culture in (microbiological identification of the causative agent) since it was mentioned in (laboratory examination)

Thank you very much for your suggestion, we have reduced the relevant content of the manuscript. Our changes to this section are in lines 161 to 162 and 184 to 186 of the revised manuscript without traces of revision.

Ciprofloxacin was applied on postoperative day 15, after which the infection indicators dropped to normal.

Sputum culture was performed on postoperative day 9. The *Ralstonia mannitolilytica* infection was reported on postoperative day 14, which was sensitive for Ciprofloxacin.

6. In follow-up part, wen was meglumine diatrizoate esophagogram was done? Is it the same day 23 to clamp the anastomotic leak? If it is the same, just place it as one paragraph because it is a bit confusing

Thank you very much for your suggestion, we have adjusted the content of the relevant paragraphs. Our changes to this section are in lines 190 to 199 of the revised manuscript without traces of revision.

TREATMENT

After ciprofloxacin had controlled the infection, endoscopic metal clip therapy was performed on postoperative day 23 to clamp the anastomotic fistula. And meglumine diatrizoate esophagogram showed no anastomotic fistula (Figure4B).

OUTCOME AND FOLLOW-UP

After the application of antibiotics and clamping of the anastomotic fistula, the infection of the patient was gradually controlled on the postoperative day 24. Since then, anastomotic fistulas related signs did not appear again.

7. Mention (figure2) in the text. It is only mentioned as legend Thank you
We are grateful for your suggestions, we have added some images and confirmed that they are mentioned in the appropriate paragraphs.