

## Retrospective Study

# Feasibility of full-spectrum endoscopy: Korea's first full-spectrum endoscopy colonoscopic trial

Jeong-Yeop Song, Youn Hee Cho, Mi A Kim, Jeong-Ae Kim, Chun Tek Lee, Moon Sung Lee

Jeong-Yeop Song, Youn Hee Cho, Mi A Kim, Jeong-Ae Kim, Chun Tek Lee, Division of Gastroenterology, Department of Internal Medicine, LCT Hospital, Suwon 442-130, South Korea

Moon Sung Lee, Division of Gastroenterology, Department of Internal Medicine, SoonChunHyang University Bucheon Hospital, Bucheon 420-767, South Korea

**Author contributions:** Song JY, Cho YH, Kim MA, Kim JA, Lee CT and Lee MS contributed equally to this work; Song JY made study conception and design and editing; Cho YH, Kim MA, Kim JA and Lee CT collected the data; Lee MS analyzed and interpreted the data; all authors have read and approved the final version to be published.

**Institutional review board statement:** This study was reviewed and approved by IRB committee of LeeChunTek (LCT) Hospital.

**Informed consent statement:** All study participants, or their legal guardian were not required to give informed consent to this retrospective study because the analysis used anonymous clinical data that were obtained retrospectively after each patient agreed to examination.

**Conflict-of-interest statement:** Authors have no financial relationships to disclosure.

**Data sharing statement:** No additional data are available.

**Open-Access:** This article is an open-access article which was selected by an in-house editor and fully peer-reviewed by external reviewers. It is distributed in accordance with the Creative Commons Attribution Non Commercial (CC BY-NC 4.0) license, which permits others to distribute, remix, adapt, build upon this work non-commercially, and license their derivative works on different terms, provided the original work is properly cited and the use is non-commercial. See: <http://creativecommons.org/licenses/by-nc/4.0/>

**Correspondence to:** Moon Sung Lee, MD, Professor, Division of Gastroenterology, Department of Internal Medicine, SoonChunHyang University Bucheon Hospital, 1174 Jung-Dong, Wonmi-Ku, Bucheon 420-767,

South Korea. [tommymd@daum.net](mailto:tommymd@daum.net)  
Telephone: +82-32-6215094  
Fax: +82-32-6215080

Received: September 17, 2015  
Peer-review started: September 17, 2015  
First decision: October 14, 2015  
Revised: October 20, 2015  
Accepted: November 19, 2015  
Article in press: November 19, 2015  
Published online: February 28, 2016

## Abstract

**AIM:** To evaluate the full-spectrum endoscopy (FUSE) colonoscopy system as the first report on the utility thereof in a Korean population.

**METHODS:** We explored the efficacy of the FUSE colonoscopy in a retrospective, single-center feasibility study performed between February 1 and July 20, 2015. A total of 262 subjects (age range: 22-80) underwent the FUSE colonoscopy for colorectal cancer screening, polyp surveillance, or diagnostic evaluation. The cecal intubation success rate, the polyp detection rate (PDR), the adenoma detection rate (ADR), and the diverticulum detection rate (DDR), were calculated. Also, the success rates of therapeutic interventions were evaluated with biopsy confirmation.

**RESULTS:** All patients completed the study and the success rates of cecal and terminal ileal intubation were 100% with the FUSE colonoscope; we found 313 polyps in 142 patients and 173 adenomas in 95. The overall PDR, ADR and DDR were 54.2%, 36.3%, and 25.2%, respectively, and were higher in males, and increased with age. The endoscopists and nurses involved considered that the full-spectrum colonoscope improved navigation and orientation within the colon.

No colonoscopy was aborted because of colonoscope malfunction.

**CONCLUSION:** The FUSE colonoscopy yielded a higher PDR, ADR, DDR than did traditional colonoscopy, without therapeutic failure or complications, showing feasible, effective, and safe in this first Korean trial.

**Key words:** Colonoscopy; Colonoscopes; Feasibility studies; Colonic polyps

© **The Author(s)** 2016. Published by Baishideng Publishing Group Inc. All rights reserved.

**Core tip:** Although many efforts have been made to improve visualization and reduce blind spots in the colonic mucosa, about 10% of the colonic surface remains unobserved during traditional standard forward-view (SFV) colonoscopy. In contrast to the maximum field of view (170°) of SFV colonoscopes, the full-spectrum endoscopy (FUSE) colonoscopy platform affords the endoscopist a high-resolution, 330° “full spectrum” view of the colorectal mucosa. In this first Korean trial, the FUSE colonoscopy yielded a higher polyp, adenoma, diverticulum detection rate without therapeutic failure or complications, to be feasible, effective, and safe.

Song JY, Cho YH, Kim MA, Kim JA, Lee CT, Lee MS. Feasibility of full-spectrum endoscopy: Korea’s first full-spectrum endoscopy colonoscopic trial. *World J Gastroenterol* 2016; 22(8): 2621-2629 Available from: URL: <http://www.wjgnet.com/1007-9327/full/v22/i8/2621.htm> DOI: <http://dx.doi.org/10.3748/wjg.v22.i8.2621>

## INTRODUCTION

Although it is widely accepted that screening colonoscopy is most effective for early detection of colorectal cancer (CRC), CRC remains a leading cause of cancer-related mortality worldwide<sup>[1]</sup>. Simple colonoscopic polypectomy can prevent CRC and reduce mortality. However, several studies have highlighted the miss rates of adenomatous polyps during colonoscopy<sup>[2,3]</sup>. The overall adenoma miss rate is approximately 20% during traditional colonoscopy, ranging from 6%-48%<sup>[4-6]</sup>. As such missed adenomas can trigger interval CRC, improving adenoma detection during colonoscopy is important to enhance screening efficiency. Other than inadequate colon preparation, incomplete colonoscopy (thus not examining the cecum), short withdrawal times (less than 6 min), and patient-related factors, the principal problem is that it is relatively difficult to visualize polyps on the proximal sides of haustral folds, in the internal curves of flexures, and in the area around the ileocecal valve<sup>[6]</sup>. These anatomical sites tend to be hidden from the traditional, standard forward-view (SFV) colonoscope

(with a 140°-170° angle of view) and are often only accessible if a skillful endoscopist manipulates the colonoscope, flattening folds and straightening flexures, with prolonged retroflexion of the colonoscope *per se*<sup>[7-9]</sup>. Such maneuvers may not always be performed, or may be performed suboptimally, because they require additional time, more skill, and are associated with (limited) risks to the patient. However, today, most endoscopists still employ colonoscopic technology that has been used for the past 40 years<sup>[10]</sup>. In recent times, efforts have been made to enhance the imaging and endoscopic technologies used during colonoscopy beyond employment of standard-definition white-light (SDWL) and the traditional SFV angle<sup>[4,11-13]</sup>. Of these, the recently developed Full-Spectrum Endoscopy® (FUSE®, EndoChoice, Alpharetta, GA, United States) colonoscope is a new platform with imagers not only on the forward tip of the colonoscope, but also on both sides of that tip<sup>[14,15]</sup>. The three imagers cover a 330° angle of view displayed on three side-by-side video monitors, affording a comprehensive picture of the entire colonic lumen, including the traditional blind spots at flexures or the proximal edges of mucosal folds. In an *in vitro* model of the colon, a significant increase in polyp detection was evident when the FUSE colonoscope was used; 85.7% versus 52.9% using a conventional scope ( $P < 0.0001$ ). The FUSE colonoscope was particularly valuable to detect polyps in flexures behind folds<sup>[14]</sup>. Further, in the first-ever pilot feasibility study in 50 subjects, the cecal intubation rate was 100% and the device was ranked highly by both patients and endoscopists; no adverse event was noted<sup>[15]</sup>. In a randomized, multicenter, back-to-back study on same-day FUSE and SFV colonoscopies in 185 patients, the adenoma miss rate with the FUSE colonoscopy was considerably less than that with SFV (7.5% vs 40.8%,  $P < 0.001$ )<sup>[16]</sup>. We thus sought to establish the feasibility, safety, and utility of the FUSE colonoscopy in terms of polyp detection rate (PDR), adenoma detection rate (ADR), and diverticulum detection rate (DDR), in Korea. We were the first to use the FUSE system in Korea; this is thus the first report in a Korean population.

## MATERIALS AND METHODS

### Study design and patients

This was a retrospective, single-center feasibility study conducted between February 1 and July 20, 2015, at Division of Gastroenterology, Department of Internal Medicine at LCT Hospital, Suwon, Korea. Gastroenterologists experienced in colonoscopy evaluated the feasibility, utility, and safety of the FUSE colonoscope in 272 patients referred for colorectal cancer screening, polyp surveillance, or diagnostic evaluation. We excluded individuals with a history of colonic resection ( $n = 2$ ), inflammatory bowel disease ( $n = 1$ ), polyposis syndrome or a suspected colonic stricture caused by prior abdominal surgery ( $n = 5$ ),

suspected acute diverticulitis ( $n = 2$ )<sup>[15]</sup>. Neither of the participating endoscopists had prior clinical experience of the FUSE colonoscopy system.

### **FUSE colonoscopy system**

The FUSE colonoscopy platform features a video colonoscope and a processor. The colonoscope is a standard adult device (168 cm in working length, outer diameter 12.8 mm) that is flexible, re-usable, re-processable, and appropriate for repeated clinical use (for diagnostic visualization and/or therapeutic interventions). The device has a high-resolution 330° field of view with maintenance of all standard colonoscopic capabilities. The technical features are identical to those of current SFV colonoscopes in terms of maneuverability [including full tip deflection (up or down 180° and left or right 160°)]; working channel diameter (3.8 mm); the availability of air or CO<sub>2</sub> insufflation options; a suction feature; and forward water jet irrigation. The FUSE colonoscopy features three imagers and light-emitting diode groups positioned at the front and on the sides of the distal tip of the colonoscope. Figure 1 shows the fields of view of the SFV and the FUSE gastroscopes and colonoscopes displayed on two or three contiguous video monitors. The left, center, and right monitors show colonic images transmitted from the left-facing, forward-facing, and right-facing lenses, respectively (Figure 2)<sup>[14-16]</sup>.

### **Colonoscopy**

All subjects underwent standard colonoscopy preparation using either a polyethylene-glycol-based solution or a sodium picosulfate preparation; these solutions are commercially available and are approved for use in colonoscopy preparation in Korea. The choice of preparative method was at the discretion of the endoscopist. The mode of conscious sedation was chosen by the endoscopist and featured the use of either midazolam or propofol, or a combination thereof. All colonoscopy examinations were performed under white light only; no electronic imaging technology was employed. The intention was to attain and intubate the cecum. Intubation of the terminal ileum was optional, thus at the discretion of the endoscopist. The endoscopists were instructed to use their usual withdrawal techniques but to spend a minimum of 6 min withdrawing and examining the colon<sup>[13]</sup>. Insertion, withdrawal, and total procedure times were derived from times printed on colonoscopic images, all of which were recorded. A polyp or diverticulum located proximal to the splenic flexure was a priori defined as being in the right colon; all more distal polyps or diverticula were regarded as being located in the left colon<sup>[4,5]</sup>. Retroflexion of the colonoscope within the rectum was performed in each subject. Biopsies and/or polypectomies, and even endoscopic submucosal dissections (ESDs), were performed as needed. All

polyps detected were completely removed and sent to the pathology department. Histological results were reported to the attending gastroenterologist and the study coordinator. Polyps were categorized as adenomatous, hyperplastic, or other. If a polyp was adenomatous on the basis of pathology, the adenoma subtype was also recorded (*i.e.*, tubular, tubulovillous, villous, or serrated). We also histologically analyzed low- and high-grade dysplasias within adenomas<sup>[15,16]</sup>.

### **Outcomes**

The primary endpoint was cecal intubation. Additional endpoints included the extent of success of diagnostic and therapeutic interventions, and the number of adverse events. We calculated the PDR, ADR, and DDR. We defined an adenoma 10 mm or greater in diameter as advanced if villous histology, or high-grade dysplasia, or cancer was evident<sup>[2]</sup>.

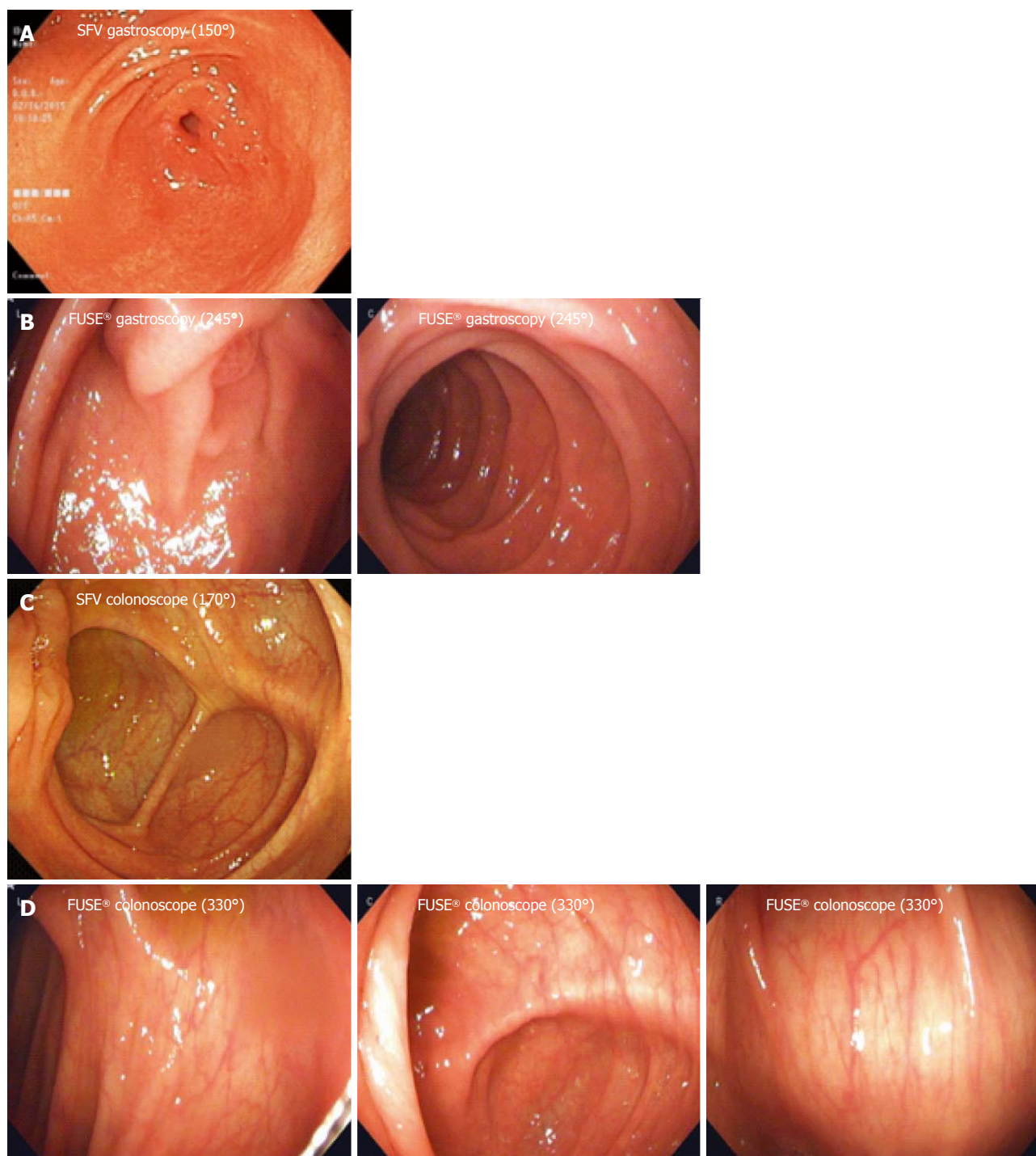
### **Statistical analysis**

All variables and derived parameters were compared using descriptive statistics. The data summary tables include sample sizes; means; standard deviations; and the medians, minima, and maxima of the means of continuous variables. The paired *t*-test was used to explore the significance of differences between the two view modes in terms of the numbers and percentages of polyps, adenomas, and diverticula detected. We calculated 95%CI where appropriate, using the binomial proportion for one-way tables. All tests were two-tailed, and a *P* value  $\leq 0.05$  was considered to indicate statistical significance. All data were analyzed using SAS version 9.1 for Windows (SAS Institute, Cary, NC, United States).

## **RESULTS**

The success rates of cecal and terminal ileal intubation were both 100% using the FUSE colonoscope. A total of 262 subjects completed the study and we found 313 polyps in 142, 173 adenomas in 95, and 26 cases of colitis. The gender ratio (M:F) was 50.4:49.6 and the mean age was  $48.9 \pm 11.8$  (range 22-80) years. The overall PDR, ADR, and DDR were 54.2%, 36.3%, and 25.2%, respectively (Table 1). The right side: left side ratios (in %) of all polyps, adenomas, and diverticula in colon, and colonoscopy procedure times were also shown at Table 1. In patients over 41 years of age, the PDR, ADR, and DDR were 60%, 42%, and 28.5%, respectively. All of the PDR, ADR, and DDR were higher in males, and increased with age (Table 2). One hundred and sixty subjects (61%) underwent a total of 387 diagnostic and/or therapeutic interventions [136/387 "cold" or simple biopsies (35.2%); 143/387 "hot" biopsy polypectomies featuring bipolar coagulation (37%); 102/387 "hot" snare polypectomies featuring bipolar coagulation (26.3%); and 6/387 ESDs (1.5%)]. After biopsy, 23





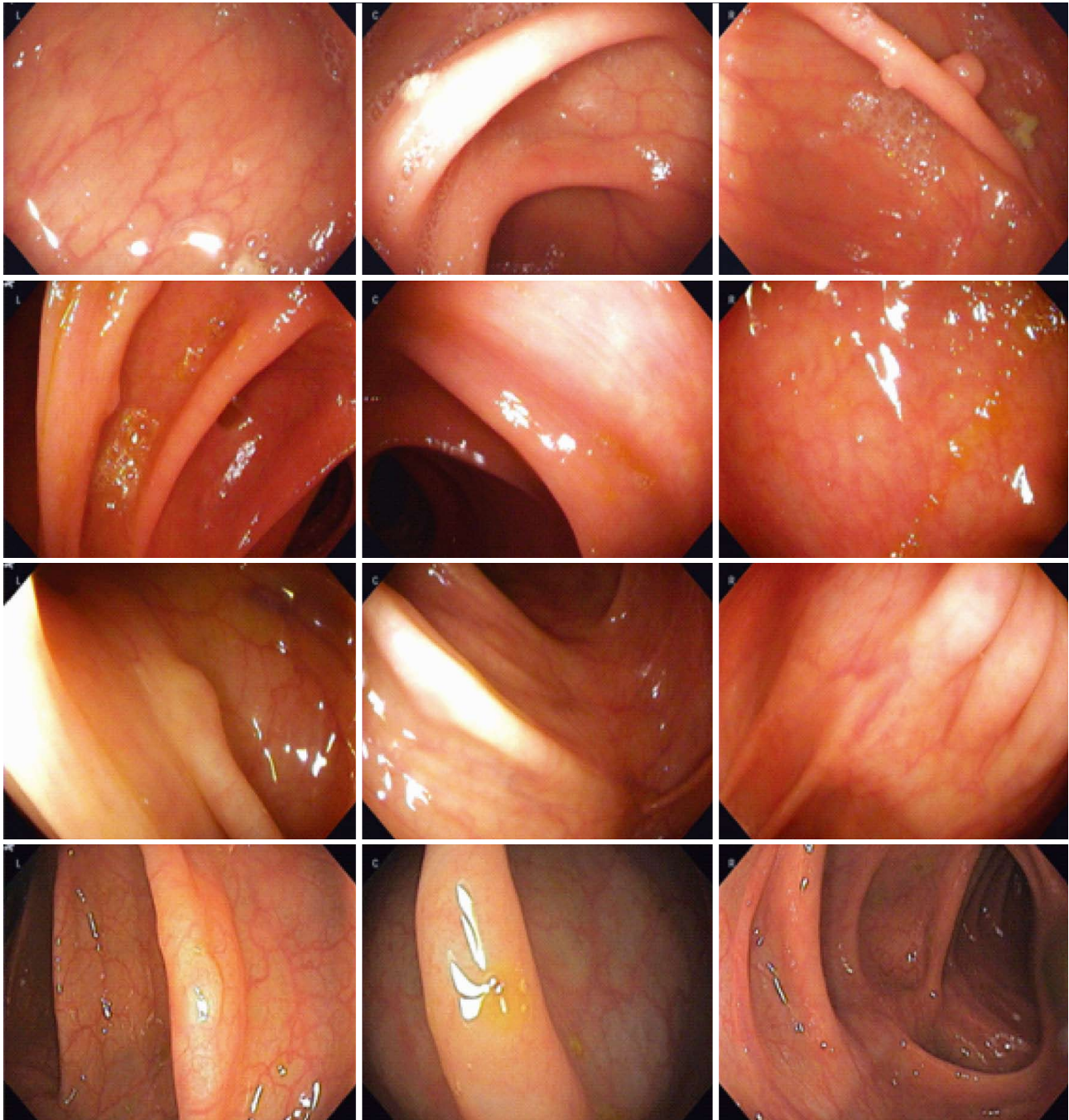
**Figure 1 Standard forward-view vs full-spectrum endoscopy.** The standard forward-viewing (SFV) endoscope has a 150° (gastroscope) or 170° (colonoscope) field of view shown on a single screen (A and C). The full-spectrum endoscopy (FUSE) system features additional imagers and provides a 245° (gastroscope) or 330° (colonoscope) field of view presented on two (gastroscope) or three (colonoscope) contiguous screens (B and D).

of the adenomas (13.3%) had advanced histologies (e.g., high-grade dysplasia, or a villous component, or cancer). All diagnostic and therapeutic interventions were performed with the FUSE colonoscope and successful. No acute or delayed adverse event was noted. The endoscopists and nurses considered that the FUSE colonoscope improved navigation and orientation within the colon. Insertion of endoscopic accessories through the working channel, followed

by guidance to the desired location, was convenient. No colonoscopy was aborted because of equipment malfunction or failure.

## DISCUSSION

The principal advantage of colonoscopy compared to non-endoscopic screening is that the former technique facilitates therapy, or at least allows biopsy of colorectal



**Figure 2 Demonstration of full-spectrum endoscopy.** The full-spectrum endoscopy (FUSE) reveals “hidden” colon polyps of several types not detected by traditional standard forward-view colonoscopy.

lesions prior to subsequent therapy. Therefore, colonoscopy is regarded as the gold standard when screening for CRC and the precursor lesions thereof, colorectal adenomas. Although many efforts have been made to improve visualization and reduce blind spots in the colonic mucosa, and to increase the PDR and ADR, about 10% of the colonic surface remains unobserved during SFV colonoscopy even after good bowel preparation<sup>[12,17]</sup>. Even more importantly, the quality of colonoscopy is a major determinant of the risk of incident interval CRC; substantial adenoma miss rates [approximately 20% for any adenoma and 2%-6% for

large adenomas ( $\geq 10$  mm in diameter)] have been reported in many studies<sup>[3,4,7,11,14]</sup>. The ADR is inversely associated with the risks of interval colorectal cancer, advanced-stage interval cancer, and fatal interval cancer. Importantly, each 1% increase in the ADR was associated with a 3% decrease in the risk of colorectal cancer<sup>[3]</sup>. In addition, other than the quality of bowel preparation and the skills of the endoscopist, growing evidence suggests that it is important to reduce the adenoma miss rate of traditional SFV colonoscopy by improving current colonoscopic techniques, and removing current limitations of visualization and



**Table 1 Patient characteristics *n* (%)**

Characteristics	
Total number of enrolled patients	262
M:F	132:130
Age range, yr	22-80
All cases: Mean $\pm$ SD, yr	48.9 $\pm$ 11.8
Under 40 (M:F)	62 (41:21)
41-60 (M:F)	160 (75:85)
Over 61 (M:F)	40 (16:24)
Total number of patients with polyp(s)	142 (54.2)
Total number of polyps detected	313
Location in colon, Rt : Lt side	130:183 (41.5:58.5)
Total number of patients with adenoma(s)	95 (36.3)
Total number of adenomas detected	173
Location in colon, Rt : Lt side	83:90 (48:52)
Total number of patients with diverticula	66 (25.2)
Location in colon, Rt : Lt side	82.1:17.9
Success rate of cecal intubation	100%
Adverse events	0
Procedure time, minute, mean $\pm$ SD	
All procedure (except ESD)	
Insertion time	5.8 $\pm$ 1.5 (5.8 $\pm$ 1.4)
Withdrawal time	12.5 $\pm$ 8.3 (11.7 $\pm$ 7.0)
Total time	18.3 $\pm$ 8.6 (17.5 $\pm$ 7.4)
Diagnostic procedure	
Insertion time	5.4 $\pm$ 1.2
Withdrawal time	7.3 $\pm$ 1.0
Total time	12.7 $\pm$ 1.4

M:F: Male:Female; ESD: Endoscopic submucosal dissection.

optics<sup>[9,10,14]</sup>. Such efforts have yielded: (1) white-light endoscopy; high-definition white-light (HDWL) endoscopy, water-infused colonoscopy, and the full-spectrum endoscopy colonoscopy platform (FUSE, EndoChoice, Alpharetta, GA, United States); (2) chromoendoscopy and optical (dye-based) or virtual chromoendoscopy (CE); and (3) accessory-assisted endoscopy, cap-assisted colonoscopy (CAC), the Third Eye Retroscope (TER), the Third Eye Panoramic (TEP, Avantis Medical Systems, Sunnyvale, United States) and other retroviewing devices, the NaviAid G-EYE balloon endoscope (SMART Medical Systems Ltd, Ra'anana, Israel), the Endocuff (EC)-assisted colonoscope (Arc Medical Design Ltd., Leeds, England), and the Extra-Wide-Angle-View colonoscope (Olympus, Tokyo, Japan).

One of the major recent advances in colonoscopy has been the development and adoption of HDWL instruments. Such scopes allow more detailed imaging of the colonic mucosa. However, studies using HDWL scopes have found that the ADR increase is minimal compared to that afforded using SDWL. Also, the newly detected polyps are small; HDWL affords no improvement in detection of large or advanced lesions<sup>[18-20]</sup>. Water infusion rather than air insufflation during colonoscopy seeks to facilitate cecal intubation and reduce patient discomfort<sup>[21]</sup>. However, a recent systematic review found no differences in the ADRs of water-immersion and air-insufflation colonoscopy<sup>[22]</sup>. Dye-spray CE improves the detection of neoplastic

lesions in high-risk populations, such as those with inflammatory bowel disease or hereditary syndromes associated with development of colonic polyps<sup>[23]</sup>. In a large randomized trial comparing CE-plus-HDWL with HDWL alone, only marginal increases in the ADR and the number of adenomas detected per patient were evident<sup>[24]</sup>. In contrast to optical CE, several virtual CE systems enhance images using light of specific wavelengths; these include the Narrow Band Imaging system (Olympus Medical Systems), Fujinon Intelligence Chromoendoscopy (FICE), Storz Professional Image Enhancement System (SPIES, Karl Storz), and the i-Scan (Pentax). Selection of specific wavelengths creates a colored image resembling that of an image derived using CE<sup>[25,26]</sup>. However, overall, studies on virtual CE have yielded conflicting results, or have found that CE was of limited utility compared to HDWL in terms of improving the ADR<sup>[27-29]</sup>. To enhance visualization during mucosal resection, mucosal folds have been flattened by fitting a 4-mm-diameter clear cap to the end of the colonoscope. However, randomized trials of CAC versus conventional colonoscopy have yielded conflicting results in terms of improving the ADR<sup>[30,31]</sup>. The Third Eye technologies, the acronyms for which are TER and TEP, are auxiliary, through-the-scope (TER) or fitted-onto-scope (TEP) techniques developed to detect polyps located on proximal folds and at anatomical flexures of the colon; they afford 135° retrograde views<sup>[12]</sup>. Several studies have evaluated additional diagnostic yields afforded by the TER technology; increases in the PDR and ADR were evident<sup>[5,32]</sup>. Despite such increases, the TER system has several limitations that mitigate against widespread adoption. The TER is more expensive than conventional colonoscopy (because the device is disposable), and the auxiliary scope must be removed from the working channel if any other item, such as forceps or a snare, is required for polyp removal. This may prolong withdrawal time and limit the utility of the system in daily practice<sup>[10,17]</sup>. The NaviAid G-EYE system uses a standard endoscope in which a permanently integrated, inflatable reusable, reprocessable balloon is incorporated at the distal flexible tip. Mechanical flattening and straightening of haustral folds using the inflated balloon allows visualization of hidden anatomical areas, thus increasing adenoma detection. The EC is similar in concept to balloon-assisted colonoscopy. This is a 2-cm-long flexible cuff with two rows of small flexible hinged wings that help to flatten large mucosal folds during withdrawal of the instrument, permitting visualization of hidden anatomical areas, thus increasing the ADR<sup>[33,34]</sup>. Although relatively few studies have been performed, increased ADRs have been reported using NaviAid G-EYE and the EC system; further evaluation is required<sup>[35,36]</sup>. The Extra-Wide-Angle-View colonoscope has a projecting convex lens affording a lateral-backward (144°-232°) view, in

**Table 2** Age and gender differences in terms of polyp detection rate, adenoma detection rate, and diverticulum detection rate

Age	Gender (n)	PDR	ADR	DDR
All patients	Overall (262)	54.2% (142/262)	36.3% (95/262)	25.2% (66/262)
	M (132)	68.2% (90/132)	47.0% (62/132)	26.5% (35/132)
	F (130)	40.0% (52/130)	25.4% (33/130)	23.8% (31/130)
Under 40 yr	Overall (62)	35.5% (22/62)	17.7% (11/62)	14.5% (9/62)
	M (41)	51.2% (21/41)	26.8% (11/41)	14.6% (6/41)
	F (21)	4.8% (1/21)	0% (0/21)	14.3% (3/21)
41-60 yr	Overall (160)	58.1% (93/160)	38.1% (61/160)	22.5% (36/160)
	M (75)	73.3% (55/75)	52.0% (39/75)	24.0% (18/75)
	F (85)	44.7% (38/85)	25.9% (22/85)	21.2% (18/85)
Over 61 yr	Overall (40)	67.5% (27/40)	57.5% (23/40)	52.5% (21/40)
	M (16)	87.5% (14/16)	75.0% (12/16)	68.8% (11/16)
	F (24)	54.2% (13/24)	45.8% (11/24)	41.7% (10/24)

PDR: Polyp detection rate; ADR: Adenoma detection rate; DDR: Diverticulum detection rate; M: Male; F: Female.

addition to a forward-view (140°) lens at the tip of the scope, and blends simultaneous views from either lens into a single endoscopic image. However, the ADRs of several studies have differed<sup>[37]</sup>. In contrast to the maximum field of view (170°) of SFV colonoscopes, the FUSE colonoscopy platform affords the endoscopist a high-resolution, 330° 'full spectrum' view of the colorectal mucosa, with maintenance of all standard colonoscopic capabilities. Following *in vitro* testing, a successful pilot study in humans, and an international multicenter, randomized, back-to-back comparative study, Hassan *et al* reported that the FUSE colonoscopy appeared to be more cost-effective in terms of colon cancer screening and surveillance than was standard colonoscopy<sup>[12,16,38]</sup>.

In our present study, the PDR, ADR, and DDR using the FUSE colonoscopy were higher than those of other studies using traditional colonoscopy ranging 18%-37.5%, 17%-25%, and 1.3%-11.5%, respectively. Very recently, Choi *et al*<sup>[39]</sup> reported the PDR, ADR of 1937 Korean individuals in a multicenter study as 49.9% and 36.6%, respectively. But those relatively high PDR, ADR might be related with more older subjects (age range: 40-84) than our study, and they used transparent cap and virtual chromoendoscopy in part<sup>[39-42]</sup>. We used only FUSE colonoscope for all diagnostic and therapeutic interventions, and we encountered no therapeutic failure or complications. However, our study has certain limitations. First, as no other Korean center currently employs the FUSE technology, this was a single-center, retrospective, non-comparative and non-randomized study. Second, we did not use a stopwatch to record time, but we did check the time stamps on the videos taken during each colonoscopy. In addition, as we performed many therapeutic interventions, even ESDs, mean total procedure time (18.3 ± 8.6 min, range 9-48 min) was thus probably longer than those of other studies<sup>[15]</sup>. But if we considered only diagnostic interventions, mean total procedure time was shortened to 12.7 ± 1.4 min (range 9-17 min). Third, we report only the presence of a diverticulum, and not

the numbers thereof, because many cases had too many diverticula to count. Fourth, we did not measure the exact polyp size, and thus cannot compare among-study differences in the PDR or ADR by the sizes of polyps or adenomas.

After several months of using the FUSE system, we also have some recommendations we wish to make to the FUSE manufacturer. Participating endoscopists considered that the FUSE colonoscope was somewhat softer and more flexible than other SFV colonoscopes, possibly resulting in more loop formation during insertion, particularly by unskilled physicians. Scope stiffness should be variable, to prevent loop formation. Also, additional working channels are needed on both sides of the scope. If "hidden" polyps are found on both sides, it is presently necessary to manipulate the scope to remove the polyps through the single central working channel. This may sometimes be difficult and time-consuming. Finally, hidden, diminutive flat lesions could be more readily detected if virtual CE was combined with the FUSE system.

In conclusion, the FUSE colonoscopy yielded a higher PDR, ADR, and DDR than did traditional colonoscopy, without therapeutic failure or complications. In this first Korean trial, the FUSE colonoscopy was feasible, effective, and safe; further larger comparative studies are required.

## COMMENTS

### Background

Although it is widely accepted that screening colonoscopy is most effective for early detection of colorectal cancer (CRC), CRC remains a leading cause of cancer-related mortality worldwide. Simple colonoscopic polypectomy can prevent CRC and reduce mortality. However, several studies have highlighted the miss rates of adenomatous polyps during colonoscopy. In recent times, many efforts have been made to enhance the imaging and endoscopic technologies used during colonoscopy beyond the traditional SFV angle. Of these, recently developed the Full-Spectrum Endoscopy® (FUSE®, EndoChoice, Alpharetta, GA, United States) colonoscopy platform is expected to improve the detection of colorectal lesions because the field of view (330°) is much wider than that of traditional colonoscopy (170°). An international, multicenter, randomized, back-to-back comparative study showed that the adenoma detection rate was significantly higher and the miss rate lower when the FUSE

rather than standard colonoscopy was employed.

## Research frontiers

As no other Korean center currently employed the FUSE technology, the author of this study explored the efficacy of the FUSE system for the first time in Korea; this is thus the first report on a Korean population.

## Innovations and breakthroughs

In this study, the polyp detection rate (PDR), adenoma detection rate (ADR), and diverticulum detection rate (DDR) using the FUSE colonoscopy (54.2%, 36.3%, and 25.2%, respectively) were higher than those of other studies using traditional colonoscopy at 18%-37.5%, 17%-25%, and 1.3%-11.5%, respectively. The authors used only the FUSE colonoscopy for all diagnostic and therapeutic interventions including ESDs, and they encountered no therapeutic failure or complications.

## Applications

This study shows that FUSE colonoscopy is feasible, effective, and safe, resulting a relatively higher PDR, ADR, and DDR, without problems.

## Peer-review

The author of this paper showed that the FUSE colonoscopy yielded a higher PDR, ADR, and DDR than did traditional colonoscopy, without therapeutic failure or complications. In this first Korean trial, the FUSE colonoscopy was feasible, effective, and safe; further larger comparative studies are required.

## REFERENCES

- 1 Ferlay J, Shin HR, Bray F, Forman D, Mathers C, Parkin DM. Estimates of worldwide burden of cancer in 2008: GLOBOCAN 2008. *Int J Cancer* 2010; **127**: 2893-2917 [PMID: 21351269 DOI: 10.1002/ijc.25516]
- 2 Zauber AG, Winawer SJ, O'Brien MJ, Lansdorp-Vogelaar I, van Ballegooijen M, Hankey BF, Shi W, Bond JH, Schapiro M, Panish JF, Stewart ET, Wayne JD. Colonoscopic polypectomy and long-term prevention of colorectal-cancer deaths. *N Engl J Med* 2012; **366**: 687-696 [PMID: 22356322 DOI: 10.1056/NEJMoa1100370]
- 3 Corley DA, Jensen CD, Marks AR, Zhao WK, Lee JK, Doubeni CA, Zauber AG, de Boer J, Fireman BH, Schottinger JE, Quinn VP, Ghai NR, Levin TR, Quesenberry CP. Adenoma detection rate and risk of colorectal cancer and death. *N Engl J Med* 2014; **370**: 1298-1306 [PMID: 24693890 DOI: 10.1056/NEJMoa1309086]
- 4 Heresbach D, Barrioz T, Lapalus MG, Coumaros D, Bauret P, Potier P, Sautereau D, Boustière C, Grimaud JC, Barthélémy C, Sée J, Serraj I, D'Halluin PN, Branger B, Ponchon T. Miss rate for colorectal neoplastic polyps: a prospective multicenter study of back-to-back video colonoscopies. *Endoscopy* 2008; **40**: 284-290 [PMID: 18389446 DOI: 10.1055/s-2007-995618]
- 5 Leufkens AM, DeMarco DC, Rastogi A, Akerman PA, Azzouzi K, Rothstein RI, Vleggaar FP, Repici A, Rando G, Okolo PI, Dewit O, Ignjatovic A, Odstrcil E, East J, Deprez PH, Saunders BP, Kalloo AN, Creel B, Singh V, Lennon AM, Siersema PD. Effect of a retrograde-viewing device on adenoma detection rate during colonoscopy: the TERRACE study. *Gastrointest Endosc* 2011; **73**: 480-489 [PMID: 21067735 DOI: 10.1016/j.gie.2010.09.004]
- 6 Leufkens AM, van Oijen MG, Vleggaar FP, Siersema PD. Factors influencing the miss rate of polyps in a back-to-back colonoscopy study. *Endoscopy* 2012; **44**: 470-475 [PMID: 22441756 DOI: 10.1055/s-0031-1291666]
- 7 Harrison M, Singh N, Rex DK. Impact of proximal colon retroflexion on adenoma miss rates. *Am J Gastroenterol* 2004; **99**: 519-522 [PMID: 15056095 DOI: 10.1111/j.1572-0241.2004.04070.x]
- 8 Hewett DG, Rex DK. Miss rate of right-sided colon examination during colonoscopy defined by retroflexion: an observational study. *Gastrointest Endosc* 2011; **74**: 246-252 [PMID: 21679946 DOI: 10.1016/j.gie.2011.04.005]
- 9 Lee SH, Park YK, Lee DJ, Kim KM. Colonoscopy procedural skills and training for new beginners. *World J Gastroenterol* 2014; **20**: 16984-16995 [PMID: 25493011 DOI: 10.3748/wjg.v20.i45.16984]
- 10 Gralnek IM. Emerging technological advancements in colonoscopy: Third Eye® Retroscope® and Third Eye® Panoramic(TM), Fuse® Full Spectrum Endoscopy® colonoscopy platform, Extra-Wide-Angle-View colonoscope, and NaviAid(TM) G-EYE(TM) balloon colonoscope. *Dig Endosc* 2015; **27**: 223-231 [PMID: 25251748 DOI: 10.1111/den.12382]
- 11 Kaminski MF, Regula J, Kraszewska E, Polkowski M, Wojciechowska U, Didkowska J, Zwierko M, Rupinski M, Nowacki MP, Butruk E. Quality indicators for colonoscopy and the risk of interval cancer. *N Engl J Med* 2010; **362**: 1795-1803 [PMID: 20463339 DOI: 10.1056/NEJMoa0907667]
- 12 East JE, Saunders BP, Burling D, Boone D, Halligan S, Taylor SA. Surface visualization at CT colonography simulated colonoscopy: effect of varying field of view and retrograde view. *Am J Gastroenterol* 2007; **102**: 2529-2535 [PMID: 17640320 DOI: 10.1111/j.1572-0241.2007.01429.x]
- 13 Barclay RL, Vicari JJ, Doughty AS, Johanson JF, Greenlaw RL. Colonoscopic withdrawal times and adenoma detection during screening colonoscopy. *N Engl J Med* 2006; **355**: 2533-2541 [PMID: 17167136 DOI: 10.1056/NEJMoa055498]
- 14 Gralnek IM, Carr-Locke DL, Segol O, Halpern Z, Siersema PD, Sloyer A, Fenster J, Lewis BS, Santo E, Suissa A, Segev M. Comparison of standard forward-viewing mode versus ultrawide-viewing mode of a novel colonoscopy platform: a prospective, multicenter study in the detection of simulated polyps in an in vitro colon model (with video). *Gastrointest Endosc* 2013; **77**: 472-479 [PMID: 23410700 DOI: 10.1016/j.gie.2012.12.011]
- 15 Gralnek IM, Segol O, Suissa A, Siersema PD, Carr-Locke DL, Halpern Z, Santo E, Domanov S. A prospective cohort study evaluating a novel colonoscopy platform featuring full-spectrum endoscopy. *Endoscopy* 2013; **45**: 697-702 [PMID: 23939509 DOI: 10.1055/s-0033-1344395]
- 16 Gralnek IM, Siersema PD, Halpern Z, Segol O, Melhem A, Suissa A, Santo E, Sloyer A, Fenster J, Moons LM, Dik VK, D'Agostino RB, Rex DK. Standard forward-viewing colonoscopy versus full-spectrum endoscopy: an international, multicentre, randomised, tandem colonoscopy trial. *Lancet Oncol* 2014; **15**: 353-360 [PMID: 24560453 DOI: 10.1016/S1470-2045(14)70020-8]
- 17 Moriyama T, Uraoka T, Esaki M, Matsumoto T. Advanced technology for the improvement of adenoma and polyp detection during colonoscopy. *Dig Endosc* 2015; **27** Suppl 1: 40-44 [PMID: 25556542 DOI: 10.1111/den.12428]
- 18 Pellisé M, Fernández-Esparrach G, Cárdenas A, Sendino O, Ricart E, Vaquero E, Gimeno-García AZ, de Miguel CR, Zabalza M, Ginès A, Piqué JM, Llach J, Castells A. Impact of wide-angle, high-definition endoscopy in the diagnosis of colorectal neoplasia: a randomized controlled trial. *Gastroenterology* 2008; **135**: 1062-1068 [PMID: 18725223 DOI: 10.1053/j.gastro.2008.06.090]
- 19 Tribonias G, Theodoropoulou A, Konstantinidis K, Vardas E, Karmiris K, Chroniaris N, Chlouverakis G, Paspatis GA. Comparison of standard vs high-definition, wide-angle colonoscopy for polyp detection: a randomized controlled trial. *Colorectal Dis* 2010; **12**: e260-e266 [PMID: 19930146 DOI: 10.1111/j.1463-1318.2009.02145.x]
- 20 Rastogi A, Early DS, Gupta N, Bansal A, Singh V, Anstas M, Jonnalagadda SS, Hovis CE, Gaddam S, Wani SB, Edmundowicz SA, Sharma P. Randomized, controlled trial of standard-definition white-light, high-definition white-light, and narrow-band imaging colonoscopy for the detection of colon polyps and prediction of polyp histology. *Gastrointest Endosc* 2011; **74**: 593-602 [PMID: 21802078 DOI: 10.1016/j.gie.2011.04.050]
- 21 Church JM. Warm water irrigation for dealing with spasm during colonoscopy: simple, inexpensive, and effective. *Gastrointest Endosc* 2002; **56**: 672-674 [PMID: 12397274 DOI: 10.1067/mge.2002.128916]
- 22 Leung FW, Amato A, Ell C, Friedland S, Harker JO, Hsieh YH, Leung JW, Mann SK, Paggi S, Pohl J, Radaelli F, Ramirez FC, Siao-Salera R, Terruzzi V. Water-aided colonoscopy: a systematic



- review. *Gastrointest Endosc* 2012; **76**: 657-666 [PMID: 22898423 DOI: 10.1016/j.gie.2012.04.467]
- 23 **Kiesslich R**, von Bergh M, Hahn M, Hermann G, Jung M. Chromoendoscopy with indigocarmine improves the detection of adenomatous and nonadenomatous lesions in the colon. *Endoscopy* 2001; **33**: 1001-1006 [PMID: 11740641 DOI: 10.1055/s-2001-18932]
  - 24 **Kahi CJ**, Anderson JC, Waxman I, Kessler WR, Imperiale TF, Li X, Rex DK. High-definition chromocolonoscopy vs. high-definition white light colonoscopy for average-risk colorectal cancer screening. *Am J Gastroenterol* 2010; **105**: 1301-1307 [PMID: 20179689 DOI: 10.1038/ajg.2010.51]
  - 25 **Murthy S**, Goetz M, Hoffman A, Kiesslich R. Novel colonoscopic imaging. *Clin Gastroenterol Hepatol* 2012; **10**: 984-987 [PMID: 22835580 DOI: 10.1016/j.cgh.2012.07.011]
  - 26 **Sauk J**, Hoffman A, Anandasabapathy S, Kiesslich R. High-definition and filter-aided colonoscopy. *Gastroenterol Clin North Am* 2010; **39**: 859-881 [PMID: 21093760 DOI: 10.1016/j.gtc.2010.08.022]
  - 27 **Sabbagh LC**, Reveiz L, Aponte D, de Aguiar S. Narrow-band imaging does not improve detection of colorectal polyps when compared to conventional colonoscopy: a randomized controlled trial and meta-analysis of published studies. *BMC Gastroenterol* 2011; **11**: 100 [PMID: 21943365 DOI: 10.1186/1471-230X-11-100]
  - 28 **Hong SN**, Choe WH, Lee JH, Kim SI, Kim JH, Lee TY, Kim JH, Lee SY, Cheon YK, Sung IK, Park HS, Shim CS. Prospective, randomized, back-to-back trial evaluating the usefulness of i-SCAN in screening colonoscopy. *Gastrointest Endosc* 2012; **75**: 1011-1021.e2 [PMID: 22381530 DOI: 10.1016/j.gie.2011.11.040]
  - 29 **Kuiper T**, van den Broek FJ, Naber AH, van Soest EJ, Scholten P, Mallant-Hent RCh, van den Brande J, Jansen JM, van Oijen AH, Marsman WA, Bergman JJ, Fockens P, Dekker E. Endoscopic trimodal imaging detects colonic neoplasia as well as standard video endoscopy. *Gastroenterology* 2011; **140**: 1887-1894 [PMID: 21419769 DOI: 10.1053/j.gastro.2011.03.008]
  - 30 **Kondo S**, Yamaji Y, Watabe H, Yamada A, Sugimoto T, Ohta M, Ogura K, Okamoto M, Yoshida H, Kawabe T, Omata M. A randomized controlled trial evaluating the usefulness of a transparent hood attached to the tip of the colonoscope. *Am J Gastroenterol* 2007; **102**: 75-81 [PMID: 17100978 DOI: 10.1111/j.1572-0241.2006.00897.x]
  - 31 **de Wijkerslooth TR**, Stoop EM, Bossuyt PM, Mathus-Vliegen EM, Dees J, Tytgat KM, van Leerdam ME, Fockens P, Kuipers EJ, Dekker E. Adenoma detection with cap-assisted colonoscopy versus regular colonoscopy: a randomised controlled trial. *Gut* 2012; **61**: 1426-1434 [PMID: 22187070 DOI: 10.1136/gutjnl-2011-301327]
  - 32 **DeMarco DC**, Odstrcil E, Lara LF, Bass D, Herdman C, Kinney T, Gupta K, Wolf L, Dewar T, Deas TM, Mehta MK, Anwer MB, Pellish R, Hamilton JK, Polter D, Reddy KG, Hanan I. Impact of experience with a retrograde-viewing device on adenoma detection rates and withdrawal times during colonoscopy: the Third Eye Retroscope study group. *Gastrointest Endosc* 2010; **71**: 542-550 [PMID: 20189513 DOI: 10.1016/j.gie.2009.12.021]
  - 33 **Lenze F**, Beyna T, Lenz P, Heinzow HS, Hengst K, Ullerich H. Endocuff-assisted colonoscopy: a new accessory to improve adenoma detection rate? Technical aspects and first clinical experiences. *Endoscopy* 2014; **46**: 610-614 [PMID: 24824090 DOI: 10.1055/s-0034-1365446]
  - 34 **Pioche M**, Matsumoto M, Takamaru H, Sakamoto T, Nakajima T, Matsuda T, Abe S, Kakugawa Y, Otake Y, Saito Y. Endocuff®-assisted colonoscopy increases polyp detection rate: a simulated randomized study involving an anatomic colorectal model and 32 international endoscopists. *Surg Endosc* 2016; **30**: 288-295 [PMID: 25861907 DOI: 10.1007/s00464-015-4208-8]
  - 35 **Gralnek IM**, Suissa A, Domanov S. Safety and efficacy of a novel balloon colonoscope: a prospective cohort study. *Endoscopy* 2014; **46**: 883-887 [PMID: 25225962 DOI: 10.1055/s-0034-1377968]
  - 36 **Biecker E**, Floer M, Heinecke A, Ströbel P, Böhme R, Schepke M, Meister T. Novel endocuff-assisted colonoscopy significantly increases the polyp detection rate: a randomized controlled trial. *J Clin Gastroenterol* 2015; **49**: 413-418 [PMID: 24921209 DOI: 10.1097/MCG.0000000000000166]
  - 37 **Uraoka T**, Tanaka S, Matsumoto T, Matsuda T, Oka S, Moriyama T, Higashi R, Saito Y. A novel extra-wide-angle-view colonoscope: a simulated pilot study using anatomic colorectal models. *Gastrointest Endosc* 2013; **77**: 480-483 [PMID: 23199903 DOI: 10.1016/j.gie.2012.08.037]
  - 38 **Hassan C**, Gralnek IM. Cost-effectiveness of "full spectrum endoscopy" colonoscopy for colorectal cancer screening. *Dig Liver Dis* 2015; **47**: 390-394 [PMID: 25704067 DOI: 10.1016/j.dld.2015.01.154]
  - 39 **Choi SY**, Park DI, Lee CK, Cha JM, Lee SH, Whangbo Y, Eun CS, Han DS, Lee BI, Shin JE. [Usefulness of polyp and adenoma detection rate in the proximal and distal colon]. *Korean J Gastroenterol* 2014; **63**: 11-17 [PMID: 24463283]
  - 40 **Corley DA**, Jensen CD, Marks AR, Zhao WK, de Boer J, Levin TR, Doubeni C, Fireman BH, Quesenberry CP. Variation of adenoma prevalence by age, sex, race, and colon location in a large population: implications for screening and quality programs. *Clin Gastroenterol Hepatol* 2013; **11**: 172-180 [PMID: 22985608 DOI: 10.1016/j.cgh.2012.09.010]
  - 41 **Francis DL**, Rodriguez-Correa DT, Buchner A, Harewood GC, Wallace M. Application of a conversion factor to estimate the adenoma detection rate from the polyp detection rate. *Gastrointest Endosc* 2011; **73**: 493-497 [PMID: 21353846 DOI: 10.1016/j.gie.2011.01.005]
  - 42 **Kim SY**, Kim YS, Kim HT, Kwon SO, Oh MK, Cha IH, Ok KS, Kwak CH, Kim JN, Moon JS. [A prospective study of factors influencing on the clinical characteristics of colonic diverticulosis]. *Korean J Gastroenterol* 2013; **62**: 97-103 [PMID: 23981943]

**P- Reviewer:** Hosoe N, Lee SH, Niu ZS, Seow-Choen F  
**S- Editor:** Qi Y **L- Editor:** A **E- Editor:** Liu XM





Published by **Baishideng Publishing Group Inc**

8226 Regency Drive, Pleasanton, CA 94588, USA

Telephone: +1-925-223-8242

Fax: +1-925-223-8243

E-mail: [bpgoffice@wjgnet.com](mailto:bpgoffice@wjgnet.com)

Help Desk: <http://www.wjgnet.com/esps/helpdesk.aspx>

<http://www.wjgnet.com>



ISSN 1007-9327



9 771007 932045