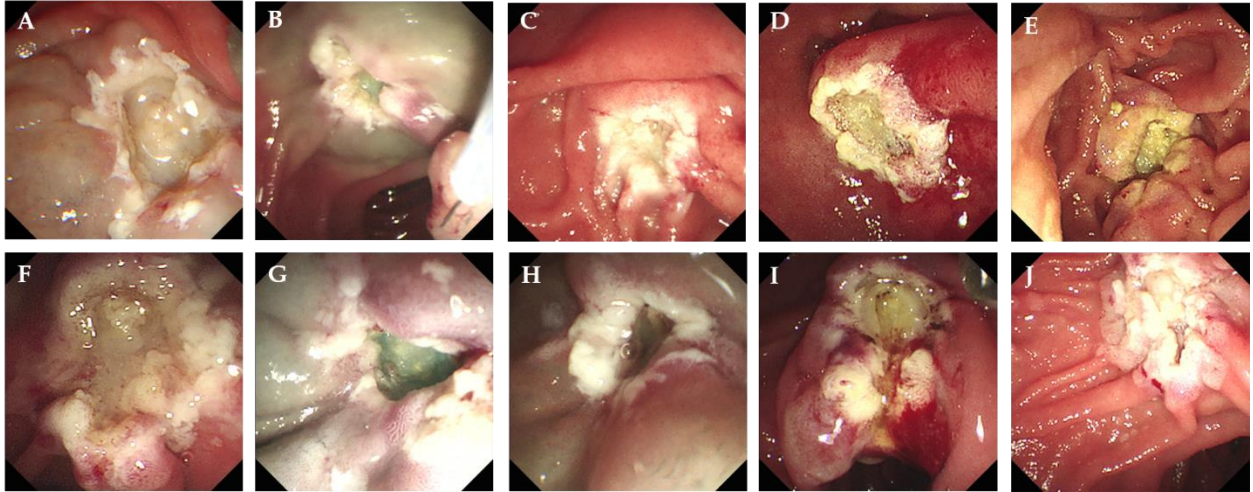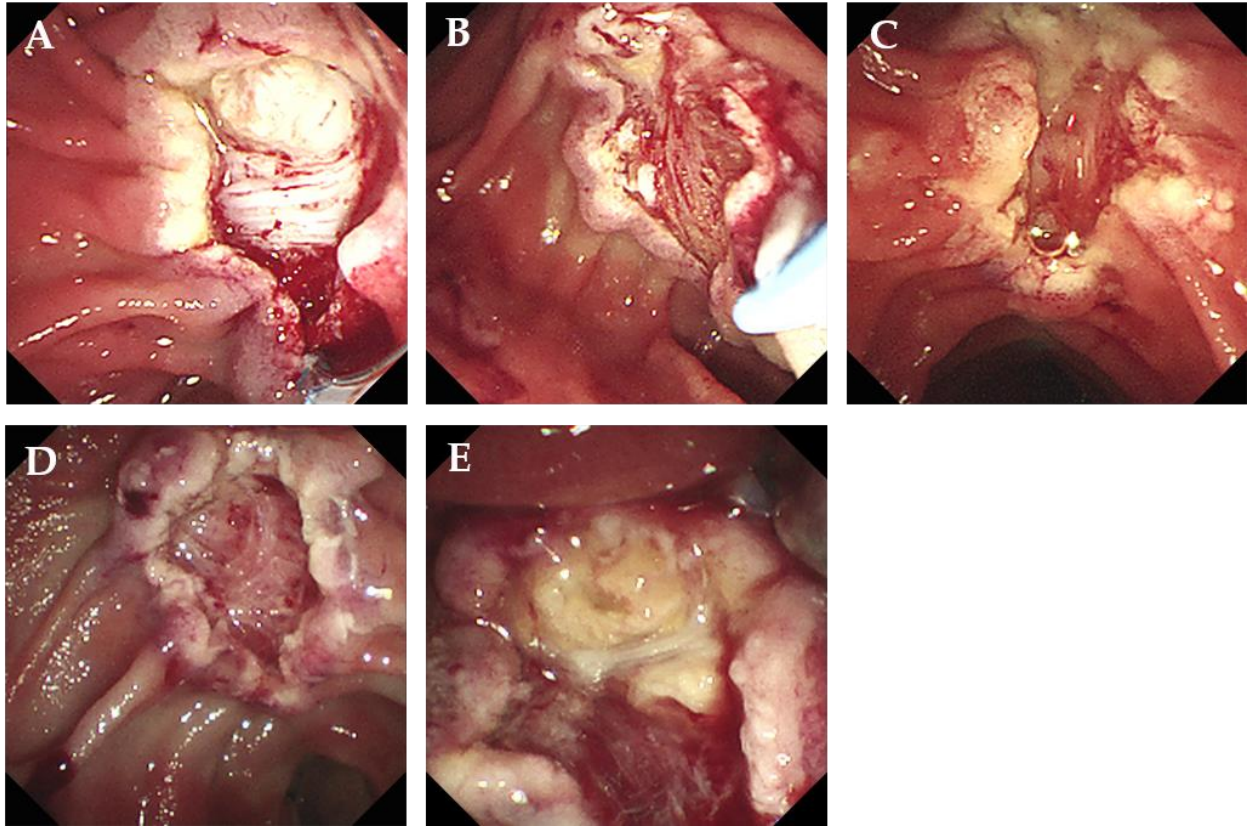


Supplementary Figure 1 Endoscopic images without exposure or injury of muscularis propria in 10 cases. A: Case 1; B: Case 2; C: Case 3; D: Case 4; E: Case 5; F: Case 6; G: Case 7; H: Case 8; I: Case 9; J: Case 10.



Supplementary Figure 2 Endoscopic images of exposure or injury of muscularis propria in 5 cases. A: Case 1; B: Case 2; C: Case 3; D: Case 4; E: Case 5.