

World Journal of *Orthopedics*

World J Orthop 2021 September 18; 12(9): 620-726



MINIREVIEWS

- 620** Coronaviruses: An overview with special emphasis on COVID-19 outbreak with musculoskeletal manifestations
Ali S, Singh A, Sharief N, Yadav M, Siddiqui S, Pandey V, Raikwar A, Singh A
- 629** Hip prosthetic loosening: A very personal review
Mjöberg B
- 640** Jones type fifth metatarsal fracture fixation in athletes: A review and current concept
Albloushi M, Alshanqiti A, Qasem M, Abitbol A, Gregory T
- 651** Effects of sclerostin antibody on bone healing
Mihara A, Yukata K, Seki T, Iwanaga R, Nishida N, Fujii K, Nagao Y, Sakai T
- 660** Current concepts in the management of bisphosphonate associated atypical femoral fractures
Rudran B, Super J, Jandoo R, Babu V, Nathan S, Ibrahim E, Wiik AV
- 672** Virtual orthopedic assessment: Main principles and specific regions
Emara KM, Diab RA, Amr M, Mahmoud SA, Nour M, Abdelsalam A, Elshobaky MA, Farhan M, Gemeah M, Emara AK
- 685** Machine learning in orthopaedic surgery
Lalehzarian SP, Gowd AK, Liu JN

ORIGINAL ARTICLE

Clinical and Translational Research

- 700** Trends and risk factors for opioid administration for non-emergent lower back pain
Gwam CU, Emara AK, Chughtai N, Javed S, Luo TD, Wang KY, Chughtai M, O'Gara T, Plate JF

Retrospective Study

- 710** Correlation of stress radiographs to injuries associated with lateral ankle instability
Sy JW, Lopez AJ, Lausé GE, Deal JB, Lustik MB, Ryan PM

CASE REPORT

- 720** Atypical osteochondroma of the lumbar spine associated with suprasellar pineal germinoma: A case report
Suwak P, Barnett SA, Song BM, Heffernan MJ

ABOUT COVER

Editorial Board Member of *World Journal of Orthopedics*, Vasileios S Nikolaou, MD, MSc, PhD, Associate Professor, Surgeon, The Second Orthopaedic Department, School of Medicine, National and Kapodistrian University of Athens, Athens 14233, Greece. vassilios.nikolaou@gmail.com

AIMS AND SCOPE

The primary aim of *World Journal of Orthopedics* (*WJO*, *World J Orthop*) is to provide scholars and readers from various fields of orthopedics with a platform to publish high-quality basic and clinical research articles and communicate their research findings online.

WJO mainly publishes articles reporting research results and findings obtained in the field of orthopedics and covering a wide range of topics including arthroscopy, bone trauma, bone tumors, hand and foot surgery, joint surgery, orthopedic trauma, osteoarthropathy, osteoporosis, pediatric orthopedics, spinal diseases, spine surgery, and sports medicine.

INDEXING/ABSTRACTING

The *WJO* is now abstracted and indexed in PubMed, PubMed Central, Emerging Sources Citation Index (Web of Science), Scopus, China National Knowledge Infrastructure (CNKI), China Science and Technology Journal Database (CSTJ), and Superstar Journals Database. The 2021 edition of Journal Citation Reports® cites the 2020 Journal Citation Indicator (JCI) for *WJO* as 0.66. The *WJO*'s CiteScore for 2020 is 3.2 and Scopus CiteScore rank 2020: Orthopedics and Sports Medicine is 87/262.

RESPONSIBLE EDITORS FOR THIS ISSUE

Production Editor: Lin-YuTong Wang; Production Department Director: Xiang Li; Editorial Office Director: Jin-Lai Wang.

NAME OF JOURNAL

World Journal of Orthopedics

ISSN

ISSN 2218-5836 (online)

LAUNCH DATE

November 18, 2010

FREQUENCY

Monthly

EDITORS-IN-CHIEF

Massimiliano Leigheb

EDITORIAL BOARD MEMBERS

<http://www.wjgnet.com/2218-5836/editorialboard.htm>

PUBLICATION DATE

September 18, 2021

COPYRIGHT

© 2021 Baishideng Publishing Group Inc

INSTRUCTIONS TO AUTHORS

<https://www.wjgnet.com/bpg/gerinfo/204>

GUIDELINES FOR ETHICS DOCUMENTS

<https://www.wjgnet.com/bpg/GerInfo/287>

GUIDELINES FOR NON-NATIVE SPEAKERS OF ENGLISH

<https://www.wjgnet.com/bpg/gerinfo/240>

PUBLICATION ETHICS

<https://www.wjgnet.com/bpg/GerInfo/288>

PUBLICATION MISCONDUCT

<https://www.wjgnet.com/bpg/gerinfo/208>

ARTICLE PROCESSING CHARGE

<https://www.wjgnet.com/bpg/gerinfo/242>

STEPS FOR SUBMITTING MANUSCRIPTS

<https://www.wjgnet.com/bpg/GerInfo/239>

ONLINE SUBMISSION

<https://www.f6publishing.com>

Jones type fifth metatarsal fracture fixation in athletes: A review and current concept

Mohammad Albloushi, Amer Alshamqiti, Mohammad Qasem, Andreas Abitbol, Thomas Gregory

ORCID number: Mohammad Albloushi 0000-0002-1759-6803; Amer Alshamqiti 0000-0003-0226-3237; Mohammad Qasem 0000-0001-8271-2404; Andreas Abitbol 0000-0001-5983-2221; Thomas Gregory 0000-0001-6292-0177.

Author contributions: Albloushi M performed the majority of the writing; Alshamqiti A contributed to the writing; Qasem M assisted in the editing of the text; Abitbol A and Gregory T provided critical expertise and input into the material of the text.

Conflict-of-interest statement: The authors have no conflicts of interest to declare.

Open-Access: This article is an open-access article that was selected by an in-house editor and fully peer-reviewed by external reviewers. It is distributed in accordance with the Creative Commons Attribution NonCommercial (CC BY-NC 4.0) license, which permits others to distribute, remix, adapt, build upon this work non-commercially, and license their derivative works on different terms, provided the original work is properly cited and the use is non-commercial. See: <http://creativecommons.org/licenses/by-nc/4.0/>

Manuscript source: Unsolicited

Mohammad Albloushi, Amer Alshamqiti, Andreas Abitbol, Thomas Gregory, Department of Orthopaedic Surgery, Avicenne Teaching Hospital, Assistance Publique-Hôpitaux de Paris, University Sorbonne-Paris-Nord, Sorbonne Paris Cité +33, France

Mohammad Qasem, Al-Razi Hospital, Ministry of Health, State of Kuwait, Kuwait City 00965, Kuwait

Corresponding author: Mohammad Qasem, PhD, Physiotherapist, Al-Razi Hospital, Ministry of Health, State of Kuwait, Jamal Abdunnasser Street, Al Solaiyebkhat Area 5, Kuwait City 00965, Kuwait. doctorqasem@hotmail.com

Abstract

Jones type fifth metatarsal fracture is a common occurrence among athletes at all levels. These fractures may occur due to several mechanisms, but inversions and twisting injuries are considered some of the leading causes in sports. However, while Jones fracture incidences are frequent in the sporting world, there is still a lack of consensus on how such fractures should be effectively managed. There are numerous treatment options for patients with fifth metatarsal Jones fractures. The role of nonoperative treatment remains controversial, with concerns about delayed union and nonunion. Surgical stabilization of metatarsal Jones fractures is therefore often recommended for athletes, as it is often associated with a low number of complications and a higher rate of union than nonoperative management. This review will focus on literature regarding the prevalence of Jones type fifth metatarsal fracture, alongside the efficacy of both conservative and surgical treatment within this population.

Key Words: Athletes; Surgery; Fifth Metatarsal; Jones fracture; Rehabilitation; Fracture

©The Author(s) 2021. Published by Baishideng Publishing Group Inc. All rights reserved.

Core Tip: Jones type fifth metatarsal fractures are a common injury among athletes. However, there remains a lack of consensus on the effective management of such fractures, especially in a demanding population group where time is often of the essence. Treatment recommendations often depend on the location and understanding of the fracture in addition to the patient's underlying state of health and other factors

manuscript

Specialty type: Orthopedics**Country/Territory of origin:** Kuwait**Peer-review report's scientific quality classification**

Grade A (Excellent): 0

Grade B (Very good): 0

Grade C (Good): C

Grade D (Fair): 0

Grade E (Poor): 0

Received: February 9, 2021**Peer-review started:** February 9, 2021**First decision:** March 31, 2021**Revised:** April 14, 2021**Accepted:** July 30, 2021**Article in press:** July 30, 2021**Published online:** September 18, 2021**P-Reviewer:** Silvestre-Muñoz A**S-Editor:** Gao CC**L-Editor:** Filipodia**P-Editor:** Wang LYT

that influence surgical risk and outcome. The role of nonoperative treatment is still controversial, but surgical stabilization of metatarsal Jones fractures is often recommended for athletes and other high-demand population groups.

Citation: Albloushi M, Alshamqiti A, Qasem M, Abitbol A, Gregory T. Jones type fifth metatarsal fracture fixation in athletes: A review and current concept. *World J Orthop* 2021; 12(9): 640-650

URL: <https://www.wjgnet.com/2218-5836/full/v12/i9/640.htm>

DOI: <https://dx.doi.org/10.5312/wjo.v12.i9.640>

INTRODUCTION

Jones type fifth metatarsal fractures are a common occurrence among athletes at all levels. These fractures may occur due to several movement mechanisms, but inversions and twisting injuries are considered some of the leading causes in sports. However, while this fracture type occurs frequently in the sporting world, there is still a lack of consensus on how such fractures should be effectively managed, especially in an industry where time is often of the essence. Treatment recommendations often depend on the location and understanding of the fracture anatomy in addition to the patient's underlying health. Several research studies have demonstrated that nonoperative treatment pathways can be used successfully in these types of fractures, although concern exists about delayed and nonunion fractures. This remains a controversial area. Surgical treatment is often recommended for athletes, as it is often associated with a low number of complications and a higher rate of union than nonoperative treatment. This review focuses on defining this fracture subtype and the efficacy of both operative and nonoperative treatment options. Operative intervention is further evaluated primarily with respect to screw *vs* plate fixation techniques.

OVERVIEW OF THE TYPES OF FIFTH METATARSAL JONES FRACTURES

Jones fracture was first described in 1902 by Sir Robert Jones as a unique type of fracture of the base of the fifth metatarsal; he described this fracture as being 1/3 inch from the base[1]. Statistically, metatarsal fractures account for a significant proportion of foot injuries, comprising 35% of fractures within the foot region and approximately 5%-6% of all skeletal injuries, with an estimated incidence of 6.7 per 10000 individuals [2]. In the normal adult population, females tend to sustain the injury more than males at a ratio of 2:1; however, in sports, which are primarily dominated by males, these injuries are more common among males[3-5]. In their review of foot injuries among athletes, Boutefnouchet *et al*[3] noted that these fractures are 10 times more likely to occur in males, with a mean age of 26 years. In this case, the high prevalence of these injuries in the sporting world was attributed to the strenuous nature of activities, resulting in the application of specific stresses within this region, such as during jumping, running, and tackling.

Anatomically, fifth metatarsal fractures are classified into two groups. According to Sarpong *et al*[2], the two groups to which these fractures belong are proximal and distal fractures. This classification is based on the fractures' healing potential as dictated by the blood supply to the affected zones. The blood supply to the proximal fifth metatarsal was first investigated by Bowes and Buckley[6], using a cadaver model for the study. Their findings discovered that blood supply within this region emanates from three possible sources: the nutrient artery, metaphyseal perforators, and periosteal arteries.

Expansion of the classification system by Torg *et al*[7] resulted in the simplification of how proximal fifth metatarsal fractures are classified. Bowes and Buckley noted that this simplification resulted in the proximal diaphysis distal classification as tuberosity, which made it part of the Jones fracture[6]. Under this system, three categories of Jones fractures emerge: Type I (acute proximal metatarsal fracture), Type II (delayed union proximal metatarsal fracture), and Type III (nonunion proximal metatarsal fracture).

Type I (acute proximal metatarsal fracture)

Type I fractures feature a fracture line and lacks intramedullary sclerosis differentiation. According to many researchers[8-11], the history of injuries in this group should include no history of a previous fracture. However, in some cases, patients may report the existence of previous pain. In other words, at the location of previous pain, the fracture is often presumed to be Type I, and due to the pain being on the lateral cortex, patients often experience limited movement.

Type II (delayed union) proximal metatarsal fracture

As noted by Do *et al*[8], Cheung and Lui[9], Saluta *et al*[12], Type II fractures are different from Type I due to the presence of an earlier injury that is characterized by a widened fracture line and the presence of intramedullary sclerosis.

Type III (non-union proximal metatarsal fracture)

Type III fractures' distinguishing features include a "complete obliteration of the medullary canal by sclerotic bone with a history of repetitive trauma and recurrent symptoms"[6]. In other words, this type of fracture contains a complete disconnection of the adjacent bones, and the treatment of this type of fracture often requires corrective surgery (Table 1).

ANATOMY AND PATHOPHYSIOLOGY OF FIFTH METATARSAL FRACTURES

Understanding foot anatomy is crucial in evaluating an effective treatment plan for athletes with Jones fractures. The fifth metatarsal is distinguished from other lesser metatarsals by the presence of a tendon insertion at the base comprising the peroneus brevis, which inserts dorsally on the proximal tubercle, and the peroneus tertius, which dorsally inserts the diaphyseal junction[2]. In addition, the plantar fascia is attached to the tubercle.

The pathophysiology of fifth metatarsal fractures is mainly represented by acute trauma. According to studies by Do *et al*[8], the mechanism of pain in patients (athletes) with Zone 1 fractures is often experienced during supination with plantar flexion (rolling motion of the outside edge of the foot during a step), such as during pitching in baseball. This type of movement often results in a pull of the plantar fascia lateral band, which results in pain. In Zone 2, injuries often emanate from plantar flexing of the forefoot. In contrast, in Zone 3 injuries, the pain usually originates from repetitive trauma. In the case of athletes, it could be due to continuous pressure when a player jumps, runs, or tackles an opponent. Notably, according to a recent study by Benjamin *et al*[13], athletes with cavovarus feet are prone to repetitive trauma, which results in Zone 3 injuries. This study proposes the theory that the physical structure of an athlete's foot could be one of the significant determinants of Jones-type fracture prevalence.

Similarly, according to other studies, there is a relationship between cavovarus feet and the development of both Jones fractures and stress fractures in the fifth metatarsal. For instance, in their study, "The Cavovarus Foot and Its Association with Fractures of the Fifth Metatarsal," Fuchs *et al*[14] noted that patients with acute Jones fractures presented with radiographic hindfoot varus. Some studies have suggested that since Zone 2 and Zone 3 may exhibit similar characteristics, it is not necessary to differentiate between them. For instance, Sarpong *et al*[2] provides an example of distal diaphyseal fractures, which occur when excessive force is applied within a position of plantar flexion, and an inversion injury occurs. In athletes, such as sprinters or volleyball players, such an injury could occur during jumping, in which toes are used, or an inversion injury is sustained with the ankle in a fully plantar flexed position. In summary, these injuries among athletes are common, as most field actions involve a broad utilization of foot movements, resulting in stress to the fifth metatarsal.

TREATMENT

Treatment options for Jones type fifth metatarsal fracture are based on the zone of the injury, comorbidities of the injured patient, and — if a sub-acute presentation — radiographic signs of healing. Acute Zone 1 injuries are mostly treated conservatively with protected weight-bearing medical boots, such as the air cast variety, hard-soled

Table 1 Summary of fifth metatarsal fractures

Class	Description
Zone 1	(1) Proximal tubercle avulsion; (2) Long plantar ligament leads to a lateral band of the plantar fascia or the peroneus Brevis's contraction; (3) May extend into the Cubo-metatarsal joint; and (4) Nonunion is uncommon
Zone 2 (Jones fracture)	(1) Metaphyseal-diaphyseal junction; (2) Involves the fourth and fifth metatarsal articulation; (3) Vascular watershed area; (4) Acute injury; and (5) Increased risk of nonunion
Zone 3	(1) Proximal diaphyseal fracture; (2) Distal to the fourth and fifth metatarsal articulation; (3) Stress fracture in athletes; (4) Associated with cavovarus foot deformities, or sensory neuropathies; and (5) Increased risk of nonunion

shoes, or casts. These devices are designed primarily for a patient's comfort rather than fracture stability, and can therefore be discontinued when the patient feels the pain has subsided. Operative treatment modalities are not first-line pathways for patients with a Zone 1 injury. In contrast, the level of severity in Zone 2 and Zone 3 fractures tends to be higher than that in Zone 1 fractures and may have better outcomes with surgical management.

Compared with the general population, athletes often require different treatment types due to their specific injury patterns and higher demands. According to a study conducted by Japjec *et al*[15] on how athletes require different treatments of injuries to the fifth metatarsal, it was suggested that on average, nonoperative treatment pathways took as long as 20 wk to heal completely, which was not a feasible amount of time for both the players and their teams[15]. In their analysis, the researchers proposed a new classification of these injuries, which included metaphyseal (Zone 1 and the majority of Zone 2) and metadiaphyseal fractures (remnants of Zone 2 and Zone 3) (see Table 2). However, the exact anatomical boundaries within this classification are not clearly defined and need further research. Nonetheless, the study successfully demonstrated that given the frequency of fractures in athletes, surgical treatment plans are efficient in treating zone 2 and 3 fifth metatarsal Jones fractures.

An analysis of the efficacy of nonsurgical and surgical treatment plants was recently conducted in a virtual study by Mirza *et al*[16]. They aimed to analyze the outcomes within the different treatment pathways of patients with basal fifth metatarsal fractures[16]. Out of the 270 study participants, 73.6% had Zone 1 fractures, 22.2% had Zone 2 fractures, and 4.2% had Zone 3 fractures. The researchers concluded that conventional treatment methods for Zones 1 and 2 took longer to cure patients (12 wk) than surgical procedures (Zone 3), which reduced the healing time by 50%. These findings support following a surgical pathway from the outset in the treatment of athletes with fifth metatarsal Jones fractures.

SURGICAL TECHNIQUES

There are several operative techniques described in the literature for fifth metatarsal Jones fractures. The choice of technique utilized is primarily dependent on the characteristics of the fracture(s). The techniques described include intramedullary screws, closed reduction, and cross-pinning with K-wire (Kirschner-wire) fixation, bone grafting, and internal fixation with a mini fragment plate and screws[6,17,18]. We focus on comparing outcomes between fixation techniques that primarily utilize screws or plates.

Surgical techniques using screws

Surgical techniques are common among athletes due to the short time it takes to heal these fractures and the lower possibility of nonunion. Studies by Watson *et al*[19], Lareau *et al*[20], Willegger *et al*[21], and D'Hooghe *et al*[22] assert that intramedullary screws and aggressive rehabilitation protocols have become popular among professional athletes seeking to return to the field after experiencing Zone 2-3 fifth metatarsal Jones fractures[23,24]. According to these studies, this technique's main advantage is that it is minimally invasive in addition to the short healing time needed and the accelerated mobility. DeLee, Evans, and Julian were the first to demonstrate the efficacy of percutaneous intramedullary screw fixation in a 1983 study titled "Stress Fracture of the Fifth Metatarsal"[6,25,26]. The study focused on utilizing 4.5-mm malleolar screws in diaphyseal stress fracture fixation in 10 athletes in which they reported an average healing time of 7.5 wk. This healing time allowed for adequate time for rehabilitation and return to sporting activities.

Table 2 Stewart classification of Jones fracture[16]

Stewart classification	
Type 1	Extra-articular fracture between the metatarsal base and diaphysis
Type 2	Intra-articular fracture of the metatarsal base
Type 3	Avulsion fracture
Type 4	Comminuted fractures with intra-articular extension
Type 5	Partial avulsion of the metatarsal base with or without a fracture

There are currently various types of intramedullary screws in use by surgeons in the fixation of fifth metatarsal Jones fractures. Among the significant options of this technique include solid and cannulated screws, whose individual performance has been studied. For instance, Bowes and Buckey noted that cannulated screws offer better precision and ease of use when placed over a guidewire[6]. However, some studies have argued that cannulated screws present an increased risk of refracture.

Studies have also evaluated the subsequent failure of cannulated screws in delayed unions, nonunion, and acute Jones fractures. For instance, Bowes and Buckley noted that intramedullary screw fixation using 4.5-mm malleolar screws resulted in refracture and may cause delayed union or non-union in Jones fractures[6]. However, in a round table discussion by Carpenter *et al*[27] and recent studies by Bryant *et al*[28], O'Malley *et al*[29] and Tan *et al*[30], this method offers a higher rate of healing among athletes, with lower re-occurrence of fractures. Thus, based on this argument, it could be concluded that the utilization of larger diameters during surgery may help to prevent future fracture.

Surgical techniques using plates (plantar plate fixation)

An alternative to intramedullary screws in fixing Jones fractures is the plantar plate fixation surgical technique. Plantar plate fixation, as reported by Duplantier *et al*[31], Mitchell *et al*[32], Young *et al*[33], and Miller *et al*[34], describes the procedure of plantar plate fixation. Researchers note that the process involves the positioning of a contoured plate[19] across the fracture site, such that the locking holes are aligned on the proximal side (the oblong). In contrast, the remaining locking holes are aligned with the distal side of the injury. One of the noted advantages of the plantar plate fixation method in treating Jones fractures is that it offers stability to the broken bones, accelerating healing. In addition, the procedure provides one of the fastest ways of managing this type of fracture among athletes.

However, several studies on the advantages and disadvantages of plantar plate fixation techniques have indicated that the method presents some risks regarding nonunion and the possibility of injuries reoccurring in the same location. According to Bernstein *et al*[35] and Haslan *et al*[36], with tension-side plating, there have been cases of pain and persistent fracture nonunion, especially in the treatment of stress fractures among athletes. Furthermore, studies indicate that the procedure requires the addition of calcaneus autografts to optimize the healing process. According to Mitchell *et al*[32], previously reported risks associated with percutaneous calcaneal autograft harvesting are currently low. This finding has improved the performance of plantar plating fixation in the treatment of fifth metatarsal Jones fractures. In addition to the issues with biomechanical principles, the literature also suggests that plantar plating is associated with hardware prominence. According to Mitchell *et al*[32], hardware prominence typically occurs due to the surgeon's failure to confirm that the plate used is adequately aligned against the cortex of the bone. Failure to position the plate properly could also result in nonunion, irritation, and an increased risk of refracture. These risks for plantar plate fixation can be reduced by using low-profile screws and plates that are accurately contoured to the cortex. This ensures that the tension side of the fracture is stabilized[37]. Adoption of these techniques allows for plantar plating to be used with good outcomes in high-demand patients, such as athletes.

POST-OPERATION MANAGEMENT PROTOCOL

As mentioned above, surgical procedures might offer faster recovery among athletes who have suffered fifth metatarsal Jones fractures. Recovery takes an average of 3-4

wk, depending on the postoperative procedures[38]. To facilitate healing, specific protocols need to be followed. Watson *et al*[38] stated that postoperative rehabilitation can be divided into five phases, as illustrated in Table 3 and Figure 1.

POSTOPERATIVE COMPLICATIONS

Postoperative complications are common, and some are higher within the athlete population. The risk of injury to the sural nerve and its branches during procedures, such as intramedullary screw fixation, is well recognized. However, historically, injury to the sural nerve or any of its branches has not been reported as a significant postoperative complication arising from the fixation of Jones fractures[9]. Nonetheless, despite the lack of reporting, several studies have indicated the occurrence of unexplained postoperative pain and paraesthesia over the lateral aspect of the foot, which fails to subside even after the removal of the screw or the plate. In such cases, researchers have often concluded that the occurrence of such pain is a result of nerve damage from surgical intervention.

Failure to note the natural curvature of the bone during surgery has been considered a major cause of nerve injury after surgical treatment. As noted by Aynardi *et al*[39], despite the success of intramedullary screw fixation of the fifth metatarsal for metaphyseal-diaphyseal and diaphyseal fractures, the size, shape, and quality of the bone cortices are crucial in preventing surgical injuries to the lateral dorsal cutaneous nerve. According to the researchers, failure to consider the natural curvature of the fifth metatarsal bone during surgery could impede the placement of a guidewire, which can lead to intraoperative complications, such as nerve damage. Therefore, to reduce the risk of nerve injury, surgeons should ensure the proper entry point of the guidewire and screw with a correct trajectory within the medullary canal. This is best achieved by a proper understanding of the patients' specific bony anatomy.

Both delayed and nonunion are commonly attributed to the use of smaller screws in surgery. Watson *et al*[38] noted that delayed unions in Zone 2 and 3 fractures are often a result of choosing screws that are smaller than 4.5 mm in diameter. In the case of athletes, according to Wukich *et al*[40], it is advisable to use larger solid screws as a way of countering the higher amount of torsional stress directed towards the fracture site. Similarly, in the case of nonunion and refractures in Zones 2 and 3, Cheung and Lui[9] recommend treatment with medullary curettage and intramedullary screw fixation or inlay grafting. However, in this case, revision of the previous screw fixation that resulted in complications should be performed with larger diameter screws in addition to reaming of the medullary canal.

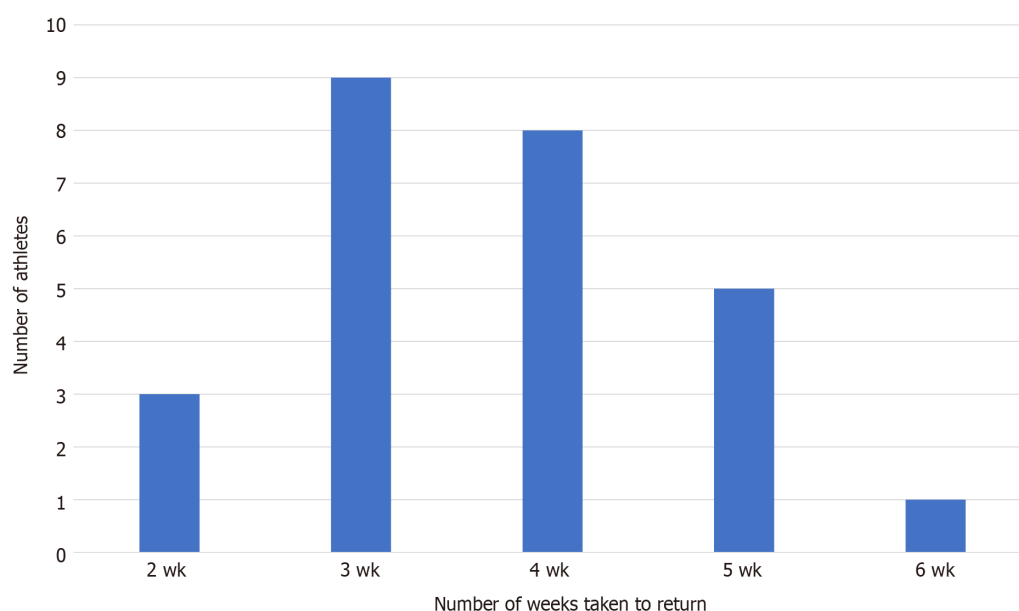
Other possible postoperative complications include wound infection, impingement by a prominent screw head, rupture of the peroneus brevis tendon, metatarsalgia, iatrogenic fracture of the metatarsal bone, and the screw missing the medullary canal. Cheung and Lui[9] summarized specific methods of avoiding and managing these complications. First, wound infection and tendon nerve injury can be avoided by careful soft tissue handling during surgery using implants with low profiles. Second, impingement by the screw head can be avoided by adequate countersinking of the cortex before the insertion of the screw and be further addressed by athletes using larger and spacious shoes. Third, screws missing the medullary canal can be avoided through the use of proper surgical techniques, choosing the correct implant, and having a proper understanding of the patients' bony anatomy. Last, the major cause of postoperative metatarsalgia is fibrosis of the joints and tendons adjacent to the site of the operation.

NON-SURGICAL TREATMENT

There are several nonsurgical treatment plans used for fifth metatarsal Jones fractures. These modalities vary by anatomical region of the fracture, patient history, and radiological findings[41-43]. Evidence-based medicine has assisted in the tailoring of individual treatment of metatarsal fractures. For example, as highlighted by several studies, some cases of nondisplaced and neck fractures of the fifth metatarsal are often treated nonoperatively. The preference to treat these injuries using nonsurgical options indicates that their level of severity is low. Examples of nonsurgical treatment options include walking casts, elastic dressings, rigid shoes, hard plastic cast shoes with weight-bearing, and posterior splints[44,45]. The effectiveness of these options depends on both the nature of the treatment option and the type of patient.

Table 3 Postoperative rehabilitation protocol for athletes

Phases of postoperative rehabilitation for fifth metatarsal Jones fractures	
Phase I	After surgery, the patient can toe-touch using weight-bearing medical aids, such as walking boots or crutches. Discontinuation of use of these aids depends on how fast an individual heals or when they can tolerate body weight. Patients are required to use bone simulators at least twice a day and perform four-way ankle-resisted exercises two times a day. These exercises include plantar flexion, dorsiflexion, inversion, and eversion[18]
Phase II	In this phase, the patient can tolerate his or her full weight and can now use a walking boot. Bone simulators and ankle exercises are limited to twice a day. Furthermore, the patient participates in training using underwater treadmills with sessions lasting approximately 20 min at a speed of between 2.5 and 3.0 mph. These parameters are adjusted per the ability of the patient to tolerate an increase. "By the end of Phase II rehabilitation, the patient should be able to do interval training for 20 min in waist-deep water. An example of an interval training protocol is as follows: 60 seconds at a 5-6 mph pace followed by a 90-s run at 7-8 mph with jet resistance at approximately 45%-60% weight bearing"[19,38]
Phase III	At this stage, walking boots are replaced with cross-training shoes with rigid or orthotic inserts. Patients are gradually introduced to single-calf exercises in combination with dorsiflexion stretching and single-leg proprioception training. Progression to full weight bearing is continued and managed using limited change of direction and position exercises. For at least two times a day, the patient is involved in bone stimulation and resistance ankle routines
Phase IV	Patients can use professional sporting shoes such as cleats or boots with rigid or orthotic inserts. Full-weight running is combined with drill works that feature a position-specific change of direction. Single-leg plyometric exercises are included. Additionally, the athlete is required to continue using "bone stimulator, resisted ankle exercises, single-leg calf raises, dorsiflexion stretching exercises, and single-leg plyometric exercises"[19,38]. This phase aims to facilitate a limited return to regular training
Phase V	The patient can now participate in full training. The bone simulator is used twice a day combined with a regular training routine until the patient is fully recovered

**Figure 1 Number of athletes returning to play vs weeks in rehabilitation[38].**

Recently, various studies have attempted to statistically analyze patients' satisfaction with nonoperative treatment pathways in treating acute Jones fractures. For instance, in studies undertaken by Sesti *et al*[46], it was established that on average, 60% to 70% of patients with acute Jones fracture were very satisfied with nonoperative procedures, 28% were satisfied, 8% reasonably satisfied, and 4% were dissatisfied (see Figure 2). These findings indicate that the choice for nonsurgical treatment is often based on perception, and, in some cases, is at the discretion of the patient.

The literature suggests that there is a significant variation in the effectiveness of conservative treatment within different fracture subtypes. Nondisplaced Zone 1 fractures at the fifth metatarsal base are often treated using protected weight-bearing methods, such as leg casts, that offer low nonunion rates of between 0.5% and 2.1% [47]. In other studies, it has been illustrated that nonoperative procedures for acute Zone 2 and 3 fractures result in longer recuperation times and a higher risk of refracturing. As highlighted in Figure 3, the average times to union for "tuberosity fractures, Jones, stress, segmental shaft, and oblique distal shaft/neck fractures were 3.7, 3.5, 4.8, 3.6 and 3.4 mo, respectively"[6]. Thus, compared with the surgical method, non-operative techniques are not feasible for professional athletes due to their inability to achieve union in Zone 2 and 3 fractures within acceptable timeframes.

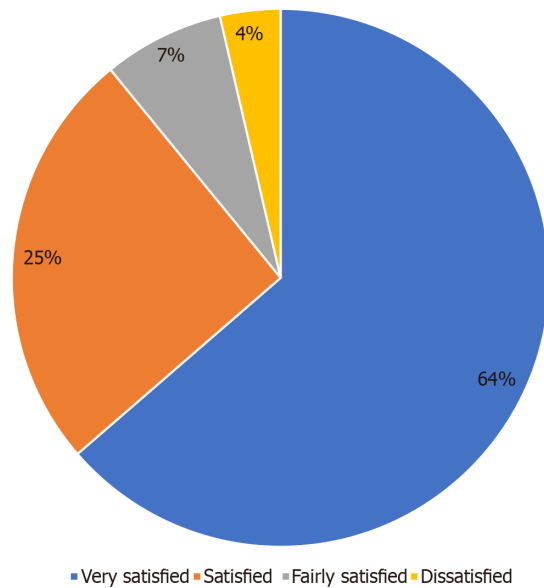


Figure 2 Patient Satisfaction with non-operative treatment of fifth metatarsal Jones fractures.

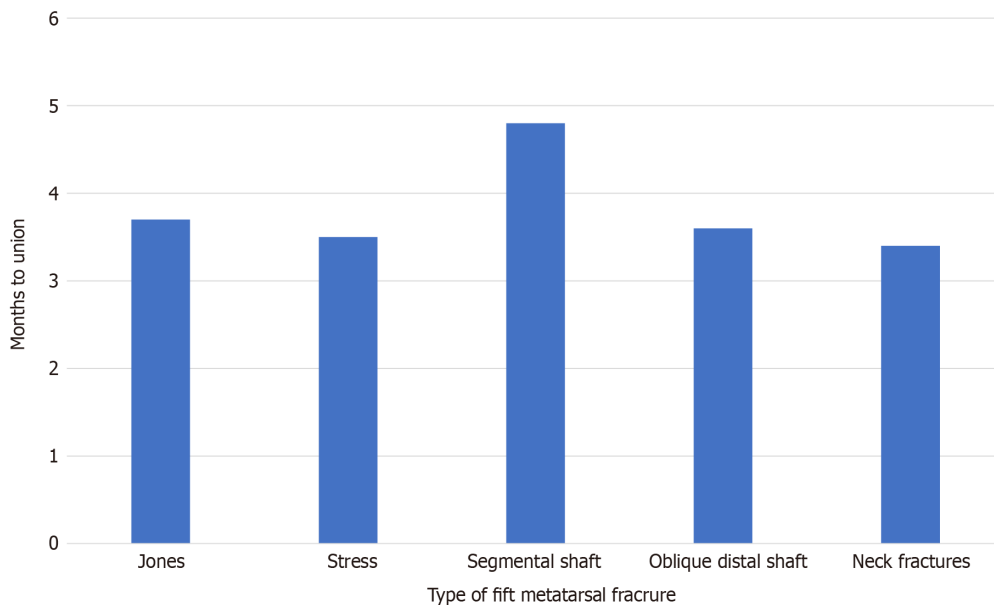


Figure 3 Average number of months to fracture union.

REHABILITATION

Several studies have described and issued recommendations on specific rehabilitation protocols to be followed during the recuperation period. In their research, Marecek *et al*[48] detailed their preferred rehabilitation protocol based on clinical data on patients with acute Jones fractures[48]. The authors note that for patients with Zone 1 fractures, non-weight-bearing options could be used in the first 3 wk after the injury. Similarly, Rhim and Hunt[49], along with Slater *et al*[50] and Qi *et al*[51], suggest the placement of the affected foot in a cast or boot for 2-3 wk. Once a union is observed, the patient can be transitioned to physical therapy, with a focus on regaining strength through eccentric and concentric open-chain exercises or muscle-specific workouts. Non-impact activities, such as elliptical trainers or static bicycles and deep-water running activities, are useful for athletes recovering from acute Jones fractures.

CONCLUSION

As discussed, there are numerous treatment options for patients with fifth metatarsal Jones fractures. For the general population, non-time-sensitive approaches, such as using a short leg cast with immobilization, could be used for treatment. However, for active individuals, such as athletes in competitive sports, the need to quickly return to play often calls for more aggressive treatment plans. Owing to various reports of faster healing and return to play, treatment options among athletes with Jones fractures have significantly shifted from nonoperative procedures to surgical options that include intramedullary screw fixation and plantar plate fixations. These procedures offer predictable union rates in addition to minimum periods of immobilization, which makes them ideal techniques for managing fifth metatarsal Jones fractures in the sporting world.

REFERENCES

- 1 **Jones R.** I. Fracture of the Base of the Fifth Metatarsal Bone by Indirect Violence. *Ann Surg* 1902; **35**: 697-700.2 [PMID: [17861128](#)]
- 2 **Sarpong NO**, Swindell HW, Trupia EP, Vosseller JT. Metatarsal fractures. *Foot Ankle Orthop* 2018; **3** [DOI: [10.1177/2473011418775094](#)]
- 3 **Boutefnouchet T**, Budair B, Backshayesh P, Ali SA. Metatarsal fractures: a review and current concepts. *Trauma* 2014; **16**: 147-63 [DOI: [10.1177/1460408614525738](#)]
- 4 **Thomson A**, Akenhead R, Whiteley R, D'Hooghe P, Van Alsenoy K, Bleakley C. Fifth metatarsal stress fracture in elite male football players: an on-field analysis of plantar loading. *BMJ Open Sport Exerc Med* 2018; **4**: e000377 [PMID: [29955378](#) DOI: [10.1136/bmjsem-2018-000377](#)]
- 5 **Matsuda S**, Fukubayashi T, Hirose N. Characteristics of the Foot Static Alignment and the Plantar Pressure Associated with Fifth Metatarsal Stress Fracture History in Male Soccer Players: a Case-Control Study. *Sports Med Open* 2017; **3**: 27 [PMID: [28785961](#) DOI: [10.1186/s40798-017-0095-y](#)]
- 6 **Bowes J**, Buckley R. Fifth metatarsal fractures and current treatment. *World J Orthop* 2016; **7**: 793-800 [PMID: [28032031](#) DOI: [10.5312/wjo.v7.i12.793](#)]
- 7 **Torg JS**, Balduini FC, Zelko RR, Pavlov HE, Peff TC, Das M. Fractures of the base of the fifth metatarsal distal to the tuberosity. Classification and guidelines for non-surgical and surgical management. *J Bone Joint Surg Am* 1984; **66**: 209-214 [DOI: [10.2106/00004623-198466020-00007](#)]
- 8 **Do DB**, Sprouse RA, Armen J. Diagnosis and management of common foot fractures. *Am Fam Physician* 2016; **93**: 183-191 [DOI: [10.1201/b15168-23](#)]
- 9 **Cheung CN**, Lui TH. Proximal Fifth Metatarsal Fractures: Anatomy, Classification, Treatment and Complications. *Arch Trauma Res* 2016; **5**: e33298 [PMID: [28144601](#) DOI: [10.5812/atr.33298](#)]
- 10 **Niu S**, Mirza F, Schwartz A, Labib S. An Anatomic Approach for Intramedullary Screw Fixation of Fifth Metatarsal Fracture: A Clinical and Radiographic Study. *Foot Ankle Orthop* 2019; **4** [DOI: [10.1177/2473011419s00323](#)]
- 11 **Baumfeld D**, Macedo BD, Nery C, Esper LE, Filho MA. Anterograde percutaneous treatment of lesser metatarsal fractures: technical description and clinical results. *Rev Bras Ortop* 2012; **47**: 760-764 [PMID: [27047897](#) DOI: [10.1016/S2255-4971\(15\)30035-5](#)]
- 12 **Saluta JR**, Nunley JA, Scott A. Percutaneous Fixation of Proximal Fifth Metatarsal Fractures. In: Scuder G, Tria A. Minimally Invasive Surgery in Orthopedics. Springer, Cham, 2015: 1-7
- 13 **Benjamin G**, Anne-Laure M, Leduc S, Marie-Lyne N. Subtle Cavovarus Foot: A Missed Risk Factor for Chronic Foot and Ankle Pathologies. *Int J Foot Ankle* 2020; **4** [DOI: [10.23937/2643-3885/1710048](#)]
- 14 **Fuchs D**, Kane J, Brodsky J, Royer C, Zide J, Reddy V, Bhimani A, Daoud Y. The Cavovarus Foot and It's Association with Fractures of the Fifth Metatarsal. *Foot Ankle Orthop* 2017; **2** [DOI: [10.1177/2473011417s000173](#)]
- 15 **Japjec M**, Starešinić M, Starjački M, Žgaljardić I, Štivičić J, Šebečić B. Treatment of proximal fifth metatarsal bone fractures in athletes. *Injury* 2015; **46** Suppl 6: S134-S136 [PMID: [26563480](#) DOI: [10.1016/j.injury.2015.10.052](#)]
- 16 **Mirza Z**, Pillai A, Alqubaisi M. How are fifth metatarsal fractures managed by the virtual fracture clinic. *Res Rev Insights* 2018; **2**: 1-7 [DOI: [10.15761/rri.1000144](#)]
- 17 **Nolte P**, Anderson R, Strauss E, Wang Z, Hu L, Xu Z, Steen RG. Heal rate of metatarsal fractures: A propensity-matching study of patients treated with low-intensity pulsed ultrasound (LIPUS) vs. surgical and other treatments. *Injury* 2016; **47**: 2584-2590 [PMID: [27641221](#) DOI: [10.1016/j.injury.2016.09.023](#)]
- 18 **Le M**, Anderson R. Zone II and III fifth metatarsal fractures in athletes. *Curr Rev Musculoskelet Med* 2017; **10**: 86-93 [PMID: [28220354](#) DOI: [10.1007/s12178-017-9388-5](#)]
- 19 **Watson S**, Trammell A, Tanner S, Martin S, Bowman L. Early Return to Play After Intramedullary Screw Fixation of Acute Jones Fractures in Collegiate Athletes: 22-Year Experience. *Orthop J Sports Med* 2020; **8**: 2325967120912423 [PMID: [32426399](#) DOI: [10.1177/2325967120912423](#)]
- 20 **Lareau CR**, Hsu AR, Anderson RB. Return to Play in National Football League Players After

- Operative Jones Fracture Treatment. *Foot Ankle Int* 2016; **37**: 8-16 [PMID: [26353796](#) DOI: [10.1177/1071100715603983](#)]
- 21 **Willegger M**, Benca E, Hirtler L, Kasperek MF, Bauer G, Zandieh S, Windhager R, Schuh R. Evaluation of Two Types of Intramedullary Jones Fracture Fixation in a Cyclic and Ultimate Load Model. *J Orthop Res* 2020; **38**: 911-917 [PMID: [31743452](#) DOI: [10.1002/jor.24530](#)]
- 22 **D'Hooghe P**, Caravelli S, Massimi S, Calder J, Dzendrowskyj P, Zaffagnini S. A novel method for internal fixation of basal fifth metatarsal fracture in athletes: a cadaveric study of the F.E.R.I. technique (Fifth metatarsal, Extra-portal, Rigid, Innovative). *J Exp Orthop* 2019; **6**: 45 [PMID: [31713049](#) DOI: [10.1186/s40634-019-0213-5](#)]
- 23 **Varner KE**, Harris JD. The Proximal Fifth Metatarsal Metadiaphyseal Jones Fracture: Intramedullary Screw vs Plantar Plate. *Oper Tech Sports Med* 2017; **25**: 59-66 [DOI: [10.1053/j.otsm.2017.03.009](#)]
- 24 **Sherman T**, Carpinello M, Postma WF. The Approach to Proximal Fifth Metatarsal Fractures in Athletes. *Clin Res Foot Ankle* 2016 [DOI: [10.4172/2329-910x.1000181](#)]
- 25 **Kawashima I**, Yamaga A, Kawai R, Hoshino Y, Ishizuka S. Recurrent fifth metatarsal stress fractures in a professional soccer player with hypoparathyroidism: a case report. *BMC Musculoskelet Disord* 2020; **21**: 347 [PMID: [32493404](#) DOI: [10.1186/s12891-020-03383-2](#)]
- 26 **Wang X**, Zhang C, Wang C, Huang JZ, Ma X. Accurate determination of screw position in treating fifth metatarsal base fractures to shorten radiation exposure time. *Singapore Med J* 2016; **57**: 619-623 [PMID: [26767892](#) DOI: [10.11622/smedj.2015196](#)]
- 27 **Carpenter B**, Bohay D, Early JS, Jennings M, Pomeroy G, Schuberth JM, Wukich DK. Cannulated Screws. *J Foot Ankle Surg* 2019; **58**: 333-336 [PMID: [30612868](#) DOI: [10.1053/j.jfas.2018.08.035](#)]
- 28 **Bryant T**, Beck DM, Daniel JN, Pedowitz DI, Raikin SM. Union Rate and Rate of Hardware Removal Following Plate Fixation of Metatarsal Shaft and Neck Fractures. *Foot Ankle Int* 2018; **39**: 326-331 [PMID: [29513603](#) DOI: [10.1177/1071100717751183](#)]
- 29 **O'Malley M**, DeSandis B, Allen A, Levitsky M, O'Malley Q, Williams R. Operative Treatment of Fifth Metatarsal Jones Fractures (Zones II and III) in the NBA. *Foot Ankle Int* 2016; **37**: 488-500 [PMID: [26781131](#) DOI: [10.1177/1071100715625290](#)]
- 30 **Tan EW**, Cata E, Schon LC. Use of a Percutaneous Pointed Reduction Clamp Before Screw Fixation to Prevent Gapping of a Fifth Metatarsal Base Fracture: A Technique Tip. *J Foot Ankle Surg* 2016; **55**: 151-156 [PMID: [26188626](#) DOI: [10.1053/j.jfas.2015.04.011](#)]
- 31 **Duplantier NL**, Mitchell RJ, Zambrano S, Stone AC, Delgado DA, Lambert BS, Moreno MR, Harris JD, McCulloch PC, Lintner DM, Varner KE. A Biomechanical Comparison of Fifth Metatarsal Jones Fracture Fixation Methods. *Am J Sports Med* 2018; **46**: 1220-1227 [PMID: [29466679](#) DOI: [10.1177/0363546517753376](#)]
- 32 **Mitchell RJ**, Duplantier NL, Delgado DA, Lambert BS, McCulloch PC, Harris JD, Varner KE. Plantar Plating for the Treatment of Proximal Fifth Metatarsal Fractures in Elite Athletes. *Orthopedics* 2017; **40**: e563-e566 [PMID: [28358977](#) DOI: [10.3928/01477447-20170327-04](#)]
- 33 **Young KW**, Kim JS, Lee HS, Jegal H, Park YU, Lee KT. Operative Results of Plantar Plating for Fifth Metatarsal Stress Fracture. *Foot Ankle Int* 2020; **41**: 419-427 [PMID: [31904259](#) DOI: [10.1177/1071100719895273](#)]
- 34 **Miller KA**, Chong ACM, Uglem TP. Variable Angle Locking Compression Plate as Alternative Fixation for Jones Fractures: A Case Series. *Kans J Med* 2019; **12**: 28-32 [PMID: [31191806](#)]
- 35 **Bernstein DT**, Mitchell RJ, McCulloch PC, Harris JD, Varner KE. Treatment of Proximal Fifth Metatarsal Fractures and Refractures With Plantar Plating in Elite Athletes. *Foot Ankle Int* 2018; **39**: 1410-1415 [PMID: [30079768](#) DOI: [10.1177/1071100718791835](#)]
- 36 **Haslan H**, Chi ZT, Yusoff MY. Decision Making in Management of Proximal Fifth Metatarsal Fracture: A Short Review. *Med Health-Kuala Lumpur* 2016; **11**: 131-138 [DOI: [10.17576/mh.2016.1102.03](#)]
- 37 **Granata JD**, Berlet GC, Philbin TM, Jones G, Kaeding CC, Peterson KS. Failed Surgical Management of Acute Proximal Fifth Metatarsal (Jones) Fractures: A Retrospective Case Series and Literature Review. *Foot Ankle Spec* 2015; **8**: 454-459 [PMID: [26130624](#) DOI: [10.1177/1938640015592836](#)]
- 38 **Watson GI**, Karnovsky SC, Konin G, Drakos MC. Optimal Starting Point for Fifth Metatarsal Zone II Fractures: A Cadaveric Study. *Foot Ankle Int* 2017; **38**: 802-807 [PMID: [28482680](#) DOI: [10.1177/1071100717702688](#)]
- 39 **Aynardi M**, Walley KC, Wisbeck JM. Intramedullary Screw Fixation of Jones Fracture: The Crucial Starting Point and Minimizing Complications. *Orthop J Harvard Med Sch* 2019; **20**: 42-45
- 40 **Wukich DK**, Rhim B, Dial DM. Failed intramedullary screw fixation of a proximal fifth metatarsal fracture (Jones fracture) in a division I athlete: A case report. *Foot Ankle Online J* 2009; **2**: 1 [DOI: [10.3827/faoj.2009.0206.0001](#)]
- 41 **Lee KT**, Kim KC, Young KW, Jegal H, Park YU, Lee HS, Roh Y. Conservative treatment of refractures after modified tension band wiring of fifth metatarsal base stress fractures in athletes. *J Orthop Surg (Hong Kong)* 2020; **28**: 2309499020926282 [PMID: [32539561](#) DOI: [10.1177/2309499020926282](#)]
- 42 **Baumbach SF**, Prall WC, Kramer M, Braunstein M, Böcker W, Polzer H. Functional treatment for fractures to the base of the fifth metatarsal - influence of fracture location and fracture characteristics. *BMC Musculoskelet Disord* 2017; **18**: 534 [PMID: [29246170](#) DOI: [10.1186/s12891-017-1893-6](#)]
- 43 **Polzer H**, Braunstein M, Baumbach S. Functional treatment for fractures to the base of the fifth metatarsal-Influence of fracture location and fracture characteristics. *Foot Ankle Orthop* 2018; **3**

- [DOI: [10.1177/2473011418s00387](https://doi.org/10.1177/2473011418s00387)]
- 44 **Wu GB**, Li B, Yang YF. Comparative study of surgical and conservative treatments for fifth metatarsal base avulsion fractures (type I) in young adults or athletes. *J Orthop Surg (Hong Kong)* 2018; **26**: 2309499017747128 [PMID: [29228848](https://pubmed.ncbi.nlm.nih.gov/29228848/) DOI: [10.1177/2309499017747128](https://doi.org/10.1177/2309499017747128)]
 - 45 **Park JY**, Kim HN, Hyun YS, Park JS, Kwon HJ, Kang SH, Kim GL. Effect of Weight-Bearing in Conservative and Operative Management of Fractures of the Base of the Fifth Metatarsal Bone. *Biomed Res Int* 2017; **2017**: 1397252 [PMID: [29441351](https://pubmed.ncbi.nlm.nih.gov/29441351/) DOI: [10.1155/2017/1397252](https://doi.org/10.1155/2017/1397252)]
 - 46 **Sesti FF**, Oliva F, Iundusi R. Fifth metatarsal tuberosity avulsion fractures: a new surgical technique without metal implant. *Muscle Ligaments Tendons J* 2019; **9**: 236 [DOI: [10.32098/mLtj.02.2019.12](https://doi.org/10.32098/mLtj.02.2019.12)]
 - 47 **Rikken QGH**, Dahmen J, Hagemeijer NC, Sierevelt IN, Kerkhoffs GMMJ, DiGiovanni CW. Adequate union rates for the treatment of acute proximal fifth metatarsal fractures. *Knee Surg Sports Traumatol Arthrosc* 2021; **29**: 1284-1293 [PMID: [32474612](https://pubmed.ncbi.nlm.nih.gov/32474612/) DOI: [10.1007/s00167-020-06072-8](https://doi.org/10.1007/s00167-020-06072-8)]
 - 48 **Marecek GS**, Earhart JS, Croom WP, Merk BR. Treatment of Acute Jones Fractures Without Weightbearing Restriction. *J Foot Ankle Surg* 2016; **55**: 961-964 [PMID: [27297739](https://pubmed.ncbi.nlm.nih.gov/27297739/) DOI: [10.1053/j.jfas.2016.04.013](https://doi.org/10.1053/j.jfas.2016.04.013)]
 - 49 **Rhim B**, Hunt JC. Lisfranc injury and Jones fracture in sports. *Clin Podiatr Med Surg* 2011; **28**: 69-86 [PMID: [21276519](https://pubmed.ncbi.nlm.nih.gov/21276519/) DOI: [10.1016/j.cpm.2010.09.003](https://doi.org/10.1016/j.cpm.2010.09.003)]
 - 50 **Slater GL**, Walters EE, O'Malley M. Reconstruction of Lateral Ankle Ligaments Update. *J Ost Arth* 2016; **1**: 2 [DOI: [10.1177/2473011420s00205](https://doi.org/10.1177/2473011420s00205)]
 - 51 **Qi R**, Li B, Xie T, Yin H. Surgical vs conservative management of fifth metatarsal fractures in adults: A protocol of retrospective study. *Medicine (Baltimore)* 2020; **99**: e22800 [PMID: [33080753](https://pubmed.ncbi.nlm.nih.gov/33080753/) DOI: [10.1097/MD.00000000000022800](https://doi.org/10.1097/MD.00000000000022800)]



Published by **Baishideng Publishing Group Inc**
7041 Koll Center Parkway, Suite 160, Pleasanton, CA 94566, USA

Telephone: +1-925-3991568

E-mail: bpgoffice@wjgnet.com

Help Desk: <https://www.f6publishing.com/helpdesk>

<https://www.wjgnet.com>

