

Orthodontic retreatment of an adult woman with mandibular backward positioning and temporomandibular joint disorder: A case report

Abstract

BACKGROUND

The role of occlusal factors on the occurrence of temporomandibular joint disorders (TMDs) is still unclear and it is tricky for orthodontists to treat malocclusions in patients with TMDs. We report the case of the second orthodontic treatment of an adult female with Class II division 2 malocclusion associated with TMD. With the removal of anterior occlusal interference, TMD symptoms were alleviated and cone beam computed tomography (CBCT) images showed the bilateral condyles shifted forward.

CASE SUMMARY

This case report presented an orthodontic retreatment of an adult female with TMD and mandibular backward positioning based on CBCT examination and Joint Space Index (JSI) analysis. The left and right JSI values of -38.5 and -52.6 indicated that the position of bilateral condyles had posterior displacement.

Ten years prior to this evaluation, she underwent orthodontic treatment resulting in the extraction of two upper premolars and one lower central incisor. The joint symptoms, including pain and sounds, were alleviated along with verified mandibular forward repositioning by extraction of another lower central incisor.

CONCLUSION

Mandibular backward positioning could be associated with TMD. JSI analysis

based on CBCT is a convenient way to examine condylar positions quantitatively.

Key words: Cone beam computerized tomography; Joint Space Index; Temporomandibular joint disorder (TMD);

Core tip:

Mandibular retrognathism is usually associated with retroclined upper anterior teeth, and this type of malocclusion is considered to be a risk factor for TMDs. Comprehensive examinations were performed to diagnose TMD, including intraoral occlusion examination, temporomandibular joint clinical examination, and CBCT imaging. Pretreatment of an intraoral occlusion in anterior teeth showed minimal overjet to restrict mandibular movement. We measured the joint space to assess the condylar position and found that the bilateral condyles were located in the posterior position. We suspected that this patient's TMD was a manifestation of functional mandibular retraction. Temporomandibular joint symptoms were alleviated with the removal of anterior occlusal interference, and the posttreatment CBCT images showed that bilateral condyles shifted forward after orthodontics. We hope this case can serve as a guide to clinical orthodontists in the treatment of Class II division 2 patients with TMDs.

INTRODUCTION

Temporomandibular joint disorders (TMDs) are common public health problems and affect approximately 60 to 70% of people worldwide, according to statistics in different countries ^[1]. The clinical symptoms of TMDs include pain, joint sounds, and functional limitations, such as restricted mandibular movement and limited mouth opening ^[2]. Pain-related disorders can affect a patient's social interactions, psychological health, and quality of life. Epidemiological researchers found that the prevalence of TMDs was associated with age, sex, occlusion, and orthodontic treatment ^[3, 4]. However, the exact causes of TMDs are still largely unknown, and it is often difficult to find an obvious cause. Moreover, the role of occlusal factors in the occurrence of TMDs has remained controversial until recently ^[5]. Therefore, the treatment of malocclusion with TMDs is a complex problem for orthodontists.

Functional malocclusion was reported to cause displacement of the condyle in the glenoid fossa ^[6] and might result in functional disorders of the temporomandibular joint (TMJ) ^[7]. Condylar displacement could be a sign of functional deviation, which was analyzed by cone beam computed tomography (CBCT) and Joint Space Index (JSI) analyses in the treatment of mandibular shift in an adult woman ^[8]. As another example, Class II division 2 patients have salient features, including deep bites, retroclined upper incisors, and mandibular retrognathism ^[9]. It was reported that mandibular retrognathism in Class II division 2 patients would have a risk of articular

disk displacement ^[10]. Nevertheless, there are few scientific reports about the pathology and treatment of functional malocclusion.

In this case, we reported orthodontic retreatment of an adult female with **TMD** and mandibular backward positioning based on CBCT examination and JSI analysis. The joint symptoms, including pain and sounds, were alleviated along with verified mandibular forward repositioning. Mandibular backward positioning could be related to TMD. Moreover, JSI analysis is a convenient way to examine condyle positions quantitatively.

CASE PRESENTATION

Chief complaints

An adult woman aged 26 years visited the clinic to request orthodontic retreatment for her relapsed crowding in her mandibular dentition.

History of past illness

Ten years prior to the present visit to the clinic, she received orthodontic treatment resulting in the extraction of two upper premolars and one lower central incisor.

Clinical examination

The clinical examination revealed that the patient had a straight profile and a strong chin (Figure 1). A 2.0 mm space in the maxillary dentition and 4.0 mm of crowding in the mandibular dentition were found. The upper incisors were retroclined, and the anterior overjet was minimal. The anterior overbite was within the normal range. Compared with the facial midline, the maxillary

dental midline deviated by 0.5 mm to the right. The mandibular dental midline was basically the center of the remaining lower central incisor since the other lower central incisors were missing. No chin deviation was evaluated. She had Class II molar and canine relationships bilaterally.

Imaging examinations

Cephalometric analysis (Figure 2, Table 1) indicated skeletal Class I malocclusion (SNA, 82.4°; SNB, 79.5°; ANB, 2.9°) with a normal mandibular plane angle (SN-MP, 34.8°). The maxillary incisors were retroclined (U1-SN, 82.8°; U1-NA, 15.8°).

The patient had experienced TMJ pain many times after her first orthodontic treatment, and we found joint clicking at the start of mouth opening in TMJ clinical examination. CBCT examination was performed to check the TMJ. CBCT examination was performed when the maxillary and mandibular teeth were in maximum intercuspation (MI). JSI was used to assess the condylar position by calculating the ratio of the anterior and posterior joint spaces.^[11] Vargas-Pereira described that the physiologic range of JSI values for the condylar position was -32.5 to 21.1.^[12] A greater value indicated an anterior position, while a smaller value indicated a posterior position. CBCT images of the TMJs were oriented sagittally and taken perpendicular to the maximum transverse of the long axis of the condylar region, as previously reported^[13]. Left and right JSI values of -38.5 and -52.6 (Table 2), respectively, were obtained in this case. The results indicated that

the position of bilateral condyles had posterior displacement and that the right condyle displacement was more severe than that of the left condyle. The right upper central incisor had dark gray discoloration, but the panorama examination showed no obvious findings. CBCT examination revealed a large periapical radiolucency associated with the upper right central incisor (Figure 2). We collected the medical history and the patient gave no history of trauma, caries, and clinical symptoms of upper right central incisor. We speculated that the periapical periodontitis of the upper right central incisor might be associated with anterior occlusal interference.

FINAL DIAGNOSIS

The final diagnoses of the presented case were Class II malocclusion and temporomandibular joint disorder (TMD).

TREATMENT

In accordance with the pretreatment records and the patient's chief complaint, the treatment objectives were to (1) advise the endodontist to treat periapical periodontitis of the upper right central incisor; (2) align the dental arch, eliminate dental crowding, and close the space; (3) achieve ideal overjet and overbite as well as coincident dental and facial midlines; and (4) prevent the aggravation of TMD and hopefully alleviate the TMD symptoms.

To continue with our treatment objectives and to attain the best esthetic and functional results, two treatment options were proposed for the patient.

The first option was nonextraction treatment. Three teeth were removed

during the first orthodontic treatment, and only slight crowding relapse occurred in the anterior mandibular dentition. Too much space could have been created if more teeth were extracted. Interproximal enamel reduction (IPR) was recommended in mild crowding [14]. Therefore, the method of nonextraction was considered. We planned to grind the lower anterior teeth to align the mandibular dentition. There were some disadvantages in this option. First, IPR was reported to have risks of tooth sensitivity and caries [14]. In addition, the overjet would still be minimal when closing the space in the upper and lower dentition. It was also difficult to correct the Class II occlusion relationship without tooth extraction.

Class II elastics are widely used for Class II malocclusion treatment; these elastics are conducive to correcting deep anterior overbite, closing the extraction space, and guiding the mandible forward. However, caution should be taken when treating hyperdivergent patients and those exhibiting progressive absorption of the condyle. In this case, the patient had a normal mandibular plane angle and posterior displacement of the condyles but no joint absorption. Class II elastics could guide the mandible forward to obtain a Class I occlusion relationship and change the position of the condyle, which might ease TMJ symptoms. However, when using Class II elastic traction, a larger overjet is required to prevent occlusal trauma in anterior teeth. Therefore, Class II elastics could not be used with the first treatment option.

The second treatment option was to extract one lower central incisor.

Since two upper premolars and one lower central incisor were extracted in the first orthodontic treatment, the removal of another lower central incisor was beneficial to establish a coordinated and symmetrical dental arch. However, after aligning and closing the space in the upper and lower dentition, it was not clear if the anterior overjet would be too large. There was an advantage to using Class II elastics to correct molar relationships in this option while guiding the mandible forward to change the position of the condyle and establish an ideal anterior overjet. Based on the consideration of the treatment objectives, the second option was chosen for this case.

Before orthodontic treatment, the patient received endodontic therapy, and the periapical periodontitis of the upper right central incisor was controlled. After extraction of the mandibular central incisor, the 0.022 * 0.028-inch slot preadjusted edgewise brackets were then bonded onto the entire dentition except for the second molars and the third molars. The archwire sequence progressed from 0.014-inch nickel-titanium wire to 0.018 * 0.025-inch stainless steel working wire. Seventeen months into treatment, all teeth were leveled and aligned, and space closure was completed. Although the use of Class II elastics had been planned, the occlusal relationship was corrected once an adequate anterior overjet was established, and no Class II elastics were actually applied. CBCT examination was performed to assess the recovery of 11 and changes in condylar positions. The total treatment time was 17 months. A Hawley retainer was used for retention.

OUTCOME AND FOLLOW-UP

The posttreatment photographs showed a Class I canine and molar relationship, normal overbite and overjet, improved midline deviation, and neatly aligned teeth (Figure 3). The posttreatment panoramic radiograph showed no significant root resorption and good root parallelism (Figure 4). CBCT examination of 11 indicated the healing of periapical radiolucent lesions around the root of the upper right central incisor (Figure 4). The posttreatment cephalometric analysis is shown in Table 1. Superimposition of the pretreatment and posttreatment cephalometric radiographs showed mild retraction of the mandibular incisors and proclination of the upper incisors (Figure 5). The CBCT images of the TMJs in the aforementioned section showed joint shifting forward after orthodontic treatment (Figure 6 and Figure 7). The right JSI after 22 months of retention was -43.2 and was larger than that observed at pretreatment (-52.6), which confirmed the condylar shift forward (Table 2). Although the CBCT image showed an incompetent left condylar after 22 months of retention, we inferred a larger JSI of the left condylar. CBCT superimposition of the pretreatment and retention bilateral TMJs also validated the same results (Figure 8). Joint clicking disappeared, and TMJ pain was relieved. After 22 months of retention, the patient visited the clinic for tooth bleaching of the upper right central incisor. Facial and intraoral photographs showed a stable occlusion (Figure 9), and CBCT images showed the TMJ in a stable position without recurrence of TMJ pain and

sound (Figure 6 and Figure 7).

DISCUSSION

Functional or occlusal factors are considered a potential etiology of TMDs. It has been proposed that the presence of occlusal interferences usually results in TMJ functional disorders. Previous studies reported that occlusal interference could cause mandibular deviation, leading to changes in the condylar position and pain in the TMJ [15]. Hidaka et al. also commented that functional malocclusion from malocclusions or orthodontic treatments led to condylar displacement in the glenoid fossa [6]. It was speculated that unstable occlusion increased the load of the mandibular condyle and articular fossa, which might affect TMJ morphology [16]. The latter might also interfere with mandibular functional movement. It was confirmed that eliminating functional occlusal factors could relieve dysfunction of the masticatory system [17].

Many scholars, such as Roth [18], advocated for functional occlusion as the goal of orthodontic treatment. The authors believed that more attention should be given to achieving centric relation (CR) and MI harmony without occlusal interference after orthodontic treatment. Articulator mountings, including a Panadent condylar position indicator (CPI) and mandibular position indicator (MPI) [19], were designed to transfer the occlusal status and the condylar position to the outside of the mouth. The traditional method is to diagnose occlusal interference and premature contact and to detect functional

displacement of the condyle. However, it was reported that this method could not accurately quantify small changes in joint position [20, 21].

Imaging examination is an essential method for the diagnosis and treatment of TMDs. Various imaging examinations can be used to detect the TMJ, such as panoramic radiography, magnetic resonance imaging (MRI) and CBCT. The latter two methods can be used for quantitative analysis. MRI has excellent sensitivity in nonmineralized tissue and is widely used to evaluate cartilage and disc position and to diagnose TMD [22]. Although the quality of MRI has improved, there are still limitations in the low-quality images of the complex bone structure of the TMJ that it provides [23]. In addition, MRI evaluation was not easily accepted by patients due to high costs; also, stomatological hospitals are rarely equipped with MRI equipment. Maxillofacial CBCT is specially designed for the maxillofacial tissue. Maxillofacial CBCT was developed from conventional CT and is specially designed for maxillofacial tissues with low cost and a low radiological dose [24]. CBCT is an intuitive, simple and accurate method for comprehensive evaluation of hard tissue, diagnosis of condylar changes, and a clear display of joint space in three dimensions [25].

Mandibular retrognathism is usually associated with Class II division 2, and such patients are more susceptible to TMDs [9]. It was reported that adults with Class II malocclusion might experience muscle pain [26], and another study found that mandibular retrognathism in Class II division 2 patients

increased the risk of articular disk displacement ^[10]. In this case, the patient extracted two upper premolars and one lower central incisor in the first orthodontic treatment, resulting in a minimal overjet to restrict mandibular movement and Class II division 2 malocclusion. We preliminarily estimated TMD risk based on medical history and temporomandibular joint clinical examination. CBCT was performed to evaluate the condyle position. Many researchers, such as Mavreas ^[27] and Ruf ^[13, 28], recommended the use of the JSI to evaluate anterior and posterior joint spaces and condylar positions. Vargas-Pereira calculated the physiologic range of the JSI (-32.5, 21.1), indicating positive anterior displacement and a negative post displacement ^[11]. We used the JSI to examine joint space in CBCT images and found that the bilateral condyles were located in the posterior position. Combined with the medical history, temporomandibular joint clinical examination, intraoral occlusion, and CBCT images, we suspected that the minimal overjet in the first orthodontic limited mandibular movement, led to **backward positioning** of the mandible, and caused TMJ symptoms. Therefore, the patient's TMD might be a consequence of functional mandibular retraction. In the second orthodontic treatment, with the proclination of upper anterior teeth and retraction of lower anterior teeth to construct an ideal overjet, joint symptoms **were alleviated** without using Class II elastic traction. Comparing the CBCT images of the TMJ before and after the second treatment, it was found that bilateral condyles shifted forward, which further suggested that occlusal

factors might be closely associated with the patient's TMD. After 22 months of retention, the condylar position was stable, and there was no recurrence of TMD.

The patient's TMD could be due to iatrogenic functional or occlusal factors during the first orthodontic treatment. Although the relationship between orthodontics and TMDs has been controversial, several studies have reported that incorrect orthodontic treatment results in iatrogenic TMDs. For example, it was reported that excessive retraction and retroclination of upper incisors could cause premature contacts and lead to distal displacement of the mandible and mandibular condyle. As a result, mandible retraction increases the risk of TMDs [29]. Therefore, more attention should be given to joint changes in orthodontic treatment.

CONCLUSION

In conclusion, mandibular backward positioning could be correlated with TMD and TMD symptoms might be alleviated with the mandibular forward repositioning for this situation. JSI analysis based on CBCT is convenient to evaluate condylar positions quantitatively.

Acknowledgements

Not applicable

References

- 1 Dantas C, Vivan C, de Fantini S, de Freitas Costa E Silva P, Pannuti C, Witzel A, Dominguez G. The influence of educational measures and low-level laser phototherapy on temporomandibular disorders: Study protocol clinical

trial (SPIRIT Compliant). *Medicine*. 2020; 99: e19005. [PMID: 32150048 DOI: 10.1097/md.00000000000019005]

2 **Schiffman E**, Ohrbach R, Truelove E, Look J, Anderson G, Goulet JP, List T, Svensson P, Gonzalez Y, Lobbezoo F, Michelotti A, Brooks SL, Ceusters W, Drangsholt M, Ettlin D, Gaul C, Goldberg LJ, Haythornthwaite JA, Hollender L, Jensen R, John MT, De Laat A, de Leeuw R, Maixner W, van der Meulen M, Murray GM, Nixdorf DR, Palla S, Petersson A, Pionchon P, Smith B, Visscher CM, Zakrzewska J, Dworkin SF. Diagnostic Criteria for Temporomandibular Disorders (DC/TMD) for Clinical and Research Applications: recommendations of the International RDC/TMD Consortium Network* and Orofacial Pain Special Interest Groupdagger. *J Oral Facial Pain Headache*. 2014; 28: 6-27. [PMID: 24482784 DOI: 10.11607/jop.1151]

3 **Agerberg G**, Carlsson GE. Functional disorders of the masticatory system. I. Distribution of symptoms according to age and sex as judged from investigation by questionnaire. *Acta Odontol Scand*. 1972; 30: 597-613. [PMID: 15303265 DOI:

4 **Poveda Roda R**, Bagan JV, Diaz Fernandez JM, Hernandez Bazan S, Jimenez Soriano Y. Review of temporomandibular joint pathology. Part I: classification, epidemiology and risk factors. *Med Oral Patol Oral Cir Bucal*. 2007; 12: E292-298. [PMID: 17664915 DOI:

5 **Stone JC**, Hannah A, Nagar N. Dental occlusion and temporomandibular disorders. *Evid Based Dent*. 2017; 18: 86-87. [PMID: 29075035 DOI: 10.1038/sj.ebd.6401258]

6 **Hidaka O**, Adachi S, Takada K. The difference in condylar position between centric relation and centric occlusion in pretreatment Japanese orthodontic patients. *Angle Orthod*. 2002; 72: 295-301. [PMID: 12169028 DOI: 10.1043/0003-3219(2002)072<0295:tdicpb>2.0.co;2]

7 **Chen Q**, Mai ZH, Lu HF, Chen L, Chen Z, Ai H. Treatment of a mandibular functional shift in an adolescent boy with temporomandibular

disorder and crossbites. Am J Orthod Dentofacial Orthop. 2015; 148: 660-673. [PMID: 26432322 DOI: 10.1016/j.ajodo.2014.10.037]

8 **Xia K**, Sun W, Yu L, Huang X, Zhao Z, Liu J. Treatment of the mandibular shift in an adult woman and the diagnostic value of joint space index: a case report. Eur J Med Res. 2020; 25: 50. [PMID: 33092645 DOI: 10.1186/s40001-020-00451-0]

9 **Prasad SE**, Indukuri RR, Singh R, Nooney A, Palagiri FB, Narayana V. Pathognomonic features of Angle's Class II division 2 malocclusion: A comparative cephalometric and arch width study. J Int Soc Prev Community Dent. 2014; 4: S105-109. [PMID: 25558449 DOI: 10.4103/2231-0762.146212]

10 **Zuaiter S**, Robin O, Gebeile-Chauty S, Raberin M. [Does dental class II division 2 predispose to temporomandibular disorders?]. Orthod Fr. 2013; 84: 277-285. [PMID: 23993369 DOI: 10.1051/orthodfr/2013052]

11 **Chavan S**, Bhad W, Doshi U. Comparison of temporomandibular joint changes in Twin Block and Bionator appliance therapy: a magnetic resonance imaging study. Progress in orthodontics. 2014; 15: 57. [PMID: 25329768 DOI: 10.1186/s40510-014-0057-6]

12 **Pereira MRV**. Quantitative Auswertungen bildgebender Verfahren und Entwicklung einer neuen metrischen Analyse für Kiefergelenkstrukturen im Magnetresonanztomogramm: Verlag nicht ermittelbar; 1997.

13 **Ruf S**, Panherz H. Temporomandibular joint growth adaptation in Herbst treatment: a prospective magnetic resonance imaging and cephalometric roentgenographic study. Eur J Orthod. 1998; 20: 375-388. [PMID: 9753819 DOI: 10.1093/ejo/20.4.375]

14 **Lapenaite E**, Lopatiene K. Interproximal enamel reduction as a part of orthodontic treatment. Stomatologija. 2014; 16: 19-24. [PMID: 24824056 DOI:

15 **Egermark-Eriksson I**, Carlsson GE, Magnusson T. A long-term epidemiologic study of the relationship between occlusal factors and mandibular dysfunction in children and adolescents. J Dent Res. 1987; 66:

67-71. [PMID: 3476545 DOI: 10.1177/00220345870660011501]

16 Koide D, Yamada K, Yamaguchi A, Kageyama T, Taguchi A. Morphological changes in the temporomandibular joint after orthodontic treatment for Angle Class II malocclusion. *Cranio*. 2018; 36: 35-43. [PMID: 28198654 DOI: 10.1080/08869634.2017.1285218]

17 Roth RH. Temporomandibular pain-dysfunction and occlusal relationships. *Angle Orthod*. 1973; 43: 136-153. [PMID: 4511992 DOI: 10.1043/0003-3219(1973)043<0136:tpaor>2.0.co;2]

18 Roth RH. Functional occlusion for the orthodontist. *J Clin Orthod*. 1981; 15: 32-40, 44-51 contd. [PMID: 6940863 DOI:

19 Crawford SD. Condylar axis position, as determined by the occlusion and measured by the CPI instrument, and signs and symptoms of temporomandibular dysfunction. *Angle Orthod*. 1999; 69: 103-115; discussion 115-106. [PMID: 10227550 DOI: 10.1043/0003-3219(1999)069<0103:capadb>2.3.co;2]

20 Kandasamy S, Boeddinghaus R, Kruger E. Condylar position assessed by magnetic resonance imaging after various bite position registrations. *Am J Orthod Dentofacial Orthop*. 2013; 144: 512-517. [PMID: 24075658 DOI: 10.1016/j.ajodo.2013.06.014]

21 Rinchuse DJ, Kandasamy S. Centric relation: A historical and contemporary orthodontic perspective. *J Am Dent Assoc*. 2006; 137: 494-501. [PMID: 16637479 DOI: 10.14219/jada.archive.2006.0222]

22 Walker TF, Broadwell BK, Noujeim ME. MRI assessment of temporomandibular disc position among various mandibular positions: a pilot study. *Cranio*. 2017; 35: 10-14. [PMID: 27077253 DOI: 10.1080/08869634.2015.1123844]

23 Al-Saleh MA, Alsufyani NA, Saltaji H, Jaremko JL, Major PW. MRI and CBCT image registration of temporomandibular joint: a systematic review. *J Otolaryngol Head Neck Surg*. 2016; 45: 30. [PMID: 27164975 DOI:

10.1186/s40463-016-0144-4]

24 Larheim TA, Abrahamsson AK, Kristensen M, Arvidsson LZ. Temporomandibular joint diagnostics using CBCT. *Dentomaxillofac Radiol*. 2015; 44: 20140235. [PMID: 25369205 DOI: 10.1259/dmfr.20140235]

25 Hilgers ML, Scarfe WC, Scheetz JP, Farman AG. Accuracy of linear temporomandibular joint measurements with cone beam computed tomography and digital cephalometric radiography. *Am J Orthod Dentofacial Orthop*. 2005; 128: 803-811. [PMID: 16360924 DOI: 10.1016/j.ajodo.2005.08.034]

26 Mohlin B, Ingervall B, Thilander B. Relation between malocclusion and mandibular dysfunction in Swedish men. *Eur J Orthod*. 1980; 2: 229-238. [PMID: 6961042 DOI: 10.1093/ejo/2.4.229]

27 Mavreas D, Athanasiou AE. Tomographic assessment of alterations of the temporomandibular joint after orthognathic surgery. *Eur J Orthod*. 1992; 14: 3-15. [PMID: 1563472 DOI: 10.1093/ejo/14.1.3]

28 Ruf S, Pancherz H. Does bite-jumping damage the TMJ? A prospective longitudinal clinical and MRI study of Herbst patients. *Angle Orthod*. 2000; 70: 183-199. [PMID: 10926428 DOI: 10.1043/0003-3219(2000)070<0183:dbjdt>2.0.co;2]

29 McLaughlin RP, Bennett JC. The extraction-nonextraction dilemma as it relates to TMD. *Angle Orthod*. 1995; 65: 175-186. [PMID: 7639431 DOI: 10.1043/0003-3219(1995)065<0175:tedair>2.0.co;2]

Footnotes

Informed consent statement: Written informed consent for publication of clinical details and clinical images were obtained from the patient.

Conflict-of-interest statement: The authors declare that they have no competing interests.

Figure Legends

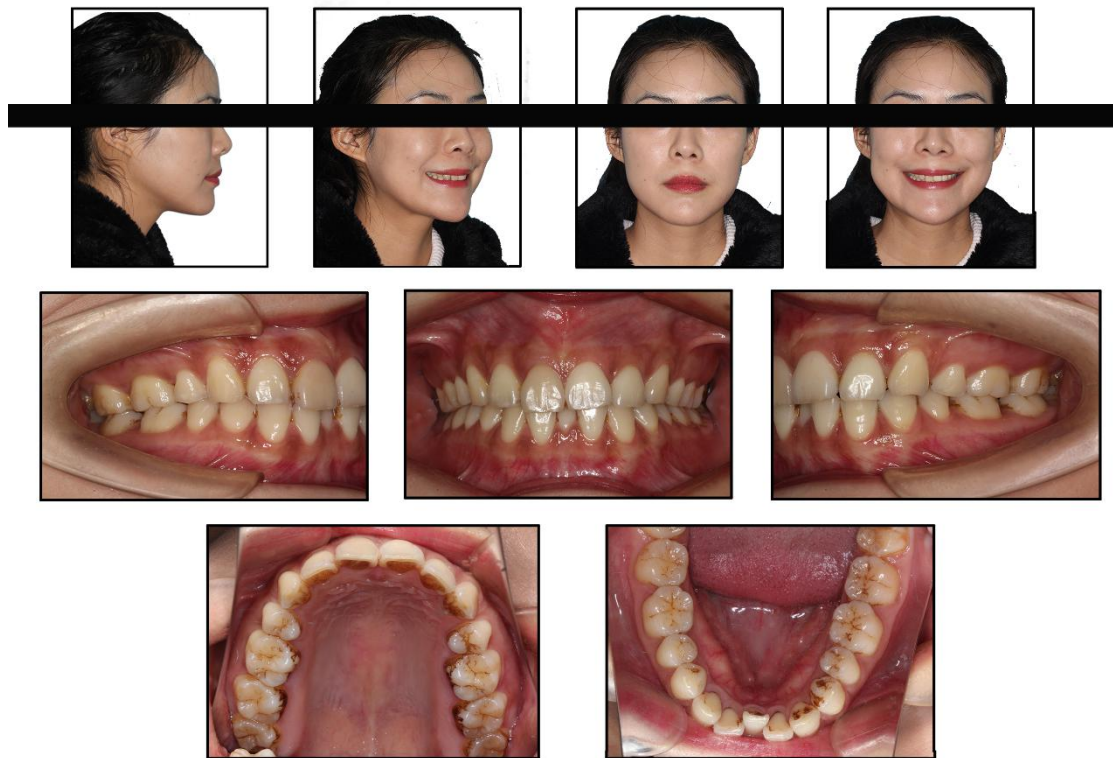

Figure 1 Pretreatment intraoral and facial photographs.

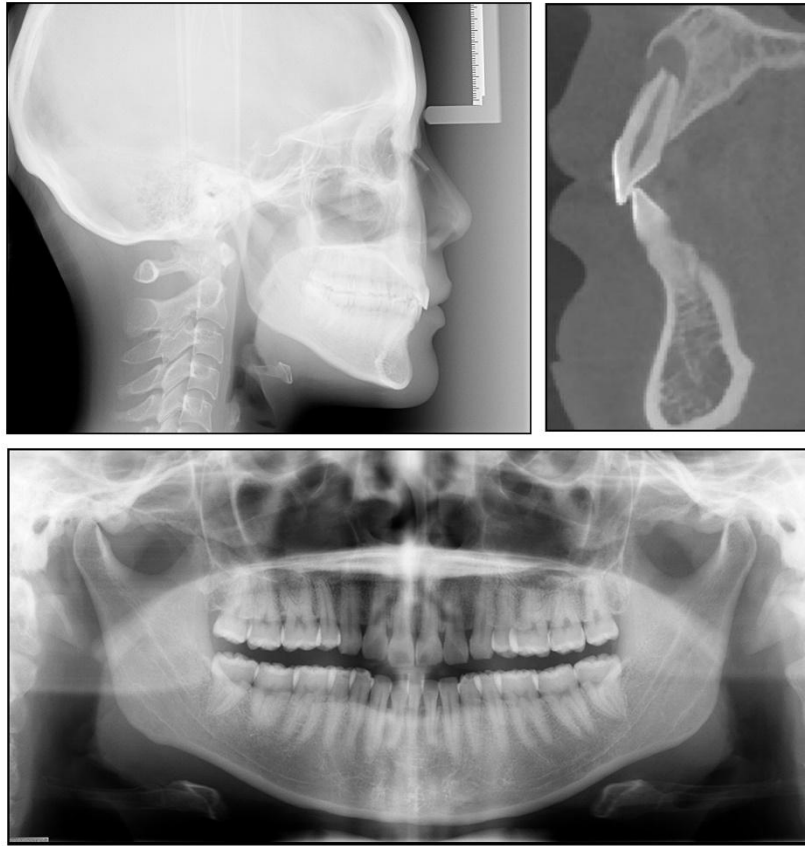

Figure 2 Pretreatment radiographs and CBCT image of the upper right central incisor.

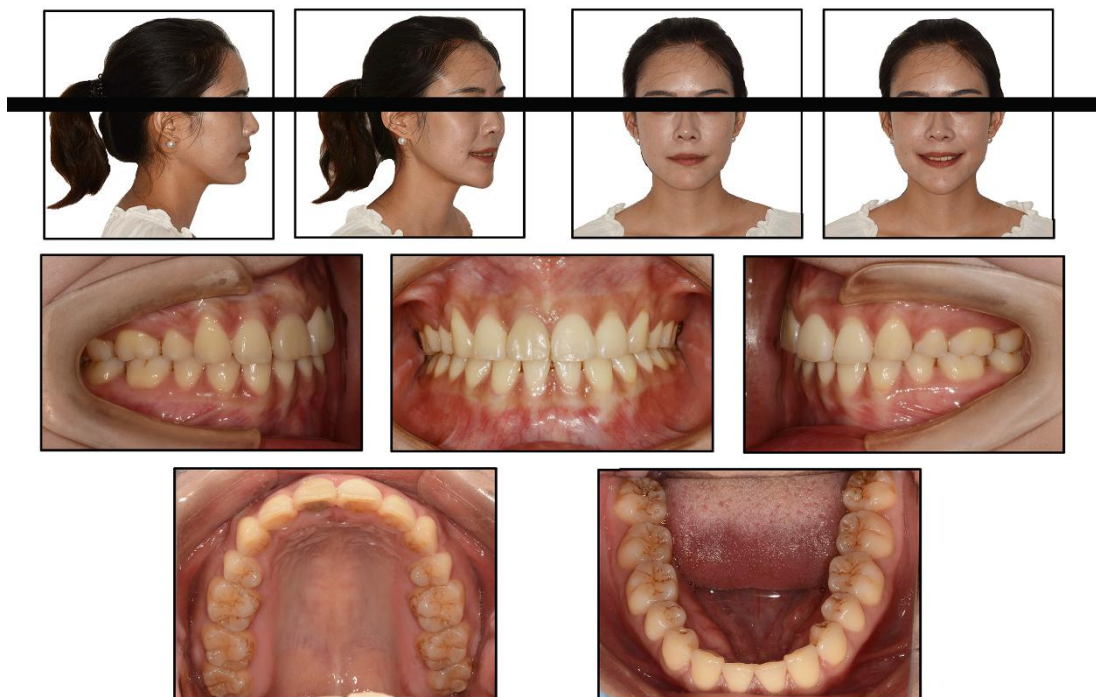


Figure 3 Posttreatment intraoral and facial photographs.

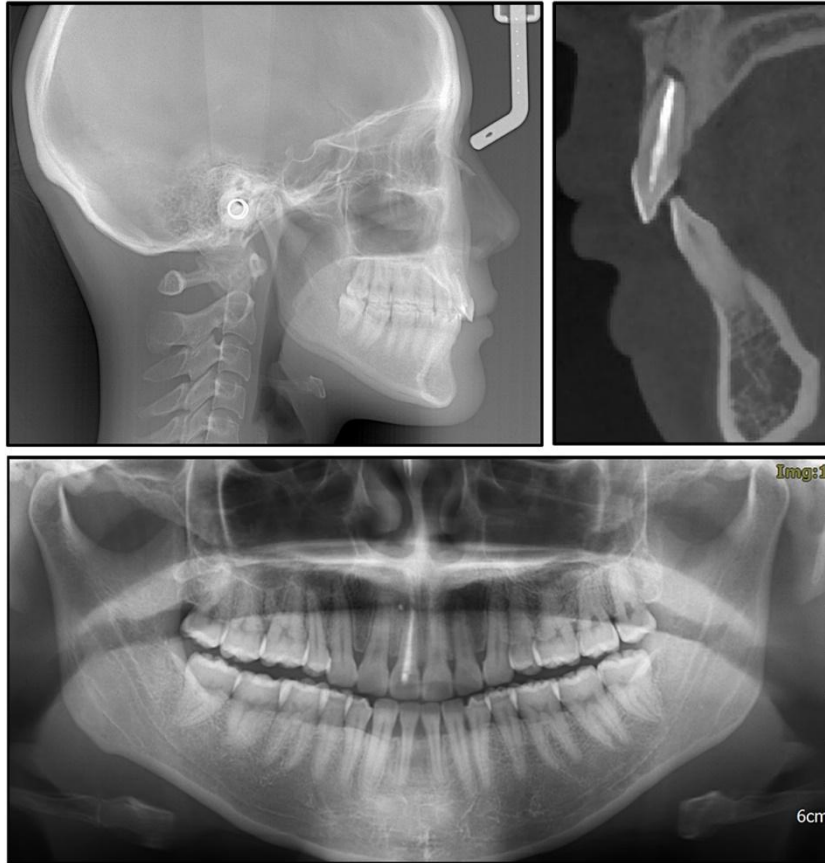


Figure 4 Posttreatment radiographs and CBCT image of the upper right central incisor.

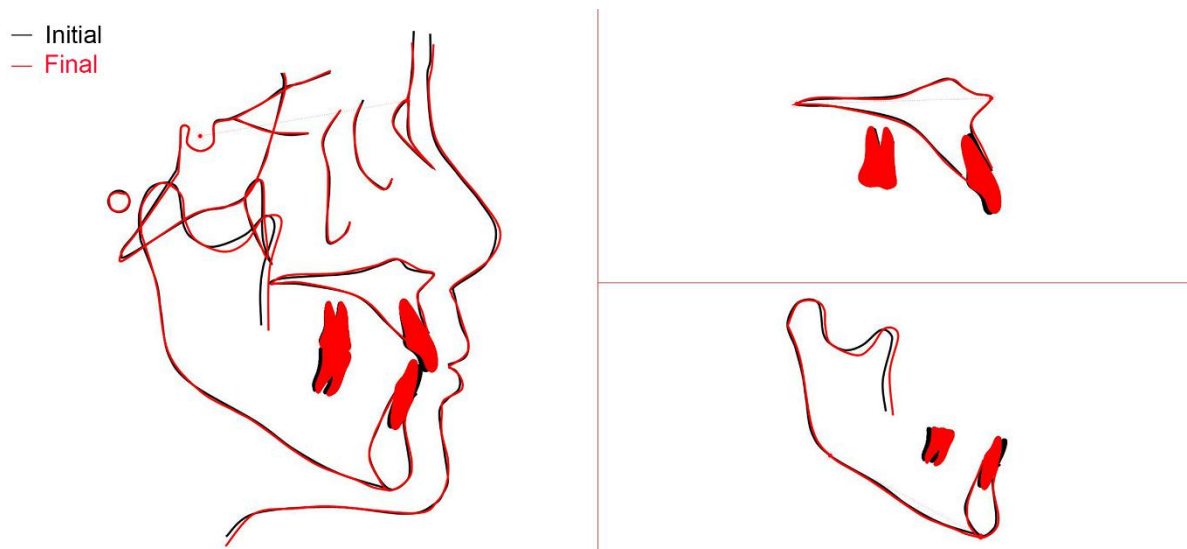


Figure 5 Superimposition of pretreatment (black) and posttreatment (red) cephalometric tracings.

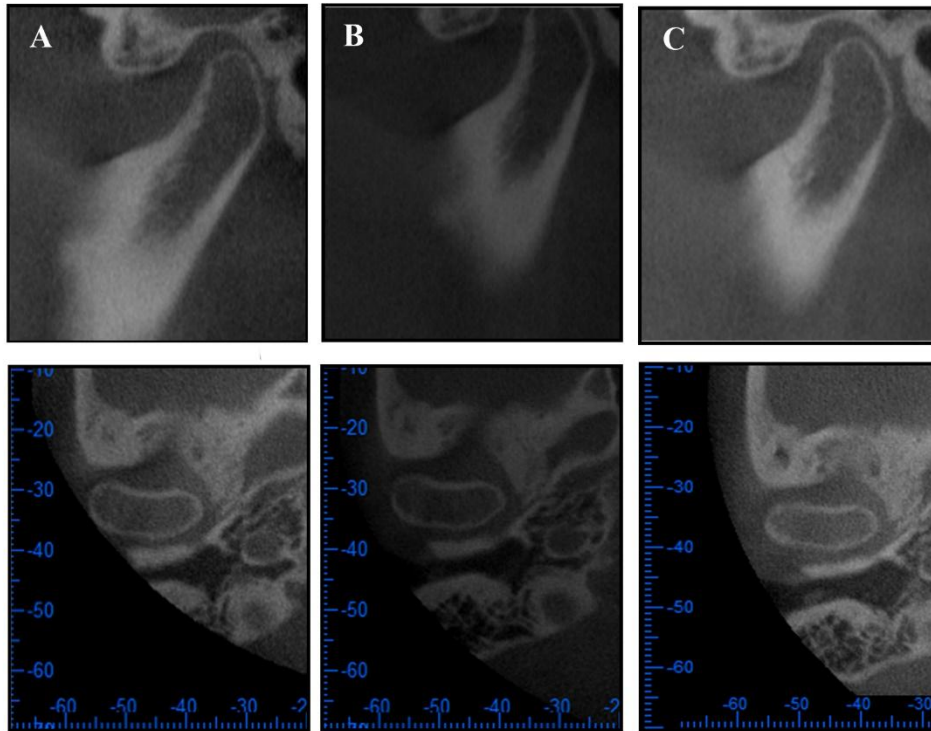


Figure 6 Pretreatment (A), posttreatment (B), and 22-month retention (C) CBCT images of the right TMJ in the sagittal (upper) and transverse (lower) planes.

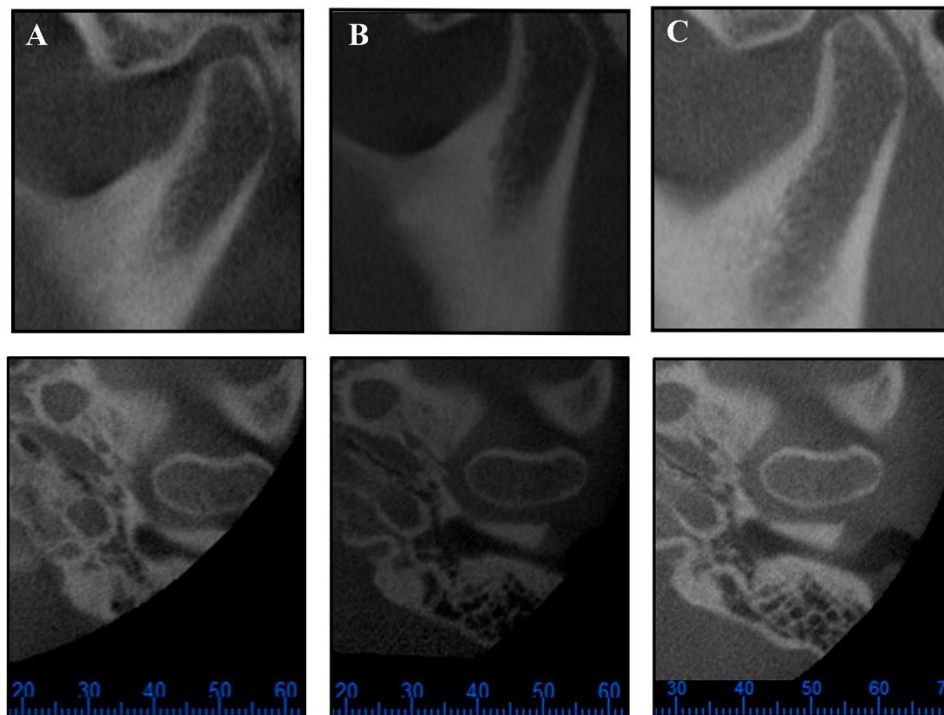


Figure 7 Pretreatment (A), posttreatment (B), and 22-month retention (C)

CBCT images of the left TMJ in the sagittal (upper) and transverse (lower) planes.

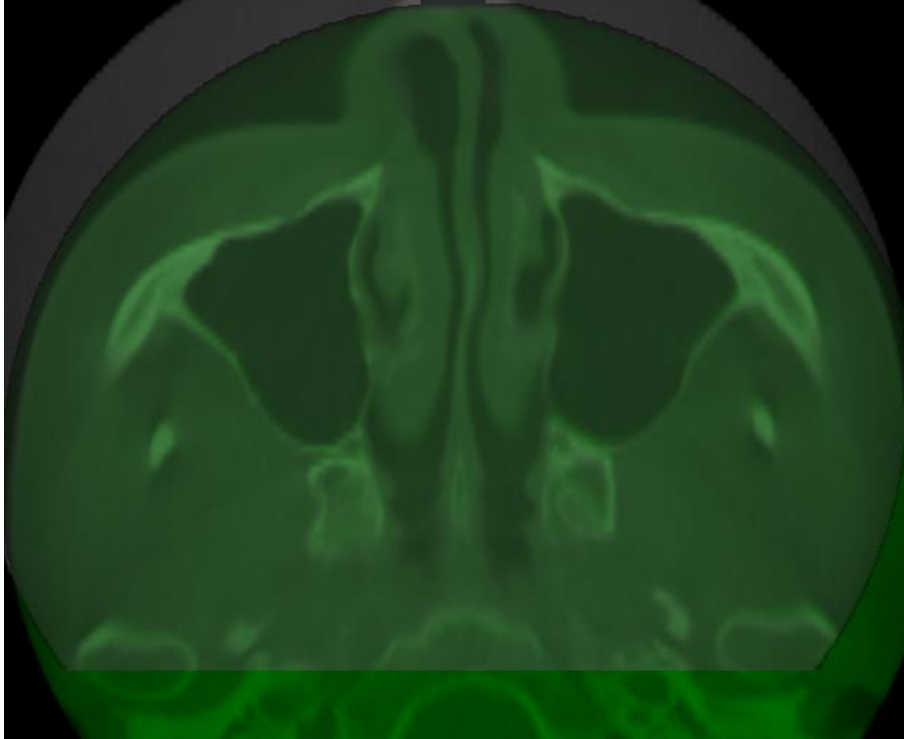


Figure 8 CBCT superimposition of pretreatment (gray) and 22-month retention (green) bilateral TMJs.

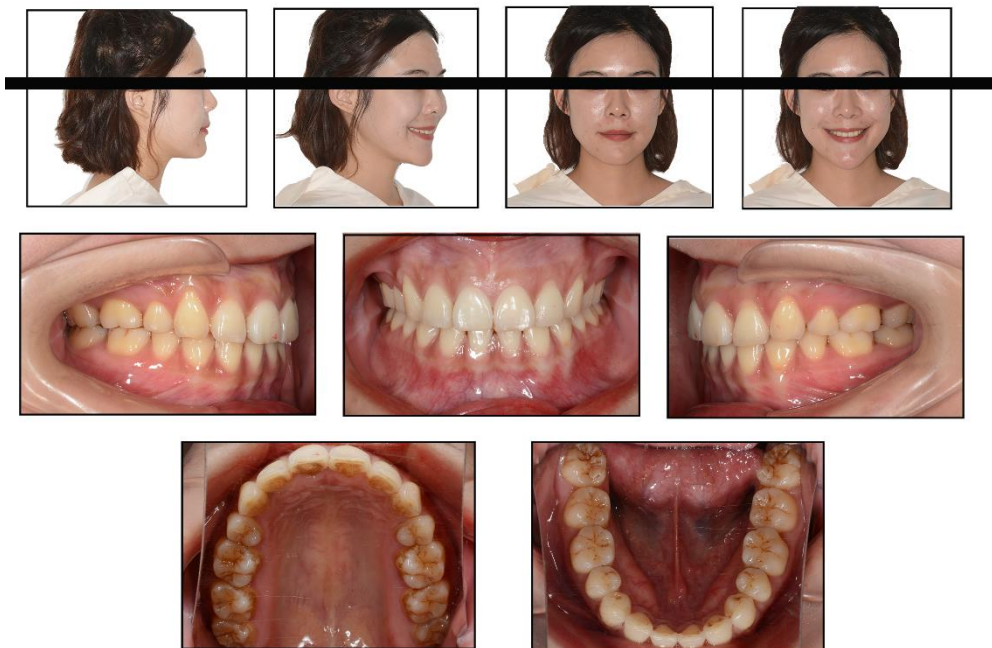


Figure 9 Intraoral and facial photographs after 22 months of retention.

Table1: Cephalometric analysis

Measurement	Normal	Pretreatment	Posttreatment
SNA°	81.7±2.5	82.4	82.2
SNB°	78.9±2.2	79.5	79.9
ANB°	2.8±1.2	2.9	2.3
SN-MP°	32.9±4.2	34.8	34.2
U1-L1°	123.2±6.2	136.8	129.2
U1-SN°	105.1±6.2	82.8	101.3
U1-NA°	23.3±6.2	15.8	17.6
L1-NB°	27.4±4.7	28.1	26.0
IMPA(L1-MP)°	95.4±4.7	93.0	91.5
UL-EP (mm)	-0.5±1.9	-2.5	-1.7
LL-EP (mm)	1.3±1.9	-2.2	-1.1

Table 2: Joint space measurements

	Right TMJ				Left TMJ		
	Anterior (mm)	JS	Posterior JS (mm)	JSI	Anterior JS (mm)	Posterior JS (mm)	JSI
Pretreatment	3.57		1.11	-52.6	2.75	1.22	-38.5
Retention of 22 month	3.28		1.30	-43.2	-	-	-
Relative change (Re-pre)	-0.29		0.19	9.4	-	-	-

Abbreviations: Re, Retention; pre, pretreatment.

Cover Letter and Responses

Dear Editor,

Thank you for giving us the opportunity to revise our article entitled " Orthodontic retreatment of an adult woman with mandibular backward positioning and temporomandibular joint disorder: A case report" (Manuscript ID: 69518). We have highly regarded the insightful comments and suggestions, carefully responded to these suggestions point-by-point in this cover letter (see following “**responses**” part), and revised the manuscript accordingly. All changes made to the text are highlighted in red color so that they can be identified with ease.

Please contact me if you have any questions. We look forward to hearing from you.

Thank you for your time.

Yours sincerely,

Corresponding author: Jun Liu

Full postal address: West China Hospital of Stomatology (Sichuan University), No.14, Sec.3, Renminnan Road, Chengdu Sichuan 610041, China

Tel.: +86 15108329615

E-mail address: junliu@scu.edu.cn

Responses

Reviewer #1

Overall Considerations: This paper showed the orthodontic retreatment case with TMD. The paper are well written, but some parts should be revised.

Comment 1: Title: The title “with significant mandibular backward positioning” is strange to me because cephalometric analysis showed skeletal Class I with a normal mandibular plane angle. So, “significant” should be omitted.

[Author response]

We thank the reviewer for this precious suggestion.

1. We have revised the title “*Orthodontic retreatment of an adult woman with significant mandibular backward positioning and temporomandibular joint disorder: A case report*” into “*Orthodontic retreatment of an adult woman with mandibular backward positioning and temporomandibular joint disorder: A case report*”.
2. We have revised “*significant mandibular backward positioning based on CBCT examination and Joint Space Index (JSI) analysis.*” into “*mandibular backward positioning based on cone beam computed tomography (CBCT) examination and Joint Space Index (JSI) analysis.*”. **(See Abstract/case summary Section, Page 1, Paragraph 1, Line 2-4)**
3. We have revised “*significant mandibular backward positioning based on CBCT examination and JSI analysis*” into “*mandibular backward positioning based on CBCT examination and JSI analysis.*”. **(See Introduction Section, Page 4, Paragraph 2, Line 2-3)**

Comment 2: The result of JSI should be written in the “case summary” of the abstract in order to conclude JSI analysis is a convenient way.

[Author response]

We thank the reviewer for this professional suggestion.

1. We have added “*The left and right JSI values of -38.5 and -52.6 indicated that the*

position of bilateral condyles had posterior displacement.” (See Abstract/case summary Section, Page 1, Paragraph 1, Line 3-4)

Comment 3: *Core tip: The first sentence “Mandibular retrognathism is usually associated with Class II division 2 malocclusion” is incorrect. There are many cases of mandibular retrognathism with Class I division 2 malocclusion.*

[Author response]

We thank the reviewer for this nice comment!

1. We have revised “Mandibular retrognathism is usually associated with Class II division 2 malocclusion,” into “Mandibular retrognathism is usually associated with retroclined upper anterior teeth,”. (See Abstract/Core tip Section, Page 2, Paragraph 1, Line 1-2)

Comment 4: *In the introduction, the abbreviation of TMD was stated twice.*

[Author response]

We thank the reviewer for this professional suggestion.

1. We have revised “Temporomandibular joint (TMJ) disorders (TMDs) are common public health problems and affect approximately 60 to 70% of people worldwide, according to statistics in different countries.” into “Temporomandibular joint disorders (TMDs) are common public health problems and affect approximately 60 to 70% of people worldwide, according to statistics in different countries” (See case Introduction Section, Page 1, Line 1-3)

Comment 5: *In the Imaging examinations, Cone beam computed tomography should be written “CBCT” because the abbreviation was in the Introduction.*

[Author response]

We thank the reviewer for this professional suggestion.

1. We have revised “Cone beam computed tomography (CBCT) examination was performed to check the TMJ.” into “CBCT examination was performed to check the

TMJ.” (See Imaging examinations Section, Page 5, Paragraph 2, Line 3)

Comment 6: Authors should explain more about JSI analysis.

[Author response]

We thank the reviewer for this professional suggestion.

1. We have added “JSI was used to assess the condylar position by calculating the ratio of the anterior and posterior joint spaces. [11]” (See Imaging examinations Section, Page 5, Paragraph 2, Line 5-7)

2. We have revised “According to the physiologic range of JSI values (-32.5, 21.1) as presented by Vargas-Pereira [12]” into “Vargas-Pereira recommended that the physiologic range of JSI values for the condylar position was -32.5 to 21.1. [12] A greater value indicated an anterior position, while a smaller value indicated a posterior position.”. (See Imaging examinations Section, Page 5, Paragraph 2, Line 7-9)

3. We have revised “JSI analysis was used to assess the condylar position in the same section, and left and right JSI values of -38.5 and -52.6, respectively, were obtained (Table 2).” into “Left and right JSI values of -38.5 and -52.6 (Table 2), respectively, were obtained in this case. The results indicated that the position of bilateral condyles had posterior displacement and that the right condyle displacement was more severe than that of the left condyle.”. (See Imaging examinations Section, Page 5, Paragraph 2, Line 12-13 and Page 6, Paragraph 1, Line 1-2)

Comment 7: What does JSI values (-32.5, 21.1) mean as presented by Vargas?

[Author response]

We thank the reviewer for this nice comment! Vargas-Pereira described that the physiologic range of JSI values for the condylar position was -32.5 to 21.1. A greater value indicated an anterior position, while a smaller value indicated a posterior position.

1. We have revised “According to the physiologic range of JSI values (-32.5, 21.1) as presented by Vargas-Pereira [12]” into “Vargas-Pereira described that the

physiologic range of JSI values for the condylar position was -32.5 to 21.1. [12] A greater value indicated an anterior position, while a smaller value indicated a posterior position.”. (See Imaging examinations Section, Page 5, Paragraph 2, Line 7-9)

Comment 8: *Authors should explain more about medical history of upper central incisor.*

[Author response]

We thank the reviewer for this professional suggestion. We collected the medical history and the patient gave no history of trauma, caries, and clinical symptoms of upper central incisor. The periapical periodontitis of the upper right central incisor was diagnosed by CBCT images.

1. We have added “*We collected the medical history and the patient gave no history of trauma, caries, and clinical symptoms of upper right central incisor. We speculated that the periapical periodontitis of the upper right central incisor might be associated with anterior occlusal interference.*” (See Imaging examinations Section, Page 6, Paragraph 1, Line 5-8)

Comment 9: *How can authors predict that the mandibular position will change to forward during orthodontic treatment? This is the critical point of this case.*

[Author response]

We thank the reviewer for this nice comment! The patient had a small baseline overjet. We inferred that the TMD might be related to the anterior occlusal interference. The pretreatment CBCT images and JSI indicated that the position of bilateral condyles had posterior displacement. Hence, we predicted that the TMD symptom would be alleviated and the mandibular position would change with the release of anterior occlusal interference.

Comment 10: *Superimposition of pre and posttreatment cephalogram did not show large change. Lateral facial view, CBCT, molar relationship also did not show large*

change. So, readers wonder if the mandible actually shifted to forward.

[Author response]

We thank the reviewer for this nice comment! The superimposition of pre and posttreatment cephalogram and lateral facial view did not change significantly, and it was difficult for them to visualize the small changes in joint space. We recommend CBCT imaging and JSI to reflect changes in condylar position. First of all, by using JSI to assess the condylar position, the right JSI after 22 months of retention was -43.2 and was larger than that obtained at pretreatment (-52.6), which confirmed the condylar shift forward. Secondly, CBCT superimposition of the pretreatment and retention bilateral TMJs in the transverse plane showed that the condylar shifted forward compared to the pretreatment. In addition, joint clicking disappeared, and TMJ pain was relieved after orthodontic treatment.

Comment 11: *Posttreatment CBCT image is not good (We cannot see the top of condyle).*

[Author response]

We thank the reviewer for this nice comment! It's a pity that we didn't obtain a complete posttreatment CBCT image. Therefore, we performed CBCT after 22 months of retention. Although the left condyle was not fully displayed again, the patient was unwilling to take CBCT one more time considering the radiation dose. Nevertheless, we can measure the JSI of the right condyle and perform the CBCT superimposition of bilateral condyles, and infer that the mandible was shifted forward.

Reviewer #2

Specific Comments to Authors: *Your abstract needs to be improved. The first sentence should briefly describe the condition (as at the start of the Introduction). Then the second sentence should start "We report the case of...." giving a very brief description. A third sentence should describe in general terms the treatment and the outcome.*

[Author response]

We thank the reviewer for this nice comment!

1. We have revised “*Temporomandibular joint disorders (TMDs) are common, and their exact causes are largely unknown. Since it is often difficult to find an obvious cause and the role of occlusal factors on the occurrence of TMDs is still unclear, it is tricky for orthodontists to treat malocclusions in patients with TMDs.*” into “*The role of occlusal factors on the occurrence of temporomandibular joint disorders (TMDs) is still unclear and it is tricky for orthodontists to treat malocclusions in patients with TMDs.*”. (See Abstract/Background Section, Page 1, Paragraph 1, Line 1-3)

2. We have added “*We report the case of the second orthodontic treatment of an adult female with Class II division 2 malocclusion associated with TMD. With the removal of anterior occlusal interference, TMD symptoms were alleviated and cone beam computed tomography (CBCT) images showed the bilateral condyles shifted forward.*”. (See Abstract/Background Section, Page 1, Paragraph 1, Line 3-7)

Reviewer #3

Specific Comments to Authors: *Punctuation may kindly be corrected.*

[Author response]

Thank the reviewer for this comment!

1. We have revised “*the 0.022 × 0.028-inch slot*” into “*the 0.022 * 0.028-inch slot*”. (See TREATMENT Section, Page 8, Paragraph 2, Line 3)

2. We have revised “*0.018 × 0.025-inch stainless steel working wire*” into “*0.018 * 0.025-inch stainless steel working wire*”. (See Abstract Section, Page 8, Paragraph 2, Line 6)

Orthers

1. We have revised “*This case report presented an orthodontic retreatment of an adult female with temporomandibular joint disorder (TMD) and significant mandibular backward positioning based on cone beam computed tomography (CBCT) examination*” into “*This case report presented an orthodontic retreatment of an adult female with TMD and mandibular backward positioning based on CBCT*”

examination”. (See Abstract/case summary Section, Page 1, Paragraph 1, Line 1-2)

2. We have revised “Temporomandibular joint symptoms disappeared with the release of functional factors” into “Temporomandibular joint symptoms were alleviated with the removal of anterior occlusal interference”. (See Abstract/Core tip Section, Page 2, Paragraph 1, Line 10-11)

3. We have revised “the TMJ” into “the temporomandibular joint (TMJ)”. (See Introduction section, Page 3, Paragraph 2, Line 2-3)

4. We have revised “temporomandibular joint disorder (TMD)” into “TMD”. (See Introduction section, Page 4, Paragraph 2, Line 2)

5. We have revised “[11]” into “[13]”. (See Treatment Section, Page 5, Paragraph 2, Line 11)

6. We have revised “[13]” into “[14]”. (See Treatment Section, Page 7, Paragraph 1, Line 3)

7. We have revised “[13]” into “[14]”. (See Treatment Section, Page 7, Paragraph 1, Line 6)

8. We have revised “[14]” into “[15]”. (See Discussion Section, Page 10, Paragraph 1, Line 5)

9. We have revised “[15]” into “[16]”. (See Discussion Section, Page 10, Paragraph 1, Line 9)

10. We have revised “[16]” into “[17]”. (See Discussion Section, Page 10, Paragraph 1, Line 11)

11. We have revised “[17]” into “[18]”. (See Discussion Section, Page 10, Paragraph 2, Line 1)

12. We have revised “[18]” into “[19]”. (See Discussion Section, Page 10, Paragraph 2, Line 6)

13. We have revised “[19,20]” into “[20,21]”. (See Discussion Section, Page 10, Paragraph 2, Line 10)

14. We have revised “[21]” into “[22]”. (See Discussion Section, Page 11,

Paragraph 1, Line 6)

15. We have revised “[22]” into “[23]”. (See Discussion Section, Page 11, Paragraph 1, Line 8)

16. We have revised “[23]” into “[24]”. (See Discussion Section, Page 11, Paragraph 1, Line 13)

17. We have revised “[24]” into “[25]”. (See Discussion Section, Page 11, Paragraph 1, Line 16)

18. We have revised “[25]” into “[26]”. (See Discussion Section, Page 11, Paragraph 2, Line 3)

19. We have revised “[26]” into “[27]”. (See Discussion Section, Page 12, Paragraph 1, Line 5)

20. We have revised “[11, 27]” into “[13, 28]”. (See Discussion Section, Page 12, Paragraph 1, Line 5)

21. We have revised “[12]” into “[11]”. (See Discussion Section, Page 12, Paragraph 1, Line 8)

22. We have revised “*led to retrusion of the mandible*” into “*led to backward positioning of the mandible*”. (See Discussion Section, Page 12, Paragraph 1, Line 13)

23. We have revised “*joint symptoms disappeared without using Class II elastic traction*” into “*joint symptoms were alleviated without using Class II elastic traction*”. (See Discussion Section, Page 12, Paragraph 1, Line 17)

24. We have revised “[28]” into “[29]”. (See Discussion Section, Page 13, Paragraph 1, Line 8)

25. We have revised “*mandibular retrusion could be associated with TMD. TMD symptoms might be alleviated with the release of mandibular backward positioning*” into “*mandibular backward positioning could be correlated with TMD and TMD symptoms might be alleviated with the mandibular forward repositioning for this situation*”. (See Conclusion Section, Page 13, Paragraph 1, Line 1-3)

26. We have revised “11” into “13”. (See References Section, Page 15, Line 17)

27. We have revised “12” into “11”. (See References Section, Page 15, Line 10)
28. We have added “12 Pereira MRV. *Quantitative Auswertungen bildgebender Verfahren und Entwicklung einer neuen metrischen Analyse für Kiefergelenkstrukturen im Magnetresonanztomogramm: Verlag nicht ermittelbar; 1997.*”. (See References Section, Page 15, Line 14-16)
29. We have revised “13” into “14”. (See References Section, Page 15, Line 21)
30. We have revised “14” into “15”. (See References Section, Page 15, Line 23)
31. We have revised “15” into “16”. (See References Section, Page 15, Line 27)
32. We have revised “16” into “17”. (See References Section, Page 16, Line 2)
33. We have revised “17” into “18”. (See References Section, Page 16, Line 5)
34. We have revised “18” into “19”. (See References Section, Page 16, Line 7)
35. We have revised “19” into “20”. (See References Section, Page 16, Line 12)
36. We have revised “20” into “21”. (See References Section, Page 16, Line 16)
37. We have revised “21” into “22”. (See References Section, Page 16, Line 19)
38. We have revised “22” into “23”. (See References Section, Page 16, Line 23)
39. We have revised “23” into “24”. (See References Section, Page 16, Line 27)
40. We have revised “24” into “25”. (See References Section, Page 17, Line 1)
41. We have revised “25” into “26”. (See References Section, Page 17, Line 5)
42. We have revised “26” into “27”. (See References Section, Page 17, Line 8)
43. We have revised “27” into “28”. (See References Section, Page 17, Line 11)
44. We have revised “28” into “29”. (See References Section, Page 17, Line 15)