

World Journal of *Orthopedics*

World J Orthop 2017 July 18; 8(7): 524-605



**MINIREVIEWS**

- 524 Radiation exposure and reduction in the operating room: Perspectives and future directions in spine surgery

Narain AS, Hijji FY, Yom KH, Kudaravalli KT, Haws BE, Singh K

- 531 Use of recombinant human bone morphogenetic protein-2 in spine surgery

Lykissas M, Gkiatas I

ORIGINAL ARTICLE**Basic Study**

- 536 Possibilities for arthroscopic treatment of the ageing sternoclavicular joint

Rathcke M, Tranum-Jensen J, Krogsgaard MR

Retrospective Study

- 545 Epidemiology of open fractures in sport: One centre's 15-year retrospective study

Wood AM, Robertson GAJ, MacLeod K, Porter A, Court-Brown CM

- 553 Acetabular revisions using porous tantalum components: A retrospective study with 5-10 years follow-up

Evola FR, Costarella L, Evola G, Barchitta M, Agodi A, Sessa G

- 561 Non-ossifying fibromas: Case series, including in uncommon upper extremity sites

Sakamoto A, Arai R, Okamoto T, Matsuda S

Observational Study

- 567 Distal radius volar rim plate: Technical and radiographic considerations

Spiteri M, Roberts D, Ng W, Matthews J, Power D

SYSTEMATIC REVIEWS

- 574 Return to sport following tibial plateau fractures: A systematic review

Robertson GAJ, Wong SJ, Wood AM

- 588 Systematic review on the use of autologous matrix-induced chondrogenesis for the repair of articular cartilage defects in patients

Shaikh N, Seah MKT, Khan WS

CASE REPORT

- 602 Painless swollen calf muscles of a 75-year-old patient caused by bilateral venous malformations

Piekaar RSM, Zwitter EW, Hedeman Joosten PPA, Jansen JA

Contents

World Journal of Orthopedics
Volume 8 Number 7 July 18, 2017

ABOUT COVER

Editorial Board Member of *World Journal of Orthopedics*, Michalis Zenios, BM BCh, MSc, Senior Lecturer, Paediatric Orthopaedics, University of Nicosia, Limassol 3025, Cyprus

AIM AND SCOPE

World Journal of Orthopedics (*World J Orthop*, *WJO*, online ISSN 2218-5836, DOI: 10.5312) is a peer-reviewed open access academic journal that aims to guide clinical practice and improve diagnostic and therapeutic skills of clinicians.

WJO covers topics concerning arthroscopy, evidence-based medicine, epidemiology, nursing, sports medicine, therapy of bone and spinal diseases, bone trauma, osteoarthritis, bone tumors and osteoporosis, minimally invasive therapy, diagnostic imaging. Priority publication will be given to articles concerning diagnosis and treatment of orthopedic diseases. The following aspects are covered: Clinical diagnosis, laboratory diagnosis, differential diagnosis, imaging tests, pathological diagnosis, molecular biological diagnosis, immunological diagnosis, genetic diagnosis, functional diagnostics, and physical diagnosis; and comprehensive therapy, drug therapy, surgical therapy, interventional treatment, minimally invasive therapy, and robot-assisted therapy.

We encourage authors to submit their manuscripts to *WJO*. We will give priority to manuscripts that are supported by major national and international foundations and those that are of great basic and clinical significance.

INDEXING/ABSTRACTING

World Journal of Orthopedics is now indexed in Emerging Sources Citation Index (Web of Science), PubMed, PubMed Central and Scopus.

FLYLEAF

I-III Editorial Board

EDITORS FOR THIS ISSUE

Responsible Assistant Editor: *Xiang Li*
Responsible Electronic Editor: *Huan-Liang Wu*
Proofing Editor-in-Chief: *Lian-Sheng Ma*

Responsible Science Editor: *Jin-Xin Kong*
Proofing Editorial Office Director: *Jin-Lei Wang*

NAME OF JOURNAL
World Journal of Orthopedics

ISSN
ISSN 2218-5836 (online)

LAUNCH DATE
November 18, 2010

FREQUENCY
Monthly

EDITORS-IN-CHIEF
Quanjun (Trey) Cui, MD, Professor, Department of Orthopaedic Surgery, School of Medicine, University of Virginia, Charlottesville, VA 22908, United States

Bao-Gan Peng, MD, PhD, Professor, Department of Spinal Surgery, General Hospital of Armed Police Force, Beijing 100039, China

EDITORIAL BOARD MEMBERS
All editorial board members resources online at <http://www.wjgnet.com>

www.wjgnet.com/2218-5836/editorialboard.htm

EDITORIAL OFFICE
Xiu-Xia Song, Director
World Journal of Orthopedics
Baishideng Publishing Group Inc
7901 Stoneridge Drive, Suite 501, Pleasanton, CA 94588, USA
Telephone: +1-925-2238242
Fax: +1-925-2238243
E-mail: editorialoffice@wjgnet.com
Help Desk: <http://www.fjpublishing.com/helpdesk>
<http://www.wjgnet.com>

PUBLISHER
Baishideng Publishing Group Inc
7901 Stoneridge Drive,
Suite 501, Pleasanton, CA 94588, USA
Telephone: +1-925-2238242
Fax: +1-925-2238243
E-mail: bpgoffice@wjgnet.com
Help Desk: <http://www.fjpublishing.com/helpdesk>
<http://www.wjgnet.com>

PUBLICATION DATE
July 18, 2017

COPYRIGHT
© 2017 Baishideng Publishing Group Inc. Articles published by this Open-Access journal are distributed under the terms of the Creative Commons Attribution Non-commercial License, which permits use, distribution, and reproduction in any medium, provided the original work is properly cited, the use is non commercial and is otherwise in compliance with the license.

SPECIAL STATEMENT
All articles published in journals owned by the Baishideng Publishing Group (BPG) represent the views and opinions of their authors, and not the views, opinions or policies of the BPG, except where otherwise explicitly indicated.

INSTRUCTIONS TO AUTHORS
<http://www.wjgnet.com/bpg/gerinfo/204>

ONLINE SUBMISSION
<http://www.fjpublishing.com>

Basic Study

Possibilities for arthroscopic treatment of the ageing sternoclavicular joint

Martin Rathcke, Jørgen Tranum-Jensen, Michael Rindom Krogsgaard

Martin Rathcke, Michael Rindom Krogsgaard, Section for Sportstraumatology M51, Bispebjerg-Frederiksberg Hospital, DK-2400 Copenhagen NV, Denmark

Jørgen Tranum-Jensen, Department of Cellular and Molecular Medicine, University of Copenhagen, DK-2200 Copenhagen N, Denmark

Author contributions: All three authors have participated equally in planning the study, examining the specimens, analyzing the results and writing the manuscript.

Institutional review board statement: The study was approved by the head of the body donation program at Department of Cellular and Molecular Medicine (ICMM) at the University of Copenhagen.

Conflict-of-interest statement: None. Each author certifies that he has no commercial associations (e.g., consultancies, stock ownership, equity interest, patent/licensing arrangements, etc.) that might pose a conflict of interest in connection with the submitted article.

Data sharing statement: No additional data are available.

Open-Access: This article is an open-access article which was selected by an in-house editor and fully peer-reviewed by external reviewers. It is distributed in accordance with the Creative Commons Attribution Non Commercial (CC BY-NC 4.0) license, which permits others to distribute, remix, adapt, build upon this work non-commercially, and license their derivative works on different terms, provided the original work is properly cited and the use is non-commercial. See: <http://creativecommons.org/licenses/by-nc/4.0/>

Manuscript source: Invited manuscript

Correspondence to: Michael Rindom Krogsgaard, MD, PhD, Professor, Specialist in Orthopaedic Surgery, Section for Sportstraumatology M51, Bispebjerg-Frederiksberg Hospital, Bispebjerg Bakke 23, DK-2400 Copenhagen NV, Denmark. mrk@dadlnet.dk
Telephone: +45-3531-3817
Fax: +45-3531-1880

Received: November 19, 2016

Peer-review started: November 23, 2016

First decision: February 15, 2017

Revised: April 17, 2017

Accepted: May 3, 2017

Article in press: May 5, 2017

Published online: July 18, 2017

Abstract

AIM

To investigate if there are typical degenerative changes in the ageing sternoclavicular joint (SCJ), potentially accessible for arthroscopic intervention.

METHODS

Both SCJs were obtained from 39 human cadavers (mean age: 79 years, range: 59-96, 13 F/26 M). Each frozen specimen was divided frontally with a band saw, so that both SCJs were opened in the same section through the center of the discs. After thawing of the specimens, the condition of the discs was evaluated by probing and visual inspection. The articular cartilages were graded according to Outerbridge, and disc attachments were probed. Cranio-caudal heights of the joint cartilages were measured. Superior motion of the clavicle with inferior movement of the lateral clavicle was measured.

RESULTS

Degenerative changes of the discs were common. Only 22 discs (28%) were fully attached and the discs were thickest superiorly. We found a typical pattern: Detachment of the disc inferiorly in connection with thinning, fraying and fragmentation of the inferior part of the disc, and detachment from the anterior and/or posterior capsule. Severe joint cartilage degeneration \geq grade 3 was more common on the clavicular side (73%) than on the sternal side (54%) of the joint. In cadavers

< 70 years 75% had \leq grade 2 changes while this was the case for only 19% aged 90 years or more. There was no difference in cartilage changes when right and left sides were compared, and no difference between sexes. Only one cadaver - a woman aged 60 years - had normal cartilages.

CONCLUSION

Changes in the disc and cartilages can be treated by resection of disc, cartilage, intraarticular osteophytes or medial clavicle end. Reattachment of a degenerated disc is not possible.

Key words: Sternoclavicular; Degenerative; Cartilage; Disc; Arthroscopy

© The Author(s) 2017. Published by Baishideng Publishing Group Inc. All rights reserved.

Core tip: Arthroscopic treatment is an option in patients with symptoms from the ageing sternoclavicular joint (SCJ). However, knowledge of age-related changes is essential for planning of such arthroscopic procedures. In 78 human cadaveric SCJs with a mean age of 79 years (range: 59-96 years) we found that degenerative changes of the discs were common, in particular inferior detachment, and only 28% were fully attached. Severe cartilage degeneration was more common on the clavicular than the sternal side. When there was inferior detachment of the disc, we observed increased supero-medial gliding of the clavicle. We conclude that a torn disc or degenerated articular cartilage might be treated by arthroscopic resection, debridement and clavicle end resection. Reattachment of a degenerated disc is not possible.

Rathcke M, Tranum-Jensen J, Krogsgaard MR. Possibilities for arthroscopic treatment of the ageing sternoclavicular joint. *World J Orthop* 2017; 8(7): 536-544 Available from: URL: <http://www.wjgnet.com/2218-5836/full/v8/i7/536.htm> DOI: <http://dx.doi.org/10.5312/wjo.v8.i7.536>

INTRODUCTION

Arthroscopy has opened for specific procedures on the sternoclavicular joint (SCJ), *e.g.*, resection of a torn intraarticular disc. Changes of the joint with age might be expected just like it is seen in the acromioclavicular joint, due to the substantial gliding and rotation in both joints during movement of the arm^[1-3]. Resection of the lateral clavicle end is a common procedure for painful osteoarthritis of the acromioclavicular joint. The prevalence of symptoms from SCJ is unknown, but surgery on the joint is infrequent^[4-6], partly by tradition and perhaps of fear to injure vessels and lungs adjacent to its posterior capsule^[7].

Open resection of the articular disc and capsulorrhaphy in patients with degenerative disease of the

SCJ has been reported successful in 6 patients^[8]. Open resection of the medial clavicular end show good results in treatment for SCJ osteoarthritis^[9,10] when the costoclavicular ligament is kept intact^[10-12]. However, the scar after open surgery can be cosmetically prominent because of the location.

Arthroscopic surgery of the SCJ can be performed through two portals (Figure 1), leaving minor scars, using a 2.7 mm arthroscope and standard instruments (Figure 2). The two portals give access to both compartments of the joint on either side of the articular disc. The depth of the joint is about 1.5 cm, and care should be taken not to exceed this during introduction of the arthroscope, in order not to penetrate the posterior capsule. Once the arthroscope is introduced all structures are usually easy to identify, and resection of the disc, medial clavicle or intraarticular osteophytes, as well as synovectomy and removal of loose bodies can be performed under visual control without risk of penetrating into the mediastinum.

The articular disc of SCJ is superiorly attached to the medial end of the clavicle, inferiorly to the first rib at its junction with the manubrium and to the joint capsule. In older cadavers the disc is incomplete in 29%-56%^[13-16], with a central hole^[13,15,16] or a meniscoid appearance^[14]. During arthroscopy in younger patients (age mean 40 years, range: 16-70, 28 F/11 M) we have often found detachment of the disc from the anterior capsule and marked disintegration of the disc at the inferior part with detachment from manubrium (Figure 3) (unpublished).

These differences in reported changes are confusing in relation to whether there is an anatomic basis for arthroscopic treatment of the disc in the painful ageing SCJ.

Degenerative changes of the articular cartilage are reported to be more severe on the medial clavicle compared to manubrium^[16], which is surprising as the superior part of the clavicular cartilage only articulates when the arm is abducted.

Our aims were to study the anatomy of the SCJ, focusing on the occurrence of conditions that are potentially accessible for surgical intervention. Also, to evaluate if the hyaline cartilages on the clavicle and manubrium are equally affected by age, and if degenerative conditions and detachment of the disc has any influence on medial end clavicular stability.

MATERIALS AND METHODS

From 39 formalin embalmed human cadavers (age mean: 79 years, range: 59-96, 13 F/26 M) we obtained both SCJs. The sternum was cut at level of the second rib, and clavicles and first rib were cut lateral to the costoclavicular ligament. To be able to examine the capsular attachments of the intraarticular disc, each specimen was frozen and divided frontally with a thin band saw, so that both SCJs were opened in the

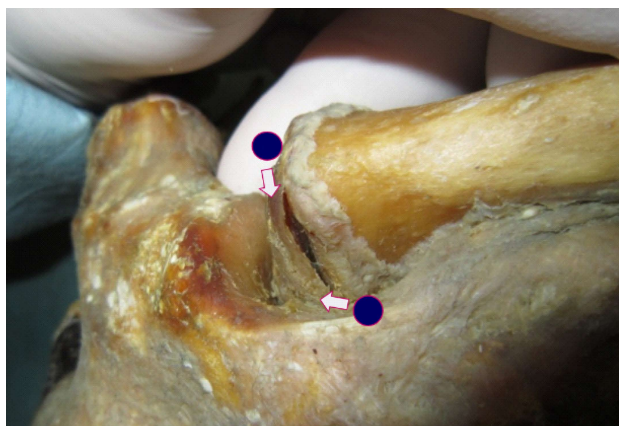


Figure 1 The two standard portals for sternoclavicular arthroscopy.

same section through the center of the disc (Figure 4). Examination of the joints was performed after the specimens had been thawed and stored in 30% ethanol. The cut surfaces were cleaned with a dry cloth. The height of the articular cartilage (cranio-caudal) on the clavicle and manubrium was measured (Figure 5). The attachments of the intraarticular disc to the clavicle and first rib-manubrium junction as well as to the anterior and posterior capsule were probed with a hooked arthroscopic probe (Figure 6). Any detachment was recorded. The disc was probed, and holes, fraying and flap lesions were visually inspected and recorded. The thickest and thinnest parts of the disc were measured with a calipergauge designed especially for this purpose (Figure 7). The cartilage at the medial clavicular end and at manubrium was classified according to Outerbridge^[17] based on visual inspection and probing, and by agreement of two observers. Information about the age and sex of the cadavers was obtained after the measurements had been recorded. There were no signs of previous surgery to any of the SCJs.

Ethical considerations

The study was conducted on deceased who had bequeathed their bodies to science and education at the Department of Cellular and Molecular Medicine (ICMM) at the University of Copenhagen according to Danish legislation (Health Law #546, § 188). The study was approved by the head of the body donation program at ICMM. The study was performed at Department of Cellular and Molecular Medicine (ICMM), University of Copenhagen, Denmark.

Statistical analysis

The data are presented as mean \pm SD. For the statistics, Student's *t* test was used. *P* < 0.05 was considered as statistically significant.

RESULTS

In the 26 males 4 discs were missing on the right side,

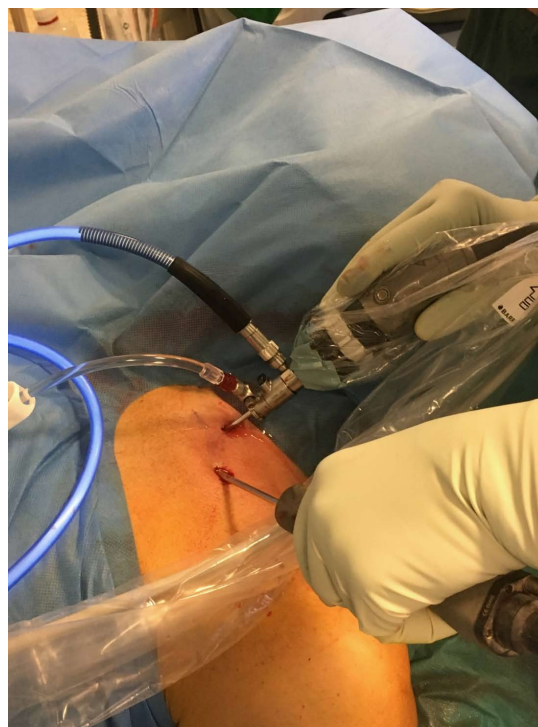

Figure 2 Sternoclavicular arthroscopy performed with the patient supine, using a 2.7 mm arthroscope and a 4.0 mm shaver.

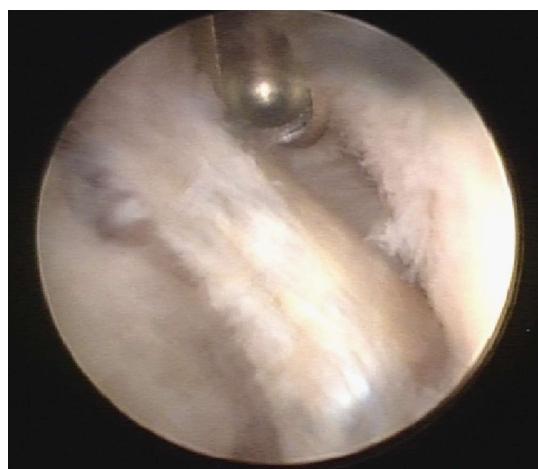


Figure 3 Arthroscopic view of the left sternoclavicular joint showing degenerative changes in the partially resected disc (in the middle) and chondral degeneration of the clavicular cartilage (right side of photo). The shaver is introduced through the superior portal.

1 joint was ankylotic and 21 discs were present, but 4 of these had a central hole. On the left side 4 discs were missing, 22 were present and 3 of these had a central hole.

In the 13 females 3 discs were missing on the right side, 10 were present and 4 of these had a central hole. On the left side 2 discs were missing, 11 were present and 4 of these had a central hole.

Figure 8 visualizes the attachments of the discs, illustrating that the discs were most often detached inferiorly. Only 22 discs (28%) were fully attached.

In nearly all cases the disc was thickest superiorly.

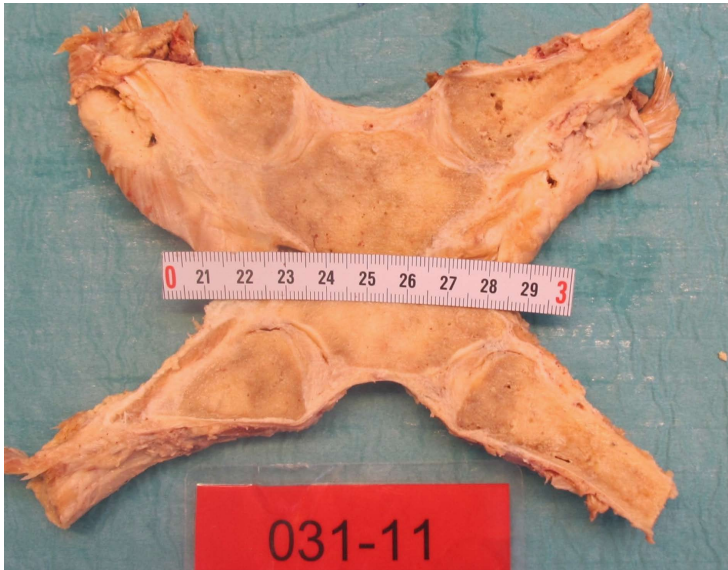

Figure 4 The sternoclavicular joints were divided frontally with a thin band saw so that both sternoclavicular joints were unfolded in the same section through the center of the discs.

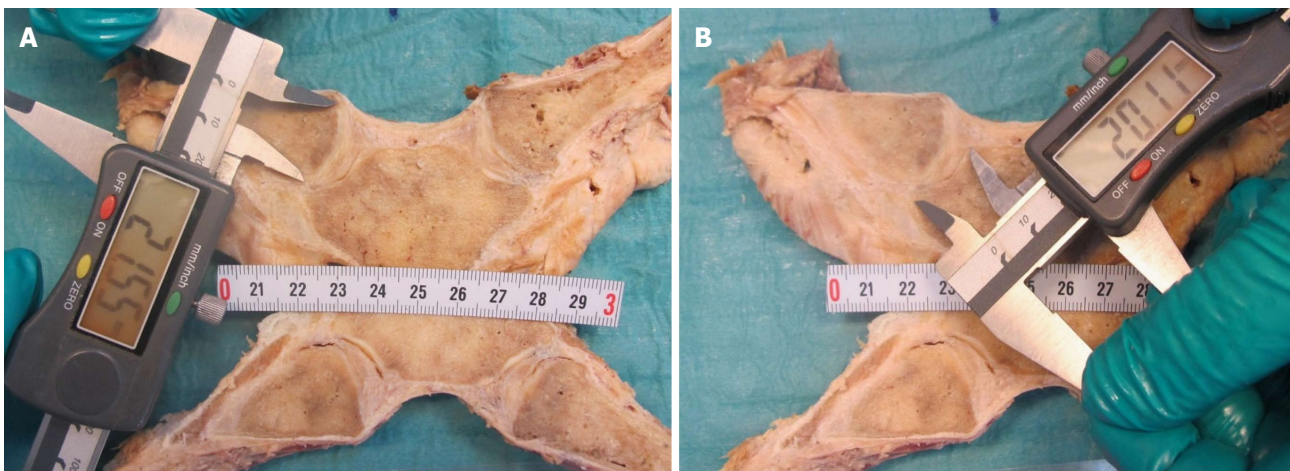


Figure 5 Measurement of the height of the articular cartilages (cranial-caudal) on the clavicle (A) and manubrium (B).

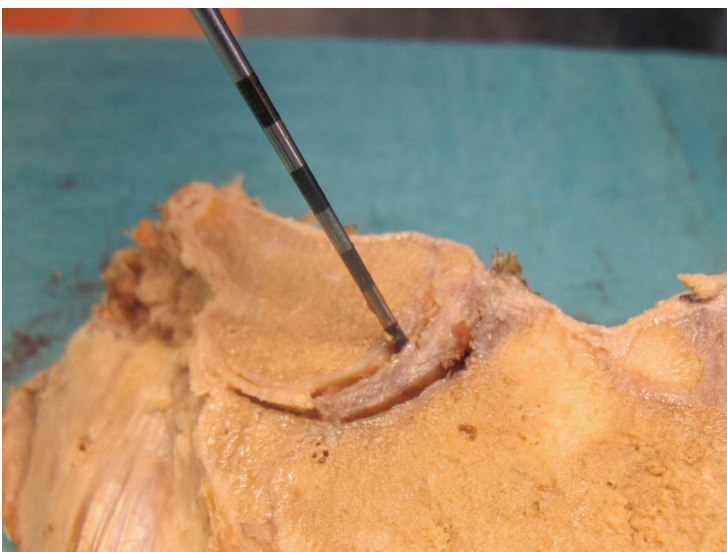


Figure 6 Probing the attachments of the intraarticular disc to the clavicle and first rib-manubrium junction as well as to the anterior and posterior capsule with a hooked arthroscopic probe.

All but one cadaver - a woman aged 60 years - showed degenerative changes of the cartilages. Grade 5 changes (no cartilage) were not seen in any of

the specimens, but one joint was ankylotic (no joint cavity). Severe degeneration \geq grade 3 was seen in 73% on the clavicular side and 54% on the sternal




Figure 7 Measurement of the thickest and thinnest parts of the intraarticular discs with a calliper gauge.

side, confirming that degenerative changes are more common on the clavicular side of the joint. In cadavers < 70 years 75% had \leq grade 2 changes, while this was the case for only 19% aged 90 years or more. In the age groups 70-79 and 80-89 years 33%-35% had \leq grade 2 changes. There was no difference in cartilage changes when right and left sides were compared, and no difference between sexes ($P > 0.05$).

We found a typical pattern: Detachment of the disc inferiorly with thinning, fraying and fragmentation of the inferior part of the disc, and detachment from the anterior and/or posterior capsule. Typical examples of changes in the discs are shown in Figure 9.

In the cases with inferior detachment we found a marked increase in supero-medial displacement of the medial clavicular end compared to cases with intact inferior attachment, when a light medially directed push was applied to the lateral clavicle shaft ($P < 0.05$) (Figure 9).

The mean cranio-caudal length \pm 1 SD of the joint cartilages was in male cadavers on the right side 26.0 ± 3.1 mm on the clavicle and 18.1 ± 2.0 mm on the sternum, and on the left side 25.4 ± 2.9 mm and 17.9 ± 2.3 mm, respectively, while in female cadavers on the right side it was 23.5 ± 2.9 mm on the clavicle and 17.2 ± 1.7 mm on the sternum, and on the left side 24.1 ± 3.0 mm and 17.5 ± 2.1 mm, respectively. All data are shown in Table 1.

DISCUSSION

Our main purpose was to evaluate if changes to the intraarticular disc in the ageing SCJ could explain painful mechanical symptoms that are seen in some patients. In light of previous reports we were surprised by the marked changes of the discs observed in the majority of the SCJs. In a large cadaver study^[16] 56% of discs were found to be incomplete, but the defects were described as a central hole and fraying.

In our study the changes were much more general; in particular inferior detachment was a common finding (20/39 right, 16/39 left). This pattern resembles what we have seen in arthroscopic examination of the SCJ in symptomatic patients with degenerative joint disease. An inferiorly detached disc is more likely to produce mechanical symptoms than a central hole as it is unstable and may cause locking during motion of the joint.

We have no information about symptoms, work or sports activity for the donors. Based on the increasing pathology with increasing age, it is likely, that the changes in the disc and cartilages are of degenerative nature. In the specimens with complete inferior detachment of the disc there was supero-medial instability of the medial clavicular end. Motion of the clavicle relative to manubrium is during most activities sliding with no compression^[2]. When the shoulder is depressed the clavicle acts as a lever arm (ratio about 7:1) with the center of rotation (the fulcrum) at its crossing of the first rib (*i.e.*, the site of the costoclavicular ligament), then the sternal end of the clavicle is lifted forcibly upwards. With increased motion of the clavicle, symptoms from an unstable, degenerated disc and degenerated cartilages are likely to increase. A forceful depression of the shoulder, *e.g.*, during lifting a heavy load, applies a substantial load on the interclavicular ligament^[1,15]. It is not known to which extent force is absorbed in the disc during lifting, but the attachment of the disc inferiorly on the manubrium and superiorly on the upper facet of the clavicular joint surface indicates that the disc in this respect may function as a ligament, working in synergy with the interclavicular ligament. Histological examination of the disc has shown the most common collagen fibers to be type I, III and V^[18] which are all strong fibrillar collagens, designed to resist force.

Slackness of the interclavicular ligament with age might result in increased tension on the disc during




Figure 8 Graphic visualization of the attachments we found of the discs in left (left) and right (right) sternoclavicular joints of males and females. Black lines: Full attachment of all four sectors; red lines: Attachment of three sectors; green lines: Attachment of two sectors; blue lines: Attachment of one sector only. inf: Inferior, sup: Superior; post: Posterior; ant: Anterior.

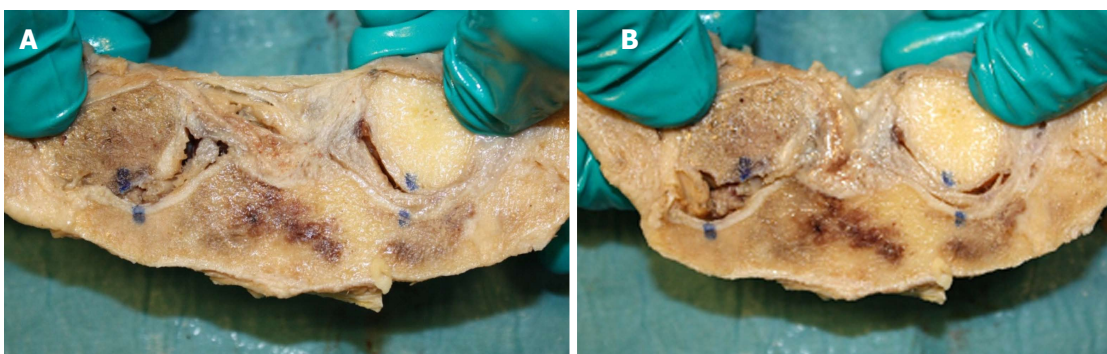


Figure 9 With inferior detachment (the sternoclavicular joint to the left) there was a substantial increase in supero-medial displacement of the medial clavicular end when a light medially directed push was applied to the lateral clavicle shaft (A: Light pull, B: Push). With full attachment of the disc (as seen in the joint to the right) this displacement was much smaller. Blue dots were marked when no external forces were applied to the joints.

lifting, and, in addition to the compressive forces on the inferior part of the disc during motion, this may

be an explanation for the high rate of thinning and detachment of the inferior part of the disc.

Table 1 Characteristics of the cadavers, the articular cartilage and the disc of the sternoclavicular joint

Age (yr)	Sex	Right thinnest/thickest part of disc mm ¹	Left thinnest/thickest part of disc mm ¹	Right attach- ment disc ²	Left attach- ment disc ²	Right cartilage C/S mm	Left cartilage C/S mm	Right cartilage quality C/S ³	Left cartilage quality C/S ³
59	F	2.1 i/3.1 s	2.2 i/4.4 s	1	5	21/15	22/14	2/2	3/3
60	F	0 i/3.9 s	0.5 i/3.9 s	5	1	23/18	25/20	0/0	0/0
65	M	2.3 i/4.3 s	4.4 i/6.4 s	1	1	24/17	26/17	2/1	2/1
65	F	1.7 i/4.8 s	0/2.4	1	5	27/18	24/21	1/1	4/4
66	M	2.2 i/4.3 s	0.9 i/4.2 s	5	1	30/19	26/21	1/1	3/1
71	M	1.2 i/4.5 s	2.2 i/6.3 s	4 + 5	1	32/20	29/21	3/2	2/3
71	M	0.6 i/1.6 s	0.9 i/2.2 s	3	5	21/17	22/13	3/3	3/3
72	F	0 i/1.4 s	0 c/2.6 s	2 + 5	1	25/18	26/19	3/2	3/2
73	M	Absent	Absent	Absent	Absent	31/20	29/21	3/3	3/3
73	M	0/3.2 anterior rim	0/4.0 anterior rim	3 + 4 + 5	3 + 4 + 5	28/18	24/17	3/4	3/4
74	M	2.9 i/3.8 s	2.0 s/3.3 i	2 + 4 + 5	1	29/19	28/17	3/2	3/2
75	F	Absent	2.1 i/2.8 s	Absent	5	19/15	18/14	3/2	1/1
75	M	2.5 i/3.5 s	1.1 i/4.1 s	5	1	25/14	25/18	3/3	2/3
76	M	0/2.2 i (flap)	2.3 i + s/3.8 c	3 + 4	1	27/17	25/17	4/4	2/3
78	M	3.5 i/4.5 s	3.5 i/5.7 s	3	1	27/19	25/22	3/3	3/3
78	M	2.3 i/3.0 s	1.0 i/2.9 s	5	5	26/17	27/18	2/1	2/1
78	M	Absent	0.9 i/3.4 s	Absent	1	25/17	29/19	4/4	3/3
79	M	0 i/0.8 s	0/2.7 s	5	5	21/17	21/17	2/3	3/2
79	M	2.0 i/3.7 s	Absent	5	Absent	29/21	28/20	3/3	2/2
79	M	0.5 i/3.9 s	0.1 i/4.4 s	1	1	24/16	21/16	3/2	4/2
79	M	Ankylosis	2.0 i/5.2 s	Ankylosis	4 + 5	25/20	23/16	Ankylosis	3/3
81	F	1.8 i/3.3 s	0/2.9 s	5	4 + 5	24/17	25/17	2/1	1/1
81	F	Absent	1.2 s/2.7 i	Absent	3	26/20	28/19	4/4	3/2
83	M	1.0 s/2.9 i	3.0 i/3.6 s	5	5	28/21	24/13	4/3	4/2
84	M	2.3 i/5.4 s	3.0 i/4.9 s	5	1	26/20	26/19	3/1	2/1
84	M	1.0 i/1.7 s	1.6 s/1.4 i	1	1	24/16	24/19	3/1	3/1
84	M	Absent	Absent	Absent	Absent	23/20	24/19	3/4	3/3
85	M	2.4 i/2.7 s	1.2 i/3.5 s	3 + 4 + 5	1	22/17	21/16	4/2	4/2
85	F	2.3 i/4.0 s	0/2.2 anterior rim	5	3 + 4 + 5	25/18	24/17	4/2	3/3
86	F	Absent	Absent	Absent	Absent	20/16	20/16	3/4	3/4
89	F	1.0 i/2.7 s	Absent	2 + 5	Absent	22/15	23/16	1/1	3/3
90	F	0.8 i/2.5 s	1.1 s/1.2 i	1	1	29/19	29/21	3/3	2/2
90	M	3.3 i/3.6 s	2.5 i/2.9 s	4 + 5	5	26/18	28/18	4/3	4/3
90	F	0/1.9 anterior rim	1.5 i/2.5 s	3 + 4 + 5	5	23/19	23/17	4/4	4/4
91	F	0 c/3.1 s	1.5 i/0 s	1	4	21/16	26/18	4/3	4/3
92	M	Absent	1.9 s/3.4 i	2 + 4 + 5	5	21/14	20/16	3/4	2/2
93	M	0/0 (absent)	0/3.2 s	Absent	4 + 5	31/18	31/17	3/3	4/4
94	M	1.7 i/3.3 s	Absent	2 + 5	Absent	26/21	27/21	3/2	4/4
96	M	0/2.2 anterior rim	0/3.8 anterior rim	3 + 4 + 5	3 + 4 + 5	26/18	28/17	4/4	4/4

¹i: Inferior; s: Superior. ²1: Full attachment; 2: Detachment anterior; 3: Detachment superior; 4: Detachment posterior; 5: Detachment inferior. ³Outerbridge classification: 0: Normal cartilage; 5: No cartilage. M: Male; F: Female.

In addition, the fact that the cranio-caudal length of the articular surface of the clavicle was about 40% longer than the articular surface on the manubrium, meaning that the upper third of the disc is not subject to compressive or frictional forces in most working situations, may explain why the superior part of the disc is often intact.

It is described that symptomatic SCJs with degenerative changes have an increased size of the clavicular head and a relative anterior subluxation of the clavicle compared to asymptomatic joints^[1], but not a superior subluxation. Even though the intraarticular disc in most of these joints must be expected to be severely changed and unable to prevent the clavicular head from superior motion during lifting, the enlargement of the head, related to the degenerative condition, might pull the interclavicular ligament superiorly, resulting in

a tightening of the ligament. This could explain why the clavicular head in this situation is not subluxating superiorly during depression of the shoulder^[19].

There was an overweight of thinning and detachment of the inferior part of the disc on the right side compared to left and fewer normal discs on the right side. Of 91% are right dominant and some activities are performed with more power by the dominant arm. This increases load on the SCJ, its ligaments and the disc, and may cause additional wear on the right SCJ on top of the degenerative wear that is affecting both sides.

We could confirm earlier findings of more severe changes of the cartilage on the clavicle compared to manubrium^[16]. Therefore, it makes sense to resect the clavicular and not the sternal part of the joint in case of surgery for osteoarthritis of the SCJ.

Arthroscopic surgery of the SCJ is described in a few series^[4-6,20]. Resection of the medial clavicular end is the procedure that has been reported in most of the cases^[4,5,20], and in open^[10] as well as arthroscopic^[4,5,20] series it resulted in marked pain reduction. The indication for this operation is degenerative changes that can be demonstrated by X-rays, MRI or CT-scan. In some cases of pain in the SCJ no such changes can be demonstrated. Our study shows that at least in the elderly population detachment of the articular disc is common. It is not known to which extent these changes in the disc are symptomatic, but detachment can probably lead to pain, locking and swelling, and technically it can be treated by arthroscopic debridement or resection of the disc as well as resection of the medial clavicular end. Pathology of the disc is not visible on X-rays or CT-scan, but can often be demonstrated on T2 weighted MRI-scans (personal experience). Persistent pain, locking and/or swelling of a SCJ without degenerative changes on X-rays or CT-scan might be caused by detachment or fraying of the disc, and an MRI-scan should be considered in these cases. The detachment and thinning of the discs inferiorly as found in our study means that surgical reattachment of the disc is impossible. Contrary, in case of traumatic detachment of otherwise normal discs in younger individuals, reattachment is an option in case of symptoms.

Detachment or destruction of the articular disc in the SCJ is a common finding in the aging population and can result in pain, locking and swelling which might be treated by resection of the torn disc. Degenerative changes of the articular cartilages are more common on the clavicle than on manubrium, and normal cartilage is rarely seen in this age group. Debridement, chondrectomy and medial clavicle resection may be relevant, but reattachment of the disc is not possible because of the marked tissue changes.

ACKNOWLEDGMENTS

We thank Johnny Grant and Lars-Bo Nielsen for preparation of the specimens and Keld Ottosen for preparing the graphic illustration (Figure 8).

COMMENTS

Background

Arthroscopy of the sternoclavicular joint (SCJ) is a recently introduced technique that has opened for more specific procedures on this joint, e.g., resection or reinsertion of a torn disc, synovectomy, chondrectomy and removal of loose bodies. Knowledge of age-related changes is essential for planning of arthroscopic procedures, and previous cadaver studies have shown conflicting results.

Research frontiers

Open surgical procedures on the SCJ leave a scar at a cosmetically problematic location, and visualization of the deep part of the joint is often limited. Arthroscopy makes full inspection of the SCJ possible. The arthroscopic procedure that has previously been reported in the SCJ is clavicle end resection

for osteoarthritis.

Innovations and breakthroughs

This is the first study to describe the SCJ in cadaver specimens prepared without interference with the joint capsule and disc attachment sites. The authors found degenerative changes to disc and joint cartilages to be much more common than previously thought and showing in a typical pattern.

Applications

Arthroscopic resection of disc, cartilages and clavicular end of the SCJ may be applied in cases of pain, locking or swelling that is resistant to non-surgical intervention.

Peer-review

This is very classic study on degenerative SCJ. The study demonstrated the stage of cartilage in SC comprehensively.

REFERENCES

- 1 Bearn JG. Direct observations on the function of the capsule of the sternoclavicular joint in clavicular support. *J Anat* 1967; **101**: 159-170 [PMID: 6047697]
- 2 Ludewig PM, Phadke V, Braman JP, Hassett DR, Cieminski CJ, LaPrade RF. Motion of the shoulder complex during multiplanar humeral elevation. *J Bone Joint Surg Am* 2009; **91**: 378-389 [PMID: 19181982 DOI: 10.2106/JBJS.G.01483]
- 3 Negri JH, Malavolta EA, Assunção JH, Gracitelli ME, Pereira CA, Bolliger Neto R, Croci AT, Ferreira Neto AA. Assessment of the function and resistance of sternoclavicular ligaments: A biomechanical study in cadavers. *Orthop Traumatol Surg Res* 2014; **100**: 727-731 [PMID: 25261174 DOI: 10.1016/j.otsr.2014.07.011]
- 4 Tytherleigh-Strong GM, Getgood AJ, Griffiths DE. Arthroscopic intra-articular disk excision of the sternoclavicular joint. *Am J Sports Med* 2012; **40**: 1172-1175 [PMID: 22459240 DOI: 10.1177/0363546512439286]
- 5 Tytherleigh-Strong G, Griffith D. Arthroscopic excision of the sternoclavicular joint for the treatment of sternoclavicular osteoarthritis. *Arthroscopy* 2013; **29**: 1487-1491 [PMID: 23910004 DOI: 10.1016/j.arthro.2013.05.029]
- 6 Tytherleigh-Strong G. Arthroscopy of the sternoclavicular joint. *Arthrosc Tech* 2013; **2**: e141-e145 [PMID: 23875140 DOI: 10.1016/j.eats.2013.01.005]
- 7 Van Tongel A, Van Hoof T, Pouliart N, Debeer P, D'Herde K, De Wilde L. Arthroscopy of the sternoclavicular joint: an anatomic evaluation of structures at risk. *Surg Radiol Anat* 2014; **36**: 375-381 [PMID: 23995518 DOI: 10.1007/s00276-013-1195-0]
- 8 Aumann U, Brüning W. [Discopathy of the sternoclavicular joint]. *Chirurg* 1980; **51**: 722-726 [PMID: 7471942]
- 9 Pingsmann A, Patsalis T, Michiels I. Resection arthroplasty of the sternoclavicular joint for the treatment of primary degenerative sternoclavicular arthritis. *J Bone Joint Surg Br* 2002; **84**: 513-517 [PMID: 12043770 DOI: 10.1302/0301-620X.84B4.12601]
- 10 Rockwood CA, Groh GI, Wirth MA, Grassi FA. Resection arthroplasty of the sternoclavicular joint. *J Bone Joint Surg Am* 1997; **79**: 387-393 [PMID: 9070528 DOI: 10.2106/00004623-199703000-00011]
- 11 Carrera EF, Archetti Neto N, Carvalho RL, Souza MA, Santos JB, Faloppa F. Resection of the medial end of the clavicle: an anatomic study. *J Shoulder Elbow Surg* 2007; **16**: 112-114 [PMID: 17055749 DOI: 10.1016/j.jse.2006.04.010]
- 12 Lee JT, Campbell KJ, Michalski MP, Wilson KJ, Spiegl UJ, Wijedicks CA, Millett PJ. Surgical anatomy of the sternoclavicular joint: a qualitative and quantitative anatomical study. *J Bone Joint Surg Am* 2014; **96**: e166 [PMID: 25274794 DOI: 10.2106/JBJS.M.01451]
- 13 Barbaix E, Lapierre M, Van Roy P, Clarijs JP. The sternoclavicular joint: variants of the discus articularis. *Clin Biomech* (Bristol, Avon) 2000; **15** Suppl 1: S3-S7 [PMID: 11078897 DOI: 10.1016/

- S0268-0033(00)00051-6]
- 14 **Emura K**, Arakawa T, Terashima T, Miki A. Macroscopic and histological observations on the human sternoclavicular joint disc. *Anat Sci Int* 2009; **84**: 182-188 [PMID: 19221859 DOI: 10.1007/s12565-009-0014-5]
 - 15 **Tubbs RS**, Loukas M, Slaphey JB, McEvoy WC, Linganna S, Shoja MM, Oakes WJ. Surgical and clinical anatomy of the interclavicular ligament. *Surg Radiol Anat* 2007; **29**: 357-360 [PMID: 17563831 DOI: 10.1007/s00276-007-0219-z]
 - 16 **van Tongel A**, MacDonald P, Leiter J, Pouliart N, Peeler J. A cadaveric study of the structural anatomy of the sternoclavicular joint. *Clin Anat* 2012; **25**: 903-910 [PMID: 22991168 DOI: 10.1002/ca.22021]
 - 17 **Outerbridge RE**. The etiology of chondromalacia patellae. *J Bone Joint Surg Br* 1961; **43-B**: 752-757 [PMID: 14038135]
 - 18 **Shimada K**, Takeshige N, Moriyama H, Miyauchi Y, Shimada S, Fujimaki E. Immunohistochemical study of extracellular matrices and elastic fibers in a human sternoclavicular joint. *Okajimas Folia Anat Jpn* 1997; **74**: 171-179 [PMID: 9446929 DOI: 10.2535/ofaj1936.74.5_171]
 - 19 **Van Tongel A**, Valcke J, Piepers I, Verschueren T, De Wilde L. Relationship of the Medial Clavicular Head to the Manubrium in Normal and Symptomatic Degenerated Sternoclavicular Joints. *J Bone Joint Surg Am* 2014; **96**: e109 [PMID: 24990983 DOI: 10.2106/JBJS.M.00623]
 - 20 **Tavakkolizadeh A**, Hales PF, Janes GC. Arthroscopic excision of sternoclavicular joint. *Knee Surg Sports Traumatol Arthrosc* 2009; **17**: 405-408 [PMID: 19089407 DOI: 10.1007/s00167-008-0692-x]

P- Reviewer: Anand A, Tawonsawatruk T **S- Editor:** Song XX
L- Editor: A **E- Editor:** Wu HL





Published by **Baishideng Publishing Group Inc**
7901 Stoneridge Drive, Suite 501, Pleasanton, CA 94588, USA
Telephone: +1-925-223-8242
Fax: +1-925-223-8243
E-mail: bpgoffice@wjgnet.com
Help Desk: <http://www.f6publishing.com/helpdesk>
<http://www.wjgnet.com>

