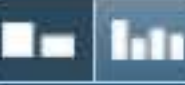



51763-Review.docx

Quotes Included
Bibliography Included0%
SIMILAR

Match Overview



Name of Journal: *World Journal of Clinical Cases*

Manuscript NO.: 51763

Manuscript Type: CASE REPORT

**Multiple neurofibromas plus fibrosarcoma with familial NF1 pathogenicity:
A case report**

Yang W *et al.* Neurofibrosarcoma with familial NF1 pathogenicity

Yang Wang, Xiao-Fan Lu, Lu-Lu Chen, Ying-Wei Zhang, Bing Zhang

There are no matching sources for this report.

Periprosthetic Humeral Fracture Treated with a Locking Plate



ALL IMAGES VIDEOS

关闭取词

739,000 Results

Any time ▾

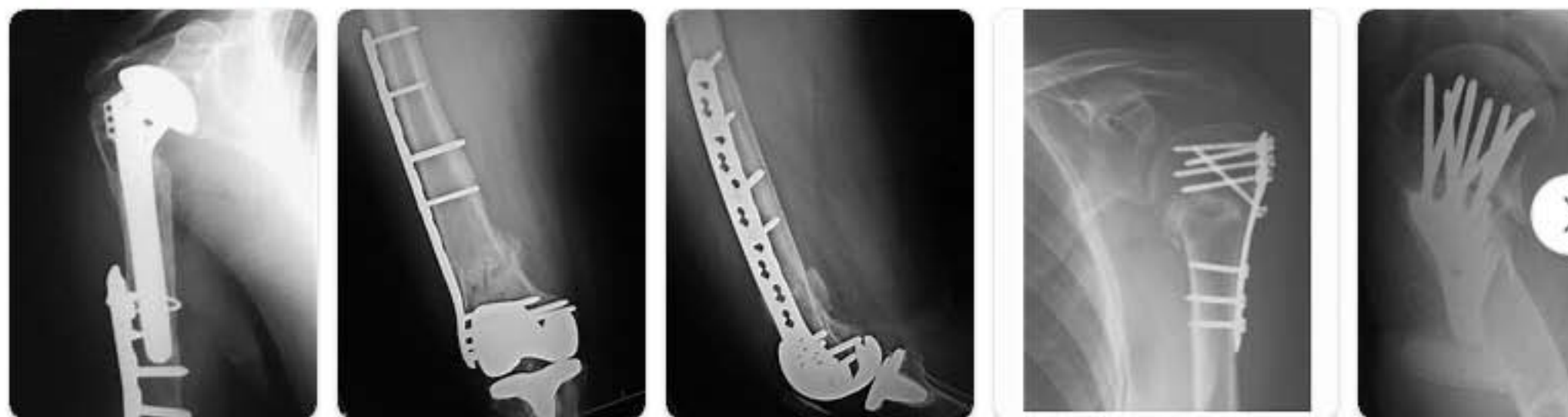
The newly developed Proximal **Humerus Locking Plate** enables the **medical treatment** of **fractures** in the joint area as well as **periprosthetic fractures** with an optional less invasive method. Properties of the implant:

Proximal Humerus Locking Plate - Werkomed
www.werkomed.com/products/proximal-humerus-locking-plate/

Was this helpful? 👍 👎

Images of Periprosthetic humeral fracture treated with a Lock...

bing.com/images



[See more images of Periprosthetic humeral fracture treated with a Locking Plate](#)

Periprosthetic fractures: epidemiology and current treatment

<https://www.ncbi.nlm.nih.gov/pmc/articles/PMC5726208>

Oct 25, 2017 · Regarding **periprosthetic distal femur fractures** with stable implant several options are allowed: Ristevski et al. ... in a systematic review providing a total of 719 **fractures**, showed that **locked**

Related search

what is a periprosthetic

periprosthetic **hum**

periprosthetic **femu**

coding periprosthetic

coding periprosthetic

[国内版](#)[国际版](#)

Multiple neurofibromas plus fibrosarcoma with familial NF1 pa



Sign in



ALL

IMAGES

VIDEOS

关闭取词

Add Bing Firefox extension >

15,300 Results

Any time ▾

Solitary intraosseous neurofibroma: Report of a unique case

<https://www.ncbi.nlm.nih.gov/pmc/articles/PMC4229774>

About 90% of the **neurofibromas** are associated with **neurofibromatosis** type 1, and hence the presence of a solitary **case** requires physical examination and **familial** history to exclude Von Recklinghausens disease. Our patient did not have café au lait spots on the trunk nor any other common clinical features suggestive of Von Recklinghausen's disease.

Connective tissue dysplasia in five new patients with NF1 ...

<https://www.ncbi.nlm.nih.gov/pmc/articles/PMC2603036>

May 31, 2005 · Of these, 89/145 (61%) showed **multiple** subcutaneous **neurofibromas**, while 34/141 (24%) had plexiform **neurofibromas**, which is similar to the 25–30% 27 observed in the general population of patients with **NF1**. Age of development of **neurofibromas** was provided for only a few patients, thus we were unable to assess number of tumours corrected for age.

Cited by: 62

Author: K. A. Mensink, R. P. Ketterling, H. C. Flyn...

Publish Year: 2005

OMIM Entry - # 162200 - NEUROFIBROMATOSIS, TYPE I; NF1

<https://omim.org/entry/162200> ▾