

# World Journal of *Nephrology*

*World J Nephrol* 2023 September 25; 12(4): 73-111



**EVIDENCE REVIEW**

- 73 Moderate stepwise restriction of potassium intake to reduce risk of hyperkalemia in chronic kidney disease: A literature review

*AlSahow A*

**MINIREVIEWS**

- 82 Immunoglobulin A vasculitis nephritis: Current understanding of pathogenesis and treatment

*Amatruda M, Carucci NS, Chimenz R, Conti G*

- 93 Transcending boundaries: Unleashing the potential of multi-organ point-of-care ultrasound in acute kidney injury

*Batool A, Chaudhry S, Koratala A*

**SYSTEMATIC REVIEWS**

- 104 Role of simulation in kidney stone disease: A systematic review of literature trends in the 26 years

*Nedbal C, Jahrreiss V, Cerrato C, Pietropaolo A, Galosi A, Veneziano D, Kallidonis P, Somani BK*

**ABOUT COVER**

Peer Reviewer of *World Journal of Nephrology*, Ahmed Akl, MD, FACP, FASN, ISN Educational Ambassador & Mentor, ISN Education Social Media Member, Mansoura 35516, Egypt. aiakl2001@yahoo.com

**AIMS AND SCOPE**

The primary aim of *World Journal of Nephrology* (WJN, *World J Nephrol*) is to provide scholars and readers from various fields of nephrology with a platform to publish high-quality basic and clinical research articles and communicate their research findings online.

WJN mainly publishes articles reporting research results obtained in the field of nephrology and covering a wide range of topics including acute kidney injury, acute or chronic interstitial nephritis, AIDS-associated nephropathy, anuria, chronic kidney disease and related complications, CKD-MBD, diabetes insipidus, diabetic nephropathies, Fanconi syndrome, glomerular diseases, inborn or acquired errors renal tubular transport, renal hypertension, kidney cortex necrosis, renal artery obstruction, renal nutcracker syndrome, renal tuberculosis, renal tubular acidosis, thrombotic microangiopathy, uremia, and Zellweger syndrome, *etc.*

**INDEXING/ABSTRACTING**

The WJN is now abstracted and indexed in PubMed, PubMed Central, Reference Citation Analysis, China National Knowledge Infrastructure, China Science and Technology Journal Database, and Superstar Journals Database.

**RESPONSIBLE EDITORS FOR THIS ISSUE**

Production Editor: *Si Zhao*; Production Department Director: *Xu Guo*; Editorial Office Director: *Ji-Hong Lin*.

**NAME OF JOURNAL**

*World Journal of Nephrology*

**ISSN**

ISSN 2220-6124 (online)

**LAUNCH DATE**

February 6, 2012

**FREQUENCY**

Bimonthly

**EDITORS-IN-CHIEF**

Li Zuo, Ying-Yong Zhao

**EDITORIAL BOARD MEMBERS**

<https://www.wjnet.com/2220-6124/editorialboard.htm>

**PUBLICATION DATE**

September 25, 2023

**COPYRIGHT**

© 2023 Baishideng Publishing Group Inc

**INSTRUCTIONS TO AUTHORS**

<https://www.wjnet.com/bpg/gerinfo/204>

**GUIDELINES FOR ETHICS DOCUMENTS**

<https://www.wjnet.com/bpg/gerinfo/287>

**GUIDELINES FOR NON-NATIVE SPEAKERS OF ENGLISH**

<https://www.wjnet.com/bpg/gerinfo/240>

**PUBLICATION ETHICS**

<https://www.wjnet.com/bpg/gerinfo/288>

**PUBLICATION MISCONDUCT**

<https://www.wjnet.com/bpg/gerinfo/208>

**ARTICLE PROCESSING CHARGE**

<https://www.wjnet.com/bpg/gerinfo/242>

**STEPS FOR SUBMITTING MANUSCRIPTS**

<https://www.wjnet.com/bpg/gerinfo/239>

**ONLINE SUBMISSION**

<https://www.f6publishing.com>



## Immunoglobulin A vasculitis nephritis: Current understanding of pathogenesis and treatment

Michela Amatruda, Nicolina Stefania Carucci, Roberto Chimenz, Giovanni Conti

**Specialty type:** Urology and nephrology

**Provenance and peer review:** Invited article; Externally peer reviewed.

**Peer-review model:** Single blind

**Peer-review report's scientific quality classification**

Grade A (Excellent): 0  
Grade B (Very good): B, B  
Grade C (Good): C  
Grade D (Fair): 0  
Grade E (Poor): 0

**P-Reviewer:** Koukoulaki M, Greece; Miao MS, China; Wang T, China

**Received:** February 16, 2023

**Peer-review started:** February 16, 2023

**First decision:** April 13, 2023

**Revised:** May 16, 2023

**Accepted:** June 12, 2023

**Article in press:** June 12, 2023

**Published online:** September 25, 2023



**Michela Amatruda, Nicolina Stefania Carucci, Roberto Chimenz, Giovanni Conti**, Pediatric Nephrology and Rheumatology Unit, AOU G Martino, University of Messina, Messina 98125, Italy

**Corresponding author:** Giovanni Conti, MD, Doctor, Pediatric Nephrology and Rheumatology Unit, AOU G Martino, University of Messina, Via C Valeria 1, Messina 98125, Italy.  
[giovanniconti@hotmail.com](mailto:giovanniconti@hotmail.com)

### Abstract

The clinical spectrum of immunoglobulin A vasculitis nephritis (IgAVN) ranges from the relatively common transitory microscopic hematuria and/or low-grade proteinuria to nephritic or nephrotic syndrome, rapidly progressive glomerulonephritis, or even renal failure. Clinical and experimental studies have shown a multifactor pathogenesis: Infection triggers, impaired glycosylation of IgA1, complement activation, Toll-like-receptor activation and B cell proliferation. This knowledge can identify IgAVN patients at a greater risk for adverse outcome and increase the evidence for treatment recommendations.

**Key Words:** Immunoglobulin A vasculitis nephritis; Immunoglobulin A vasculitis; Henoch-Schoenlein purpura; Immunoglobulin A nephropathy; Vasculitis, glomerulonephritis

©The Author(s) 2023. Published by Baishideng Publishing Group Inc. All rights reserved.

**Core Tip:** This review summarizes the main mechanisms involved in the pathogenesis of immunoglobulin A vasculitis nephritis and the recent treatment development, in order to decrease the risk of kidney disease progression.

**Citation:** Amatruda M, Carucci NS, Chimenz R, Conti G. Immunoglobulin A vasculitis nephritis: Current understanding of pathogenesis and treatment. *World J Nephrol* 2023; 12(4): 82-92

**URL:** <https://www.wjnet.com/2220-6124/full/v12/i4/82.htm>

**DOI:** <https://dx.doi.org/10.5527/wjn.v12.i4.82>

## INTRODUCTION

Immunoglobulin A (IgA) vasculitis (IgAV), also known as Henoch-Schoenlein purpura (HSP), is the most common systemic vasculitis in children. It is defined by the presence of non-thrombocytopenic palpable purpura or petechiae (mandatory criterion) predominantly located in the lower limbs, plus abdominal pain or IgA deposition in tissue biopsy or arthritis/arthralgia or renal disease[1,2]. 20%-80% of patients with IgAV develop renal involvement, termed IgAV nephritis (IgAVN), which is the key element in affecting long-term outcome[3-5].

According to the European SHARE (Single Hub and Access point for paediatric Rheumatology in Europe) plane[6], all IgAV patients should be investigated for renal involvement at diagnosis and throughout follow-up by measuring blood pressure, determining the presence of haematuria, quantifying albuminuria and/or proteinuria and, finally, estimating glomerular filtration rate (eGFR)[7]. If initial tests are normal, they need to be monitored for at least 6-12 mo[8-12]. The renal biopsy should be performed in the case of impaired eGFR, persistent proteinuria, nephrotic (*e.g.*, severe proteinuria, low serum albumin levels and oedema) or nephritic (*e.g.*, impaired eGFR, hypertension, haematuria/proteinuria) syndrome.

This review summarizes some important current aspects of IgAVN and most importantly the understanding of its pathogenesis and treatment founded on the results of a multitude of clinical and experimental researches.

## IGA NEPHROPATHY AND IGAVN

IgA nephropathy (IgAN) is the most common primary glomerulonephritis in children and adults. Exclusive renal involvement is characterized by a very slow progression, typical of chronic diseases[9]. In contrast, IgAVN is the most common cause of secondary glomerulonephritis in pediatric age; renal involvement tends to have an acute and self-limiting course similar to that of post-infectious glomerulonephritis, but if persistent it can lead to chronic kidney disease and end-stage renal disease approximately 20 years after diagnosis[10,11].

In a retrospective study based on the epidemiological, clinical and laboratory characteristics of IgAV patients, Carucci *et al*[12] investigated the initial risk factors for IgAVN development, suggesting that age at diagnosis and abdominal pain were associated with a higher risk of onset of the kidney disease in pediatric age. However, additional long-term studies are still needed for the retrospective study type[12].

According to a Japanese study conducted by Komatsu *et al*[13], IgAVN has two peaks in incidence (1-19 years and 60-69 years), while IgAN has an isolated peak in incidence during the 4<sup>th</sup> decade. Compared to IgAN, IgAVN is clinically more severe (especially considering the parameters of proteinuria and hypoalbuminemia), and histologically more aggressive, with a higher percentage of proliferative endocapillary glomerulonephritis and crescentic glomerulonephritis [13].

Despite these differences, several studies have shown that the two diseases share the same pathogenesis, namely a defect in IgA1 glycosylation[14-16]. In addition, glomerular histologic findings can be identical, ranging from focal proliferative lesions with diffuse mesangial IgA deposits to extracapillary proliferative lesions with crescent formation, making it sometimes impossible to distinguish IgAN from IgAVN in the absence of extrarenal signs. For this reason, the two entities have recently been considered to be two different manifestations of the same pathology and in 2012, during the Chapel Hill Consensus Conference on the nomenclature of vasculitis, it was decided to replace the definition "HSP" with that of "IgAV", considering it the systemic form of IgAN[17,18].

In an interesting case series by Kamei *et al*[10], 11% of patients with an initial diagnosis of IgAN subsequently (over a period ranging from 5 mo to 14 years) developed palpable purpura, which allowed the diagnosis to be changed to IgAVN, supporting the hypothesis that IgAN and IgAVN are actually two variants of the same disease. In almost all of these patients, worsening of nephritis was described after the onset of purpura[10]. For this reason, patients diagnosed with IgAN require careful and prolonged follow-up with special attention to the possible appearance of purpura, a sometimes nuanced finding that therefore risks going unnoticed[19].

## PATHOGENESIS

IgAVN shares many pathophysiological features with IgAN (Table 1). The aim of this review is to update the pathogenesis of IgAVN by providing more information regarding impaired glycosylation of IgA1, generation of immune complexes and their kidney deposition, and finally concerning complement activation and stimulation of the mesangial cells, which leads to their expansion and cytokine release[20]. Toll-like-receptor (TLR) activation and B cell proliferation, infection triggers, and genetic factors are also involved in the IgAVN pathogenesis[21].

### Infection triggers

*Helicobacter pylori*[22], *Streptococcus pneumoniae* and *Haemophilus Influenzae*[23,24] are the main pathogens associated with the disease. Infections may be involved in the pathogenesis of IgAVN through two mechanisms. The first is due to the presence of N-acetylgalactosamine (GalNAc) on the superficial side of pathogens stimulating the output of cross-reactive IgA and IgG that identify galactose-deficient IgA1 (Gd-IgA1). Alternatively, microbial agents containing antigens similar to structures on the vessel wall generate a cross-reactive autoantibody response[25].

**Table 1 Mechanism of immunoglobulin A vasculitis nephritis pathogenesis**

No.	Mechanism of IgAVN pathogenesis
1	Infection triggers ( <i>Helicobacter pylori</i> , <i>Streptococcus pneumoniae</i> and <i>Haemophilus Influenzae</i> )[22-25]
2	Genetic factors[26-28]
3	Impaired glycosylation of IgA1 (Gd-IgA1)[29-41]
4	Complement activation[42-45]
5	TLR activation and B cell proliferation[46-48]
6	AECAs[49-51]
7	NAP1r[52,53]
8	Elevated plasma levels of IgE, eosinophil activation, higher levels of ECP and renal $\alpha$ -SMA[54-56]

IgAVN: Immunoglobulin A vasculitis nephritis; Gd-IgA1: Galactose-deficient-immunoglobulin A; TLR: Toll-like-receptor; AECAs: Anti-endothelial cell antibodies; NAP1r: Nephritis-associated plasmin receptor;  $\alpha$ -SMA:  $\alpha$ -smooth muscle; ECP: Eosinophil cationic protein.

### Genetic factors

Little is known yet about the role of genetic factors in the IgAVN pathogenesis, although the presence of ethnic and geographical differences in the incidence of IgAV and IgAVN would indicate its involvement[26,27]. Furthermore, several genes involved in cytokine and chemokine production, complement activation, and regulation of endothelium activity have been implicated in IgAV susceptibility[25,28].

Serum levels of Gd-IgA1 are heritable in both IgAN and IgAVN, indicating that the genetic predisposition to develop IgAVN and IgAN is the same[16].

### Impaired glycosylation of IgA1

IgAVN and IgAN appear to have identical pathophysiology, with only quantitative differences[29]. High levels of IgA and IgA-containing immune complexes have been observed in both cases. However, this serum abnormality is not a sensitive marker for diagnosis[30]. IgA1, not IgA2, is the main component of IgAN and IgAVN. The IgA1 molecule has a hinge region which contains up to six O-linked glycan chains made up of GalNAc, typically with  $\beta$ 1,3-linked galactose (Gal) attached to it[31,32]. Normally, mono- and di-sialylated Gal-GalNAc disaccharides are present in healthy subjects[33,34]. Elevated levels of Gd-IgA1 have been detected in patients with IgAVN and IgAN, compared with the healthy population and patients with other glomerular diseases[35]. Therefore, Gd-IgA1 now plays a pivotal role in both IgAN and IgAVN pathogenesis[36].

It has been reported that these patients have decreased galactosylation of O-glycans, resulting in reduced  $\beta$ 1,3-galactosyltransferase activity in the peripheral B cells of patients. Reduced  $\beta$ 1,3-galactosyltransferase activity leads to a lack of terminal  $\beta$ 1,3-galactosyl residues in the hinge region of IgA1[15,37].

Gd-IgA1 polymer molecules are known to be anti-glycan IgA1 or IgG, resulting in the formation of circulating immune complexes that are deposited in the renal mesangium and subepithelial and subendothelial space, and which incite glomerular injury. In IgAVN, IgA deposit can be found not just in the kidney, but also in other sides like the skin, and larger immune complexes are found compared to IgAN[15]. Deposition of IgA1-containing immune complexes appears to be mediated by a relationship with mesangial transferrin 1 (CD71) and CD89 receptors, also known as Fc $\alpha$ RI, which may occur as a transmembrane receptor in myeloid cells. These receptors on the mesangial surface are more highly expressed than in healthy children.

The monomeric IgA can bind, but without crossbinding with Fc $\alpha$ RI, leading to anti-inflammatory reactions[38]. Monovalent Fc $\alpha$ RI targeting results in the formation of intracellular structures called "inhibisomes", which obstruct the signaling of nearby activated receptors. This process is referred to as ITAM inhibitory signaling (ITAMi) and results in a downregulation of immune activation. In contrast, IgA immune complexes binding to Fc $\alpha$ RI on neutrophils induce activating ITAM signaling, resulting in multiple pro-inflammatory functions. In addition, the activation of Fc $\alpha$ RI induces the LTB<sub>4</sub> chemoattractant release, resulting in neutrophil migration[39,40].

Consequently, after deposition the mesangial cells start to proliferate and produce other components of the extracellular matrix, and also inflammatory and profibrogenic cells such as cytokines and chemokines[35-41].

### Complement activation

The activation of the complement system plays an important role in the pathophysiology of IgAV and IgAVN, including infection triggers and genetics. Indeed, mesangial deposits contain the complement components C3 and C5-C9, which are able to form the attack complex that destroys the membrane of target cells[42]. High levels of C3a, C5a and Bb have also been documented in the serum of pediatric patients with acute IgAV. C5a is a neutrophil chemoattractant that increases during systemic inflammation. C3a and C5a increase interleukin (IL)-8 secretion by endothelial cells, further attracting neutrophils.



More recently, the lectin-related complement activation pathway has also been shown to be involved in IgAVN and IgAN, as IgA can activate mannan-related lectins[43,44]. In contrast, IgA cannot activate the classic pathway and the main activator of the classic pathway, C1q, which is not present in immune complexes[45].

### TLR activation and B cell proliferation

Another mechanism considered to be responsible for IgAV injury is the hyperreactivity of B and T cells in response to specific antigenic triggers. TLR signaling is the first line of defense against microbial infection. Hyperactivated TLR signaling causes cellular inflammatory infiltration that generates cytokines and autoantibodies, leading to autoimmune diseases[46,47].

TLRs are expressed in numerous cells, including kidney cells. There is increasing evidence to support the role for TLRs in autoimmune and inflammatory kidney diseases[22].

Donadio *et al*[48] showed children with IgAV that had significantly increased expression of mRNA encoding for TLR4, compared with healthy controls. TLR2 mRNA expression showed a borderline increase, while no difference was found in the expression of mRNA encoding for TLR3 and TLR9. Regulatory T cells (Treg) expressing the transcriptional factor FoxP3 play a potent anti-inflammatory role. Defective expression of FoxP3 mRNA and reduced expression of transforming growth factor- $\beta$ 1 mRNA were also demonstrated, indicating a defective activity of Treg cells in IgAV[48].

However, it is still unclear if TLR expression is also associated with IgAVN development.

### The role of anti-endothelial cell antibodies in IgAVN

Anti-endothelial cell antibodies (AECAs) are a heterogeneous group of antibodies directed to human endothelial cell antigens. A role of these antibodies in IgAVN has been hypothesized[49]. According to the hypothesis, tumor necrosis factor- $\alpha$  can increase the binding of IgA1 AECAs to endothelial cells. The latter produce IL-8, leading to neutrophil migration[50].

The interaction between IgA1 AECAs and Fc $\alpha$ RI on neutrophils results in the release of LTB<sub>4</sub>, inducing neutrophil recruitment, reactive oxygen species release, neutrophil extracellular traps accompanied by the cell death (NETosis) and antibody-dependent cellular cytotoxicity. All this leads to vascular injury in the final analysis[51].

### Other possible pathogenic mechanisms of IgAVN

Other pathogenetic mechanisms underlying IgAVN need to be further investigated. Masuda *et al*[52] showed that nephritis-associated plasmin receptor, a nephritogenic antigen for acute poststreptococcal glomerulonephritis, might have a pathogenic role in a subgroup of patients with IgAVN[52].

In a study by Davin *et al*[29], elevated plasma levels of IgE were found more commonly in patients with IgAN, but the pathogenetic role of IgE has not yet been clarified. In fact, mast cells are not usually present in the mesangium[24].

Eosinophil activation, higher levels of eosinophil cationic protein (ECP) in serum, and renal  $\alpha$ -smooth muscle ( $\alpha$ -SMA) expression have also been proposed as playing a role in the pathogenesis of IgAVN[25].

Observations indicate that enhanced renal  $\alpha$ -SMA expression could be an early histological marker of IgAN progression. Similarly, increased expression of  $\alpha$ -SMA in the tubule-interstitial region, but not in glomeruli, has been associated with bad prognosis[26].

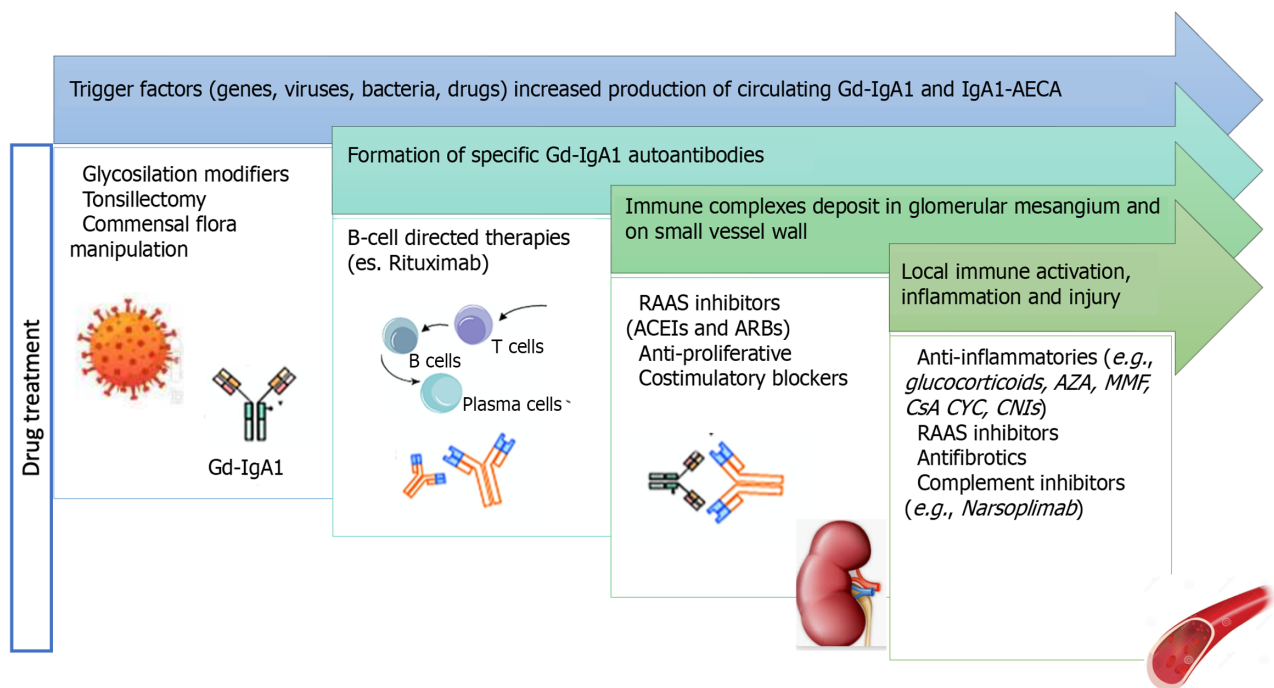
## BIOMARKERS

It is currently not possible to predict and identify which children may develop chronic kidney damage from onset. Some serum and urine markers can identify IgAV patients with or without renal involvement and in predicting the severity of renal inflammation to avoid chronic damage[53,54]. Measuring biomarkers in urine has many advantages: Samples are easy to collect using non-invasive methods; urine reflects damages in renal parenchyma, unlike blood, which comes into contact with many organs and organ systems; the number of different core proteins in the urine is lower than in blood [55]. In a prospective, multicenter study, Pillebout *et al*[54] identified biomarkers that may identify IgAVN at the onset of the disease: Serum Gd-IgA1 level, urine IgA, IgG, IgM, IL-6, IL-8, IL-10, and IgA-IgG and IgA-sCD89 complex levels[54]. A systematic literature review performed by Sugino *et al*[56] identifies that some clinical and urinary biomarkers potentially correlate with the presence and severity of IgAVN in children. The most promising preclinical urinary biomarkers in predicting nephritis are: Kidney injury molecule-1 (KIM-1), monocyte chemotactic protein-1 (MCP-1), N-acetyl- $\beta$ -glucosaminidase (NAG), and angiotensinogen. Urinary KIM-1, MCP-1, and NAG correlate with the disease severity of nephritis (4). However, none of them prove to be established markers of disease. Further studies are needed to verify whether preclinical markers are better than the currently used ones (24-h urinary protein values, urinary protein:creatinine ratio and urinary albumin concentration)[55].

## TREATMENT

Figure 1 illustrates the integration of the pathogenesis diagram with the drug treatment diagram to reveal the supporting mechanism of the drugs.

Decisions regarding the treatment of IgAVN are challenging due to the large percentage of patients with a positive prognosis and the uncertain clinical progression of single patients. Unfortunately, evidence-based treatment is not yet



DOI: 10.5527/wjn.v12.i4.82 Copyright ©The Author(s) 2023.

**Figure 1 Pathogenesis and drug treatment for immunoglobulin A vasculitis and nephritis.** Gd-IgA1: Galactose-deficient-immunoglobulin A; AECA: Anti-endothelial cell antibodies; RAAS: Renin-angiotensin-aldosterone system; ACEI: Angiotensin-converting enzyme inhibitors; ARBs: Angiotensin receptor blockers; AZA: Azathioprine; MMF: Mycophenolate mofetil; CsA: Cyclosporine A; CYC: Cyclophosphamide; CNIs: Calcineurin inhibitors.

available even for the most serious event[1]. In several retrospective studies, delayed therapy has been related to a bad outcome. Therefore, despite the risk of spontaneous remission, it may be recommended that severely affected patients be treated as soon as possible.

Recently, the Kidney Disease Improving Global Outcomes (KDIGO) guidelines have mainly highlighted that the treatment of IgAVN remains a matter of debate and, in the absence of sufficient long-term data, have recommended that it should be treated in the same way as in patients with non-severe forms of isolated IgAN. However, the KDIGO guidelines do not take into account the more acute onset of IgAVN with more aggressive lesions in renal histology[57]. According to KDIGO guidelines, IgAVN patients should first receive a supporting care including routine modification (smoking cessation, weight control, regular exercise and dietary sodium restriction), blood pressure control and a course of renin-angiotensin system (RAS) blockers without immunosuppressive drugs or steroids. In the opinion of experts, this approach can result in the undertreatment of glomerular inflammation, mainly because acute and potentially aggressive glomerular inflammation goes untouched or its immunosuppressed treatment is postponed for several months.

On the contrary, European treatment guidelines consider IgAN and IgAVN as two distinct entities and suggest oral steroids as a first line therapy in IgAVN. In this regard, the German Society of Pediatric Nephrology has recently suggested an early treatment approach for patients with important kidney involvement. Following this treatment suggestion, IgAVN patients with nephritic syndrome, nephrotic syndrome, or glomerular cellular growths will receive an initial standardized corticosteroid- based treatment regimen for 2 mo, followed by an additional immunosuppression in patients with inadequate response after 3-6 mo from the start of treatment[58].

Corticosteroids, intravenous or oral, are part of most treatment regimens, and there is some evidence of their positive result on the long-term outcome of adult IgAN patients. Similarly, other immunosuppressive therapies, such as azathioprine (AZA), mycophenolate mofetil (MMF), cyclosporine A (CsA), or rituximab, have been shown to be effective in individual cases or in small series of patients. Cyclophosphamide (CYC) has also been used for more severe manifestations of IgAN (Table 2)[6]. In conclusion, given the rare nature of severe IgAVN, there is a necessity to standardize the diagnostic and therapeutic approach at least nationally, but ideally multinationally, in order to gain more expertise and move to evidence-based treatment. Future treatment strategies should be evaluated in large multicenter trials. Figure 2 summarizes the treatments available for IgA vasculitis and nephritis.

### Corticosteroids

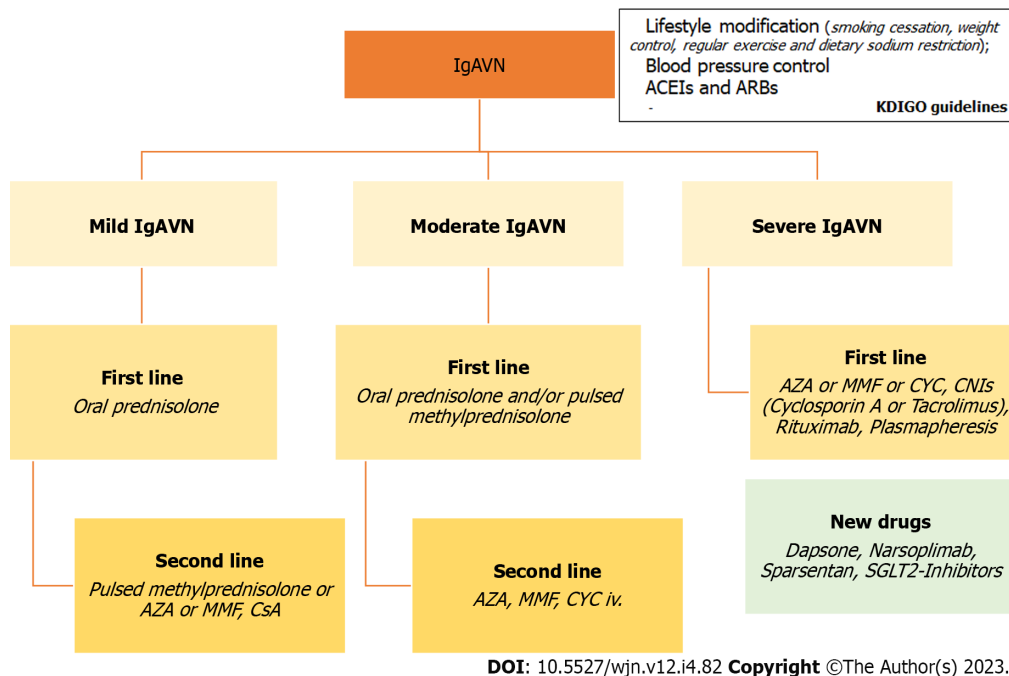
Several studies highlight a potential beneficial impact of corticosteroids in IgAVN. Oral prednisolone and/or pulsed methylprednisolone should be used as the earliest treatment in those cases with mild-moderate IgAVN[6]. A randomized, placebo-controlled trial showed that IgAVN was resolved more quickly in children treated with prednisone than in those treated with placebo. However, the study offered outcome data only 6 mo after randomization. Hence, it is unknown whether prednisone treatment reduced the number of cases with persistent IgAVN or simply encouraged a more rapid resolution of the renal disease compared with the placebo[59]. Kim *et al*[60] showed that corticosteroid exposure significantly reduced serum Gd-IgA1 levels, which are associated with the pathophysiology of IgAVN[60].



**Table 2 Treatments according to European treatment guidelines**

		Class of drugs	Ref.
Mild IgAVN	First line	Corticosteroids: Oral prednisolone	[60-62]
	Second line (or corticosteroid-sparing agent)	Immunosuppressive therapies: Pulsed methylprednisolone or AZA or MMF, CsA	[6,71,72]
Moderate IgAVN	First line	Corticosteroids: Oral prednisolone and/or pulsed methylprednisolone	[6,60-62]
	Second line (Cortico-dependent and cortico-resistant forms of IgAVN)	Immunosuppressive therapies: AZA, MMF, CYC iv	[71,72]
Severe IgAVN	First line	Immunosuppressive therapies + corticosteroids: AZA or MMF or CYC, CNIs ( <i>Cyclosporin A</i> or <i>Tacrolimus</i> ), <i>Rituximab</i> , <i>Plasmapheresis</i>	[64-66,74-77]
New drugs: <i>Dapsone</i> , <i>Narsoplimab</i> , <i>Sparsentan</i>			[81,82]
RAS blockers (ACEIs and ARBs) should be used in IgAVN as soon as possible			[78-80]

ACEI: Angiotensin-converting enzyme inhibitors; ARBs: Angiotensin receptor blockers; IgAVN: Immunoglobulin A vasculitis nephritis; AZA: Azathioprine; MMF: Mycophenolate mofetil; CsA: Cyclosporine A; CYC: Cyclophosphamide; CNIs: Calcineurin inhibitors.



**Figure 2 Therapeutic algorithm for immunoglobulin A vasculitis and nephritis.** ACEI: Angiotensin-converting enzyme inhibitors; ARBs: Angiotensin receptor blockers; IgAVN: Immunoglobulin A vasculitis nephritis; AZA: Azathioprine; MMF: Mycophenolate mofetil; CYC: Cyclophosphamide; CNIs: Calcineurin inhibitors; CsA: Cyclosporine A.

However, no evidence has been found that early treatment with steroids could prevent nephritis in IgAV patients and reduce the risk of proteinuria in the following 12 mo[61].

### Other immunosuppressive therapies

In the cortico-dependent and cortico-resistant forms of IgAVN, other immunosuppressive treatments, such as calcineurin inhibitors (CNIs), AZA, MMF, CYC, rituximab and plasmapheresis can be considered. AZA, MMF or intravenous CYC can be used in the first- or second-line management of moderate-severe IgAVN[6].

CNIs should be considered a hopeful agent for the treatment of severe IgAVN. The two CNIs currently on the market are CsA and tacrolimus. CsA was found to be effective in improving histological lesions and proteinuria in IgAVN patients[62,63]. In a pilot study of 20 IgAVN children, 12 of whom received tacrolimus treatment reached complete remission; eight achieved partial remission at the end of 6 mo[64].

Current data are not in favor of CYC use in IgAVN because no statistically significant differences were found in the group of patients treated with this immunosuppressive drug compared to the group treated with high doses of corticosteroid[65,66]. CsA or oral CYC cannot be routinely recommended in moderate IgAVN. Intravenous CYC with pulsed methylprednisolone and/or oral prednisolone are also required as an earliest treatment in patients with IgAVN[6]. AZA

appeared to be an effective steroid-sparing drug. This has allowed all steroid-dependent patients to go steroid-free. No formal guidelines are available for the duration of treatment. In studies no patient has had any adverse events associated with AZA therapy[67,68].

MMF should be suggested patients with IgAVN, especially if proteinuria still remains after an initial steroid course and despite antiproteinuric treatment[69,70]. A current meta-analysis has, in fact, reported results combining eight studies and proposed that patients with IgAN treated with MMF had higher remission than the control group[71]. In association with steroid therapy, AZA and MMF can be used as a maintenance treatment in those patients with severe IgAVN[6].

Data on the use and efficacy of the anti-CD20 monoclonal antibody rituximab in patients with IgAVN are still limited. A few case reports have recommended that rituximab could be successful in IgAVN in both pediatric and adult ages, especially if other oral immunosuppressive treatments have not been able to induce remission[72,73].

Finally, there is plasmapheresis, which can be used as a rescue therapy in cases of rapid progression to renal failure or persistent nephrotic syndrome. Interestingly, early plasmapheresis has been useful in some patients even without additional immunosuppression[74,75].

### **RAS blockers**

Numerous data suggest that RAS blockers such as angiotensin-converting enzyme inhibitors/angiotensin receptor blockers should be used in IgAVN and as soon as possible. Prospective randomized trials have shown that the use of these drugs improves long-term renal issues in children and adults and prevents/Limits secondary glomerular injury in patients with persistent proteinuria[76-78].

### **New drugs**

Dapsone is a drug that could be considered for the treatment of IgAVN because it can suppress the development of toxic-free radicals by neutrophils. It also reduces the output of IgA antibodies, an essential phenomenon in the pathophysiology of IgAVN[79,80].

A phase II study recently demonstrated the safety, tolerability, and efficacy of narsoplimab, a novel Mannan-binding lectin-associated serine proteinase 2 inhibitor. It is a humanized monoclonal antibody that inhibits the lecithin pathway target of the complement system and seems to result in a clinically significant reduction in proteinuria and the stability of renal function as evaluated by eGFR in high-risk patients with IgAN[81].

A clinical trial is being conducted to evaluate the use of sparsentan as a potential first-line treatment in patients with newly diagnosed IgAN who have not received previous treatment with RAS blockers. Treatment response will be based on endpoints of proteinuria and GFR and will be assessed by changes from the baseline compared to another treatment [76].

Many studies have shown the renoprotective role of sodium-glucose cotransporter 2 (SGLT2) inhibitors in early to advanced diabetic kidney disease. Recent evidence show that SGLT2 inhibitors are similarly renoprotective in non-diabetic chronic kidney disease, such as IgAN, in a wide range of eGFR of 25-75 mL/min/1.73 m<sup>2</sup> and albumin/creatinine ratio of 200-5000 mg/g[82,83].

---

## **INTERVENTIONS FOR PREVENTING IGAVN**

According to a recent Cochran study on the prevention and treatment of IgAVN, studies have shown no benefit of prednisone with respect to placebo or no treatment in preventing persistent kidney disease in children without or with little kidney disease at the time of onset[61].

---

## **CONCLUSION**

According to the European SHARE initiative, only follow-up is required for patients with microscopic haematuria, no renal disorder and proteinuria, or with non-persistent mild or moderate proteinuria. In the case of severe proteinuria or impaired GFR, a paediatric nephrologist must be consulted and a renal biopsy performed. In the case of mild IgAVN, oral prednisolone should be used as a first-line treatment. In some patients with persistent proteinuria, the addition of AZA or MMF, CsA or pulsed methylprednisolone, may be used as a second-line treatment or as a corticosteroid- sparing agent. For patients with moderate IgAVN, oral prednisolone and/or pulsed methylprednisolone should be used as earliest treatment. Addition of AZA, MMF or intravenous CYC may also be used in the first- or second-line treatment of moderate nephritis, according to the histological findings in the kidney biopsy. For severe IgAVN, intravenous CYC with pulsed methylprednisolone and oral prednisolone should be used as a first-line treatment. AZA/MMF plus steroid therapy can be used as a second life[6].

---

## **FOOTNOTES**

**Author contributions:** Amatruda M wrote the article and reviewed the references; Carucci NS wrote the article and revised the references; Chimenz R corrected the article; Conti G thought up the article, supervised the chapters of the article and corrected it.

**Conflict-of-interest statement:** All the authors report no relevant conflicts of interest for this article.

**Open-Access:** This article is an open-access article that was selected by an in-house editor and fully peer-reviewed by external reviewers. It is distributed in accordance with the Creative Commons Attribution NonCommercial (CC BY-NC 4.0) license, which permits others to distribute, remix, adapt, build upon this work non-commercially, and license their derivative works on different terms, provided the original work is properly cited and the use is non-commercial. See: <https://creativecommons.org/licenses/by-nc/4.0/>

**Country/Territory of origin:** Italy

**ORCID number:** Michela Amatruda 0000-0001-9232-777X; Roberto Chimenz 0000-0001-9143-4637; Giovanni Conti 0000-0002-0617-500X.

**S-Editor:** Fan JR

**L-Editor:** A

**P-Editor:** Zhao S

## REFERENCES

- 1 Delbet JD, Parmentier C, Herbez Rea C, Mouche A, Ulinski T. Management of IgA Vasculitis with Nephritis. *Paediatr Drugs* 2021; **23**: 425-435 [PMID: 34396492 DOI: 10.1007/s40272-021-00464-0]
- 2 Hastings MC, Rizk DV, Kiryluk K, Nelson R, Zahr RS, Novak J, Wyatt RJ. IgA vasculitis with nephritis: update of pathogenesis with clinical implications. *Pediatr Nephrol* 2022; **37**: 719-733 [PMID: 33818625 DOI: 10.1007/s00467-021-04950-y]
- 3 Kliegman RM, Stanton B, St. Geme J, Schor NF, Behrman RE. *Pediatrics di Nelson* (19<sup>o</sup> edizione). Elsevier 2013; **910-914**: 1873-1874
- 4 Chen JY, Mao JH. Henoch-Schönlein purpura nephritis in children: incidence, pathogenesis and management. *World J Pediatr* 2015; **11**: 29-34 [PMID: 25557596 DOI: 10.1007/s12519-014-0534-5]
- 5 Pohl M. Henoch-Schönlein purpura nephritis. *Pediatr Nephrol* 2015; **30**: 245-252 [PMID: 24733586 DOI: 10.1007/s00467-014-2815-6]
- 6 Ozen S, Marks SD, Brogan P, Groot N, de Graeff N, Avcin T, Bader-Meunier B, Dolezalova P, Feldman BM, Kone-Paut I, Lahdenne P, McCann L, Pilkington C, Ravelli A, van Royen A, Uziel Y, Vastert B, Wulfraat N, Kamphuis S, Beresford MW. European consensus-based recommendations for diagnosis and treatment of immunoglobulin A vasculitis-the SHARE initiative. *Rheumatology (Oxford)* 2019; **58**: 1607-1616 [PMID: 30879080 DOI: 10.1093/rheumatology/kez041]
- 7 Salvador CL, Tøndel C, Rowe AD, Bjerre A, Brun A, Brackman D, Mørkrid L. Estimating glomerular filtration rate in children: evaluation of creatinine- and cystatin C-based equations. *Pediatr Nephrol* 2019; **34**: 301-311 [PMID: 30171354 DOI: 10.1007/s00467-018-4067-3]
- 8 Goldstein AR, White RH, Akuse R, Chantler C. Long-term follow-up of childhood Henoch-Schönlein nephritis. *Lancet* 1992; **339**: 280-282 [PMID: 1346291 DOI: 10.1016/0140-6736(92)91341-5]
- 9 Rajasekaran A, Julian BA, Rizk DV. IgA Nephropathy: An Interesting Autoimmune Kidney Disease. *Am J Med Sci* 2021; **361**: 176-194 [PMID: 33309134 DOI: 10.1016/j.amjms.2020.10.003]
- 10 Kamei K, Ogura M, Sato M, Ito S, Ishikura K. Evolution of IgA nephropathy into anaphylactoid purpura in six cases--further evidence that IgA nephropathy and Henoch-Schönlein purpura nephritis share common pathogenesis. *Pediatr Nephrol* 2016; **31**: 779-785 [PMID: 26679340 DOI: 10.1007/s00467-015-3290-4]
- 11 Mao S, Xuan X, Sha Y, Zhao S, Zhu C, Zhang A, Huang S. Clinico-pathological association of Henoch-Schoenlein purpura nephritis and IgA nephropathy in children. *Int J Clin Exp Pathol* 2015; **8**: 2334-2342 [PMID: 26045740]
- 12 Carucci NS, La Barbera G, Peruzzi L, La Mazza A, Silipigni L, Alibrandi A, Santoro D, Chimenz R, Conti G. Time of Onset and Risk Factors of Renal Involvement in Children with Henoch-Schönlein Purpura: Retrospective Study. *Children (Basel)* 2022; **9** [PMID: 36138703 DOI: 10.3390/children9091394]
- 13 Komatsu H, Fujimoto S, Yoshikawa N, Kitamura H, Sugiyama H, Yokoyama H. Clinical manifestations of Henoch-Schönlein purpura nephritis and IgA nephropathy: comparative analysis of data from the Japan Renal Biopsy Registry (J-RBR). *Clin Exp Nephrol* 2016; **20**: 552-560 [PMID: 26456327 DOI: 10.1007/s10157-015-1177-0]
- 14 Çakıcı EK, Gür G, Yazılıtaş F, Eroğlu FK, Güngör T, Arda N, Orhan D, Özalp Ateş FS, Bülbül M. A retrospective analysis of children with Henoch-Schönlein purpura and re-evaluation of renal pathologies using Oxford classification. *Clin Exp Nephrol* 2019; **23**: 939-947 [PMID: 30895528 DOI: 10.1007/s10157-019-01726-5]
- 15 Novak J, Moldoveanu Z, Renfrow MB, Yanagihara T, Suzuki H, Raska M, Hall S, Brown R, Huang WQ, Goepfert A, Kilian M, Poulsen K, Tomana M, Wyatt RJ, Julian BA, Mestecky J. IgA nephropathy and Henoch-Schoenlein purpura nephritis: aberrant glycosylation of IgA1, formation of IgA1-containing immune complexes, and activation of mesangial cells. *Contrib Nephrol* 2007; **157**: 134-138 [PMID: 17495451 DOI: 10.1159/000102455]
- 16 Kiryluk K, Moldoveanu Z, Sanders JT, Eison TM, Suzuki H, Julian BA, Novak J, Gharavi AG, Wyatt RJ. Aberrant glycosylation of IgA1 is inherited in both pediatric IgA nephropathy and Henoch-Schönlein purpura nephritis. *Kidney Int* 2011; **80**: 79-87 [PMID: 21326171 DOI: 10.1038/ki.2011.16]
- 17 Jennette JC, Falk RJ, Bacon PA, Basu N, Cid MC, Ferrario F, Flores-Suarez LF, Gross WL, Guillevin L, Hagen EC, Hoffman GS, Jayne DR, Kallenberg CG, Lamprecht P, Langford CA, Luqmani RA, Mahr AD, Matteson EL, Merkel PA, Ozen S, Pusey CD, Rasmussen N, Rees AJ, Scott DG, Specks U, Stone JH, Takahashi K, Watts RA. 2012 revised International Chapel Hill Consensus Conference Nomenclature of Vasculitides. *Arthritis Rheum* 2013; **65**: 1-11 [PMID: 23045170 DOI: 10.1002/art.37715]
- 18 Mittal A, Dijoo M, Sabhikhi A, Gulati S. Henoch Schönlein Purpura Nephritis Developing in a Child with Known IgA Nephropathy. *Indian J Pediatr* 2018; **85**: 808-809 [PMID: 29623535 DOI: 10.1007/s12098-018-2660-x]
- 19 Yamabe H, Kaizuka M, Tsunoda S, Nagasawa T, Nomura K, Shimada M. Henoch-Schönlein Nephritis Manifesting with Purpura 15 years after Diagnosis of IgA Nephropathy. *Case Rep Nephrol* 2019; **2019**: 1042648 [PMID: 31772794 DOI: 10.1155/2019/1042648]
- 20 Suzuki H, Kiryluk K, Novak J, Moldoveanu Z, Herr AB, Renfrow MB, Wyatt RJ, Scolari F, Mestecky J, Gharavi AG, Julian BA. The

- pathophysiology of IgA nephropathy. *J Am Soc Nephrol* 2011; **22**: 1795-1803 [PMID: 21949093 DOI: 10.1681/ASN.2011050464]
- 21 **Lau KK**, Suzuki H, Novak J, Wyatt RJ. Pathogenesis of Henoch-Schönlein purpura nephritis. *Pediatr Nephrol* 2010; **25**: 19-26 [PMID: 19526254 DOI: 10.1007/s00467-009-1230-x]
  - 22 **Xiong LJ**, Tong Y, Wang ZL, Mao M. Is *Helicobacter pylori* infection associated with Henoch-Schönlein purpura in Chinese children? a meta-analysis. *World J Pediatr* 2012; **8**: 301-308 [PMID: 23151856 DOI: 10.1007/s12519-012-0373-1]
  - 23 **Senior BW**, Woof JM. The influences of hinge length and composition on the susceptibility of human IgA to cleavage by diverse bacterial IgA1 proteases. *J Immunol* 2005; **174**: 7792-7799 [PMID: 15944283 DOI: 10.4049/jimmunol.174.12.7792]
  - 24 **Wang L**, Li X, Shen H, Mao N, Wang H, Cui L, Cheng Y, Fan J. Bacterial IgA protease-mediated degradation of agIgA1 and agIgA1 immune complexes as a potential therapy for IgA Nephropathy. *Sci Rep* 2016; **6**: 30964 [PMID: 27485391 DOI: 10.1038/srep30964]
  - 25 **Rigante D**, Castellazzi L, Bosco A, Esposito S. Is there a crossroad between infections, genetics, and Henoch-Schönlein purpura? *Autoimmun Rev* 2013; **12**: 1016-1021 [PMID: 23684700 DOI: 10.1016/j.autrev.2013.04.003]
  - 26 **Galla JH**, Kohaut EC, Alexander R, Mestecky J. Racial difference in the prevalence of IgA-associated nephropathies. *Lancet* 1984; **2**: 522 [PMID: 6147580 DOI: 10.1016/s0140-6736(84)92599-6]
  - 27 **Gardner-Medwin JM**, Dolezalova P, Cummins C, Southwood TR. Incidence of Henoch-Schönlein purpura, Kawasaki disease, and rare vasculitides in children of different ethnic origins. *Lancet* 2002; **360**: 1197-1202 [PMID: 12401245 DOI: 10.1016/S0140-6736(02)11279-7]
  - 28 **Yu HH**, Liu PH, Yang YH, Lee JH, Wang LC, Chen WJ, Chiang BL. Chemokine MCP1/CCL2 and RANTES/CCL5 gene polymorphisms influence Henoch-Schönlein purpura susceptibility and severity. *J Formos Med Assoc* 2015; **114**: 347-352 [PMID: 25839768 DOI: 10.1016/j.jfma.2012.12.007]
  - 29 **Davin JC**, Ten Berge IJ, Weening JJ. What is the difference between IgA nephropathy and Henoch-Schönlein purpura nephritis? *Kidney Int* 2001; **59**: 823-834 [PMID: 11231337 DOI: 10.1046/j.1523-1755.2001.059003823.x]
  - 30 **de Almeida JL**, Campos LM, Paim LB, Leone C, Koch VH, Silva CA. Renal involvement in Henoch-Schönlein purpura: a multivariate analysis of initial prognostic factors. *J Pediatr (Rio J)* 2007; **83**: 259-266 [PMID: 17551657 DOI: 10.2223/JPED.1638]
  - 31 **Renfrow MB**, Mackay CL, Chalmers MJ, Julian BA, Mestecky J, Kilian M, Poulsen K, Emmett MR, Marshall AG, Novak J. Analysis of O-glycan heterogeneity in IgA1 myeloma proteins by Fourier transform ion cyclotron resonance mass spectrometry: implications for IgA nephropathy. *Anal Bioanal Chem* 2007; **389**: 1397-1407 [PMID: 17712550 DOI: 10.1007/s00216-007-1500-z]
  - 32 **Tarelli E**, Smith AC, Hendry BM, Challacombe SJ, Pouria S. Human serum IgA1 is substituted with up to six O-glycans as shown by matrix assisted laser desorption ionisation time-of-flight mass spectrometry. *Carbohydr Res* 2004; **339**: 2329-2335 [PMID: 15337464 DOI: 10.1016/j.carres.2004.07.011]
  - 33 **Field MC**, Dwek RA, Edge CJ, Rademacher TW. O-linked oligosaccharides from human serum immunoglobulin A1. *Biochem Soc Trans* 1989; **17**: 1034-1035 [PMID: 2628063 DOI: 10.1042/bst0171034]
  - 34 **Baenziger J**, Kornfeld S. Structure of the carbohydrate units of IgA1 immunoglobulin. II. Structure of the O-glycosidically linked oligosaccharide units. *J Biol Chem* 1974; **249**: 7270-7281 [PMID: 4373463]
  - 35 **Amore A**, Cirina P, Conti G, Brusa P, Peruzzi L, Coppo R. Glycosylation of circulating IgA in patients with IgA nephropathy modulates proliferation and apoptosis of mesangial cells. *J Am Soc Nephrol* 2001; **12**: 1862-1871 [PMID: 11518779 DOI: 10.1681/ASN.V1291862]
  - 36 **Lau KK**, Wyatt RJ, Moldoveanu Z, Tomana M, Julian BA, Hogg RJ, Lee JY, Huang WQ, Mestecky J, Novak J. Serum levels of galactose-deficient IgA in children with IgA nephropathy and Henoch-Schönlein purpura. *Pediatr Nephrol* 2007; **22**: 2067-2072 [PMID: 17943324 DOI: 10.1007/s00467-007-0623-y]
  - 37 **Allen AC**, Willis FR, Beattie TJ, Feehally J. Abnormal IgA glycosylation in Henoch-Schönlein purpura restricted to patients with clinical nephritis. *Nephrol Dial Transplant* 1998; **13**: 930-934 [PMID: 9568852 DOI: 10.1093/ndt/13.4.930]
  - 38 **Berthelot L**, Papista C, Maciel TT, Biarnes-Pelicot M, Tissandie E, Wang PH, Tamouza H, Jamin A, Bex-Coudrat J, Gestin A, Boumediene A, Arcos-Fajardo M, England P, Pillebout E, Walker F, Daugas E, Vrtosnik F, Flamant M, Benhamou M, Cogné M, Moura IC, Monteiro RC. Transglutaminase is essential for IgA nephropathy development acting through IgA receptors. *J Exp Med* 2012; **209**: 793-806 [PMID: 22451718 DOI: 10.1084/jem.20112005]
  - 39 **Moura IC**, Centelles MN, Arcos-Fajardo M, Malheiros DM, Collawn JF, Cooper MD, Monteiro RC. Identification of the transferrin receptor as a novel immunoglobulin (Ig)A1 receptor and its enhanced expression on mesangial cells in IgA nephropathy. *J Exp Med* 2001; **194**: 417-425 [PMID: 11514599 DOI: 10.1084/jem.194.4.417]
  - 40 **Heineke MH**, Ballering AV, Jamin A, Ben Mkaddem S, Monteiro RC, Van Egmond M. New insights in the pathogenesis of immunoglobulin A vasculitis (Henoch-Schönlein purpura). *Autoimmun Rev* 2017; **16**: 1246-1253 [PMID: 29037908 DOI: 10.1016/j.autrev.2017.10.009]
  - 41 **Moura IC**, Benhamou M, Launay P, Vrtosnik F, Blank U, Monteiro RC. The glomerular response to IgA deposition in IgA nephropathy. *Semin Nephrol* 2008; **28**: 88-95 [PMID: 18222350 DOI: 10.1016/j.semnephrol.2007.10.010]
  - 42 **Yang YH**, Tsai IJ, Chang CJ, Chuang YH, Hsu HY, Chiang BL. The interaction between circulating complement proteins and cutaneous microvascular endothelial cells in the development of childhood Henoch-Schönlein Purpura. *PLoS One* 2015; **10**: e0120411 [PMID: 25760949 DOI: 10.1371/journal.pone.0120411]
  - 43 **Roos A**, Rastaldi MP, Calvaresi N, Oortwijn BD, Schlagwein N, van Gijlswijk-Janssen DJ, Stahl GL, Matsushita M, Fujita T, van Kooten C, Daha MR. Glomerular activation of the lectin pathway of complement in IgA nephropathy is associated with more severe renal disease. *J Am Soc Nephrol* 2006; **17**: 1724-1734 [PMID: 16687629 DOI: 10.1681/ASN.2005090923]
  - 44 **Hisano S**, Matsushita M, Fujita T, Iwasaki H. Activation of the lectin complement pathway in Henoch-Schönlein purpura nephritis. *Am J Kidney Dis* 2005; **45**: 295-302 [PMID: 15685507 DOI: 10.1053/j.ajkd.2004.10.020]
  - 45 **Wyatt RJ**. The complement system in IgA nephropathy and Henoch-Schönlein purpura: functional and genetic aspects. *Contrib Nephrol* 1993; **104**: 82-91 [PMID: 8325036 DOI: 10.1159/000422400]
  - 46 **Gluba A**, Banach M, Hannam S, Mikhailidis DP, Sakowicz A, Rysz J. The role of Toll-like receptors in renal diseases. *Nat Rev Nephrol* 2010; **6**: 224-235 [PMID: 20177402 DOI: 10.1038/nrneph.2010.16]
  - 47 **Amura CR**, Renner B, Lyubchenko T, Faubel S, Simonian PL, Thurman JM. Complement activation and toll-like receptor-2 signaling contribute to cytokine production after renal ischemia/reperfusion. *Mol Immunol* 2012; **52**: 249-257 [PMID: 22750071 DOI: 10.1016/j.molimm.2012.05.020]
  - 48 **Donadio ME**, Loiacono E, Peruzzi L, Amore A, Camilla R, Chiale F, Vergano L, Boido A, Conrieri M, Bianciotto M, Bosetti FM, Coppo R. Toll-like receptors, immunoproteasome and regulatory T cells in children with Henoch-Schönlein purpura and primary IgA nephropathy. *Pediatr Nephrol* 2014; **29**: 1545-1551 [PMID: 24687448 DOI: 10.1007/s00467-014-2807-6]



- 49 **Legendre P**, Régent A, Thiebault M, Mouthon L. Anti-endothelial cell antibodies in vasculitis: A systematic review. *Autoimmun Rev* 2017; **16**: 146-153 [PMID: 27989761 DOI: 10.1016/j.autrev.2016.12.012]
- 50 **Yang YH**, Huang YH, Lin YL, Wang LC, Chuang YH, Yu HH, Lin YT, Chiang BL. Circulating IgA from acute stage of childhood Henoch-Schönlein purpura can enhance endothelial interleukin (IL)-8 production through MEK/ERK signalling pathway. *Clin Exp Immunol* 2006; **144**: 247-253 [PMID: 16634798 DOI: 10.1111/j.1365-2249.2006.03076.x]
- 51 **Otten MA**, Bakema JE, Tuk CW, Glennie MJ, Tutt AL, Beelen RH, van de Winkel JG, van Egmond M. Enhanced FcαRI-mediated neutrophil migration towards tumour colonies in the presence of endothelial cells. *Eur J Immunol* 2012; **42**: 1815-1821 [PMID: 22535639 DOI: 10.1002/eji.201141982]
- 52 **Masuda M**, Nakanishi K, Yoshizawa N, Iijima K, Yoshikawa N. Group A streptococcal antigen in the glomeruli of children with Henoch-Schönlein nephritis. *Am J Kidney Dis* 2003; **41**: 366-370 [PMID: 12552498 DOI: 10.1053/ajkd.2003.50045]
- 53 **Williams CEC**, Toner A, Wright RD, Oni L. A systematic review of urine biomarkers in children with IgA vasculitis nephritis. *Pediatr Nephrol* 2021; **36**: 3033-3044 [PMID: 33993342 DOI: 10.1007/s00467-021-05107-7]
- 54 **Pillebout E**, Jamin A, Ayari H, Housset P, Pierre M, Sauvaget V, Viglietti D, Deschenes G, Monteiro RC, Berthelot L; HSPgnosis group. Biomarkers of IgA vasculitis nephritis in children. *PLoS One* 2017; **12**: e0188718 [PMID: 29190714 DOI: 10.1371/journal.pone.0188718]
- 55 **Jelusic M**, Sestan M, Giani T, Cimaz R. New Insights and Challenges Associated With IgA Vasculitis and IgA Vasculitis With Nephritis-Is It Time to Change the Paradigm of the Most Common Systemic Vasculitis in Childhood? *Front Pediatr* 2022; **10**: 853724 [PMID: 35372148 DOI: 10.3389/fped.2022.853724]
- 56 **Sugino H**, Sawada Y, Nakamura M. IgA Vasculitis: Etiology, Treatment, Biomarkers and Epigenetic Changes. *Int J Mol Sci* 2021; **22** [PMID: 34299162 DOI: 10.3390/ijms22147538]
- 57 **Rovin BH**, Adler SG, Barratt J, Bridoux F, Burdge KA, Chan TM, Cook HT, Fervenza FC, Gibson KL, Glasscock RJ, Jayne DRW, Jha V, Liew A, Liu ZH, Mejia-Vilet JM, Nester CM, Radhakrishnan J, Rave EM, Reich HN, Ronco P, Sanders JF, Sethi S, Suzuki Y, Tang SCW, Tesar V, Vivarelli M, Wetzels JFM, Lytvyn L, Craig JC, Tunncliffe DJ, Howell M, Tonelli MA, Cheung M, Earley A, Floege J. Executive summary of the KDIGO 2021 Guideline for the Management of Glomerular Diseases. *Kidney Int* 2021; **100**: 753-779 [PMID: 34556300 DOI: 10.1016/j.kint.2021.05.015]
- 58 **Butzer S**, Hennies I, Gimpel C, Gellermann J, Schalk G, König S, Büscher AK, Lemke A, Pohl M. Early clinical course of biopsy-proven IgA vasculitis nephritis. *BMC Pediatr* 2022; **22**: 570 [PMID: 36195856 DOI: 10.1186/s12887-022-03611-9]
- 59 **Ronkainen J**, Koskimies O, Ala-Houhala M, Antikainen M, Merenmies J, Rajantie J, Ormälä T, Turtinen J, Nuutinen M. Early prednisone therapy in Henoch-Schönlein purpura: a randomized, double-blind, placebo-controlled trial. *J Pediatr* 2006; **149**: 241-247 [PMID: 16887443 DOI: 10.1016/j.jpeds.2006.03.024]
- 60 **Kim MJ**, Schaub S, Molyneux K, Koller MT, Stampf S, Barratt J. Effect of Immunosuppressive Drugs on the Changes of Serum Galactose-Deficient IgA1 in Patients with IgA Nephropathy. *PLoS One* 2016; **11**: e0166830 [PMID: 27930655 DOI: 10.1371/journal.pone.0166830]
- 61 **Hahn D**, Hodson EM, Willis NS, Craig JC. Interventions for preventing and treating kidney disease in Henoch-Schönlein Purpura (HSP). *Cochrane Database Syst Rev* 2015; **2015**: CD005128 [PMID: 26258874 DOI: 10.1002/14651858.CD005128.pub3]
- 62 **Jauhola O**, Ronkainen J, Autio-Harmainen H, Koskimies O, Ala-Houhala M, Arikoski P, Hölttä T, Jahnukainen T, Rajantie J, Ormälä T, Nuutinen M. Cyclosporine A vs. methylprednisolone for Henoch-Schönlein nephritis: a randomized trial. *Pediatr Nephrol* 2011; **26**: 2159-2166 [PMID: 21626222 DOI: 10.1007/s00467-011-1919-5]
- 63 **Shin JI**, Park JM, Shin YH, Kim JH, Lee JS, Jeong HJ. Henoch-Schönlein purpura nephritis with nephrotic-range proteinuria: histological regression possibly associated with cyclosporin A and steroid treatment. *Scand J Rheumatol* 2005; **34**: 392-395 [PMID: 16234188 DOI: 10.1080/03009740510026544]
- 64 **Zhang DF**, Hao GX, Li CZ, Yang YJ, Liu FJ, Liu L, Yuan XY, Li RH, Dong L, Dong Q, Jacqz-Aigrain E, Zhao W. Off-label use of tacrolimus in children with Henoch-Schönlein purpura nephritis: a pilot study. *Arch Dis Child* 2018; **103**: 772-775 [PMID: 29535109 DOI: 10.1136/archdischild-2017-313788]
- 65 **Pillebout E**, Alberti C, Guillemin L, Ouslimani A, Thervet E; CESAR study group. Addition of cyclophosphamide to steroids provides no benefit compared with steroids alone in treating adult patients with severe Henoch Schönlein Purpura. *Kidney Int* 2010; **78**: 495-502 [PMID: 20505654 DOI: 10.1038/ki.2010.150]
- 66 **Tarshish P**, Bernstein J, Edelmann CM Jr. Henoch-Schönlein purpura nephritis: course of disease and efficacy of cyclophosphamide. *Pediatr Nephrol* 2004; **19**: 51-56 [PMID: 14634864 DOI: 10.1007/s00467-003-1315-x]
- 67 **Singh S**, Devidayal, Kumar L, Joshi K, Minz RW, Datta U. Severe Henoch-Schönlein nephritis: resolution with azathioprine and steroids. *Rheumatol Int* 2002; **22**: 133-137 [PMID: 12172950 DOI: 10.1007/s00296-002-0208-9]
- 68 **Sarcina C**, Tinelli C, Ferrario F, Pani A, De Silvestri A, Scaini P, Del Vecchio L, Alberghini E, Buzzi L, Baragetti I, Pozzi C. Changes in Proteinuria and Side Effects of Corticosteroids Alone or in Combination with Azathioprine at Different Stages of IgA Nephropathy. *Clin J Am Soc Nephrol* 2016; **11**: 973-981 [PMID: 27129712 DOI: 10.2215/CJN.02300215]
- 69 **Ren P**, Han F, Chen L, Xu Y, Wang Y, Chen J. The combination of mycophenolate mofetil with corticosteroids induces remission of Henoch-Schönlein purpura nephritis. *Am J Nephrol* 2012; **36**: 271-277 [PMID: 22965140 DOI: 10.1159/000341914]
- 70 **Han F**, Chen LL, Ren PP, Le JY, Choong PJ, Wang HJ, Xu Y, Chen JH. Mycophenolate mofetil plus prednisone for inducing remission of Henoch-Schönlein purpura nephritis: a retrospective study. *J Zhejiang Univ Sci B* 2015; **16**: 772-779 [PMID: 26365119 DOI: 10.1631/jzus.B1400335]
- 71 **Du B**, Jia Y, Zhou W, Min X, Miao L, Cui W. Efficacy and safety of mycophenolate mofetil in patients with IgA nephropathy: an update meta-analysis. *BMC Nephrol* 2017; **18**: 245 [PMID: 28724421 DOI: 10.1186/s12882-017-0647-x]
- 72 **Fenoglio R**, Naretto C, Basolo B, Quattrocchio G, Ferro M, Mesiano P, Beltrame G, Roccatello D. Rituximab therapy for IgA-vasculitis with nephritis: a case series and review of the literature. *Immunol Res* 2017; **65**: 186-192 [PMID: 27449502 DOI: 10.1007/s12026-016-8827-5]
- 73 **Maritati F**, Fenoglio R, Pillebout E, Emmi G, Urban ML, Rocco R, Nicastro M, Incerti M, Goldoni M, Trivioli G, Silvestri E, Mohammad AJ, Jayne D, Eriksson P, Segelmark M, Novikov P, Harris H, Roccatello D, Vaglio A. Brief Report: Rituximab for the Treatment of Adult-Onset IgA Vasculitis (Henoch-Schönlein). *Arthritis Rheumatol* 2018; **70**: 109-114 [PMID: 28973844 DOI: 10.1002/art.40339]
- 74 **Shenoy M**, Ognjanovic MV, Coulthard MG. Treating severe Henoch-Schönlein and IgA nephritis with plasmapheresis alone. *Pediatr Nephrol* 2007; **22**: 1167-1171 [PMID: 17530298 DOI: 10.1007/s00467-007-0498-y]
- 75 **Augusto JF**, Sayegh J, Delapierre L, Croue A, Tollis F, Cousin M, Subra JF. Addition of plasma exchange to glucocorticosteroids for the treatment of severe Henoch-Schönlein purpura in adults: a case series. *Am J Kidney Dis* 2012; **59**: 663-669 [PMID: 22300649 DOI: 10.1053/j.ajkd.2011.12.015]

- 76 **Ninchoji T**, Kaito H, Nozu K, Hashimura Y, Kanda K, Kamioka I, Shima Y, Hamahira K, Nakanishi K, Tanaka R, Yoshikawa N, Iijima K, Matsuo M. Treatment strategies for Henoch-Schönlein purpura nephritis by histological and clinical severity. *Pediatr Nephrol* 2011; **26**: 563-569 [PMID: [21203777](#) DOI: [10.1007/s00467-010-1741-5](#)]
- 77 **Praga M**, Gutiérrez E, González E, Morales E, Hernández E. Treatment of IgA nephropathy with ACE inhibitors: a randomized and controlled trial. *J Am Soc Nephrol* 2003; **14**: 1578-1583 [PMID: [12761258](#) DOI: [10.1097/01.asn.0000068460.37369.dc](#)]
- 78 **Coppo R**, Peruzzi L, Amore A, Piccoli A, Cochat P, Stone R, Kirschstein M, Linné T. IgACE: a placebo-controlled, randomized trial of angiotensin-converting enzyme inhibitors in children and young people with IgA nephropathy and moderate proteinuria. *J Am Soc Nephrol* 2007; **18**: 1880-1888 [PMID: [17513327](#) DOI: [10.1681/ASN.2006040347](#)]
- 79 **Lee KH**, Hong SH, Jun J, Jo Y, Jo W, Choi D, Joo J, Jung G, Ahn S, Kronbichler A, Eisenhut M, Shin JI. Treatment of refractory IgA vasculitis with dapsone: a systematic review. *Clin Exp Pediatr* 2020; **63**: 158-163 [PMID: [32024340](#) DOI: [10.3345/kjp.2019.00514](#)]
- 80 **Iqbal H**, Evans A. Dapsone therapy for Henoch-Schönlein purpura: a case series. *Arch Dis Child* 2005; **90**: 985-986 [PMID: [16113142](#) DOI: [10.1136/adc.2004.061598](#)]
- 81 **Lafayette RA**, Rovin BH, Reich HN, Tumlin JA, Floege J, Barratt J. Safety, Tolerability and Efficacy of Narsoplimab, a Novel MASP-2 Inhibitor for the Treatment of IgA Nephropathy. *Kidney Int Rep* 2020; **5**: 2032-2041 [PMID: [33163724](#) DOI: [10.1016/j.ekir.2020.08.003](#)]
- 82 **Tesař V**. SGLT2 inhibitors in non-diabetic kidney disease. *Adv Clin Exp Med* 2022; **31**: 105-107 [PMID: [35077036](#) DOI: [10.17219/acem/145734](#)]
- 83 **Wheeler DC**, Toto RD, Stefánsson BV, Jongs N, Chertow GM, Greene T, Hou FF, McMurray JJV, Pecoits-Filho R, Correa-Rotter R, Rossing P, Sjöström CD, Umanath K, Langkilde AM, Heerspink HJL; DAPA-CKD Trial Committees and Investigators. A pre-specified analysis of the DAPA-CKD trial demonstrates the effects of dapagliflozin on major adverse kidney events in patients with IgA nephropathy. *Kidney Int* 2021; **100**: 215-224 [PMID: [33878338](#) DOI: [10.1016/j.kint.2021.03.033](#)]





Published by **Baishideng Publishing Group Inc**  
7041 Koll Center Parkway, Suite 160, Pleasanton, CA 94566, USA

**Telephone:** +1-925-3991568

**E-mail:** [bpgoffice@wjgnet.com](mailto:bpgoffice@wjgnet.com)

**Help Desk:** <https://www.f6publishing.com/helpdesk>

<https://www.wjgnet.com>

