

# World Journal of *Clinical Cases*

*World J Clin Cases* 2023 August 6; 11(22): 5193-5415



**MINIREVIEWS**

- 5193 Research progress on reactive oxygen species production mechanisms in tumor sonodynamic therapy  
*Dong HQ, Fu XF, Wang MY, Zhu J*

**ORIGINAL ARTICLE****Retrospective Study**

- 5204 Combining the age-male-albumin-bilirubin-platelets score and shear wave elastography stratifies carcinogenic risk in hepatitis C patients after viral clearance  
*Masaoka R, Gytoku Y, Shirahashi R, Suda T, Tamano M*
- 5215 Changes in neurotransmitter levels, brain structural characteristics, and their correlation with PANSS scores in patients with first-episode schizophrenia  
*Xu XJ, Liu TL, He L, Pu B*
- 5224 Five-year outcomes of immediate implant placement for mandibular molars with and without chronic apical periodontitis: A retrospective study  
*Yang H, Luo D, Yuan MJ, Yang JJ, Wang DS*

**Observational Study**

- 5236 Standardization of apple cancellation test for neglect patients in Korea: An observational study  
*Jang WH, Jang JS*

**Prospective Study**

- 5244 Diabetic neuropathy results in vasomotor dysfunction of medium sized peripheral arteries  
*Ege F, Kazci Ö, Aydin S*

**SYSTEMATIC REVIEWS**

- 5252 COVID-19-induced gastrointestinal autonomic dysfunction: A systematic review  
*Elbeltagi R, Al-Beltagi M, Saeed NK, Bediwy AS*

**META-ANALYSIS**

- 5273 Meta-analysis of outcomes from drug-eluting stent implantation in infrapopliteal arteries  
*Li MX, Tu HX, Yin MC*

**CASE REPORT**

- 5288 Acute hepatitis of unknown etiology in an adult female: A case report  
*Dass L, Pacia AMM, Hamidi M*

- 5296** Zimberelimab plus chemotherapy as the first-line treatment of malignant peritoneal mesothelioma: A case report and review of literature  
*Peng XD, You ZY, He LX, Deng Q*
- 5303** Recurrent ventricular arrhythmia due to aconite intoxication successfully treated with landiolol: A case report  
*Matsuo C, Yamamoto K, Fukushima H, Yajima D, Inoue H*
- 5309** Anti-phospholipase A2 receptor-associated membranous nephropathy with human immunodeficiency virus infection treated with telitacicept: A case report  
*Wang JL, Sun YL, Kang Z, Zhang SK, Yu CX, Zhang W, Xie H, Lin HL*
- 5316** Rapid progression of heart failure secondary to radioactive iodine treatment of hyperthyroidism: A case report  
*Li ZH, Ni LJ, Liu YQ, Si DY*
- 5322** Pathological complete response to neoadjuvant alectinib in unresectable anaplastic lymphoma kinase positive non-small cell lung cancer: A case report  
*Wang LM, Zhao P, Sun XQ, Yan F, Guo Q*
- 5329** Hepatoid adenocarcinoma of the stomach with neuroendocrine differentiation: A case report and review of literature  
*Fei H, Li ZF, Chen YT, Zhao DB*
- 5338** Acquired haemophilia as a complicating factor in treatment of non-muscle invasive bladder cancer: A case report  
*Ryšánková K, Gumulec J, Grepl M, Krhut J*
- 5344** Persistent dysexecutive syndrome after pneumococcal meningitis complicated by recurrent ischemic strokes: A case report  
*Abbruzzese L, Martinelli G, Salti G, Basagni B, Damora A, Scarselli C, Peppoloni G, Podgorska A, Rosso G, Bacci M, Alfano AR, MANCUSO M*
- 5351** Treatment of refractory anti-melanoma differentiation-associated gene 5 antibody-positive dermatomyositis complicated by rapidly progressing interstitial pulmonary disease: Two case reports  
*Wang QH, Chen LH*
- 5358** TINAVI robot-assisted one-stage anteroposterior surgery in lateral position for severe thoracolumbar fracture dislocation: A case report  
*Ye S, Chen YZ, Zhong LJ, Yu CZ, Zhang HK, Hong Y*
- 5365** Individual with concurrent chest wall tuberculosis and triple-negative essential thrombocythemia: A case report  
*Xu XY, Yang YB, Yuan J, Zhang XX, Kang L, Ma XS, Yang J*
- 5373** Self-strangulation induced penile partial amputation: A case report  
*Maimaitiming ABLT, Mulati YLSD, Apizi ART, Li XD*
- 5382** Long-term rare giant sialolithiasis for 30 years: A case report and review of literature  
*Mao JS, Lee YC, Chi JCY, Yi WL, Tsou YA, Lin CD, Tai CJ, Shih LC*

- 5391** Kawasaki disease with peritonsillar abscess as the first symptom: A case report  
*Huo LM, Li LM, Peng HY, Wang LJ, Feng ZY*
- 5398** Treatment of a patient with severe lactic acidosis and multiple organ failure due to mitochondrial myopathy: A case report  
*Chen L, Shuai TK, Gao YW, Li M, Fang PZ, Christian W, Liu LP*
- 5407** Early esophageal carcinomas in achalasia patient after endoscopic submucosal dissection combined with peroral endoscopic myotomy: A case report  
*An BQ, Wang CX, Zhang HY, Fu JD*

**LETTER TO THE EDITOR**

- 5412** Caution in the use of sedation and endomyocardial biopsy for the management of pediatric acute heart failure caused by endocardial fibroelastosis  
*Xin XX, Se YY*

**ABOUT COVER**

Editorial Board Member of *World Journal of Clinical Cases*, Etienne Andrade Munhoz, PhD, Associate Professor, Department of Dentistry, Health Science Centre, Federal University of Santa Catarina, Florianopolis 88040-379, Brazil. etiamfob@yahoo.com

**AIMS AND SCOPE**

The primary aim of *World Journal of Clinical Cases* (WJCC, *World J Clin Cases*) is to provide scholars and readers from various fields of clinical medicine with a platform to publish high-quality clinical research articles and communicate their research findings online.

WJCC mainly publishes articles reporting research results and findings obtained in the field of clinical medicine and covering a wide range of topics, including case control studies, retrospective cohort studies, retrospective studies, clinical trials studies, observational studies, prospective studies, randomized controlled trials, randomized clinical trials, systematic reviews, meta-analysis, and case reports.

**INDEXING/ABSTRACTING**

The WJCC is now abstracted and indexed in Science Citation Index Expanded (SCIE, also known as SciSearch®), Journal Citation Reports/Science Edition, Current Contents®/Clinical Medicine, PubMed, PubMed Central, Reference Citation Analysis, China National Knowledge Infrastructure, China Science and Technology Journal Database, and Superstar Journals Database. The 2023 Edition of Journal Citation Reports® cites the 2022 impact factor (IF) for WJCC as 1.1; IF without journal self cites: 1.1; 5-year IF: 1.3; Journal Citation Indicator: 0.26; Ranking: 133 among 167 journals in medicine, general and internal; and Quartile category: Q4.

**RESPONSIBLE EDITORS FOR THIS ISSUE**

Production Editor: Si Zhao; Production Department Director: Xu Guo; Editorial Office Director: Jin-Lei Wang.

**NAME OF JOURNAL**

*World Journal of Clinical Cases*

**ISSN**

ISSN 2307-8960 (online)

**LAUNCH DATE**

April 16, 2013

**FREQUENCY**

Thrice Monthly

**EDITORS-IN-CHIEF**

Bao-Gan Peng, Jerzy Tadeusz Chudek, George Kontogeorgos, Maurizio Serati, Ja Hyeon Ku

**EDITORIAL BOARD MEMBERS**

<https://www.wjgnet.com/2307-8960/editorialboard.htm>

**PUBLICATION DATE**

August 6, 2023

**COPYRIGHT**

© 2023 Baishideng Publishing Group Inc

**INSTRUCTIONS TO AUTHORS**

<https://www.wjgnet.com/bpg/gerinfo/204>

**GUIDELINES FOR ETHICS DOCUMENTS**

<https://www.wjgnet.com/bpg/GerInfo/287>

**GUIDELINES FOR NON-NATIVE SPEAKERS OF ENGLISH**

<https://www.wjgnet.com/bpg/gerinfo/240>

**PUBLICATION ETHICS**

<https://www.wjgnet.com/bpg/GerInfo/288>

**PUBLICATION MISCONDUCT**

<https://www.wjgnet.com/bpg/gerinfo/208>

**ARTICLE PROCESSING CHARGE**

<https://www.wjgnet.com/bpg/gerinfo/242>

**STEPS FOR SUBMITTING MANUSCRIPTS**

<https://www.wjgnet.com/bpg/GerInfo/239>

**ONLINE SUBMISSION**

<https://www.f6publishing.com>



## TINAVI robot-assisted one-stage anteroposterior surgery in lateral position for severe thoracolumbar fracture dislocation: A case report

Sen Ye, Yan-Zhen Chen, Ling-Jian Zhong, Chang-Zhang Yu, Han-Kun Zhang, Yang Hong

**Specialty type:** Orthopedics

**Provenance and peer review:**

Unsolicited article; Externally peer reviewed.

**Peer-review model:** Single blind

**Peer-review report's scientific quality classification**

Grade A (Excellent): 0

Grade B (Very good): B

Grade C (Good): C, C

Grade D (Fair): 0

Grade E (Poor): 0

**P-Reviewer:** Hoveidaei AH, Iran;  
Kuroki H, Japan

**Received:** April 14, 2023

**Peer-review started:** April 14, 2023

**First decision:** June 21, 2023

**Revised:** June 22, 2023

**Accepted:** July 10, 2023

**Article in press:** July 10, 2023

**Published online:** August 6, 2023



**Sen Ye, Yan-Zhen Chen, Ling-Jian Zhong, Chang-Zhang Yu, Han-Kun Zhang, Yang Hong,** Department of Spine Surgery, Xingguo Hospital Affiliated to Gannan Medical College, Ganzhou 342400, Jiangxi Province, China

**Corresponding author:** Yan-Zhen Chen, MD, Professor, Department of Spine Surgery, Xingguo Hospital Affiliated to Gannan Medical College, No. 699 Wenming Avenue, Xingguo County, Ganzhou 342400, Jiangxi Province, China. [13507071872@163.com](mailto:13507071872@163.com)

### Abstract

#### BACKGROUND

The combined anterior/posterior approach appears to be capable of reconstructing spinal stability, correcting thoracolumbar deformity, and promoting neural recovery in severe thoracolumbar fracture dislocation. However, this type of operation requires changing the body position during the procedure, resulting in a lengthy operation time. As a universal surgical robot, TINAVI robot has achieved good surgical results in clinical surgery. But to our knowledge, no reports describing TINAVI robot-assisted single lateral position anteroposterior surgery for thoracolumbar fracture dislocation.

#### CASE SUMMARY

We describe a case of a 16-year-old female patient with severe thoracolumbar fracture and dislocation underwent surgery assisted by the TINAVI robot. A one-stage combined anterior and posterior operation was performed on a severe thoracolumbar fracture dislocation using the TINAVI robot, and the operation was completed in right lateral position.

#### CONCLUSION

The TINAVI robot-assisted one-stage anterior and posterior surgery in right lateral position for severe thoracolumbar fracture and dislocation is both safe and effective.

**Key Words:** TINAVI; Thoracolumbar fracture; Spine surgery; Case report

©The Author(s) 2023. Published by Baishideng Publishing Group Inc. All rights reserved.

**Core Tip:** Currently, there is no reports describing TINAVI robot-assisted single lateral position anteroposterior surgery for thoracolumbar fracture dislocation. We describe a case of a 16-year-old female patient with severe thoracolumbar fracture and dislocation underwent surgery assisted by the TINAVI robot. A one-stage combined anterior and posterior operation was performed on a severe thoracolumbar fracture dislocation using the TINAVI robot, and the operation was completed in right lateral position. We hope to bring more options to the approach of spinal surgery by sharing the case.

**Citation:** Ye S, Chen YZ, Zhong LJ, Yu CZ, Zhang HK, Hong Y. TINAVI robot-assisted one-stage anteroposterior surgery in lateral position for severe thoracolumbar fracture dislocation: A case report. *World J Clin Cases* 2023; 11(22): 5358-5364

**URL:** <https://www.wjgnet.com/2307-8960/full/v11/i22/5358.htm>

**DOI:** <https://dx.doi.org/10.12998/wjcc.v11.i22.5358>

## INTRODUCTION

Thoracolumbar fracture-dislocation is a high-energy spinal injury caused by compression or flexion/traction force[1]. Simple anterior or posterior surgery cannot completely decompress and reconstruct the stability of the three columns of the spine in severe thoracolumbar fracture and dislocation[2]. The combination of anterior and posterior surgery is an effective method for treating severe thoracolumbar fracture and dislocation. The combined anterior and posterior approach of thoracolumbar fracture and dislocation, on the other hand, frequently requires changing the position during the operation, resulting in a longer operation time. If the anterior and posterior operations are only performed in a lateral position, pedicle screw placement becomes more difficult, and frequent fluoroscopy is required to confirm screw accuracy, resulting in a longer operation time[3,4]. In addition, inaccurate placement of pedicle screws may lead to several complications, such as peripheral neurovascular injury, cerebrospinal fluid leakage, thoracic and abdominal organ injury, and so on[5,6]. To improve the accuracy of screw placement location in thoracolumbar pedicle screw fixation surgery, several robotic systems have been used in clinical surgery[7].

As a universal surgical robot, TINAVI robot has achieved good surgical results in clinical surgery[8-13]. TINAVI robot-assisted one-stage anterior posterior surgery for severe thoracolumbar fracture dislocation may be safe and effective[10]. It can accurately insert pedicle screws, reducing operation time and tissue damage. This was, to the best of our knowledge, the first case of TINAVI robot-assisted single lateral position anteroposterior surgery for thoracolumbar fracture-dislocation. The patients and their families were informed that the case data would be submitted for publication and consented.

## CASE PRESENTATION

### Chief complaints

A 16-year-old girl suffered back pain from falling from a height 6 d ago.

### History of present illness

The patient had no prior history with regard to the lesion.

### History of past illness

The patient had no specific history of past illness.

### Personal and family history

The patient had no known personal or family medical history.

### Physical examination

Localized back tenderness, kyphosis and restricted mobility. ASIA B of spinal cord injury. There was an open fracture of left ankle joint. The patient was bedridden and the rest of the examination could not be coordinated.

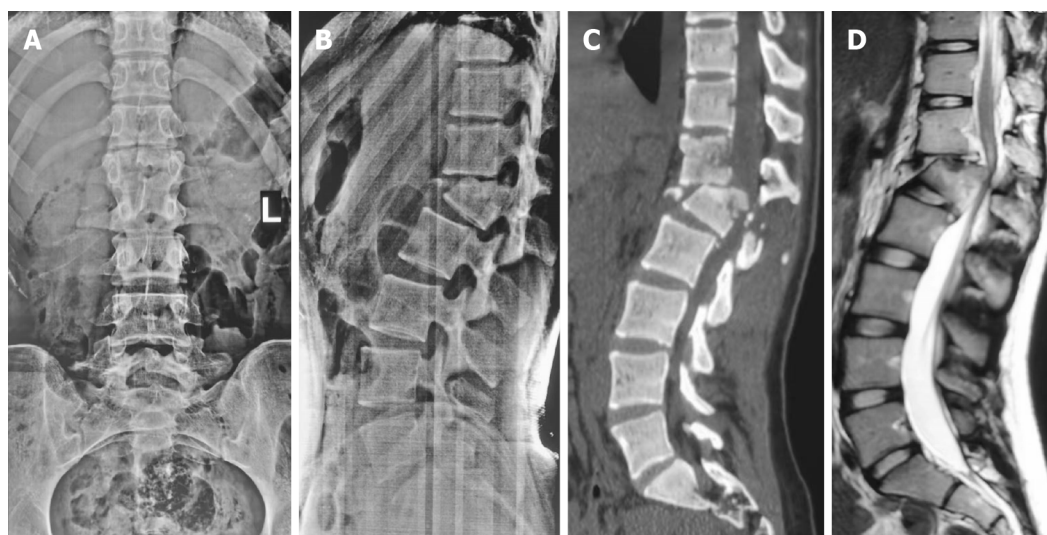### Laboratory examinations

All ordered laboratory tests (complete blood count, basic metabolic panel, lipid panel, liver panel, coagulation tests, urinalysis, and stool analysis) were normal.

### Imaging examinations

Anteroposterior, lateral, and computed tomography (CT) views revealed a classic kyphosis with a fracture dislocation of L1 (AO Type C, Load-sharing classification = 8). The kyphotic deformity's corresponding Cobb angle was approximately 26°. The spinal cord injury was discovered using magnetic resonance imaging (Figure 1). Besides, there were open fracture of left ankle joint, and fracture of right ankle joint.





DOI: 10.12998/wjcc.v11.i22.5358 Copyright ©The Author(s) 2023.

**Figure 1** A 16-year-old female with thoracolumbar fracture dislocation of L1 (AO Type C, Load-sharing classification, leukemic stem cell = 8), ASIA B of spinal cord injury. A and B: The pre-operative anteroposterior and lateral radiographs showed thoracolumbar kyphosis with a 26° Cobb's angle; C: Pre-operative computed tomography scan reconstructions showed L1 fracture dislocation; D: Pre-operative sagittal T2-weighted magnetic resonance image revealed the spinal cord injury.

## FINAL DIAGNOSIS

The patient was diagnosed with L1 fracture combined with spinal cord injury, accompanied by bilateral ankle fractures.

## TREATMENT

In the first step, we would treat thoracolumbar fracture dislocation with TINAVI robot-assisted lateral position combined with anteroposterior surgery, and in the second step, we would complete the operation on bilateral ankle fracture (Figure 2).

The surgical technique for the treatment of thoracolumbar fracture dislocation was described as follows:

### Patient positioning

General anesthesia was administered. The patient was positioned in the right lateral position on a carbon fiber surgical bed with hip and knee flexion. The posterior axillary line was marked as a reference point for subsequent steps.

### C-arm fluoroscopy

A C-arm fluoroscopy machine was used to assist in precise positioning during the procedure. The fluoroscopy line was set perpendicular to the posterior axillary line and passed through the injured vertebra. The intersection point of the was marked, creating an anterior incision marker line approximately 8 cm.

### Tracker placement and 3D scanning

A tracker was attached to the left iliac crest to enable accurate tracking of the patient's movements during the procedure. A 3D C-arm scan was performed to obtain a detailed image of the target vertebra. The 3D image was transferred to the robot workstation for automatic registration and further planning.

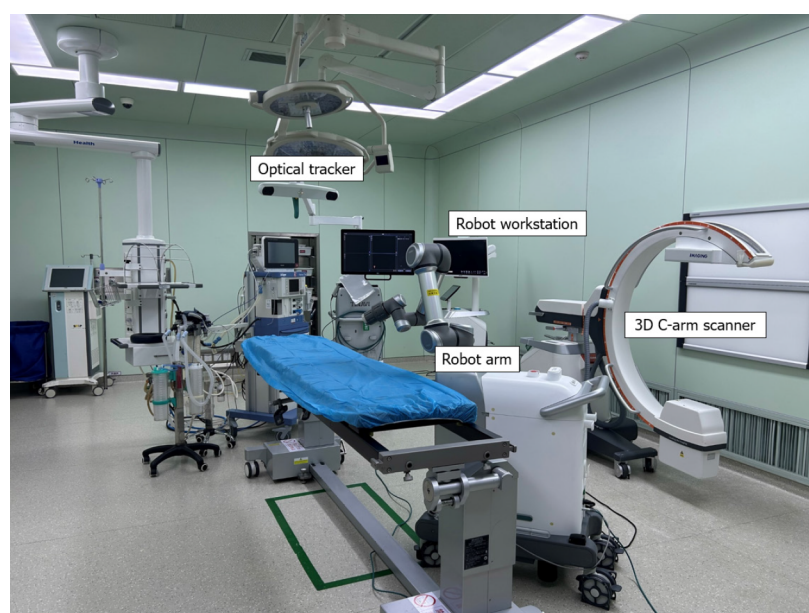
### Planning and adjustment

Using the 3D image, the surgeon planned the placement of percutaneous pedicle screws in the T12 and L2 vertebrae. The plan included determining the screw entry point, direction, and specification. The position of the robot arm was adjusted according to the planned trajectory.

### Guiding cannula and implantation

After the robot arm was correctly positioned, a guide cannula was inserted along the robot arm guide. The surgeon marked the position for implantation on the skin and made a longitudinal incision. The guiding cannula was used to fully expand the soft tissue, ensuring contact with the bony surface. The guiding pin of an electric drill was implanted along the direction of the guiding cannula to create a pathway for the pedicle screws. The guiding cannula was then removed, and the same procedure was repeated to implant the remaining guiding pins. C-arm fluoroscopy was used to verify the proper position of the guide pins.





DOI: 10.12998/wjcc.v11.i22.5358 Copyright ©The Author(s) 2023.

**Figure 2** TINAVI orthopedic robotic system. 3D: Three dimensional.

### **Accessing the injured vertebra**

The surgeon reached the injured vertebra directly by separating the physiologic space between the abdominal vascular sheath and the anterior border of the psoas major muscle. This approach allowed direct access to the surgical site while minimizing disruption to surrounding structures.

### **Spinal canal decompression and artificial vertebral body implantation**

The operation was completed within the dilated channel using the oblique lateral interbody fusion channel and light source system. The transverse artery in the vertebral body was cauterized using a bipolar device. The periosteum was peeled off to fully expose the pedicle and intervertebral foramen. Special care was taken to protect the spinal nerve passing through the foramen. A corpectomy was performed on the L1 vertebra and adjacent intervertebral disc to achieve punctate bleeding and decompress the spinal cord. The bone mass in the spinal canal was carefully scraped off, relieving dural compression. The upper and lower vertebral bodies were stretched to achieve reduction. An artificial vertebral body was created using autogenous bone, and an vertebral screw rod system was installed. A drainage tube was routinely implanted to assist with fluid drainage during the initial postoperative period. To ensure stability and consolidation, image-guided transpedicular screws were inserted in the T12 and L2 vertebrae. The operation lasted 270 min and resulted in a blood loss of 400 mL. We used antibiotics for 24 h to prevent infection and removed the drainage tube when the drainage volume was less than 50 mL. During the operation, there were no complications (Figure 3).

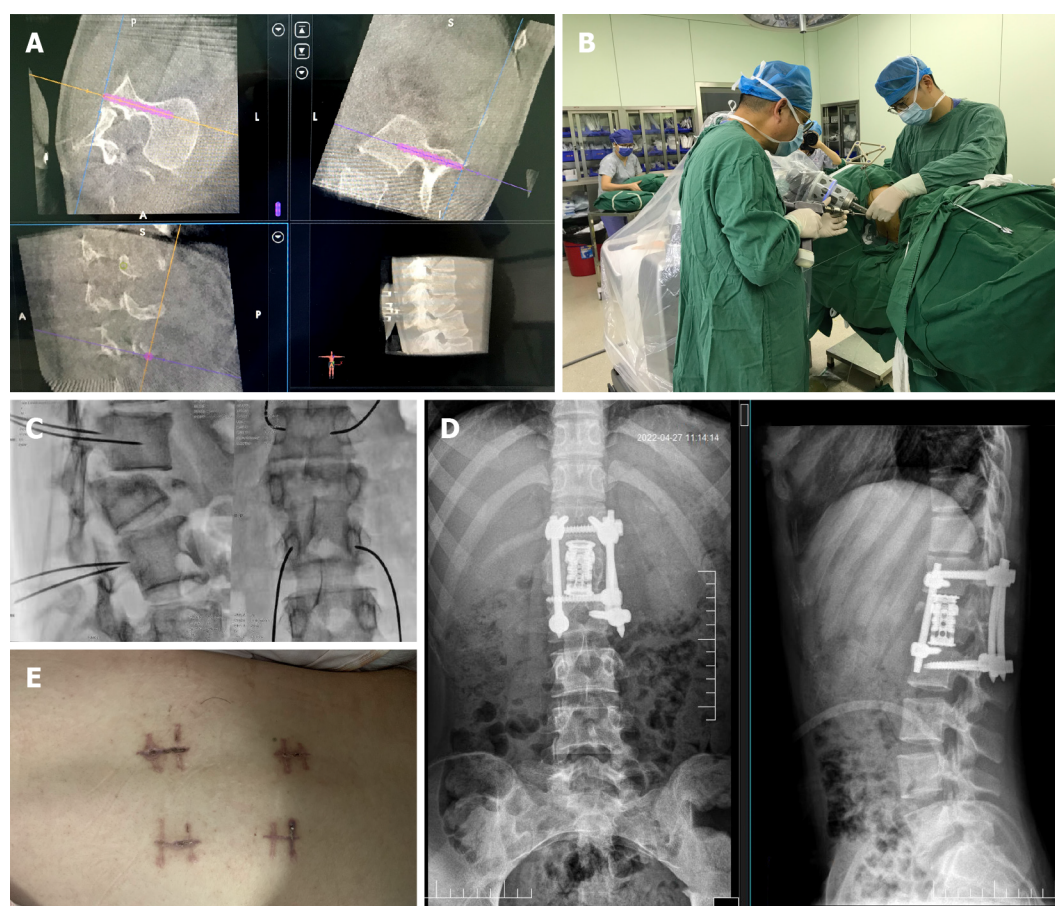
## **OUTCOME AND FOLLOW-UP**

After 5 mo of observation, the Cobb angle was 5.6°. There was no obvious loss of Cobb angle, no signs of nonunion, and neural function improved from ASIA B to ASIA D (Figure 4).

## **DISCUSSION**

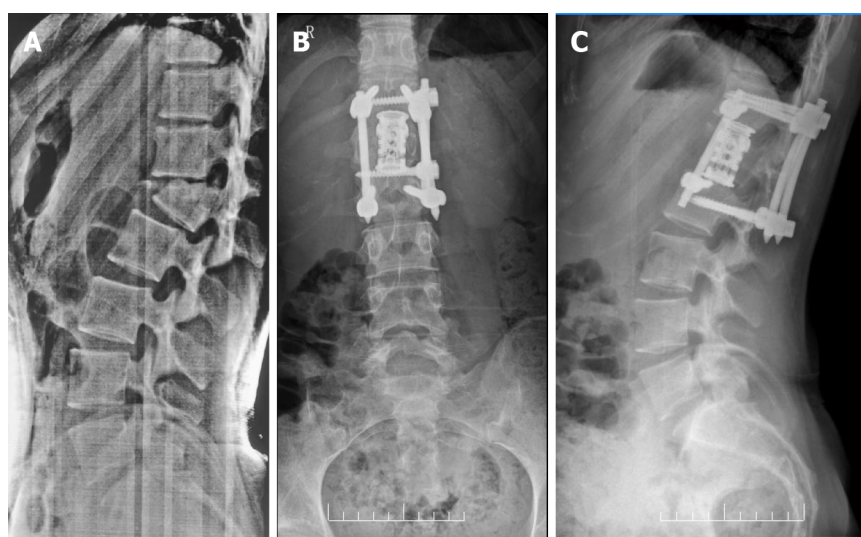
Thoracolumbar fracture-dislocation is frequently associated with nerve injury[1], which can be treated with either anterior or posterior surgery[14]. However, according to the load-sharing classification, posterior internal fixation may fail in cases of thoracolumbar burst fractures greater than 7 points[15]. Furthermore, posterior ligament reduction can reduce severe thoracolumbar fractures satisfactorily, but the sign of unstable healing accounted for 59.6%[16]. Moreover, the anterior operation was unable to stabilize the spine's posterior column[17]. As a result, either an anterior or posterior approach alone would be ineffective for treating severe thoracolumbar fracture dislocation.

It is a reliable method to perform anterior and posterior surgery simultaneously for severe thoracolumbar fracture and dislocation, which can achieve full decompression and better nerve recovery[2]. The preoperative Cobb angle for thoracolumbar kyphosis was 26°, and the postoperative Cobb angle was 5°. After 5 mo of observation, the Cobb angle was 5.6°. There was no obvious loss of Cobb angle, no signs of nonunion, and neural function improved from ASIA B to ASIA D.



DOI: 10.12998/wjcc.v11.i22.5358 Copyright ©The Author(s) 2023.

**Figure 3** TINAVI robot-assisted one-stage anteroposterior surgery in lateral position. A: Design the best virtual screw trajectory on 3D image; B: The electric drill is implanted with the guiding pin along the direction of the guiding cannula; C: C-arm fluoroscopy to determine the position of the guiding pin; D: The postoperative anteroposterior and lateral radiographs showed thoracolumbar kyphosis with a 5° Cobb's angle; E: Postoperative wound.



DOI: 10.12998/wjcc.v11.i22.5358 Copyright ©The Author(s) 2023.

**Figure 4** The anteroposterior and lateral radiographs of 5-mo follow-up showed no loss of corrected Cobb's angle. A: The pre-operative lateral radiographs showed thoracolumbar kyphosis with a 26° Cobb's angle; B: The anteroposterior radiographs of 5-mo follow-up; C: The lateral radiographs of 5-mo follow-up showed thoracolumbar kyphosis with a 5.6° Cobb's angle.

Traditional surgery without robot assistance takes longer time. Besides, the operator must master the technology of lateral pedicle screw insertion, which has more technical requirements for the surgeon. As a result, we attempt to perform anterior and posterior surgery for severe thoracolumbar fracture dislocation using the TINAVI robot and pedicle screw

implantation. There is no report that we are aware of that describes the treatment of severe thoracolumbar fracture dislocation with one-stage lateral anterior posterior combined surgery using the TINAVI robot.

Pedicle screw implantation accuracy was 85.8%-96.2% for "perfect" and 93.4%-96.7 for "clinically acceptable"[18,19]. Based on 3D images, the TINAVI robot system can significantly improve surgical accuracy and safety in pedicle screw fixation. The electric drill is not only easy to implant with the guiding pin along the direction of the guiding cannula under the accurate positioning guidance of the TINAVI robot, but it also does not require frequent fluoroscopy. Tissue trauma and operation time are significantly reduced. The screws at the rostral can be planned to tilt up and the screws at the distal can be planned to tilt down as much as possible, which may enable in the placement of the front screw.

At the end of 2016, the TINAVI robot developed in China was certified by the National Food and Drug Administration. Subsequently, it began to be officially applied in clinical practice and gradually expanded to the field of spinal surgery. Han *et al*[10] compared the safety and efficacy of robot assisted thoracolumbar surgery with the conventional fluoroscopy-assisted group thoracolumbar surgery through a prospective randomized controlled study, in which the rate of excellent screw placement position in the robotic group was 98.7%, higher than the 93.5% in the conventional group; In terms of deviations in screw planning positions and actual positions, the mean deviations of the screws in the robotic group were ( $1.5 \pm 0.8$ ) mm. Fan *et al*[20] previously conducted a randomized controlled study of robot assisted *vs* conventional fluoroscopy-assisted placement of cervical screws and showed that both the excellent and acceptable rates of screw placement were higher in the robotic group (87.6% *vs* 60.8% and 98.9% *vs* 91.2%); The deviation between the actual position of the screw and the planned position was 0.83 mm, lower than the deviation of the conventional group. In addition, Le *et al*[21] conducted a retrospective study on robot assisted and conventional fluoroscopy-assisted placement of lumbar cortical bone screws, and the results showed that the excellent and acceptable rates of screw positions in the robot group were higher than those in the acceptable group (87.2% *vs* 66.9% and 95.3% *vs* 86.9%).

This case report has some limitations. The number of cases is small, the follow-up time is short, and the results still need to be verified by larger samples and longer follow-up studies. In addition, the current cost of using TINAVI robot is still relatively high, and further research is needed to quantify the clinical benefits of its use.

## CONCLUSION

To summarize, the TINAVI robot-assisted one-stage anterior and posterior surgery in right lateral position for severe thoracolumbar fracture and dislocation is both safe and effective. It can insert pedicle screws precisely, reduce surgical time, and reduce tissue damage, and is expected to gradually become widely used in orthopedic clinical surgery in the future.

## ACKNOWLEDGEMENTS

We thanked Professor Fei Zou from the Department of Orthopaedics of Huashan Hospital affiliated to Fudan University for providing guidance for this operation.

## FOOTNOTES

**Author contributions:** Ye S and Chen YZ completed the surgery and wrote the manuscript; Zhong LJ and Yu CZ assisted in completing the surgery and recorded it; Zhang HK and Hong Y followed up the patient; All authors read and approved the final manuscript.

**Informed consent statement:** Written informed consent was obtained from the patient for publication of this case report and any accompanying images.

**Conflict-of-interest statement:** The authors declare that they have no conflict of interest to disclose.

**CARE Checklist (2016) statement:** The authors have read the CARE Checklist (2016), and the manuscript was prepared and revised according to the CARE Checklist (2016).

**Open-Access:** This article is an open-access article that was selected by an in-house editor and fully peer-reviewed by external reviewers. It is distributed in accordance with the Creative Commons Attribution NonCommercial (CC BY-NC 4.0) license, which permits others to distribute, remix, adapt, build upon this work non-commercially, and license their derivative works on different terms, provided the original work is properly cited and the use is non-commercial. See: <https://creativecommons.org/licenses/by-nc/4.0/>

**Country/Territory of origin:** China

**ORCID number:** Sen Ye 0000-0003-4425-7417; Yan-Zhen Chen 0000-0003-2919-5991; Ling-Jian Zhong 0000-0001-6383-8415; Chang-Zhang Yu 0000-0003-4358-9620; Han-Kun Zhang 0000-0002-0040-8570; Yang Hong 0000-0001-9066-7084.

**S-Editor:** Liu JH

**L-Editor:** A



## REFERENCES

- 1 Wang F, Zhu Y. Treatment of complete fracture-dislocation of thoracolumbar spine. *J Spinal Disord Tech* 2013; **26**: 421-426 [PMID: 22425889 DOI: 10.1097/BSD.0b013e31824e1223]
- 2 Xia Q, Xu BS, Zhang JD, Miao J, Li JG, Zhang XL, Zhou J. Simultaneous combined anterior and posterior surgery for severe thoracolumbar fracture dislocations. *Orthop Surg* 2009; **1**: 28-33 [PMID: 22009778 DOI: 10.1111/j.1757-7861.2008.00006.x]
- 3 Zhang B, Wang JC, Jiang YZ, Song QP, An Y. Effectiveness and postoperative rehabilitation of one-stage combined anterior-posterior surgery for severe thoracolumbar fractures with spinal cord injury. *World J Clin Cases* 2022; **10**: 6001-6008 [PMID: 35949859 DOI: 10.12998/wjcc.v10.i18.6001]
- 4 Ma Y, Deng SC, Jia ZH, Hao YH. Lateral position one-stage combined anteroposterior approach versus posterior approach with subtotal corpectomy, decompression, and reconstruction of spine in the treatment of thoracolumbar burst fractures. *Zhonghua Yi Xue Za Zhi* 2013; **93**: 2112-2116 [PMID: 24284239]
- 5 Coe JD, Arlet V, Donaldson W, Berven S, Hanson DS, Mudiya R, Perra JH, Shaffrey CI. Complications in spinal fusion for adolescent idiopathic scoliosis in the new millennium. A report of the Scoliosis Research Society Morbidity and Mortality Committee. *Spine (Phila Pa 1976)* 2006; **31**: 345-349 [PMID: 16449909 DOI: 10.1097/01.brs.0000197188.76369.13]
- 6 Jutte PC, Castelein RM. Complications of pedicle screws in lumbar and lumbosacral fusions in 105 consecutive primary operations. *Eur Spine J* 2002; **11**: 594-598 [PMID: 12522719 DOI: 10.1007/s00586-002-0469-8]
- 7 Li C, Wang L, Perka C, Trampuz A. Clinical application of robotic orthopedic surgery: a bibliometric study. *BMC Musculoskelet Disord* 2021; **22**: 968 [PMID: 34809652 DOI: 10.1186/s12891-021-04714-7]
- 8 Tian W. Robot-Assisted Posterior C1-2 Transarticular Screw Fixation for Atlantoaxial Instability: A Case Report. *Spine (Phila Pa 1976)* 2016; **41** Suppl 19: B2-B5 [PMID: 27145470 DOI: 10.1097/BRS.0000000000001674]
- 9 Tian W, Wang H, Liu YJ. Robot-assisted Anterior Odontoid Screw Fixation: A Case Report. *Orthop Surg* 2016; **8**: 400-404 [PMID: 27627725 DOI: 10.1111/os.12266]
- 10 Han X, Tian W, Liu Y, Liu B, He D, Sun Y, Han X, Fan M, Zhao J, Xu Y, Zhang Q. Safety and accuracy of robot-assisted versus fluoroscopy-assisted pedicle screw insertion in thoracolumbar spinal surgery: a prospective randomized controlled trial. *J Neurosurg Spine* 2019; **1**: 1-8 [PMID: 30738398 DOI: 10.3171/2018.10.SPINE18487]
- 11 Tian W, Fan M, Zeng C, Liu Y, He D, Zhang Q. Telerobotic Spinal Surgery Based on 5G Network: The First 12 Cases. *Neurospine* 2020; **17**: 114-120 [PMID: 32252160 DOI: 10.14245/ns.1938454.227]
- 12 Yongqi L, Dehua Z, Hongzi W, Ke Z, Rui Y, Zhou F, Shaobo W, Yi L. Minimally invasive versus conventional fixation of tracer in robot-assisted pedicle screw insertion surgery: a randomized control trial. *BMC Musculoskelet Disord* 2020; **21**: 208 [PMID: 32252725 DOI: 10.1186/s12891-020-03239-9]
- 13 Zhang Q, Xu YF, Tian W, Le XF, Liu B, Liu YJ, He D, Sun YQ, Yuan Q, Lang Z, Han XG. Comparison of Superior-Level Facet Joint Violations Between Robot-Assisted Percutaneous Pedicle Screw Placement and Conventional Open Fluoroscopic-Guided Pedicle Screw Placement. *Orthop Surg* 2019; **11**: 850-856 [PMID: 31663290 DOI: 10.1111/os.12534]
- 14 Chokshi JJ, Shah M. Outcomes of Including Fracture Level in Short-Segment Fixation for Thoracolumbar Fracture Dislocation. *Asian Spine J* 2019; **13**: 56-60 [PMID: 30326687 DOI: 10.31616/asj.2018.0064]
- 15 Park SR, Na HY, Kim JM, Eun DC, Son EY. More than 5-Year Follow-up Results of Two-Level and Three-Level Posterior Fixations of Thoracolumbar Burst Fractures with Load-Sharing Scores of Seven and Eight Points. *Clin Orthop Surg* 2016; **8**: 71-77 [PMID: 26929802 DOI: 10.4055/cios.2016.8.1.71]
- 16 Liang C, Liu G, Liang G, Zheng X, Yin D, Xiao D, Zeng S, Cai H, Chang Y. Healing pattern classification for thoracolumbar burst fractures after posterior short-segment fixation. *BMC Musculoskelet Disord* 2020; **21**: 373 [PMID: 32532236 DOI: 10.1186/s12891-020-03386-z]
- 17 Wu H, Fu C, Yu W, Wang J. The options of the three different surgical approaches for the treatment of Denis type A and B thoracolumbar burst fracture. *Eur J Orthop Surg Traumatol* 2014; **24**: 29-35 [PMID: 23412275 DOI: 10.1007/s00590-012-1152-3]
- 18 Zhang RJ, Zhou LP, Zhang L, Zhang HQ, Zhang JX, Shen CL. Safety and risk factors of TINAVI robot-assisted percutaneous pedicle screw placement in spinal surgery. *J Orthop Surg Res* 2022; **17**: 379 [PMID: 35941684 DOI: 10.1186/s13018-022-03271-6]
- 19 Du J, Gao L, Huang D, Shan L, Wang W, Fan Y, Hao D, Yan L. Radiological and Clinical Differences between Tinavi Orthopedic Robot and O-Arm Navigation System in Thoracolumbar Screw Implantation for Reconstruction of Spinal Stability. *Med Sci Monit* 2020; **26**: e924770 [PMID: 32918810 DOI: 10.12659/MSM.924770]
- 20 Fan M, Liu Y, He D, Han X, Zhao J, Duan F, Liu B, Tian W. Improved Accuracy of Cervical Spinal Surgery With Robot-Assisted Screw Insertion: A Prospective, Randomized, Controlled Study. *Spine (Phila Pa 1976)* 2020; **45**: 285-291 [PMID: 31568094 DOI: 10.1097/BRS.0000000000003258]
- 21 Le X, Tian W, Shi Z, Han X, Liu Y, Liu B, He D, Yuan Q, Sun Y, Xu Y. Robot-Assisted Versus Fluoroscopy-Assisted Cortical Bone Trajectory Screw Instrumentation in Lumbar Spinal Surgery: A Matched-Cohort Comparison. *World Neurosurg* 2018; **120**: e745-e751 [PMID: 30172976 DOI: 10.1016/j.wneu.2018.08.157]



Published by **Baishideng Publishing Group Inc**  
7041 Koll Center Parkway, Suite 160, Pleasanton, CA 94566, USA

**Telephone:** +1-925-3991568

**E-mail:** [bpgoffice@wjgnet.com](mailto:bpgoffice@wjgnet.com)

**Help Desk:** <https://www.f6publishing.com/helpdesk>

<https://www.wjgnet.com>

