

Changes in serum and histology of patients with chronic hepatitis B after interferon alpha-2b treatment

Hong-Lei Han, Zhen-Wei Lang

Hong-Lei Han, Zhen-Wei Lang, Department of Pathology, Beijing Youan Hospital, Beijing 100054, Beijing City, China

Correspondence to: Professor Zhen-Wei Lang, Department of Pathology, Beijing Youan Hospital, Beijing 100054, Beijing City, China
Telephone: +86-10-63292211-2402

Received: 2001-07-19 **Accepted:** 2001-09-21

Abstract

AIM: Chronic hepatitis B is a serious health problem. Interferon has long been used to treat Chronic hepatitis B. To evaluate the effects of interferon on chronic hepatitis B better, we designed the study to investigate the changes in sera and liver histology of patients with chronic hepatitis B after interferon alpha-2b treatment.

METHODS: Twenty-four patients with chronic hepatitis B were enrolled in this study. They all received interferon alpha-2b treatment as following: 3 million units, i.m., t.i.w., for 18 weeks. Sera of all patients were obtained respectively for evaluation of ALT, HBsAg, HBeAg, HBV DNA and TIMP-1 before and after interferon treatment, also a liver biopsy pre- and post-treatment was performed for comparison of HAI, HBsAg, HBeAg, TIMP-1 and activated HSC in the liver tissue.

RESULTS: Patients who had normalization of serum ALT and seroconversion of HBeAg and/or HBV DNA (blot hybridization) after treatment were defined as responders. The response rate in this study group was 37.5 % (7/24). Compared to pretreatment, the serum HBV DNA and TIMP-1 decreased significantly ($P < 0.05$), so did the HAI, HBsAg, HBeAg, TIMP-1 and activated HSC ($P < 0.05$).

CONCLUSION: The significant decrease in HBV DNA in sera, the seroconversion of HBeAg, and the decrease of viral expression in liver indicated that interferon alpha-2b treatment can inhibit viral replication. The normalization of ALT in sera and the improvement of HAI in liver showed that interferon alpha-2b can improve the liver histology of patients with chronic hepatitis B. At the same time, interferon alpha-2b treatment can reduce the TIMP-1 in serum and liver and decrease the number of activated HSC, which may alleviate or inhibit hepatic fibrosis. Although the response rate was unsatisfactory, interferon play a beneficial role on patients with chronic hepatitis B in other respects. We still need further studies to improve the therapy effects.

Han HL, Lang ZW. Changes in serum and histology of patients with chronic hepatitis B after interferon alpha-2b treatment. *World J Gastroenterol* 2003; 9(1): 117-121
<http://www.wjgnet.com/1007-9327/9/117.htm>

INTRODUCTION

Chronic hepatitis B is a serious problem threatening public health, especially in our country. Interferon has been used to treat it for a long time. It has been proved that after interferon

treatment, the response rate in patients with chronic hepatitis B is about 30-50 %, with normalization of ALT, seroconversion of HBeAg and HBV DNA and improvement of liver HAI^[1-11]. However, the effects on hepatic fibrosis and viral antigen in liver tissue have been seldom reported. In this study, we evaluated mainly the effects of interferon treatment on some indexes of sera and liver histology.

MATERIALS AND METHODS

Materials

Patients Twenty-four patients were enrolled in this study. Of these, 21 were male, 3 were female. The mean age was 38.4. All patients had moderately elevated serum ALT. All patients were negative for hepatitis C and D. None had alcoholic liver disease, autoimmune or drug-induced liver disease, no patients had received antiviral or immunomodulatory therapy. Informed consent was obtained from each patient before the study. All patients were treated with recombinant IFN- α -2b 3MU thrice a week for 18 weeks (The IFN- α -2b was a product of Anke Company of biological technic of Anhui Province). Liver biopsy was performed in each patient before and after IFN treatment and serum specimens were obtained at the same time.
Response to IFN- α -2b treatment Patients who had normalization of serum ALT and seroconversion of HBeAg and/or HBV DNA (blot hybridization) after treatment were defined as responders, while those with negative result were taken as non-responders.

Methods

Assay for serum HBV, HCV, CMV and EBV markers All markers were measured by using the enzyme linked immunosorbent assay (ELISA). Antibodies to HBsAg, anti-HBs, HBeAg, anti-HBe, anti-HBc-IgM, anti-HBc-IgG, anti-HCV-IgG and anti-HCV-IgM were products of American Abbott Company. Anti-CMV-IgG and anti-EBV-IgG were purchased from Italian Deyi Company. The reagents for HBV DNA blot hybridization were products of Yuanli Reagent Company of Shanghai Medical University.

Quantitative PCR of serum HBV DNA Blood samples were obtained under fasting conditions before and after the IFN treatment. All sera were stored at -40 °C until assay. Quantitative polymerized chain reaction (PCR) of HBV DNA was performed as the method introduced by American Biotronics Company^[12]. The logarithms of the HBV DNA levels were statistically analyzed.

Assay for serum TIMP-1 Serum TIMP-1 was evaluated by using sandwich method of ELISA. Multiclonal antibody to TIMP-1 was bought from Beijing Zhongshan Biological Company, while monoclonal antibody to TIMP-1 was from Fujian Maxim Biological Company. Other reagents for ELISA were purchased from Beijing Zhongshan Biological Company.

Histological analysis Liver specimens were graded by 2 pathologists blinded to the response to treatment, using the histological activity index (HAI) described by Knodell^[13].

Assay for viral antigen in liver Expression of HBsAg, HBeAg and HBeAg in liver were evaluated using immunohistochemical S-P method. S-P kit was produced by Fujian Maxim Biological

Company. The procedures were performed according to the kit instruction. Expression of viral antigen in the liver was evaluated by semi-quantitative scoring system referring to the method introduced by Lindh^[14]. Based on the ratio of positive cells, the score was 0-3 respectively, corresponding to the positivity in 0 %, 1-20 %, 20-50 %, and more than 50 % of hepatocytes examined.

Liver fibrosis (1) Using α -smooth muscle actin (α -SMA) as a marker of activated hepatic stellate cell (HSC), the changes of activated HSC in the liver were analysed. (2) The expression of TIMP-1 in the liver was also investigated by using immunohistochemical method. The reagents for both HSC and TIMP-1 were bought from Fujian Maxim Biological Company. Scoring systems were the same as that for viral antigens.

Statistical analysis

All statistics were performed by using statistical procedure of social science (SPSS), including chi-square test and Wilcoxon's rank sum test. The probability values less than 5 % were considered significant.

RESULTS

Responders and non-responders

After interferon treatment, 7/24 (37.5 %) of patients were responders who had normalization of ALT and seroconversion of HBeAg and/or HBV DNA. The other 15 (62.5%) patients were non-responders.

Changes in serum level of HBV DNA

The average logarithm of serum HBV DNA before interferon treatment was 8.20 ± 0.60 m, which changed to 7.21 ± 1.14 after treatment (Table 1 and Figure 1). Compared to pretreatment, the serum level of HBV DNA decreased significantly ($P < 0.05$). Moreover, the decrease of serum HBV DNA level of responders was significant ($P < 0.05$).

Table 1 Changes of serum HBV DNA of patients with chronic hepatitis B (Logarithm of the value expressed by copy/ml) ($\bar{x} \pm s$)

	responders (n=9)	non-responders (n=15)	all patients (n=24)
pretreatment	8.52 ± 0.39	8.00 ± 0.64	8.20 ± 0.60
post-treatment	7.24 ± 0.83	7.16 ± 0.14	7.21 ± 1.14
P value	$P = 0.028$	$P = 0.051$	$P = 0.002$

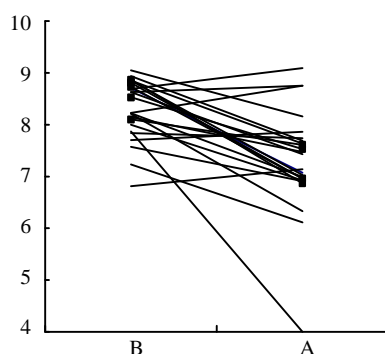


Figure 1 Changes of the logarithm value of serum HBV DNA of patients with chronic hepatitis B (B: before IFN treatment; A: after IFN treatment)

Changes in serum TIMP-1

Because of limited samples, only the serum TIMP-1 of 13

patients (4 responders and 9 non-responders) were evaluated. After the IFN treatment was completed, the optical density (OD) values of serum TIMP-1 of 10/13 (76.9 %) of patients decreased. Compared to pretreatment, the decrease was significant (pretreatment 0.481 ± 0.199 , post-treatment 0.367 ± 0.210 , $P < 0.05$) (Figure 2), regardless of the responders or non-responders.

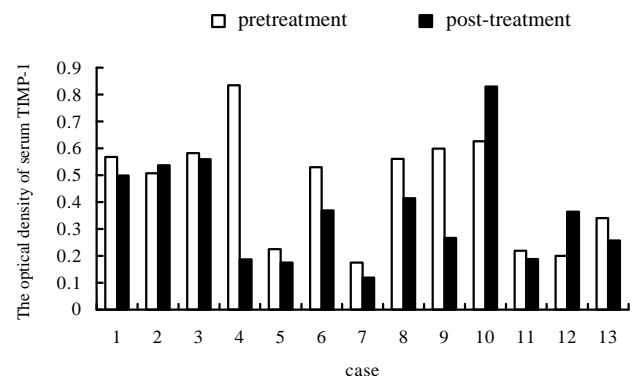


Figure 2 Changes of OD value of serum TIMP-1 of patients with chronic hepatitis B

Changes in HAI

Before IFN treatment, there was no significant difference of the HAI between the responders and non-responders ($P > 0.05$). After treatment, the HAI of patients decreased markedly ($P < 0.05$), especially the necrosis and intralobular inflammation ($P < 0.05$), but not the portal inflammation and fibrosis ($P > 0.05$). The changes of HAI of responders was significant ($P < 0.05$), while that of non-responders was insignificant ($P > 0.05$). (Table 2).

Table 2 Changes of HAI of patients with chronic hepatitis B ($\bar{x} \pm s$)

	responders (n=9)		nonresponders (n=15)		all patients (n=24)	
	pre-treatment	post-treatment	pre-treatment	post-treatment	pre-treatment	post-treatment
necrosis	2.57 ± 1.51	2.14 ± 1.21	2.82 ± 0.98	1.91 ± 1.04	2.72 ± 1.18^a	2.06 ± 1.11
lob. inf.	3.29 ± 0.49^a	1.57 ± 0.98	2.67 ± 0.82	2.36 ± 0.92	2.72 ± 0.89^a	1.78 ± 1.00
portal inf.	3.00 ± 1.00	2.29 ± 1.25	2.32 ± 0.96	2.09 ± 0.94	2.58 ± 1.00	2.39 ± 0.98
necrosis	1.71 ± 1.25	1.57 ± 1.13	1.91 ± 1.14	1.36 ± 1.12	1.82 ± 1.15	1.44 ± 1.10
HAI	10.57 ± 3.6^a	7.57 ± 4.12	9.41 ± 3.04	7.45 ± 3.11	9.86 ± 3.22^a	7.78 ± 3.30

^a $P < 0.05$

Viral antigens in liver

In the liver, HBsAg was expressed in the following pattern: membranous, submembranous, cytoplasmic or inclusion body. In this study, before IFN treatment, HBsAg was mainly located in the cytoplasm of hepatocytes, and was positive in 22/24 (91.7 %). The positivity of HBsAg in the liver of responders was not considerably different from that of non-responders ($P > 0.05$). After IFN treatment, 17 patients were found to have HBsAg expression in the liver, which was not significantly different from that of pretreatment (pretreatment 1.50 ± 1.79 , post-treatment 1.11 ± 0.83 , $P > 0.05$), regardless of responders or non-responders (Responders: pretreatment 1.33 ± 0.52 , post-treatment 1.17 ± 0.75 , $P > 0.05$; Non-responders: pretreatment 1.50 ± 0.80 , post-treatment 1.08 ± 0.90 , $P > 0.05$). The location of HBsAg switched from a diffuse cytoplasmic pattern to a membranous and/or sub membranous pattern.

HBcAg can be mainly detected in hepatocyte nucleus and cytoplasm (Figure 3). HBcAg expression was positive in 20/

24 (83.3 %). There was no significant difference between HBcAg expression in the liver of the responders and non-responders ($P>0.05$). However 12/20 (60 %) of patients were found to have a decrease in HBcAg expression in liver after IFN treatment, and the location of HBcAg changed to nucleic pattern mostly. Statistics showed that HBcAg expression in the liver declined significantly, Compared to pretreatment (1.28 ± 0.75 , post-treatment 0.61 ± 0.85 , $P<0.05$). The decrease in the responders was marked, but not that in the non-responders (Responders: pretreatment 1.67 ± 0.52 , post-treatment 0.17 ± 0.47 , $P<0.05$; Non-responders: pretreatment 1.08 ± 0.79 , post-treatment 0.83 ± 0.94 , $P>0.05$).

Positive HBeAg expression in liver was mainly located in cytoplasm and nucleus of hepatocytes (Figure 4). HBeAg was detected in the liver of 12/24 (50 %) of patients before IFN treatment and 4/24 (16.7 %) after treatment. Statistics proved that HBeAg expression decreased remarkably (pre-treatment 0.78 ± 0.94 , post-treatment 0.22 ± 0.43 , $P<0.05$). But the decrease in the responders was not significantly different from that in the non-responders ($P>0.05$).

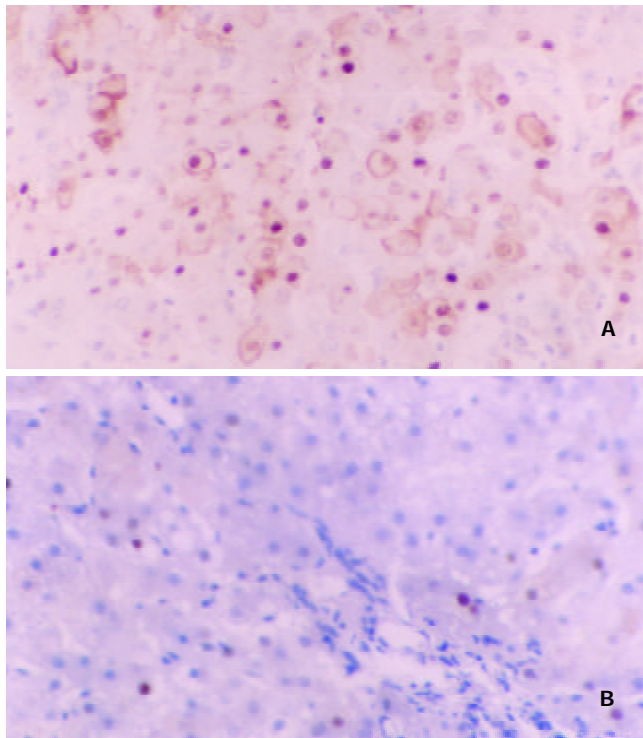


Figure 3 Changes of HBcAg expression in liver of patients with chronic hepatitis B. A: before IFN treatment; B: after IFN treatment

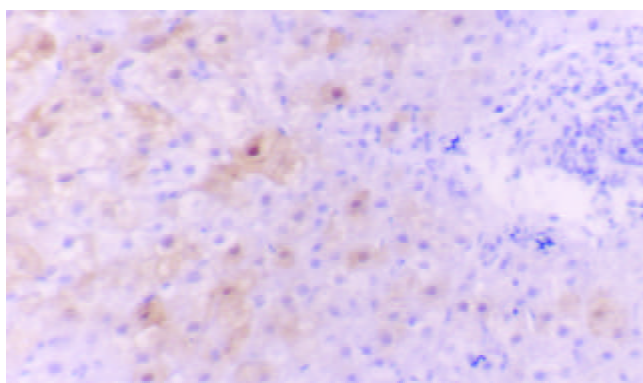


Figure 4 HBeAg expression in liver of patients with chronic hepatitis B before IFN treatment

Liver fibrosis

HSC in liver Normally, there are only several activated HSCs which contain α -SMA. But in the liver of patients with chronic hepatitis B, there were large number of α -SMA-positive HSC, diffusely located in the sinusoids (Figure 5). This showed that the number of α -SMA-positive HSC in the liver decreased significantly after treatment (pre-treatment 1.39 ± 0.35 , post-treatment 0.61 ± 0.70 , $P<0.05$). The marked change of HSC was related to the change of HAI ($P<0.05$), but not to the fibrosis score in accordance with HAI.

TIMP-1 in liver TIMP-1 in the liver was located in cytoplasm of hepatocyte (Figure 6). Before IFN- α treatment, 21/24 (87.5 %) of patients were detected positive TIMP-1 in their livers. In addition, there was no significant difference in TIMP-1 expression between responders and non-responders ($P>0.05$). After treatment, the TIMP-1 in liver of 18/21 (85.6 %) patients decreased. Compared to pretreatment, TIMP-1 in liver decreased significantly (pre-treatment 1.765 ± 1.033 , post-treatment 0.588 ± 0.441 , $P<0.01$), regardless of the responders or non-responders.

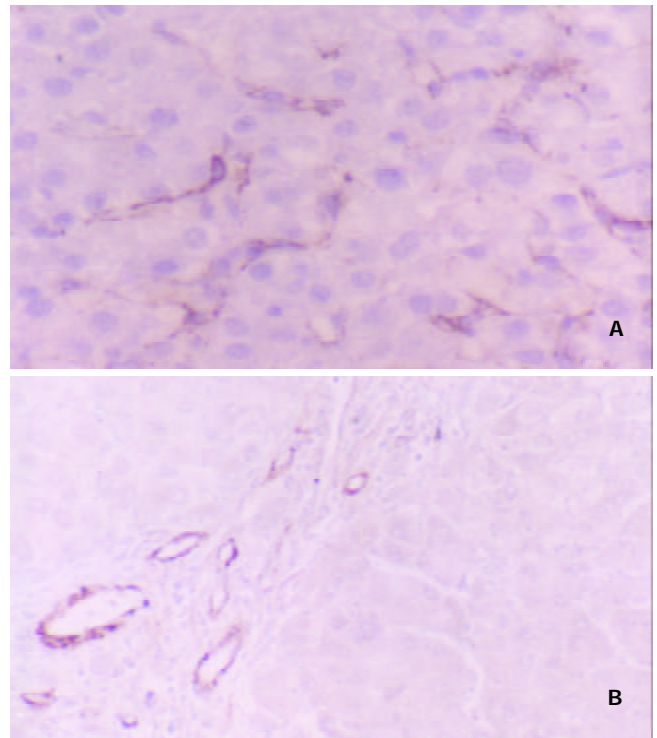


Figure 5 Changes of α -SMA-positive HSC in liver of patients with chronic hepatitis B. A: before IFN treatment; B: after IFN treatment

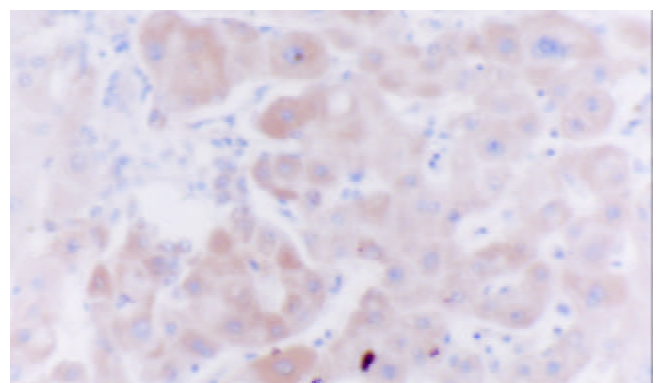


Figure 6 TIMP-1 in liver of patients with chronic hepatitis B before IFN treatment

DISCUSSION

Interferon- α treatment is effective in decreasing serum alanine transferase (ALT), converting serum HBeAg and HBVDNA to negative, and improving necroinflammation in the liver of patients with chronic hepatitis B. In this study, we evaluated the effect of interferon- α on both liver histology and serum parameters.

Viral markers in sera

Among the patients, 9/24 (37.5 %) showed response reaction after interferon treatment, which agreed with other studies^[14]. The serum ALT of responders became normal, and the serum HBeAg and/or HBVDNA became negative after treatment. Compared to pre-treatment, the serum HBVDNA of the patients decreased significantly ($P < 0.05$), especially that of the responders ($P < 0.05$). The results suggested that interferon- α could inhibit the viral replication.

Viral antigen in liver

It was reported that interferon- α can inhibit all hepatitis B virus antigens expression in primary hepatocyte culture^[15]. Moreover, interferon can change the location of HBsAg in hepatocyte from cytoplasm to the cell membrane or submembrane region^[15], which may enhance immune recognition and clearance of infected hepatocytes. Our study evaluated the effect of interferon- α on viral antigen in liver of chronic hepatitis B. In this group, the decline of HBsAg expression in liver was not significant, but the HBsAg expression switched from cytoplasmic to membranous/submembranous, which supported some previous studies^[5,6]. However, the HBcAg and HBeAg in the liver decreased significantly after interferon treatment, especially in the responders, but not in the non-responders. This might be related to the fact that HBcAg and HBeAg of hepatocytes were target antigens of immune reaction mediated by HBV. IFN could enhance the recognition of immune system on the infected hepatocytes.

HAI

Shiratori *et al* proved that interferon therapy can improve liver histology of hepatitis C by alleviating hepatic inflammation and fibrosis^[16]. Our study showed that after interferon treatment, HAI of liver of all the patients decreased significantly ($P < 0.05$), mainly in the aspects of necrosis and intralobular inflammation. The change in responders was significant, but not that in the non-responders. This indicated interferon treatment can improve the hepatic lesions of patients with chronic hepatitis B.

Liver fibrosis

Many patients with chronic hepatitis B progress slowly to liver fibrosis even cirrhosis. During this course, HSC plays a key role in the process of fibrosis. Proliferation and transformation of HSC is basic characteristic of liver fibrosis. On the one hand, liver injury and cytokines released stimulate HSC to proliferate, differentiate and acquire myofibroblast phenotype, with increase of collagen synthesis, expression of α -SMA, secretion and desposition of extracellular matrix (ECM)^[17,18]. On the other hand, HSC can secrete matrix metalloproteinase (MMP) which can degrade ECM. It is worth noting that HSC also secretes tissue inhibitor of metalloproteinase (TIMP)-the inhibitor of MMP. TIMP can noncovalently bind with MMP to inhibit the degradation of ECM, and promote liver fibrosis. Researches showed that in liver of patients with liver disease related to hepatitis B, the expression of TIMPs and MMP altered to make the liver tend to develop fibrosis^[19-22]. Certain medicine can improve liver cirrhosis^[23]. Several reports suggested that interferon treatment can alleviate hepatic fibrosis caused by viral hepatitis^[24-30]. The mechanism is not clear. Some evidence

supported that interferon reduced HSCs^[31], probably by inducing the apoptosis of HSCs^[32]. Others believed that interferon changed the amount of enzymes, such as MMP and TIMPs^[33,34].

HSC in liver

In our study, the number of HSC containing α -SMA decreased significantly after interferon treatment ($P < 0.05$). The α -SMA expression by HSC decreased in 50 % of patients. This suggested that interferon treatment might inhibit the proliferation or transformation of HSC with the same conclusion by Guido's^[31]. The significant association of α -SMA to liver HAI ($P < 0.05$) suggested that the effect of interferon on HSC maybe related to its anti-inflammatory function. But there was no significant relation between reduction of HSC and change of fibrosis according to Knodell's HAI, which might be due to the small size of our patients.

TIMP-1 in serum and liver

Mitsuda *et al* found that IFN- α could not only reduce the TIMP-1 in serum to enhance fibrinolysis, but also inhibit the fibrogenesis of patients with chronic hepatitis C^[33]. Whether IFN- α has similar effect on the patients with chronic hepatitis B remains to be seen.

In this study, TIMP-1 in both serum and liver of patients with chronic hepatitis B decreased markedly after IFN- α treatment. This phenomenon suggests that IFN- α can inhibit production or TIMP-1 expression to improve fibrinolysis and inhibit fibrosis.

In conclusion, our study suggests that IFN- α treatment can inhibit viral replication, alleviate liver injury, inhibit activation of HSC, decrease TIMP-1 in liver and serum and inhibit liver fibrosis. The detailed mechanism and the optimal dose and course of IFN- α still deserve more studies. Although the interval of two biopsy was not very long, evidence suggested that interferon has long-term beneficial effect in patients with chronic hepatitis B^[35]. The result was not very satisfactory. Maybe we should combine interferon and other medicines to treat chronic hepatitis B, as some study did^[36].

REFERENCES

- 1 Pessoa MG, Wright TL. Update on clinical trials in the treatment of hepatitis B. *J Gastroenterol Hepatol* 1999; **14** (Suppl): S6-S11
- 2 Lau GKK, Carman WF, Locarnini SA, Okuda K, Lu ZM, Williams R, Lam SK. Treatment of chronic hepatitis B virus infection: An Asia-Pacific perspective. *J Gastroenterol Hepatol* 1999; **14**: 3-12
- 3 Yao GB. Treatment of chronic hepatitis B in China. *J Gastroenterol Hepatol* 2000; **15**(Suppl): E61-E66
- 4 Ishikawa T, Kakumu S. Update of liver disease related to chronic hepatitis B virus infection. *Intern Med* 2001; **40**: 178-179
- 5 Liaw YF. Management of patients with chronic hepatitis B. *J Gastroenterol Hepatol* 2002; **17**: 406-408
- 6 Wang XZ, Chen YX, Ma LS, Ma JY, Pan BR. Antiviral therapy of chronic hepatitis B in China. *Shijie Huaren Xiaohua Zazhi* 2002; **10**: 745-748
- 7 Hoofnagle JH, Peters M, Mullen KD, Jones DB, Rustgi V, Bisceglie AD, Hallahan C, Park Y, Meschivetz C, Jones EA. Randomized, controlled trial of recombinant human α -interferon in patients with chronic hepatitis B. *Gastroenterol* 1988; **95**: 1318-1325
- 8 Oliveri F, Santantonio T, Bellati G, Colombatto P, Mels GC, Carriero L, Dastoli G, Pastore G, Ideo G, Bonino F, Brunetto MR. Long term response to therapy of chronic anti-HBe-Positive Hepatitis B is poor independent of type and schedule of interferon. *Am J Gastroenterol* 1999; **94**: 1366-1372
- 9 Brunetto MR, Oliveri F, Coco B, Leandro G, Colombatto P, Gorin JM, Bonino F. Outcome of anti-HBe positive chronic hepatitis B in alpha-interferon treated and untreated patients: a long term cohort study. *J Hepatol* 2002; **36**: 263-270
- 10 You J, Zhuang L, Tang BZ, Yang WB, Ding SY, Li W, Wu RX,

- Zhang HL, Zhang YM, Yan SM, Zhang L. A randomized controlled clinical trial on the treatment of Thymosin a1 versus interferon- α in patients with hepatitis B. *World J Gastroenterol* 2001; **7**: 411-414
- 11 **Zhuang L**, You J, Tang BZ, Ding SY, Yan KH, Peng D, Zhang YM, Zhang L. Preliminary results of Thymosins-a1 versus interferon- α -treatment in patients with HBeAg negative and serum HBV DNA positive chronic hepatitis B. *World J Gastroenterol* 2001; **7**: 407-410
- 12 **Kaneko S**, Feinstone SM, Miller RH. Rapid and sensitive method for the detection of serum hepatitis B virus DNA using the Polymerase Chain Reaction Technique. *J Clin Microbiol* 1989; **27**: 1930-1933
- 13 **Knodel RG**, Ishak KG, Black WC, Chen TS, Craig R, Kaplowitz N, Kiernan TW, Wollman J. Formulation and application of a numerical scoring system for assessing histological activity in asymptomatic chronic active hepatitis. *Hepatology* 1981; **1**: 431-435
- 14 **Lindh M**, Savage K, Rees J, Garwood L, Horal P, Norkrans G, Dhillon AP. HBeAg immunostaining of liver tissue in various stages of chronic hepatitis B. *Liver* 1999; **19**: 294-298
- 15 **Lau JYN**, Bain VG, Naoumov NV, Smith HM, Alexander GJM, Williams R. Effect of interferon- γ on hepatitis B viral antigen expression in primary hepatocyte culture. *Hepatology* 1991; **14**: 975-979
- 16 **Shiratori Y**, Imazeki F, Moriyama M, Yano M, Arakawa Y, Yokosuka O, Kuroki T, Nishiguchi S, Sata M, Yamada G, Fujiyama S, Yoshida H, Omata M. Histological improvement of fibrosis in patients with hepatitis C who have sustained response to interferon therapy. *Ann Intern Med* 2000; **132**: 517-524
- 17 **Qin JP**, Jiang MD. Phenotype and regulation of hepatic stellate cell and liver fibrosis. *Shijie Huaren Xiaohua Zazhi* 2001; **9**: 801-804
- 18 **Huang GC**, Zhang JS. Signal transduction in the cells activated by hepatic stellate cells. *Shijie Huaren Xiaohua Zazhi* 2001; **9**: 1056-1060
- 19 **Xie YM**, Nie QH, Zhou YX, Cheng YQ, Kang WZ. Detection of TIMP-1 and TIMP-2 RNA expressions in cirrhotic liver tissue using digoxigenin labeled probe by in situ hybridization. *Shijie Huaren Xiaohua Zazhi* 2001; **9**: 251-254
- 20 **Nie QH**, Cheng YQ, Xie YM, Zhou YX, Bai XG, Cao YZ. Methodologic research on TIMP-1, TIMP-2 detection as a new diagnostic index for hepatic fibrosis and its significance. *World J Gastroenterol* 2002; **8**: 282-287
- 21 **Liu HL**, Li XH, Wang DY, Yang SP. Matrix metalloproteinase-2 and tissue inhibitor of metalloproteinase -1 expression in fibrotic rat liver. *World J Gastroenterol* 2000; **6**: 881-884
- 22 **Wu CH**. Fibrodynamics-elucidation of the mechanisms and sites of liver fibrogenesis. *World J Gastroenterol* 1999; **5**: 388-390
- 23 **Wang LT**, Zhang B, Jie J. Effect of anti-fibrosis compound on collagen expression of hepatic cells in experimental liver fibrosis of rats. *World J Gastroenterol* 2000; **6**: 877-880
- 24 **Li XQ**, Zeng MX, Ling QH. Effects of interferon- γ on DNA synthesis and collagen production of cultured rat hepatocytes. *Shijie Huaren Xiaohua Zazhi* 1998; **6**: 488-490
- 25 **Cheng ML**, Wu YY, Huang KF, Luo TY, Ding YS, Lu YY, Liu RC, Wu J. Clinical study on the treatment of liver fibrosis due to hepatitis B by IFN- α 1 and traditional medicine preparation. *World J Gastroenterol* 1999; **5**: 267-269
- 26 **Cheng ML**, Lu YY, Wu J, Luo TY, Huang KF, Ding YS, Liu RC, Li J, Li Z. Three-year follow-up study on hepatic fibrosis due to chronic hepatitis B is treated by interferon- α -1b and traditional medicine preparation. *World J Gastroenterol* 2000; **6**(suppl 3): 81
- 27 **Zavaglia C**, Airolidi A, Pinzello G. Antiviral therapy of HBV- and HCV-induced liver cirrhosis. *J Clin Gastroenterol* 2000; **30**: 234-241
- 28 **Du XF**, Weng HL, Cai WM. Histological changed in 20 hepatic fibrosis with chronic hepatitis B after human interferon- α treatment. *Chin J Hepatol* 2001; **9**: 273-275
- 29 **Weng HL**, Cai WM, Liu RH. Animal experiment and clinical study of effect of gammaa2interferon on hepatic fibrosis. *World J Gastroenterol* 2001; **7**: 42-48
- 30 **Deuffic-Burban S**, Poynard T, Valleron AJ. Quantification of fibrosis progression in patients with chronic hepatitis C using a Markov model. *J Viral Hepatitis* 2002; **9**: 114-122
- 31 **Guido M**, Rugge M, Chemello L, Leandro G, Fattovich G, Giustina G, Cassaro M, Alberti A. Liver stellate cells in chronic viral hepatitis: the effect of interferon therapy. *J Hepatol* 1996; **24**: 301-307
- 32 **Xu WH**, Lü XX, Zhu JR. Apoptosis of hepatic stellate cell of rats with liver fibrosis. *Shijie Huaren Xiaohua Zazhi* 2002; **10**: 972-974
- 33 **Mitsuda A**, Suou T, Ikuta Y, Kawasaki H. Changes in serum tissue inhibitor of matrix metalloproteinase-1 after interferon alpha treatment in chronic hepatitis C. *J Hepatol* 2000; **32**: 666-672
- 34 **Wang Y**, Gao Y, Yu JL, Huang YQ, Jiang XQ. Effect of interferon-alpha on interstitial collagenase gene expression in rat liver fibrosis. *Shijie Huaren Xiaohua Zazhi* 2001; **9**: 20-23
- 35 **Lin SM**, Sheen IS, Chien RN, Chu CM, Liaw YF. Long term beneficial effect of interferon therapy in patients with chronic hepatitis B virus infection. *Hepatology* 1999; **29**: 971-975
- 36 **You J**, Zhuang L, Tang BZ, Yang H, Yang WB, Li W, Zhang HL, Zhang YM, Zhang L, Yan SM. Interferon alpha with thymopeptide in the treatment of chronic hepatitis B. *Shijie Huaren Xiaohua Zazhi* 2001; **9**: 388-391

Edited by Wu XN