

World Journal of *Clinical Cases*

World J Clin Cases 2024 March 16; 12(8): 1382-1548



Contents

Thrice Monthly Volume 12 Number 8 March 16, 2024

EDITORIAL

- 1382 Latest updates on structure and recommendations of cardiac rehabilitation programs in chronic heart failure
Kourek C, Briasoulis A, Magouliotis DE, Skoularigis J, Xanthopoulos A
- 1388 Immunoglobulin A glomerulonephropathy: A review
El Labban M, Surani S

ORIGINAL ARTICLE

Retrospective Study

- 1395 Serum proteins differentially expressed in gestational diabetes mellitus assessed using isobaric tag for relative and absolute quantitation proteomics
Cao WL, Yu CP, Zhang LL

Observational Study

- 1406 Effect of comprehensive nursing on the quality of life and swallowing function in individuals diagnosed with ischemic stroke
Hu HF, Sang YF, Xiao YQ

META-ANALYSIS

- 1416 Safety and effectiveness of butorphanol in epidural labor analgesia: A protocol for a systematic review and meta-analysis
Tang GC, He M, Huang ZZ, Cheng Y

CASE REPORT

- 1422 Left lower lobe sleeve resection for the clear cell variant of pulmonary mucoepidermoid carcinoma: A case report
Yu XH, Wang WX, Yang DS, Gong LH
- 1430 Lower extremity peripherally inserted central catheter placement ectopic to the ascending lumbar vein: A case report
Zhu XJ, Zhao L, Peng N, Luo JM, Liu SX
- 1437 Effect of foot reflexology on an infant with sensorineural hearing loss: A case report
Lee YJ, Chen MQ, Dong J
- 1442 Development of immature ovarian teratoma after mature teratoma in a girl with familial ovarian teratoma: A case report
Ju UC, Kang WD, Kim SM

- 1448** Metastatic clear cell sarcoma of the pancreas: A rare case report
Liu YJ, Zou C, Wu YY
- 1454** 3M syndrome patient with a novel mutation: A case report
Luo MR, Dai SM, Li Y, Wang Q, Liu H, Gao P, Liu JY, Chen J, Zhao SJ, Yin GY
- 1461** Appendiceal intussusception complicated by adenocarcinoma of the cecum: A case report
Long Y, Xiang YN, Huang F, Xu L, Li XY, Zhen YH
- 1467** Malignant triton tumor in the abdominal wall: A case report
Yang HJ, Kim D, Lee WS, Oh SH
- 1474** Multilocular thymic cysts can be easily misdiagnosed as malignant tumor on computer tomography: A case report
Sun J, Yang QN, Guo Y, Zeng P, Ma LY, Kong LW, Zhao BY, Li CM
- 1481** Diagnosis of poorly differentiated adenocarcinoma of the stomach by confocal laser endomicroscopy: A case report
Lou JX, Wu Y, Huhe M, Zhang JJ, Jia DW, Jiang ZY
- 1487** High-grade pancreatic intraepithelial neoplasia diagnosed based on changes in magnetic resonance cholangiopancreatography findings: A case report
Furuya N, Yamaguchi A, Kato N, Sugata S, Hamada T, Mizumoto T, Tamaru Y, Kusunoki R, Kuwai T, Kouno H, Kuraoka K, Shibata Y, Tazuma S, Sudo T, Kohno H, Oka S
- 1497** Chronic infectious unilateral giant thyroid cyst related to diabetes mellitus: A case report
Liu JB, Zhang SL, Jiang WL, Sun HK, Yang HC
- 1504** Multiple thoracic and abdominal foregut duplication cysts: A case report
Alsinan TA, Altokhais TI
- 1510** Advanced cervix cancer patient with chemotherapy-induced grade IV myelosuppression achieved complete remission with cadonilimab: A case report
Zhu R, Chen TZ, Sun MT, Zhu CR
- 1517** Detection of 4p16.3 deletion and 11p15.5p15.4 gain in a boy by comparative genomic hybridization array: A case report
Kaya I
- 1523** Eccrine porocarcinoma in the temple of an elderly woman: A case report
Wu ZW, Zhu WJ, Huang S, Tan Q, You C, Hu DG, Li LN
- 1530** Analysis and monitoring of drug therapy in a patient with peptic ulcer complicated by infection: A case report
Gou YP, Huang Y, Chen L, Zheng W, Zheng YH
- 1536** Primary gastroduodenal tuberculosis presenting as gastric outlet obstruction: A case report and review of literature
Ali AM, Mohamed YG, Mohamud AA, Mohamed AN, Ahmed MR, Abdullahi IM, Saydam T

- 1544** Clinical manifestations and the prenatal diagnosis of trisomy 7 mosaicism: Two case reports

Hou F, Li Y, Jin H

ABOUT COVER

Peer Reviewer of *World Journal of Clinical Cases*, Makram Koubaa, MD, Assistant Professor, Department of Infectious Diseases, Hedi Chaker University Hospital, Sfax 3029, Tunisia. makram.koubaa@gmail.com

AIMS AND SCOPE

The primary aim of *World Journal of Clinical Cases* (WJCC, *World J Clin Cases*) is to provide scholars and readers from various fields of clinical medicine with a platform to publish high-quality clinical research articles and communicate their research findings online.

WJCC mainly publishes articles reporting research results and findings obtained in the field of clinical medicine and covering a wide range of topics, including case control studies, retrospective cohort studies, retrospective studies, clinical trials studies, observational studies, prospective studies, randomized controlled trials, randomized clinical trials, systematic reviews, meta-analysis, and case reports.

INDEXING/ABSTRACTING

The WJCC is now abstracted and indexed in Science Citation Index Expanded (SCIE, also known as SciSearch®), Journal Citation Reports/Science Edition, Current Contents®/Clinical Medicine, PubMed, PubMed Central, Reference Citation Analysis, China Science and Technology Journal Database, and Superstar Journals Database. The 2023 Edition of Journal Citation Reports® cites the 2022 impact factor (IF) for WJCC as 1.1; IF without journal self cites: 1.1; 5-year IF: 1.3; Journal Citation Indicator: 0.26; Ranking: 133 among 167 journals in medicine, general and internal; and Quartile category: Q4.

RESPONSIBLE EDITORS FOR THIS ISSUE

Production Editor: Hua-Ge Yin, Production Department Director: Xu Guo, Editorial Office Director: Jin-Lei Wang.

NAME OF JOURNAL

World Journal of Clinical Cases

ISSN

ISSN 2307-8960 (online)

LAUNCH DATE

April 16, 2013

FREQUENCY

Thrice Monthly

EDITORS-IN-CHIEF

Bao-Gan Peng, Salim Surani, Jerzy Tadeusz Chudek, George Kontogeorgos, Maurizio Serati

EDITORIAL BOARD MEMBERS

<https://www.wjgnet.com/2307-8960/editorialboard.htm>

PUBLICATION DATE

March 16, 2024

COPYRIGHT

© 2024 Baishideng Publishing Group Inc

INSTRUCTIONS TO AUTHORS

<https://www.wjgnet.com/bpg/gerinfo/204>

GUIDELINES FOR ETHICS DOCUMENTS

<https://www.wjgnet.com/bpg/GerInfo/287>

GUIDELINES FOR NON-NATIVE SPEAKERS OF ENGLISH

<https://www.wjgnet.com/bpg/gerinfo/240>

PUBLICATION ETHICS

<https://www.wjgnet.com/bpg/GerInfo/288>

PUBLICATION MISCONDUCT

<https://www.wjgnet.com/bpg/gerinfo/208>

ARTICLE PROCESSING CHARGE

<https://www.wjgnet.com/bpg/gerinfo/242>

STEPS FOR SUBMITTING MANUSCRIPTS

<https://www.wjgnet.com/bpg/GerInfo/239>

ONLINE SUBMISSION

<https://www.f6publishing.com>



Clinical manifestations and the prenatal diagnosis of trisomy 7 mosaicism: Two case reports

Fei Hou, Yan Li, Hua Jin

Specialty type: Medicine, research and experimental

Provenance and peer review: Unsolicited article; Externally peer reviewed.

Peer-review model: Single blind

Peer-review report's scientific quality classification

Grade A (Excellent): 0
Grade B (Very good): 0
Grade C (Good): 0
Grade D (Fair): 0
Grade E (Poor): 0

P-Reviewer: Velikova TV, Bulgaria

Received: December 29, 2023

Peer-review started: December 29, 2023

First decision: January 16, 2024

Revised: February 8, 2024

Accepted: February 21, 2024

Article in press: February 21, 2024

Published online: March 16, 2024



Fei Hou, Yan Li, Hua Jin, Department of Prenatal Diagnosis, Jinan Maternal and Child Health Hospital, Jinan 250001, Shandong Province, China

Corresponding author: Hua Jin, PhD, Doctor, Department of Prenatal Diagnosis, Jinan Maternal and Child Health Hospital, No. 2 Jianguoxiaojing 3 Road, Shizhong District, Jinan 250001, Shandong Province, China. tonyshirly@163.com

Abstract

BACKGROUND

The clinical manifestations of trisomy 7 mosaicism are diverse and nonspecific, so prenatal diagnosis is very difficult.

CASE SUMMARY

Two pregnant women with abnormal prenatal screening results were included. One was a 22-year-old woman (G1P0). At 31st week of gestation, ultrasound revealed that the posterior horn of the left lateral ventricle was 10 mm and the right renal pelvis had a separation of 7 mm. The other pregnant woman was 33 years old (G2P1L1A0), and her fetus was found to have a cardiac malformation at the 24th week of gestation. Copy number variation sequencing, whole-exome sequencing and karyotype analysis were carried out after amniocentesis, and both fetuses were diagnosed with trisomy 7 mosaicism. After parental counseling, one woman continued the pregnancy, and the other woman terminated the pregnancy.

CONCLUSION

In trisomy 7 mosaicism, the low proportion of trisomy does not lead to abortion, but can result in abnormal fetal development, which can be detected *via* ultrasound. Therefore, clinicians need to pay more attention to various aspects of fetal growth and development, combining with imaging, cellular, molecular genetics and other methods to perform comprehensive evaluations of fetuses to provide more reliable genetic counseling for pregnant women.

Key Words: Trisomy 7 mosaicism; Copy number variation sequencing; Whole-exome sequencing; Karyotype analysis; Prenatal diagnosis; Case report

©The Author(s) 2024. Published by Baishideng Publishing Group Inc. All rights reserved.

Core Tip: Herein, two fetuses were prenatally diagnosed according to abnormal ultrasound findings, including a widened posterior horn of the left lateral ventricle, renal dysplasia and a cardiac malformation. Copy number variation sequencing, whole-exome sequencing and karyotype analysis were carried out, and both fetuses were confirmed to have trisomy 7 mosaicism.

Citation: Hou F, Li Y, Jin H. Clinical manifestations and the prenatal diagnosis of trisomy 7 mosaicism: Two case reports. *World J Clin Cases* 2024; 12(8): 1544-1548

URL: <https://www.wjgnet.com/2307-8960/full/v12/i8/1544.htm>

DOI: <https://dx.doi.org/10.12998/wjcc.v12.i8.1544>

INTRODUCTION

Non-mosaic trisomy 7 usually leads to spontaneous abortion in early pregnancy. As a result, the mosaic form of trisomy 7, which is detected by noninvasive prenatal screening (NIPS) or chorionic villus sampling, is more likely to be present, either confined placental mosaicism or fetal mosaicism[1]. Trisomy 7 is the most frequently observed type of rare autosomal trisomy in NIPS[1]. Because it involves imprinting genes, trisomy 7 may lead to uniparental diploidy (UPD) through trisomic rescue. Therefore, it is crucial to provide correct and appropriate prenatal diagnosis and genetic counseling to pregnant women. However, the prenatal diagnosis of trisomy 7 mosaicism is difficult because of its variable and nonspecific clinical features[2]. Here, we report the ultrasound manifestations and prenatal diagnosis of two cases with trisomy 7 mosaicism.

CASE PRESENTATION

Chief complaints

Two pregnant women with abnormal ultrasound results presented to our hospital for prenatal diagnosis.

History of present illness

The prenatal screening results of both pregnant women revealed low risk. However, their ultrasound examination results suggested abnormal fetal development.

History of past illness

Both pregnant women had no history of past illness.

Personal and family history

Neither the pregnant women nor their husbands had a significant personal or family history.

Physical examination

The physical examinations of the two pregnant women did not reveal any abnormalities.

Laboratory examinations

Copy number variation sequencing (CNV-seq), whole-exome sequencing (WES) and karyotype analysis were carried out after amniocentesis. No pathogenic mutations associated with the clinical presentation were detected by WES. The CNV-seq results revealed that the first fetus had trisomy 7 mosaicism with approximately 40% mosaicism, while the karyotype analysis revealed 47,XN,+7[45]/46,XN[34] (Figure 1).

The results for the second fetus were similar to those for the first fetus. CNV-seq revealed 65% trisomy 7, and karyotype analysis revealed 47,XN,+7[65]/46,XN[36] (Figure 2).

Imaging examinations

In the first pregnant woman, at the 16th week of gestation, ultrasound showed that the fetus had a single umbilical artery and a choroid plexus cyst; at the 21st week of gestation, ultrasound showed an echogenic bowel and mild separation of bilateral renal pelvis; and at the 31st week of gestation, ultrasound showed that the posterior horn of left lateral ventricle was 10 mm and the right renal pelvis had a separation of 7 mm. In the second pregnant woman, at the 24th week of gestation, ultrasound revealed a fetal cardiac malformation, including severe aortic stenosis, mild mitral stenosis with severe regurgitation, left ventricular cord sclerosis and a small foramen ovale.

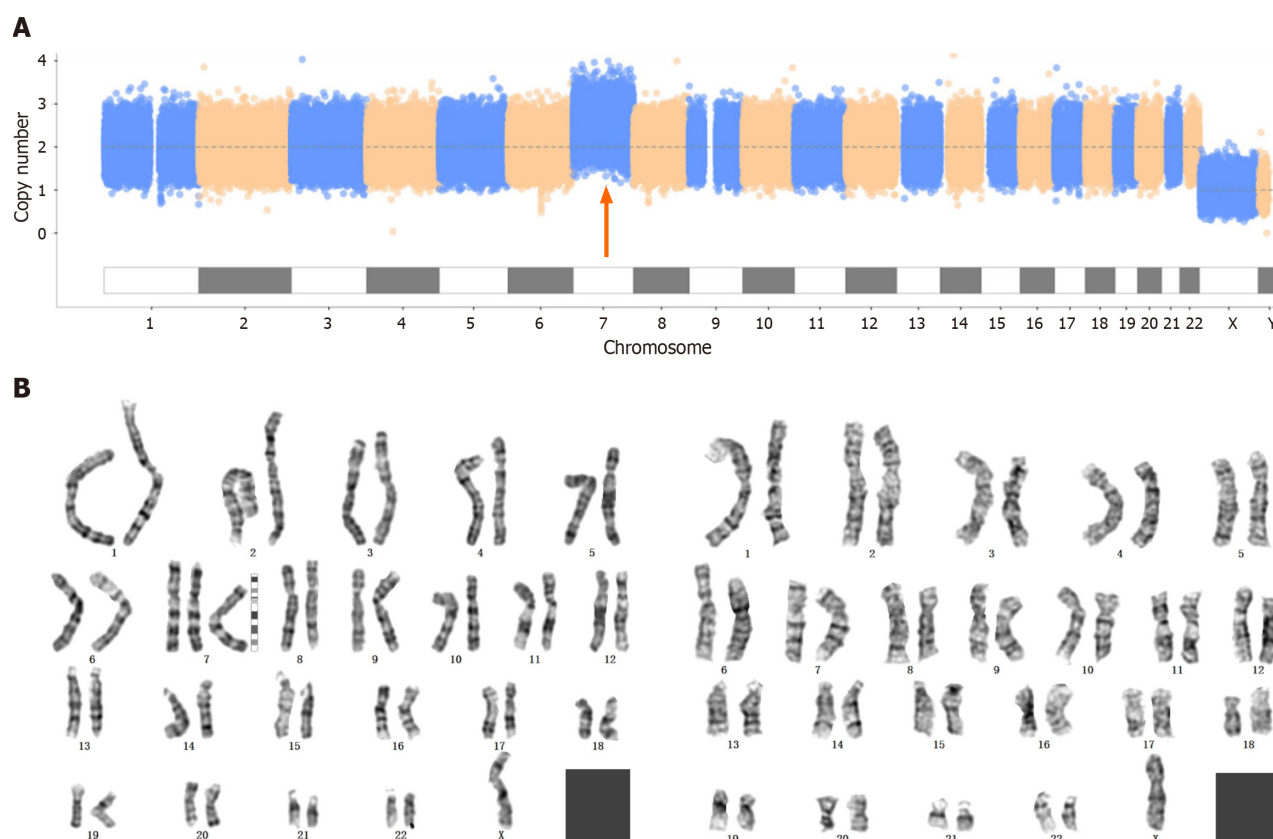


Figure 1 Prenatal diagnosis of the first fetus. A: The copy number variation sequencing results; B: The karyotype analysis results.

FINAL DIAGNOSIS

According to these findings, both fetuses were diagnosed with trisomy 7 mosaicism.

TREATMENT

We did not provide treatment.

OUTCOME AND FOLLOW-UP

After parental counseling, the second pregnant woman terminated the pregnancy, and the other pregnant woman delivered a baby at the 39th week of gestation. The baby was followed up for 1 year after birth, at which point no obvious abnormalities were found.

DISCUSSION

Trisomy 7 usually leads to spontaneous abortion in early pregnancy, and trisomy 7 mosaicism is most commonly reported. Previous studies have shown that 15%-80% of trisomy 7 in the placenta will not lead to stillbirth or miscarriage, and the prognosis is good if UPD or fetal chimerism is not involved[3,4]. Trisomy 7 mosaicism may be associated with Potter syndrome or renal dysplasia, cardiac abnormalities, prenatal and postnatal growth retardation, cleft lip and palate, recurrent ear infections, and epilepsy[5]. Consistent with the findings of previous reports, the two fetuses reported in this study exhibited a certain degree of renal dysplasia or a cardiac malformation due to trisomy 7 mosaicism.

A high proportion of trisomy 7 in the placenta or fetus may lead to intrauterine death[6,7]. The lower the proportion of trisomy is, the lower the effect on the fetus. Hsu *et al*[7] summarized the outcomes of 8 fetuses prenatally diagnosed with trisomy 7 mosaicism. Among these fetuses, 7 had normal live births, 4 of whom were followed up for 4-54 months and were reported to be developmentally normal. In addition, trisomy 7 mosaicism was confirmed in the foreskin fibroblasts of 2 patients[7]. We found that the proportion of trisomy in the above 4 patients ranged from 5% to 48%. In this study, the first pregnant woman gave birth to a baby with trisomy 7 mosaicism (approximately 40%-45% mosaicism). Like in a previous study, we followed the baby for 1 year after birth and found no significant developmental abnormalities.

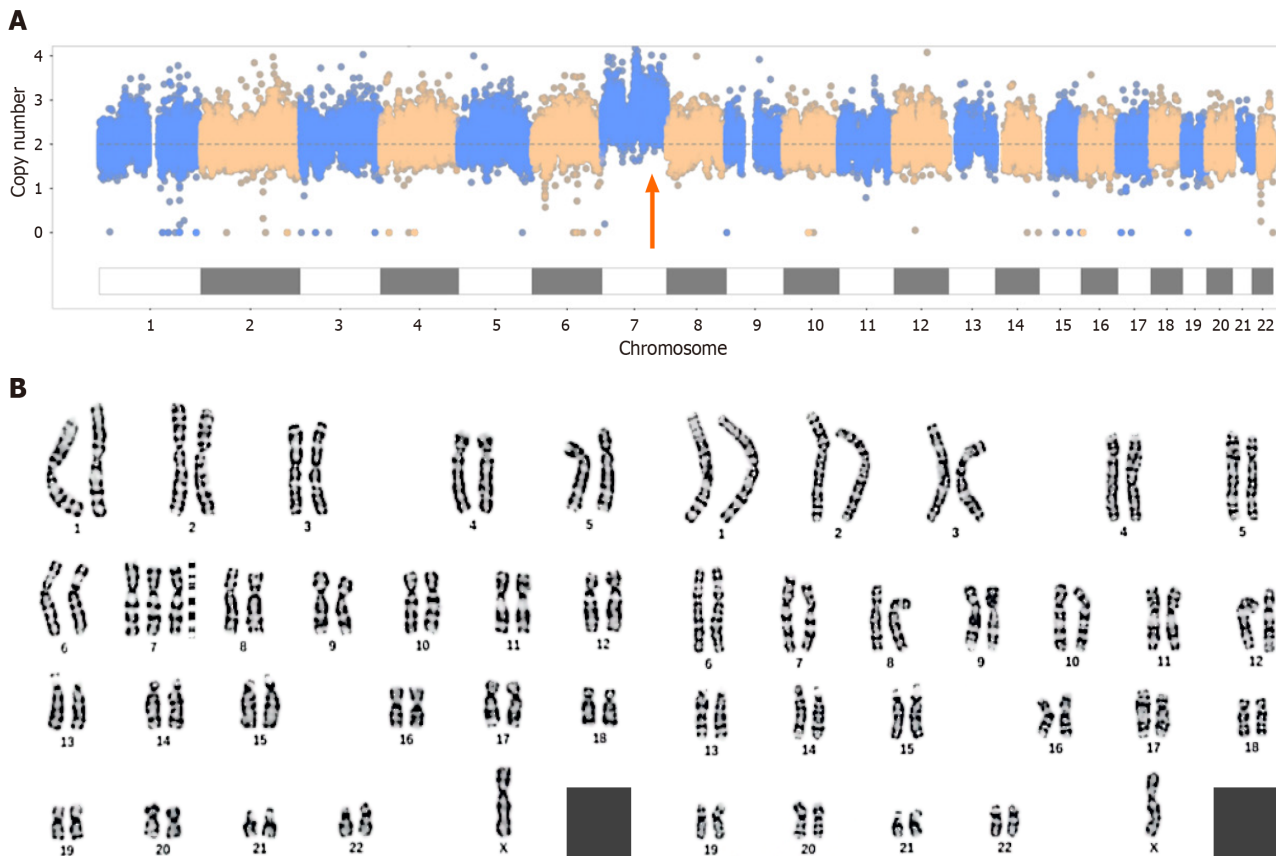


Figure 2 Prenatal diagnosis of the second fetus. A: The copy number variation sequencing results; B: The karyotype analysis results.

Human chromosome 7 is an imprinting chromosome which contains several imprinted genes related to diseases. It has been confirmed that chromosome 7 is closely related to Silver-Russell syndrome (SRS). SRS is characterized by intrauterine growth restriction and postnatal developmental delay and is mostly caused by maternal UPD[2]. The clinical phenotypes of trisomy 7 mosaicism, which have been reported thus far, are quite different. Therefore, for prenatally diagnosed cases, it is difficult to judge risk. The two trisomy 7 mosaicism cases reported in this paper had different prenatal ultrasound findings due to differences in trisomy proportions, resulting in differences in pregnancy outcomes. When conducting genetic counseling, clinicians should comprehensively evaluate fetuses and provide guidance according to specific conditions.

CONCLUSION

In trisomy 7 mosaicism, the low proportion of trisomy does not lead to abortion, but can result in abnormal fetal development, which can be detected *via* ultrasound. Therefore, clinicians need to pay more attention to various aspects of fetal growth and development, combining with imaging, cellular, molecular genetics and other methods to perform comprehensive evaluations of fetuses to provide more reliable genetic counseling for pregnant women.

ACKNOWLEDGEMENTS

We sincerely thank the participants and their families for their cooperation.

FOOTNOTES

Co-first authors: Fei Hou and Yan Li.

Author contributions: Hou F and Li Y contributed equally to this work; Hou F performed the research and wrote the manuscript; Li Y analyzed the data and wrote the manuscript; Jin H designed the research study. All authors have read and approve the final manuscript.

Informed consent statement: The patient and her legal guardian, provided informed written consent prior to study enrollment.

Conflict-of-interest statement: The authors declare that they have no conflict of interest.

CARE Checklist (2016) statement: The authors have read the CARE Checklist (2016), and the manuscript was prepared and revised according to the CARE Checklist (2016).

Open-Access: This article is an open-access article that was selected by an in-house editor and fully peer-reviewed by external reviewers. It is distributed in accordance with the Creative Commons Attribution NonCommercial (CC BY-NC 4.0) license, which permits others to distribute, remix, adapt, build upon this work non-commercially, and license their derivative works on different terms, provided the original work is properly cited and the use is non-commercial. See: <https://creativecommons.org/licenses/by-nc/4.0/>

Country/Territory of origin: China

ORCID number: Fei Hou 0000-0001-7164-9200; Yan Li 0000-0001-7991-7564; Hua Jin 0000-0001-8008-8257.

S-Editor: Zhang L

L-Editor: A

P-Editor: Zhao YQ

REFERENCES

- 1 **Zhu X**, Lam DYM, Chau MHK, Xue S, Dai P, Zhao G, Cao Y, Cheung SWH, Kwok YKY, Choy KW, Kong X, Leung TY. Clinical Significance of Non-Invasive Prenatal Screening for Trisomy 7: Cohort Study and Literature Review. *Genes (Basel)* 2020; **12** [PMID: 33374124 DOI: 10.3390/genes12010011]
- 2 **Chen CP**, Su YN, Chern SR, Hwu YM, Lin SP, Hsu CH, Tsai FJ, Wang TY, Wu PC, Lee CC, Chen YT, Chen LF, Wang W. Mosaic trisomy 7 at amniocentesis: prenatal diagnosis and molecular genetic analyses. *Taiwan J Obstet Gynecol* 2010; **49**: 333-340 [PMID: 21056320 DOI: 10.1016/S1028-4559(10)60070-8]
- 3 **Qi Y**, Yang J, Hou Y, Guo F, Peng H, Wang D, Du Q, Yin A. The significance of trisomy 7 mosaicism in noninvasive prenatal screening. *Hum Genomics* 2019; **13**: 18 [PMID: 30971315 DOI: 10.1186/s40246-019-0201-y]
- 4 **Ndah BV**, Stead JA, Brancazio LR, Hummel M, Wenger SL. Prenatal detection of trisomy for the entire long arm of chromosome 7. *J Med Genet* 2000; **37**: 551-553 [PMID: 10970193 DOI: 10.1136/jmg.37.7.551]
- 5 **Kalousek DK**, Langlois S, Robinson WP, Telenius A, Bernard L, Barrett IJ, Howard-Peebles PN, Wilson RD. Trisomy 7 CVS mosaicism: pregnancy outcome, placental and DNA analysis in 14 cases. *Am J Med Genet* 1996; **65**: 348-352 [PMID: 8923948 DOI: 10.1002/(SICI)1096-8628(19961111)65:4<348::AID-AJMG19>3.0.CO;2-U]
- 6 **Bilimoria KY**, Rothenberg JM. Prenatal diagnosis of a trisomy 7/maternal uniparental heterodisomy 7 mosaic fetus. *Am J Med Genet A* 2003; **118A**: 60-63 [PMID: 12605443 DOI: 10.1002/ajmg.a.10101]
- 7 **Hsu LY**, Yu MT, Neu RL, Van Dyke DL, Benn PA, Bradshaw CL, Shaffer LG, Higgins RR, Khodr GS, Morton CC, Wang H, Brothman AR, Chadwick D, Disteché CM, Jenkins LS, Kalousek DK, Pantzar TJ, Wyatt P. Rare trisomy mosaicism diagnosed in amniocytes, involving an autosome other than chromosomes 13, 18, 20, and 21: karyotype/phenotype correlations. *Prenat Diagn* 1997; **17**: 201-242 [PMID: 9110367 DOI: 10.1002/(sici)1097-0223(199703)17:3<201::aid-pd56>3.0.co;2-h]



Published by **Baishideng Publishing Group Inc**
7041 Koll Center Parkway, Suite 160, Pleasanton, CA 94566, USA

Telephone: +1-925-3991568

E-mail: office@baishideng.com

Help Desk: <https://www.f6publishing.com/helpdesk>

<https://www.wjgnet.com>

