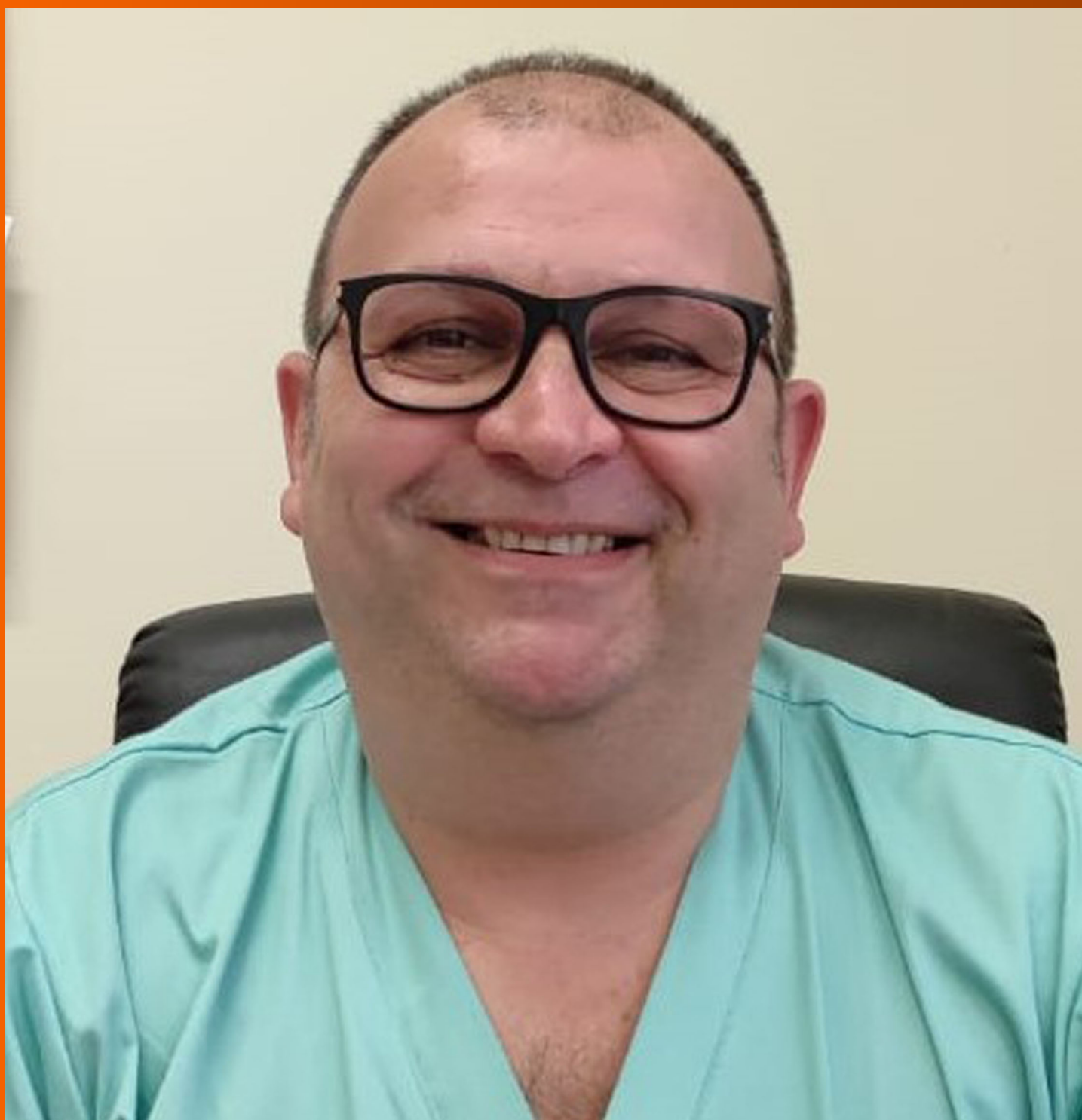

# World Journal of *Gastrointestinal Endoscopy*

*World J Gastrointest Endosc* 2022 May 16; 14(5): 250-353



### REVIEW

- 250** Percutaneous endoscopic gastrostomy and jejunostomy: Indications and techniques  
*Fugazza A, Capogreco A, Cappello A, Nicoletti R, Da Rio L, Galtieri PA, Maselli R, Carrara S, Pellegatta G, Spadaccini M, Vespa E, Colombo M, Khalaf K, Repici A, Anderloni A*
- 267** Current updates and future directions in diagnosis and management of gastroenteropancreatic neuroendocrine neoplasms  
*Canakis A, Lee LS*

### MINIREVIEWS

- 291** Endobiliary biopsy  
*Inchingolo R, Acquafredda F, Posa A, Nunes TF, Spiliopoulos S, Panzera F, Praticò CA*
- 302** Lessons learned: Preventable misses and near-misses of endoscopic procedures  
*Turshudzhyan A, Rezaizadeh H, Tadros M*

### ORIGINAL ARTICLE

#### Retrospective Study

- 311** Recognition of esophagitis in endoscopic images using transfer learning  
*Caires Silveira E, Santos Corrêa CF, Madureira Silva L, Almeida Santos B, Mattos Pretti S, Freire de Melo F*
- 320** Why is endosonography insufficient for residual diagnosis after neoadjuvant therapy for esophageal cancer? Solutions using muscle layer evaluation  
*Yonemoto S, Uesato M, Nakano A, Murakami K, Toyozumi T, Maruyama T, Suito H, Tamachi T, Kato M, Kainuma S, Matsusaka K, Matsubara H*

### CASE REPORT

- 335** Endoscopic ultrasonography drainage and debridement of an infected subcapsular hepatic hematoma: A case report  
*Doyon T, Maniere T, Désilets É*
- 342** Intraoperative endoscopic retrograde cholangiopancreatography for traumatic pancreatic ductal injuries: Two case reports  
*Canakis A, Kesar V, Hudspath C, Kim RE, Scalea TM, Darwin P*

### LETTER TO THE EDITOR

- 351** Acute upper gastrointestinal bleeding: A stitch on time saves nine  
*Gupta N, Gupta A*

**ABOUT COVER**

Editorial Board Member of *World Journal of Gastrointestinal Endoscopy*, Girolamo Geraci, MD, PhD, Associate Professor, Department of Surgical, Oncological and Oral Sciences (DiChirOnS), University Teaching Hospital AOUP "Paolo Giaccone", Palermo 90127, Italy. [girolamo.geraci@unipa.it](mailto:girolamo.geraci@unipa.it)

**AIMS AND SCOPE**

The primary aim of *World Journal of Gastrointestinal Endoscopy* (WJGE, *World J Gastrointest Endosc*) is to provide scholars and readers from various fields of gastrointestinal endoscopy with a platform to publish high-quality basic and clinical research articles and communicate their research findings online.

WJGE mainly publishes articles reporting research results and findings obtained in the field of gastrointestinal endoscopy and covering a wide range of topics including capsule endoscopy, colonoscopy, double-balloon enteroscopy, duodenoscopy, endoscopic retrograde cholangiopancreatography, endosonography, esophagoscopy, gastrointestinal endoscopy, gastroscopy, laparoscopy, natural orifice endoscopic surgery, proctoscopy, and sigmoidoscopy.

**INDEXING/ABSTRACTING**

The WJGE is now abstracted and indexed in Emerging Sources Citation Index (Web of Science), PubMed, PubMed Central, Reference Citation Analysis, China National Knowledge Infrastructure, China Science and Technology Journal Database, and Superstar Journals Database. The 2021 edition of Journal Citation Reports® cites the 2020 Journal Citation Indicator (JCI) for WJGE as 0.36.

**RESPONSIBLE EDITORS FOR THIS ISSUE**

Production Editor: Yi-Xuan Cai; Production Department Director: Xu Guo; Editorial Office Director: Jia-Ping Yan.

**NAME OF JOURNAL**

*World Journal of Gastrointestinal Endoscopy*

**ISSN**

ISSN 1948-5190 (online)

**LAUNCH DATE**

October 15, 2009

**FREQUENCY**

Monthly

**EDITORS-IN-CHIEF**

Anastasios Koulaouzidis, Bing Hu, Sang Chul Lee, Joo Young Cho

**EDITORIAL BOARD MEMBERS**

<https://www.wjgnet.com/1948-5190/editorialboard.htm>

**PUBLICATION DATE**

May 16, 2022

**COPYRIGHT**

© 2022 Baishideng Publishing Group Inc

**INSTRUCTIONS TO AUTHORS**

<https://www.wjgnet.com/bpg/gerinfo/204>

**GUIDELINES FOR ETHICS DOCUMENTS**

<https://www.wjgnet.com/bpg/GerInfo/287>

**GUIDELINES FOR NON-NATIVE SPEAKERS OF ENGLISH**

<https://www.wjgnet.com/bpg/gerinfo/240>

**PUBLICATION ETHICS**

<https://www.wjgnet.com/bpg/GerInfo/288>

**PUBLICATION MISCONDUCT**

<https://www.wjgnet.com/bpg/gerinfo/208>

**ARTICLE PROCESSING CHARGE**

<https://www.wjgnet.com/bpg/gerinfo/242>

**STEPS FOR SUBMITTING MANUSCRIPTS**

<https://www.wjgnet.com/bpg/GerInfo/239>

**ONLINE SUBMISSION**

<https://www.f6publishing.com>



## Endoscopic ultrasonography drainage and debridement of an infected subcapsular hepatic hematoma: A case report

Theo Doyon, Thibault Maniere, Étienne Désilets

**Specialty type:** Gastroenterology and hepatology

**Provenance and peer review:** Unsolicited article; Externally peer reviewed.

**Peer-review model:** Single blind

**Peer-review report's scientific quality classification**

Grade A (Excellent): 0  
Grade B (Very good): B, B, B  
Grade C (Good): C, C, C, C  
Grade D (Fair): 0  
Grade E (Poor): 0

**P-Reviewer:** Cen LS, China; Ghannam WM, Egypt; Peltec A, Moldova; Sugimoto M, Japan; Zharikov YO, Russia

**Received:** December 6, 2021

**Peer-review started:** December 6, 2021

**First decision:** January 12, 2022

**Revised:** January 25, 2022

**Accepted:** April 26, 2022

**Article in press:** April 26, 2022

**Published online:** May 16, 2022



**Theo Doyon**, Faculté de Médecine et des Sciences de la Santé, Université de Sherbrooke, Sherbrooke J1H 7N4, Québec, Canada

**Thibault Maniere, Étienne Désilets**, Department of Gastroenterology, Hopital Charles-Lemoyne, Greenfield Park J4V 2H1, Québec, Canada

**Corresponding author:** Theo Doyon, Faculté de Médecine et des Sciences de la Santé, Université de Sherbrooke, 3001 12e avenue Nord, Sherbrooke J1H 7N4, Québec, Canada.  
[theo.doyon@usherbrooke.ca](mailto:theo.doyon@usherbrooke.ca)

### Abstract

#### BACKGROUND

Endoscopic ultrasonography (EUS) has evolved in the last years making it not only a diagnostic modality but a therapeutic procedure. EUS is now used as an alternative technique to percutaneous and surgical drainage. Even though EUS is a challenging procedure and not always suitable compared to percutaneous drainage, there is a need for developing new therapeutic approaches to the liver for when percutaneous drainage is not feasible.

#### CASE SUMMARY

We present the case of a 82 years old male who developed an infected subcapsular hepatic hematoma (SHH) of the left lobe following percutaneous biliary drainage. After 2 failed attempts of percutaneous drainage of the SHH and because the patients couldn't withstand surgery, we conducted a EUS drainage and debridement of the SHH. Using a lumen apposing metal stent (LAMS) by a transgastric approach, we were able to gain endoscopic access to the SHH. With our experience in the debridement of walled off pancreatic necrosis using this technique, we were confident it was the right approach. After four debridement sessions, the computed tomography scan showed a clear regression of the SHH.

#### CONCLUSION

To our knowledge, this is the first case of successful endoscopic debridement of a SHH using a LAMS which appear to be feasible and safe in this specific case.

**Key Words:** Intervention endoscopic ultrasonography; Complication; Hepatic subcapsular hematoma; Transmural drainage; Lumen apposing metal stent; Case report

©The Author(s) 2022. Published by Baishideng Publishing Group Inc. All rights reserved.

**Core Tip:** We conducted an endoscopic ultrasonography drainage and debridement of a subcapsular hepatic hematoma (SHH). Using a lumen apposing metal stent (LAMS) with a transgastric approach, we were able to gain endoscopic access to the SHH. With our experience in the debridement of walled off pancreatic necrosis using this technique, we were confident it was the right approach. After four sessions of debridement, the computed tomography scan showed a clear regression of the SHH. To our knowledge, this is the first case of successful endoscopic debridement of a SHH using a LAMS which appear to be feasible and safe in this specific case.

**Citation:** Doyon T, Maniere T, Désilets É. Endoscopic ultrasonography drainage and debridement of an infected subcapsular hepatic hematoma: A case report. *World J Gastrointest Endosc* 2022; 14(5): 335-341

**URL:** <https://www.wjgnet.com/1948-5190/full/v14/i5/335.htm>

**DOI:** <https://dx.doi.org/10.4253/wjge.v14.i5.335>

## INTRODUCTION

Endoscopic ultrasonography (EUS) has evolved making it more and more a therapeutic procedure[1-3]. For instance, it is now used for drainage of abscesses or hematomas when the first line of treatment that is percutaneous drainage is not feasible or has failed[1,4-7] or for gallbladder drainage for cases of refractory acute cholecystitis in the elderly who can't withstand surgery[8]. EUS is now used as an alternative technique to surgical drainage which is highly invasive, making EUS more favorable in term of procedural complications[1]. Percutaneous drainage, despite its high success rate also has its complications: Bleeding, perforation, peritonitis, fistula, sepsis and hematomas like subcapsular hepatic hematoma (SHH)[4,5,9]. Even though EUS is a challenging procedure and not always suitable compared to percutaneous drainage[5], there is a need for developing new therapeutic approaches to the liver when percutaneous drainage is not feasible[5] thus preventing the use of surgical drainage and its potential complications[1]. SHH can be a life-threatening situation[9-13]. SHH are traditionally managed conservatively with antibiotics and pain management[4,11,12,14]. However, when the SHH is persistent, becomes infected or worsens, it can be treated by percutaneous drainage and in case of failure by surgical drainage[4,5,13].

In walled off pancreatic necrosis (WOPN), debridement of the necrosis can be done surgically or by EUS which is less at risk of complications compared to conventional surgery[3,15,16]. The usual procedure for the drainage and debridement of WOPN is a puncture of the collection under EUS and dilation of the track using a cystotome or a balloon[15,16]. Endoscopic drainage of WOPN is then assured by the placement of multiple double pigtail stents or by installing a lumen apposing metal stent (LAMS) under EUS and use the stent as an access to get inside the necrosis for debridement of the WOPN[15]. Knowing that surgical drainage of SHH is an invasive and risky procedure, that the site of the hematoma can make percutaneous drainage difficult[1,4,5], that EUS drainage of a liver abscess is an effective and successful method to drain difficult to access abscess using a transgastric or transduodenal approach[4,5,7] and that EUS is used in debridement of WOPN[15,16]; we hypothesized that debridement of a SHH using EUS could be successful.

## CASE PRESENTATION

### Chief complaints

We report the case of a 82 years old male, known for a pancreatic cystic lesion under punctual surveillance by EUS.

### History of present illness

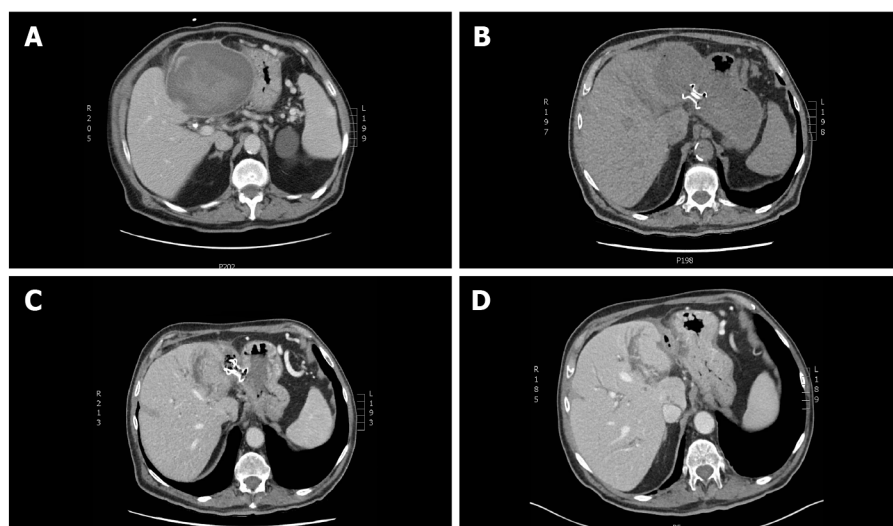
The patient has a pancreatic cystic lesion under punctual surveillance by EUS.

### History of past illness

The history of past illness are chronic kidney failure, hypertension, type 2 diabetes, dyslipidemia and coronary artery disease for which he took medication.

### Personal and family history

None personal or family history.



DOI: 10.4253/wjge.v14.i5.335 Copyright ©The Author(s) 2022.

**Figure 1** Computed tomography scan of the upper abdomen showing the left subcapsular hepatic hematoma at different stages of endoscopic treatment. A: At diagnosis, the subcapsular hepatic hematoma (SHH) size was 12.5 cm × 10.5 cm × 12.5 cm and was compressing the stomach; B: At day 1 after endoscopic ultrasonography and lumen apposing metal stent (LAMS) was installed by transgastric approach; C: A month later, a control computed tomography (CT) scan of the upper abdomen showed a resorption of the SHH after 4 debridement sessions; D: Control CT scan of the upper abdomen after the LAMS was removed endoscopically.

### Physical examination

During a routine monitoring of the pancreatic cystic lesion, EUS revealed a focal dilatation of the left intrahepatic bile duct.

### Laboratory examinations

His laboratory tests showed white blood cells at  $10.9 \times 10^9/L$ , hemoglobin at 109 g/L, bilirubin at 23  $\mu\text{mol/L}$ , alkaline phosphatase 231 U/L, aspartate aminotransferase 70 U/L, alanine aminotransferase 134 U/L and CA199 at 315 kU/L. Hours after the percutaneous drainage, the patient developed right upper quadrant pain and the hemoglobin level went down to 62 g/L.

### Imaging examinations

Sequential endoscopic retrograde cholangiopancreatography was performed with cytology brushing and dilatation of a left intrahepatic biliary stricture followed by deployment of a 15 cm 8.5 Fr plastic stent in that area. A percutaneous drain in the left intrahepatic bile duct was then added in radiology.

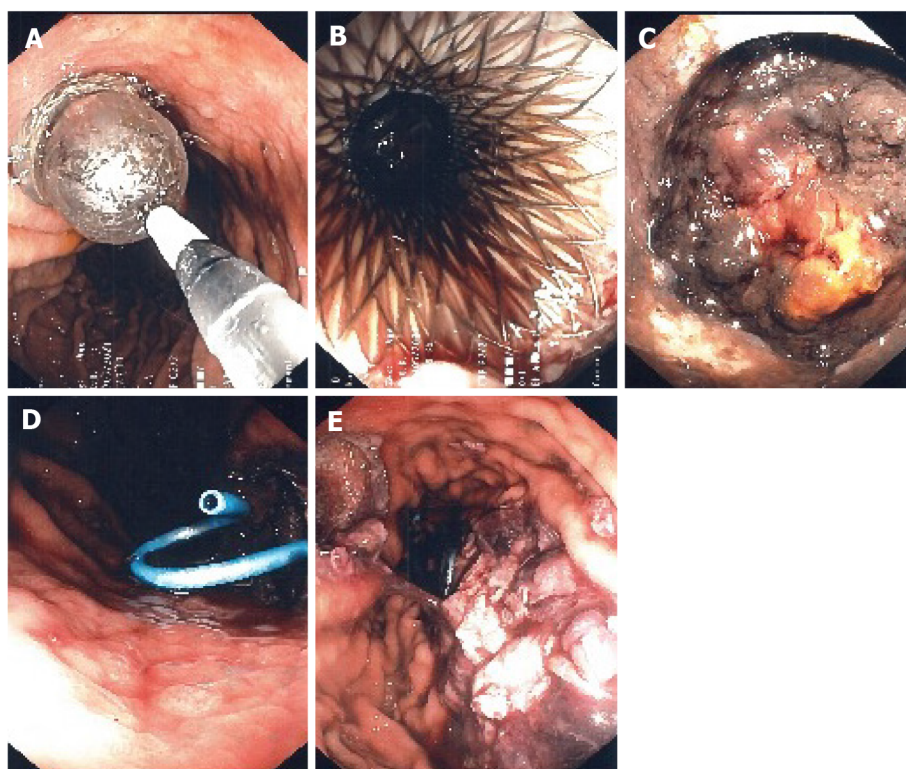
## FINAL DIAGNOSIS

The patient developed cholangitis.

## TREATMENT

A control computed tomography (CT) scan revealed a 12.5 cm × 10.5 cm × 12.5 cm hypodense lesion compatible with a SHH in the left lobe (segment 3) (Figure 1). The patient was sent back in radiology and there was no active bleeding or pseudoaneurysm during the arteriography. Over the next days the patient developed a fever. A percutaneous 10 Fr catheter was inserted in the hematoma to attempt drainage and was repositioned once. Only a modest amount of bloody fluid was collected (150 mL). After a month of conservative treatment and a failed attempt to wean the patient from antibiotics, a control CT scan showed an expansion of the SHH with air bubbles within. Percutaneous drainage was again performed in radiology using a multiperforated 10 Fr stent and drained 100 cc of bloody liquid. Control CT showed a slow regression of the SHH and a thick wall around it.

Seeing the slow rate of resorption of the infected SHH, a consultation in hepatobiliary surgery was obtained but the patient was deemed too sick to withstand surgery. After consent from the patient, we decided to perform a EUS drainage of the infected SHH with a 10 mm × 15 mm LAMS (Hot-Axios, Boston scientific) by a transgastric approach under conscious sedation. The collection appeared heterogenous, surrounded by a thick wall and very close to the stomach smaller curvature. Considering the



DOI: 10.4253/wjge.v14.i5.335 Copyright ©The Author(s) 2022.

**Figure 2** Endoscopic ultrasonography guided transgastric insertion of fully covered 10 mm × 15 mm lumen apposing metal stent allows endoscopic access to the subcapsular hepatic hematoma for drainage and debriement. A: Dilatation of the lumen apposing metal stent (LAMS) was needed for the first debriement; B: Endoscopic image showing the LAMS after dilatation during the first of four debriements; C: Endoscopic image showing the subcapsular hepatic hematoma (SHH) during the second debriement; D: After each debriement, a double pigtail stent was inserted into the lumen of the LAMS allowing a more complete drainage of the SHH; E: Endoscopic image showing debris of the hematoma inside the stomach after the last debriement.

location of the SHH, the puncture was easy, and deployment of the LAMS was done using the standard Seldinger technique. Pus and blood were drained from the hematoma into the stomach immediately after deployment. After the procedure, the patient recovered well, with no adverse event. The two percutaneous drains were removed. The following day, the first of four debriement sessions under conscious sedation were performed with a standard gastroscope through the LAMS (Figure 2). Dilatation of the LAMS at 18 mm was needed at the first debriement. Each debriement session lasted between 30-35 min. Informed consent was obtained before each session. At the end of each debriement, a double-sided pigtail 7 Fr drain was installed inside the LAMS stent to help drain the SHH and maintain position and patency.

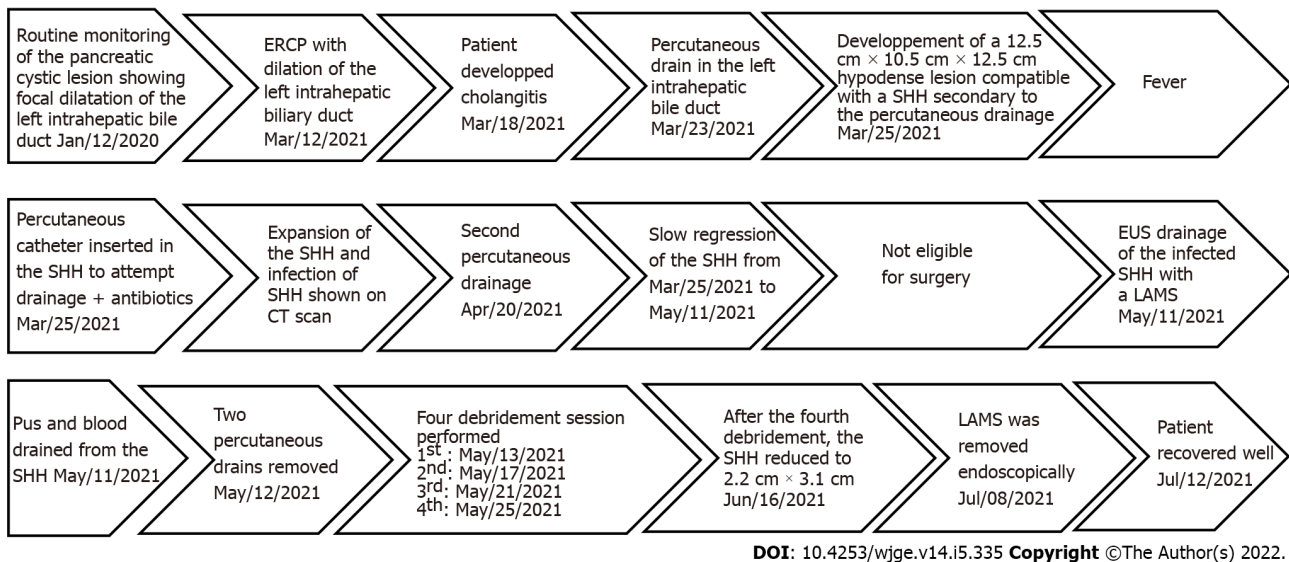
## OUTCOME AND FOLLOW-UP

After the fourth debriement, the endoscopic appearance of the SHH cavity was clean with whitish walls and a CT scan revealed a massive regression of the SHH (2.2 cm × 3.1 cm); showing that the EUS procedure was a success. The LAMS was then removed endoscopically and the fistula between the stomach and the SHH closed immediately. The patient recovered well (Figure 3).

## DISCUSSION

SHH is an “accumulation of blood between the Glisson’s capsule and the liver parenchyma; rupture into the peritoneum has a 75% mortality rate” [10] which makes it life threatening [11]. In this case, the SHH was present for more than 3 mo, giving it time to organize itself and coagulate making it refractory to percutaneous drainage. Moreover, the SHH was infected, and the patient was under antibiotics for 6 wk without any success. Finally, the patient couldn’t withstand surgery, so we had no choice but to try EUS drainage as a therapeutic procedure.

Important factors helped us choose this approach: The patient didn’t have any coagulopathy; the encapsulated look and thick walls of the SHH; the anatomy of this region and the proximity of the SHH,



**Figure 3 Timeline of the medical care episode.** CT: Computed tomography; SHH: Subcapsular hepatic hematoma; ERCP: Endoscopic retrograde cholangiopancreatography; EUS: Endoscopic ultrasonography; LAMS: Lumen apposing metal stent.

in segment 3 of the liver, with the small curvature of the stomach; the absence of pseudoaneurysm or active bleeding on the arteriogram and our experience in the debridement of WOPN. Altogether, it made us confident that EUS drainage and debridement under conscious sedation was the right approach. This way we were able to use a known and proven technique to a novel situation (*i.e.*, SHH). The procedure was a success, since after drainage and debridement, there was a significant reduction in the volume of the SHH (Figure 1).

This makes it the first EUS drainage and debridement of a SHH to our knowledge in the medical literature. We warn that this technique may be used only in cases where the collection is near the gastric or duodenal wall and when there is an experienced endoscopist who has competence in therapeutic EUS. The use of a naso-cystic tube to improve irrigation and shorten the resolution of SHH is debatable. Those tube are used also for common bile duct infection but are not well tolerated by patients. We decided to keep the LAMS in place for 2 mo to maintain the fistula wide open and make the access to the SHH easier. We removed it after the fourth debridement when the SHH was resolved. It is usually advised to remove those stents after 4–6 wk to avoid potential bleeding due to mucosal erosion[17].

There are many risks associated with the procedure. Aside from the general risks related to endoscopic anesthesia (respiratory failure, aspiration), the specific risk are bile leak, bleeding, infection, perforation, peritonitis and death. To assess and minimize the bleeding risk, doppler was used before the first endoscopic access to avoid any vascular structure in the gastric wall. The SHH was scanned with multiphasic acquisitions to rule out the presence of a pseudoaneurysm. If significant bleeding was to happen, we would have referred to angiography and arterial embolization. For peritonitis, the decision to send the patient to the operating room to proceed with conservative management would have been based on the severity and extent on imaging studies.

Furthermore, since the access to the SHH was in the smaller curvature, there was a potential risk of reflux of digestive flora into the SHH. This is a potential risk of all trans-gastric drainage techniques for which the consequences are unknown to our knowledge. Some have stated that it could be beneficial in the way that stomach acidity can provide a kind of chemical debridement [some even stop proton pump inhibitors (PPIs) between sessions of pancreatic necrosis debridement][18]; others fear potential supra-infection from the digestive flora and food reflux from the digestive lumen[19]. In our case, the patient remained on large spectrum IV antibiotics from the first to the last endoscopic intervention to prevent supra-infection. PPIs were maintained.

We did not study the cost effectiveness of this approach compared to surgery. This is certainly an interesting question. Surgery remains for us the gold standard for refractory SHH; we proceeded this way because the risk of surgery was too high in our case. In the future, we think that EUS should be considered along the other modalities (surgery and radiological drainage) for the treatment of all kinds of peri-digestive infections (pseudocyst, pancreatic necrosis, liver and perihepatic abscesses, acute cholecystitis). The choice of the best modality should be based on available scientific data, specific risks for the patient, local expertise, and availability of the technology.

There are many potential advantages to the use of EUS: It is less invasive than surgery, there is no need for a transcutaneous tube or collecting bag, it can be a permanent drainage (*ex*: For gallbladders and pseudocyst) and larger stents allow for potential endoscopic debridement if needed. However, the lack of availability and expertise and the cost of material and technology make using EUS as a

therapeutical option challenging.

## CONCLUSION

To our knowledge, this is the first case of successful endoscopic debridement of a SHH using a LAMS which appear to be feasible and safe in this specific case. Thus, EUS drainage of an infected SHH seems like an alternative therapeutic approach to consider, but clinical indications remain to be defined. More experience from other centers around the world will be needed before applying this treatment in a widespread fashion.

## FOOTNOTES

**Author contributions:** Doyon T, Manière T and Désilets E contributed equally to this work.

**Informed consent statement:** The patient signed an informed written consent form for all the information that is found in this case report, and for all the procedures he went through.

**Conflict-of-interest statement:** All authors disclosed no financial relationships relevant to this publication.

**CARE Checklist (2016) statement:** This case report was written according to the CARE Checklist (2016).

**Open-Access:** This article is an open-access article that was selected by an in-house editor and fully peer-reviewed by external reviewers. It is distributed in accordance with the Creative Commons Attribution NonCommercial (CC BY-NC 4.0) license, which permits others to distribute, remix, adapt, build upon this work non-commercially, and license their derivative works on different terms, provided the original work is properly cited and the use is non-commercial. See: <https://creativecommons.org/licenses/by-nc/4.0/>

**Country/Territory of origin:** Canada

**ORCID number:** Theo Doyon 0000-0003-1950-456X; Thibault Maniere 0000-0002-8229-8888; Étienne Désilets 0000-0002-0960-3946.

**S-Editor:** Wang JJ

**L-Editor:** A

**P-Editor:** Wang JJ

## REFERENCES

- 1 Morita S, Kamimura K, Suda T, Oda C, Hoshi T, Kanefuji T, Yagi K, Terai S. Endoscopic ultrasound-guided transmural drainage for subphrenic abscess: report of two cases and a literature review. *BMC Gastroenterol* 2018; **18**: 55 [PMID: 29699494 DOI: 10.1186/s12876-018-0782-2]
- 2 Campos S, Poley JW, van Driel L, Bruno MJ. The role of EUS in diagnosis and treatment of liver disorders. *Endosc Int Open* 2019; **7**: E1262-E1275 [PMID: 31579708 DOI: 10.1055/a-0958-2183]
- 3 Braden B, Gupta V, Dietrich CF. Therapeutic EUS: New tools, new devices, new applications. *Endosc Ultrasound* 2019; **8**: 370-381 [PMID: 31417067 DOI: 10.4103/eus.eus\_39\_19]
- 4 Chin YK, Asokkumar R. Endoscopic ultrasound-guided drainage of difficult-to-access liver abscesses. *SAGE Open Med* 2020; **8**: 2050312120921273 [PMID: 32435490 DOI: 10.1177/2050312120921273]
- 5 Singhal S, Changela K, Lane D, Anand S, Duddempudi S. Endoscopic ultrasound-guided hepatic and perihepatic abscess drainage: an evolving technique. *Therap Adv Gastroenterol* 2014; **7**: 93-98 [PMID: 24587822 DOI: 10.1177/1756283X13506178]
- 6 Fei BY, Li CH. Subcapsular hepatic haematoma after endoscopic retrograde cholangiopancreatography: an unusual case. *World J Gastroenterol* 2013; **19**: 1502-1504 [PMID: 23538782 DOI: 10.3748/wjg.v19.i9.1502]
- 7 Carvajal JJ, Betancur Salazar K, Mosquera-Klinger G. Transgastric drainage of a liver abscess through endoscopic ultrasound in a patient with multiple organ failure. *Rev Gastroenterol Mex (Engl Ed)* 2021; **86**: 94-96 [PMID: 32115290 DOI: 10.1016/j.rgmx.2019.12.002]
- 8 Quencer KB, Tadros AS, Marashi KB, Cizman Z, Reiner E, O'Hara R, Oklu R. Bleeding after Percutaneous Transhepatic Biliary Drainage: Incidence, Causes and Treatments. *J Clin Med* 2018; **7** [PMID: 29723964 DOI: 10.3390/jcm7050094]
- 9 Small AJ, Irani S. Endoscopic ultrasound gallbladder drainage: Patient selection, preparation, and performance. *Techniques Gastrointest Endosc* 2017; **19**: 230234 [DOI: 10.1016/j.tgie.2017.10.002]
- 10 Ndzenge A, Hammoudeh F, Brutus P, Ajah O, Purcell R, Leadon J, Rafal RB, Balmir S, Enriquez DA, Posner GL, Jaffe EA, Chandra P. An obscure case of hepatic subcapsular hematoma. *Case Rep Gastroenterol* 2011; **5**: 223-226 [PMID: 21552450 DOI: 10.1159/000326998]

- 11 **Zappa MA**, Aiolfi A, Antonini I, Musolino CD, Porta A. Subcapsular hepatic haematoma of the right lobe following endoscopic retrograde cholangiopancreatography: Case report and literature review. *World J Gastroenterol* 2016; **22**: 4411-4415 [PMID: 27158211 DOI: 10.3748/wjg.v22.i17.4411]
- 12 **García Tamez A**, López Cossio JA, Hernández Hernández G, González Huevo MS, Rosales Solís AA, Corona Esquivel E. Subcapsular hepatic hematoma: An unusual, but potentially life-threatening post-ERCP complication. Case report and literature review. *Endoscopia* 2016; **28**: 75-80 [DOI: 10.1016/j.endomx.2016.04.001]
- 13 **Corazza LR**, D'Ambrosio L, D'Ascoli B, Dileonzo MF. Subcapsular Hepatic Hematoma. Is it still an unusual Complication Post ERC? *Gastroenterol Hepatol Open Access* 2017; **6**: 149-152 [DOI: 10.15406/ghoa.2017.06.00211]
- 14 **Brown V**, Martin J, Magee D. A rare case of subcapsular liver haematoma following laparoscopic cholecystectomy. *BMJ Case Rep* 2015; **2015** [PMID: 26113588 DOI: 10.1136/bcr-2015-209800]
- 15 **Jha AK**, Goenka MK, Kumar R, Suchismita A. Endotherapy for pancreatic necrosis: An update. *JGH Open* 2019; **3**: 80-88 [PMID: 30834345 DOI: 10.1002/jgh3.12109]
- 16 **Jagielski M**, Smoczyński M, Adrych K. The role of endoscopic ultrasonography in transmural drainage/debridement of walled-off pancreatic necrosis. *Prz Gastroenterol* 2018; **13**: 160-162 [PMID: 30002777 DOI: 10.5114/pg.2018.72608]
- 17 **Ahmad W**, Fehmi SA, Savides TJ, Anand G, Chang MA, Kwong WT. Protocol of early lumen apposing metal stent removal for pseudocysts and walled off necrosis avoids bleeding complications. *Scand J Gastroenterol* 2020; **55**: 242-247 [PMID: 31942808 DOI: 10.1080/00365521.2019.1710246]
- 18 **Thompson CC**, Kumar N, Slattery J, Clancy TE, Ryan MB, Ryou M, Swanson RS, Banks PA, Conwell DL. A standardized method for endoscopic necrosectomy improves complication and mortality rates. *Pancreatol* 2016; **16**: 66-72 [PMID: 26748428 DOI: 10.1016/j.pan.2015.12.001]
- 19 **Kim JJ**, Hiotis SP, Sur MD. Gastric Reflux Into the Gallbladder After EUS-guided Stenting-Letter to the Editor Regarding "EUS-guided Versus Percutaneous Gallbladder Drainage: Isn't It Time to Convert? *J Clin Gastroenterol* 2019; **53**: 392-393 [PMID: 28697146 DOI: 10.1097/MCG.0000000000000890]



Published by **Baishideng Publishing Group Inc**  
7041 Koll Center Parkway, Suite 160, Pleasanton, CA 94566, USA

**Telephone:** +1-925-3991568

**E-mail:** [bpgoffice@wjgnet.com](mailto:bpgoffice@wjgnet.com)

**Help Desk:** <https://www.f6publishing.com/helpdesk>

<https://www.wjgnet.com>

