

[\(PDF\) Congenital Lacrimal Sac Fistula: A Case Report and ...](#)
<https://www.researchgate.net/publication/338293945...>

We report a case of congenital lacrimal sac fistula located on the temporal side of the lateral canthus. A systemically healthy 1-year-old girl came to the outpatient clinic with a complaint of ...
Estimated Reading Time: 4 mins

Search Tools

Turn off Hover Translation (关闭取词)

[Infantile Dural Arteriovenous Fistula of the Transverse ...](#)
<https://www.ncbi.nlm.nih.gov/pmc/articles/PMC4877555>

May 10, 2016 · Imaging study of case 1 before and after embolization showing direct fistula with the transverse sinus. A : Lateral view of the left vertebral artery showing vertebral dural branches supplying...
Cited by: 1 Author: Ahmed Elsayed Sultan, Tamer Hassan
Publish Year: 2016

[Intracranial pial arteriovenous fistula in infancy: a case ...](#)
<https://link.springer.com/content/pdf/10.1007/s00381-013-2217-2.pdf> ▾

Report of three cases and review of the literature. J Neurosurg 100:201–205. PubMed Article Google Scholar 24. Weon YC, Yoshida Y, Sachet M, Mahadevan J, Alvarez H, Rodesch G, Lasjaunias P (2005)...
Cited by: 16 Author: U. M. Kraneburg, V. D. W. Nga, E. Y. S. Ting, ...
Publish Year: 2014

[Anal duplication: is surgery indicated? A report of three ...](#)
<https://pubmed.ncbi.nlm.nih.gov/31256296>

Aim of the study: Anal canal duplications (ACDs) are extremely rare with only approximately 90 cases described in the literature. We report on three additional patients. Methods: Cases were analyzed to...
Cited by: 1 Author: A C Trecartin, A Peña, M Lovell, J Bruny, C ...
Publish Year: 2019

[Three case reports: Temporal association between tyrosine ...](#)
<https://journals.lww.com/md-journal/Fulltext/2019/...>

How to cite this article: Carretero-González A, Santamaría JS, Castellano D, de Velasco G. Three case reports: Temporal association between tyrosine-kinase inhibitor-induced hepatitis and immune...

[Pediatric pial arteriovenous fistula located at the bottom ...](#)
<https://link.springer.com/article/10.1007/s00381-020-04635-1> ▾

Apr 28, 2020 · A pial arteriovenous fistula (pAVF) is a rare condition characterized by a direct connection between a cerebral artery and cerebral vein without an intervening nidus. The prognosis is poor in...

ALL

IMAGES

VIDEOS

271,000 Results

Any time ▾

[Anal duplication: is surgery indicated? A report of three ...](https://pubmed.ncbi.nlm.nih.gov/31256296)

<https://pubmed.ncbi.nlm.nih.gov/31256296>

Aim of the study: Anal canal duplications (ACDs) are extremely rare with only approximately 90 cases described in the literature. We report on three additional patients. Methods: Cases were analyzed to evaluate presenting symptoms, physical exam and MRI findings. A comprehensive literature review was performed to compare our patients to previously described cases.

Cited by: 3

Author: A C Trecartin, A Peña, M Lovell, J Bruny, C ...

Publish Year: 2019

[Intracranial pial arteriovenous fistula in infancy: a case ...](https://link.springer.com/article/10.1007/s00381-013-2217-2)

<https://link.springer.com/article/10.1007/s00381-013-2217-2> ▾

Jul 02, 2013 · Report of three cases and review of the literature. J Neurosurg 100:201–205. PubMed Article Google Scholar 24. Weon YC, Yoshida Y, Sachet M, Mahadevan J, Alvarez H, Rodesch G, Lasjaunias P (2005) Supratentorial cerebral arteriovenous fistulas (AVFs) in children: review of 41 cases with 63 non choroidal single-hole AVFs.

Cited by: 17

Author: U. M. Kraneburg, V. D. W. Nga, E. Y. S. Ting, ...

Publish Year: 2014

[Perilymphatic Fistula After Penetrating Ear Trauma - The ...](https://westjem.com/case-report/perilymphatic...)

<https://westjem.com/case-report/perilymphatic...> ▾**Introduction**

Case Report

Discussion

Conclusion

References

Perilymphatic fistula (PLF) refers to an abnormal communication of perilymph between the middle and inner ear through a defect in the otic capsule, and is associated with acute hearing loss, tinnitus, and vertigo. Some of the more common causes of PLF include penetrating injury (such as that of ear picks in Japan), barotrauma, middle ear surgery, and temporal bone fracture.^{1,2} Many reported cases of traumatic PLF deal with concurrent management of temporal bone fractures, in which case conservativ...

See more on westjem.com

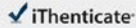
Estimated Reading Time: 11 mins

[Intracranial Pial Arteriovenous Fistulae: Diagnosis and](#)

21-Mar-2021 06:02:42

7236 words • 11 matches • 15 sources

FAU

 iThenticate

64801_Auto_Edited -IT check.docx

Quoted Excluded
Bibliography Excluded
0%
3048/345

Name of Journal: *World Journal of Clinical Cases*

Manuscript NO: 64801

Manuscript Type: CASE REPORT



Pediatric temporal fistula: three cases report and a literature review

Gu *et al.* Pediatric temporal fistula




MEIZHEN GU, HONGMING XU, FANG CHEN, WEIWEI XIA, Xiao-Yan Li

Match Overview

There are no matching sources for this report.

PAGE: 1 OF 13

Text-Only Report

国内版

国际版

Pediatric temporal fistula: Three case reports



ALL IMAGES VIDEOS

1,130,000 Results

Any time ▾

[PDF] Case Reports - Indian Pediatrics

<https://www.indianpediatrics.net/nov2004/1152.pdf>

congenital CSF fistula in 55% of cases, traumatic or surgical CSF fistula in 17%, immunodeficiency in 21% and unknown cause in 6%(3). Drummond, et al. (4) reported 6 (1.3%) children with recurrent meningitis over an 11-year period after reviewing 463 cases of meningitis. Of these, two were diagnosed with temporal anatomical

Treatment of a cerebral pial arteriovenous fistula in a ...

<https://pubmed.ncbi.nlm.nih.gov/26053963>

Treatment of a cerebral pial arteriovenous fistula in a patient with sickle cell disease-related moyamoya syndrome: case report J Neurosurg Pediatr . 2015 Aug;16(2):207-11. doi: 10.3171/2014.12.PEDS14486.

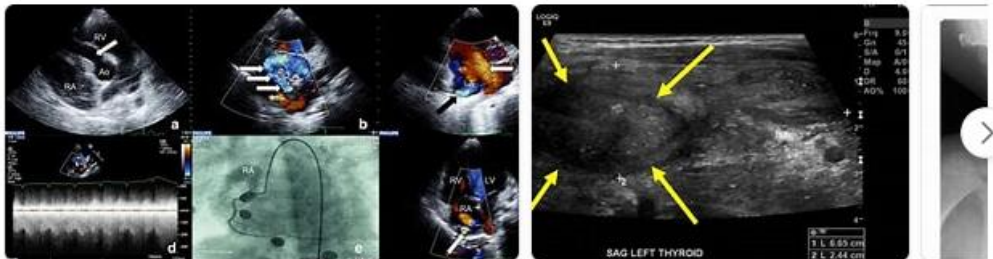
Cited by: 4

Author: Anna Lo Presti, Alexander G. Weil, Aria ...

Publish Year: 2015

Images of Pediatric temporal fistula Three case Reports

bing.com/images



See all images >

Pediatric esophagopleural fistula: Two case reports and a ...

<https://www.ncbi.nlm.nih.gov/pubmed/28489746>

Pediatric esophagopleural fistula: Two case reports and a literature review. Cui Y(1), Ren Y, Shan Y, Chen D, Wang F, Zhu Y, Zhu Y, Author information: (1)Department of Critical Care Medicine, Shanghai ...