

Acute kidney injury associated with consumption of starfruit juice: A case report

Thajudeen Mohammed Zuhary, R Ponampalam

Specialty type: Toxicology

Provenance and peer review:

Invited article; Externally peer reviewed.

Peer-review model: Single blind

Peer-review report's scientific quality classification

Grade A (Excellent): 0
Grade B (Very good): 0
Grade C (Good): C, C
Grade D (Fair): 0
Grade E (Poor): 0

P-Reviewer: Chen BH, Taiwan; Tu GW, China

Received: January 6, 2022

Peer-review started: January 6, 2022

First decision: March 24, 2022

Revised: May 6, 2022

Accepted: July 18, 2022

Article in press: July 18, 2022

Published online: September 9, 2022



Thajudeen Mohammed Zuhary, R Ponampalam, Department of Emergency Medicine, Singapore General Hospital, Singapore 169608, Singapore

Corresponding author: Thajudeen Mohammed Zuhary, MBBS, Doctor, Department of Emergency Medicine, Singapore General Hospital, Outram Road, Singapore 169608, Singapore. thajudeen.mohd.zuhary@sgh.com.sg

Abstract

BACKGROUND

This study aims to highlight the potential serious complications of acute kidney injury (AKI) resulting from the consumption of excessive amounts of starfruit, a common traditional remedy.

CASE SUMMARY

A 78-year-old male with a past medical history of hypertension, diabetes mellitus and hyperlipidemia without prior nephropathy presented to the emergency department (ED) with hiccups, nausea, vomiting and generalized weakness. In the preceding 1 wk, he had consumed 3 bottles of concentrated juice self-prepared from 1 kg of small sour starfruits. His serum creatinine was noted to be 1101 µmol/L from baseline normal prior to his ED visit. He was diagnosed with AKI secondary to excessive starfruit consumption.

CONCLUSION

Consumption of starfruit can cause acute renal failure, with a good outcome when promptly identified and treated.

Key Words: Acute kidney injury; Acute renal failure; Starfruit; Hemodialysis; Case report

©The Author(s) 2022. Published by Baishideng Publishing Group Inc. All rights reserved.

Core Tip: Physicians should have a high index of suspicion on possible interactions and toxicities that may occur with the use of traditional medications in combination with prescription drugs in susceptible patients. This report highlights the toxicity of starfruit when consumed as a traditional remedy for diabetes mellitus resulting in acute kidney injury.

Citation: Zuhary TM, Ponampalam R. Acute kidney injury associated with consumption of starfruit juice: A case report. *World J Crit Care Med* 2022; 11(5): 330-334

URL: <https://www.wjgnet.com/2220-3141/full/v11/i5/330.htm>

DOI: <https://dx.doi.org/10.5492/wjccm.v11.i5.330>

INTRODUCTION

The starfruit (*Averrhoa carambola*) is a popular fruit in tropical countries due to its nutritional and medicinal benefits[1], and is used to treat various ailments such as diabetes mellitus, rheumatism, and cough. The starfruit is used as a traditional remedy in Asian countries such as Malaysia and Indonesia to treat diabetes mellitus due to its hypoglycemic properties[2]. Despite its frequent consumption, many people are unaware of the dangers of overindulging in starfruit. When consumed in large quantities, the fruit contains high levels of oxalic acid, which can be nephrotoxic. Starfruit-induced neurotoxicity and nephrotoxicity, which manifests as acute kidney injury (AKI) in individuals with underlying renal dysfunction, is well documented[3,4]. AKI in individuals with normal renal function is rare. We present a case report of AKI following the consumption of starfruit.

CASE PRESENTATION

Chief complaints

A 78-year-old male presented to the emergency department (ED) with hiccups, nausea, vomiting and generalized weakness.

History of present illness

In the preceding week, he had consumed 3 bottles of concentrated juice which were self-prepared from 1 kg of starfruits. Following ingestion of the third bottle of the fruit juice, he developed bouts of severe nausea and vomiting without abdominal pain or diarrhea.

History of past illness

He had a past medical history of hypertension, diabetes mellitus and hyperlipidemia.

Personal and family history

No significant family history.

Physical examination

On arrival at the ED, his vital signs were stable (temperature was 36.8°C, pulse rate 60 bpm, respiratory rate 18 breaths/min, and blood pressure 161/78 mmHg) and there was no pitting edema. Examinations of his cardiovascular, respiratory, abdominal and neurological systems were normal.

Laboratory examinations

Laboratory examination results are shown in [Figure 1](#) and [Table 1](#).

Imaging examinations

No imaging was undertaken.

MULTIDISCIPLINARY EXPERT CONSULTATION

The patient was initially seen in the ED and admitted under renal medicine for specialized care.

FINAL DIAGNOSIS

Acute kidney injury.

TREATMENT

The patient was treated with 4 sessions of hemodialysis and supportive care such as intravenous fluid. After each session

Table 1 Trend in patient's blood investigations

	Day 1	Day 2	Day 3	Day 4	Day 5	Day 7	Day 13	Day 17	Day 24	Day 60	Day 135
Renal function											
Serum creatinine (μmol/L)	1101		680	659	495	340	328	208	177	127	99
Serum urea (mmol/L)	38.1		23.1	27.1	22.0	14.5	25.2	17.4	10.6	12.4	6.2
Electrolytes											
Sodium (mmol/L)	134		142	146	147	137	135	136	138	140	144
Potassium (mmol/L)	4.4		3.5	3.5	3.1	4.0	4.3	4.0	4.1	3.8	3.9
Chloride (mmol/L)	101		105	102	100	98	101	102	105	108	110
Bicarbonate (mmol/L)	15.9		22.8	26.8	31.1	24.6	28.3	23.7	24.6	23.5	24.9
Magnesium (mmol/L)	0.91										
Liver function											
Total protein (g/L)	60										76
Serum albumin (g/L)	32										41
Total bilirubin (mmol/L)	07										09
Alkaline phosphatase (U/L)	58										65
Alkaline transaminase (U/L)	57										17
Routine tests											
White blood cells ($\times 10^9/L$)	9.33					10.25					9.89
Neutrophil (%)	78.8					74.6					74.1
Lymphocytes (%)	11.1					11.6					15.9
Hemoglobin (g/dL)	12.3					13.8					14.1
Platelet count ($\times 10^9/L$)	208					307					281
Coagulation											
APTT (secs)	27.0					28.5					
Prothrombin time (secs)	11.2					11.4					
Other indicators											
Creatine kinase (U/L)	7224			4755	2863	754		84			84
PTH (pg/mL)	11.0										
Urine creatinine (μmol/L)			5233					3862	7747		8035

APTT: Activated partial thromboplastin time; PTH: Parathyroid hormone.

of hemodialysis, blood tests to determine renal function were repeated. Progressive improvement in renal function was noted with each session of hemodialysis.

OUTCOME AND FOLLOW-UP

The patient's renal function returned to normal.

DISCUSSION

Starfruit has several toxins including caromboxin, an excitatory central nervous system stimulant and oxalate a nephrotoxic agent[5-7]. The sour type of starfruit has higher levels of oxalate than the sweet type. Homemade and medicinal supplements often have high levels of oxalate. When consumed in large amounts, especially when fasting or dehydrated, deposits of calcium oxalate crystals in the renal tubules lead to kidney damage[6]. Chronic kidney disease

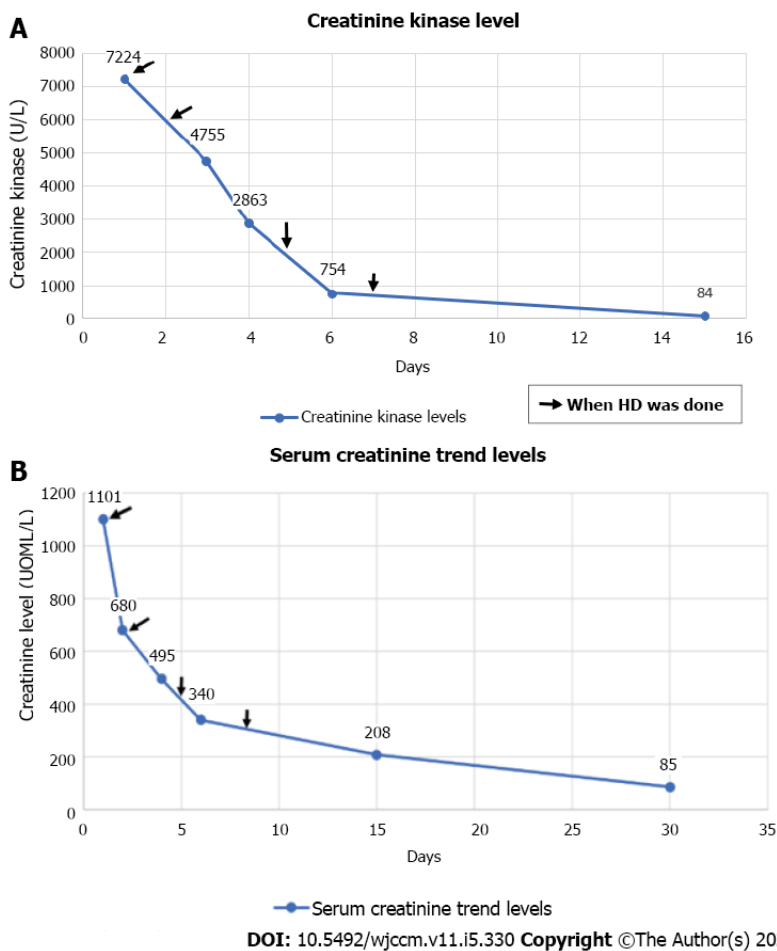


Figure 1 Laboratory examination results. A: Trend in creatinine kinase following hemodialysis; B: Trend in serum creatinine.

has been identified as a major risk factor for starfruit-induced kidney toxicity. Starfruit juice volume of approximately 25 mL is known to cause nephrotoxicity in patients with chronic kidney disease. Other known risk factors include dehydration, the amount of starfruit ingested, and consumption on an empty stomach. Patients with starfruit toxicity show gastrointestinal symptoms such as nausea, vomiting, and abdominal discomfort immediately after ingestion. These symptoms are believed to be due to the direct corrosive effects of dietary oxalates rather than systemic effects[8]. This may be followed by a decrease in urinary output, which can lead to renal dysfunction and acute renal failure. Typical histological findings are the intraluminal and intraepithelial deposition of colorless oxalate crystals. There is no specific treatment for acute kidney damage from starfruit. In patients requiring renal replacement therapy, hemodialysis and hemoperfusion are preferred[9].

Our patient had no evidence of pre-existing renal failure or other contributory factors predisposing to AKI such as sepsis, dehydration, nephrotoxic drugs or obstructive urological causes based on clinical evaluation and tests done. In addition, over the course of four sessions of hemodialysis, he had gradual restoration of his renal function. The temporal relationship between the ingestion of large amount of fruit juice and the onset of symptoms in this case strongly suggests starfruit intoxication as the transient and reversible etiology likely due to resolving oxalate nephropathy.

CONCLUSION

In Asian countries where starfruit is commonly consumed as a traditional remedy, it is imperative for emergency physicians to be aware of starfruit toxicity in patients with unexplained AKI. This will help identify and treat these patients promptly to prevent starfruit-induced nephrotoxicity. Patient history is the key to reaching an early diagnosis. It is essential to prevent starfruit nephrotoxicity by educating the public and especially diabetics on the risks of consuming excess starfruit. Consumption of starfruit as a traditional remedy to control blood sugar levels in diabetics should be discouraged by educating the public.

ACKNOWLEDGEMENTS

We thank the staff of both the Emergency Department and Nephrology Departments for their major contributions in the daily care of this patient.

FOOTNOTES

Author contributions: Zuhary TM and Ponampalam R equally contributed to this case study.

Informed consent statement: Informed written consent was obtained from the patient.

Conflict-of-interest statement: All authors report no relevant conflict of interest for this article.

CARE Checklist (2016) statement: The authors have read the CARE Checklist (2016), and the manuscript was prepared and revised according to the CARE Checklist (2016).

Open-Access: This article is an open-access article that was selected by an in-house editor and fully peer-reviewed by external reviewers. It is distributed in accordance with the Creative Commons Attribution NonCommercial (CC BY-NC 4.0) license, which permits others to distribute, remix, adapt, build upon this work non-commercially, and license their derivative works on different terms, provided the original work is properly cited and the use is non-commercial. See: <https://creativecommons.org/licenses/by-nc/4.0/>

Country/Territory of origin: Singapore

ORCID number: Thajudeen Mohammed Zuhary 0000-0003-1196-2670; R Ponampalam 0000-0002-5813-2044.

S-Editor: Wu YXJ

L-Editor: Webster JR

P-Editor: Wu YXJ

REFERENCES

- 1 Muthu N, Lee SY, Phua KK, Bhore SJ. Nutritional, Medicinal and Toxicological Attributes of Star-Fruits (*Averrhoa carambola* L.): A Review. *Bioinformation* 2016; **12**: 420-424 [PMID: 28405126 DOI: 10.6026/97320630012420]
- 2 Gunasekara LCA, Fernando PHP, Sivakanesan R. A Preliminary Study on the Hypoglycaemic Effect of *Averrhoa carambola* (Star Fruit) in Rats. Sri Lanka: Proceedings of the Peradeniya University Research Sessions; 2011; 83 [DOI: 10.18006/2015.3(5).423.429]
- 3 Neto MM, Silva GE, Costa RS, Vieira Neto OM, Garcia-Cairasco N, Lopes NP, Haendchen PF, Silveira C, Mendes AR, Filho RR, Dantas M. Star fruit: simultaneous neurotoxic and nephrotoxic effects in people with previously normal renal function. *NDT Plus* 2009; **2**: 485-488 [PMID: 25949386 DOI: 10.1093/ndtplus/sfp108]
- 4 Chang JM, Hwang SJ, Kuo HT, Tsai JC, Guh JY, Chen HC, Tsai JH, Lai YH. Fatal Outcome after Ingestion of Star Fruit (*AverrhoaCarambola*) in Uremic Patients. *Am J Kidney Dis* 2000; **35**: 189-193 [DOI: 10.1016/S0272-6386(00)70325-8]
- 5 Fang HC, Lee PT, Lu PJ, Chen CL, Chang TY, Hsu CY, Chung HM, Chou KJ. Mechanisms of star fruit-induced acute renal failure. *Food Chem Toxicol* 2008; **46**: 1744-1752 [PMID: 18294746 DOI: 10.1016/j.fct.2008.01.016]
- 6 Chen CL, Fang HC, Chou KJ, Wang JS, Chung HM. Acute oxalate nephropathy after ingestion of star fruit. *Am J Kidney Dis* 2001; **37**: 418-422 [PMID: 11157385 DOI: 10.1053/ajkd.2001.21333]
- 7 Su YJ, Lee CH, Huang SC, Chuang FR. Quiz page April 2011. A woman with oliguria. Acute oxalate nephropathy caused by excess intake of pure carambola juice. *Am J Kidney Dis* 2011; **57**: A23-A25 [PMID: 21421133 DOI: 10.1053/j.ajkd.2010.11.023]
- 8 Konta T, Yamaoka M, Tanida H, Matsunaga T, Tomoike H. Acute renal failure due to oxalate ingestion. *Intern Med* 1998; **37**: 762-765 [PMID: 9804084 DOI: 10.2169/internalmedicine.37.762]
- 9 Chen LL, Fang JT, Lin JL. Chronic renal disease patients with severe star fruit poisoning: hemoperfusion may be an effective alternative therapy. *Clin Toxicol (Phila)* 2005; **43**: 197-199 [PMID: 15902795 DOI: 10.1081/CLT-57872]



Published by **Baishideng Publishing Group Inc**
7041 Koll Center Parkway, Suite 160, Pleasanton, CA 94566, USA

Telephone: +1-925-3991568

E-mail: bpgoffice@wjgnet.com

Help Desk: <https://www.f6publishing.com/helpdesk>

<https://www.wjgnet.com>

