

World Journal of *Clinical Cases*

World J Clin Cases 2019 December 26; 7(24): 4172-4425



**REVIEW**

- 4172** Polyunsaturated fatty acids and DNA methylation in colorectal cancer
Moradi Sarabi M, Mohammadrezaei Khorramabadi R, Zare Z, Eftekhari E

ORIGINAL ARTICLE**Retrospective Study**

- 4186** Impact of resection margins on long-term survival after pancreaticoduodenectomy for pancreatic head carcinoma
Li CG, Zhou ZP, Tan XL, Gao YX, Wang ZZ, Liu Q, Zhao ZM
- 4196** Arthroscopy combined with unicompartmental knee arthroplasty for treatment of isolated unicompartmental knee arthritis: A long-term comparison
Wang HR, Li ZL, Li J, Wang YX, Zhao ZD, Li W
- 4208** Intact, pie-crusting and repairing the posterior cruciate ligament in posterior cruciate ligament-retaining total knee arthroplasty: A 5-year follow-up
Ma DS, Wen L, Wang ZW, Zhang B, Ren SX, Lin Y
- 4218** Community-acquired pneumonia complicated by rhabdomyolysis: A clinical analysis of 11 cases
Zhao B, Zheng R

Clinical Trials Study

- 4226** Dissection and ligation of the lateral circumflex femoral artery is not necessary when using the direct anterior approach for total hip arthroplasty
Zhao GY, Wang YJ, Xu NW, Liu F

Observational Study

- 4234** Expression of interleukin-32 in bone marrow of patients with myeloma and its prognostic significance
Wang G, Ning FY, Wang JH, Yan HM, Kong HW, Zhang YT, Shen Q

Randomized Controlled Trial

- 4245** Effect of different types of laryngeal mask airway placement on the right internal jugular vein: A prospective randomized controlled trial
Zhang JJ, Qu ZY, Hua Z, Zuo MZ, Zhang HY

SYSTEMATIC REVIEW

- 4254** Chronic pain, posttraumatic stress disorder, and opioid intake: A systematic review
López-Martínez AE, Reyes-Pérez Á, Serrano-Ibáñez ER, Esteve R, Ramírez-Maestre C

CASE REPORT

- 4270 Acute appendicitis in a patient after a uterus transplant: A case report
Kristek J, Kudla M, Chlupac J, Novotny R, Mirejovsky T, Janousek L, Fronek J
- 4277 Pneumococcal infection transmission between family members with congenital asplenia: A case report
Shibata J, Hiramatsu K, Kenzaka T, Kato T
- 4285 Successful treatment of warfarin-induced skin necrosis using oral rivaroxaban: A case report
Kamada M, Kenzaka T
- 4292 Simultaneous *Paragonimus* infection involving the breast and lung: A case report
Oh MY, Chu A, Park JH, Lee JY, Roh EY, Chai YJ, Hwang KT
- 4299 Isolated peritoneal lymphomatosis defined as post-transplant lymphoproliferative disorder after a liver transplant: A case report
Kim HB, Hong R, Na YS, Choi WY, Park SG, Lee HJ
- 4307 Three-dimensional image simulation of primary diaphragmatic hemangioma: A case report
Chu PY, Lin KH, Kao HL, Peng YJ, Huang TW
- 4314 Natural orifice specimen extraction with laparoscopic radical gastrectomy for distal gastric cancer: A case report
Sun P, Wang XS, Liu Q, Luan YS, Tian YT
- 4321 Huge brown tumor of the rib in an unlocatable hyperparathyroidism patient with “self-recovered” serum calcium and parathyroid hormone: A case report
Wang WD, Zhang N, Qu Q, He XD
- 4327 Percutaneous management of atrium and lung perforation: A case report
Zhou X, Ze F, Li D, Li XB
- 4334 Epstein-Barr virus-positive post-transplant lymphoproliferative disorder presenting as hematochezia and enterobrosis in renal transplant recipients in China: A report of two cases
Sun ZJ, Hu XP, Fan BH, Wang W
- 4342 Postoperative multidrug-resistant *Acinetobacter baumannii* meningitis successfully treated with intravenous doxycycline and intraventricular gentamicin: A case report
Wu X, Wang L, Ye YZ, Yu H
- 4349 Reconstruction of massive skin avulsion of the scrota and penis by combined application of dermal regeneration template (Pelnac) and split-thickness skin graft with vacuum-assisted closure: A case report
Fang JJ, Li PF, Wu JJ, Zhou HY, Xie LP, Lu H

- 4355** Multisystem smooth muscle dysfunction syndrome in a Chinese girl: A case report and review of the literature
Chen SN, Wang YQ, Hao CL, Lu YH, Jiang WJ, Gao CY, Wu M
- 4366** Kidney inflammatory myofibroblastic tumor masquerading as metastatic malignancy: A case report and literature review
Zhang GH, Guo XY, Liang GZ, Wang Q
- 4377** Hydroxychloroquine-induced renal phospholipidosis resembling Fabry disease in undifferentiated connective tissue disease: A case report
Wu SZ, Liang X, Geng J, Zhang MB, Xie N, Su XY
- 4384** Spontaneous ovarian hyperstimulation syndrome: Report of two cases
Gui J, Zhang J, Xu WM, Ming L
- 4391** Castleman disease in the hepatic-gastric space: A case report
Xu XY, Liu XQ, Du HW, Liu JH
- 4398** KIT and platelet-derived growth factor receptor α wild-type gastrointestinal stromal tumor associated with neurofibromatosis type 1: Two case reports
Kou YW, Zhang Y, Fu YP, Wang Z
- 4414** Isolated elevated aspartate aminotransferase in an asymptomatic woman due to macro-aspartate aminotransferase: A case report
Zhan MR, Liu X, Zhang MY, Niu JQ
- 4420** Rehabilitation of anterior pituitary dysfunction combined with extrapontine myelinolysis: A case report
Yang MX, Chen XN

ABOUT COVER

Editorial Board Member of *World Journal of Clinical Cases*, Ashu Seith Bhalla, MD, Professor, Department of Radiodiagnosis, All India Institute of Medical Sciences, New Delhi 110029, India

AIMS AND SCOPE

The primary aim of *World Journal of Clinical Cases* (WJCC, *World J Clin Cases*) is to provide scholars and readers from various fields of clinical medicine with a platform to publish high-quality clinical research articles and communicate their research findings online.

WJCC mainly publishes articles reporting research results and findings obtained in the field of clinical medicine and covering a wide range of topics, including case control studies, retrospective cohort studies, retrospective studies, clinical trials studies, observational studies, prospective studies, randomized controlled trials, randomized clinical trials, systematic reviews, meta-analysis, and case reports.

INDEXING/ABSTRACTING

The WJCC is now indexed in PubMed, PubMed Central, Science Citation Index Expanded (also known as SciSearch®), and Journal Citation Reports/Science Edition. The 2019 Edition of Journal Citation Reports cites the 2018 impact factor for WJCC as 1.153 (5-year impact factor: N/A), ranking WJCC as 99 among 160 journals in Medicine, General and Internal (quartile in category Q3).

RESPONSIBLE EDITORS FOR THIS ISSUE

Responsible Electronic Editor: Ji-Hong Liu

Proofing Production Department Director: Yun-Xiaojuan Wu

NAME OF JOURNAL

World Journal of Clinical Cases

ISSN

ISSN 2307-8960 (online)

LAUNCH DATE

April 16, 2013

FREQUENCY

Semimonthly

EDITORS-IN-CHIEF

Dennis A Bloomfield, Bao-Gan Peng, Sandro Vento

EDITORIAL BOARD MEMBERS

<https://www.wjnet.com/2307-8960/editorialboard.htm>

EDITORIAL OFFICE

Jin-Lei Wang, Director

PUBLICATION DATE

December 26, 2019

COPYRIGHT

© 2019 Baishideng Publishing Group Inc

INSTRUCTIONS TO AUTHORS

<https://www.wjnet.com/bpg/gerinfo/204>

GUIDELINES FOR ETHICS DOCUMENTS

<https://www.wjnet.com/bpg/GerInfo/287>

GUIDELINES FOR NON-NATIVE SPEAKERS OF ENGLISH

<https://www.wjnet.com/bpg/gerinfo/240>

PUBLICATION MISCONDUCT

<https://www.wjnet.com/bpg/gerinfo/208>

ARTICLE PROCESSING CHARGE

<https://www.wjnet.com/bpg/gerinfo/242>

STEPS FOR SUBMITTING MANUSCRIPTS

<https://www.wjnet.com/bpg/GerInfo/239>

ONLINE SUBMISSION

<https://www.f6publishing.com>

Huge brown tumor of the rib in an unlocatable hyperparathyroidism patient with “self-recovered” serum calcium and parathyroid hormone: A case report

Wen-Da Wang, Ning Zhang, Qiang Qu, Xiao-Dong He

ORCID number: Wen-Da Wang (0000-0003-0955-2912); Ning Zhang (0000-0003-0081-6459); Qiang Qu (0000-0002-4913-2114); Xiao-Dong He (0000-0002-6682-2926).

Author contributions: He XD, Zhang N and Wang WD performed the operation; Wang WD collected the case data and drafted the article; He XD and Qu Q made critical revisions to the manuscript.

Informed consent statement: Consent was obtained from the patient for publication of this report and any accompanying images.

Conflict-of-interest statement: The authors have no conflicts of interest to declare.

CARE Checklist (2016) statement: CARE Checklist (2016) statement has been uploaded.

Open-Access: This article is an open-access article that was selected by an in-house editor and fully peer-reviewed by external reviewers. It is distributed in accordance with the Creative Commons Attribution-Non Commercial (CC BY-NC 4.0) license, which permits others to distribute, remix, adapt, build upon this work non-commercially, and license their derivative works on different terms, provided the original work is properly cited and the use is non-commercial. See: <http://creativecommons.org/licenses/by-nc/4.0/>

Wen-Da Wang, Department of Surgery, Peking Union Medical College Hospital, Chinese Academy of Medical Sciences and Peking Union Medical College, Beijing 100730, China

Ning Zhang, Qiang Qu, Xiao-Dong He, Department of General Surgery, Peking Union Medical College Hospital, Chinese Academy of Medical Sciences and Peking Union Medical College, Beijing 100730, China

Corresponding author: Xiao-Dong He, MD, Doctor, Professor, Department of General Surgery, Peking Union Medical College Hospital, Chinese Academy of Medical Sciences, Shuaifuyuan 1, Beijing 100730, China. hexiaodong@pumch.cn

Telephone: +86-10-69152613

Fax: +86-10-69152613

Abstract

BACKGROUND

The brown tumor is a kind of complication of hyperparathyroidism (HPT). The ultimate therapy usually is the resolution of HPT. We herein report an unlocatable HPT patient who received resection of a huge brown tumor of the rib, and experienced “self-recovery” of serum calcium and parathyroid hormone.

CASE SUMMARY

A 34-year-old female patient who suffered from a gradually increasing mass of the left chest wall since 2007 came to our hospital for treatment. The patient had a history of serum Ca and parathyroid hormone (PTH) increasing since June 2015 and received zoledronic acid treatment for 17 mo. When she came to our hospital in November 2017 after discontinuing medical treatment for 3 mo, the serum Ca and PTH levels were within normal ranges. The patient had no imaging abnormalities of parathyroid ultrasound or ^{99m}Tc-methoxyisobutyl isonitrile. Enhanced computed tomography revealed a local soft tissue mass of 96 mm × 113 mm with bone erosion of the left 8th rib, and the mass presented irregular enhancement with an unclear boundary between the mass and spleen. The mass was thought to likely be caused by HPT, but a malignancy could not be ruled out. Resection of the mass was performed, and the pathology proved that the mass was a brown tumor. A diagnosis of unlocatable HPT was considered. Since the serum Ca and PTH levels were both normal pre- and post-operation, the patient did not receive exploratory surgery for HPT, and received regular follow-up.

CONCLUSION

Manuscript source: Unsolicited manuscript

Received: August 17, 2019

Peer-review started: August 17, 2019

First decision: September 23, 2019

Revised: October 17, 2019

Accepted: November 15, 2019

Article in press: November 15, 2019

Published online: December 26, 2019

P-Reviewer: Eleftheriadis T

S-Editor: Wang J

L-Editor: Filipodia

E-Editor: Xing YX



The huge brown tumor of the rib and “self-recovered” serum PTH and Ca levels are relatively rare in HPT patients. An exploratory operation may be deferred for these patients, and long-term follow-up should be performed.

Key words: Brown tumor; Hyperparathyroidism; Unlocatable; Self-recovered; Resection; Case report

©The Author(s) 2019. Published by Baishideng Publishing Group Inc. All rights reserved.

Core tip: This is a very interesting case of unlocatable hyperparathyroidism (HPT). The patient presented a huge mass on her left chest wall. However, the serum Ca and parathyroid hormone levels were both normal pre- and post-operation, and the diagnosis was difficult to make. The mass was thought to be likely caused by HPT, but a malignancy could not be ruled out. Finally, the pathology proved that the mass was a brown tumor. Since the patient experienced serum calcium and parathyroid hormone “self-recovery”, she did not receive exploratory surgery for HPT, and received regular follow-up.

Citation: Wang WD, Zhang N, Qu Q, He XD. Huge brown tumor of the rib in an unlocatable hyperparathyroidism patient with “self-recovered” serum calcium and parathyroid hormone: A case report. *World J Clin Cases* 2019; 7(24): 4321-4326

URL: <https://www.wjgnet.com/2307-8960/full/v7/i24/4321.htm>

DOI: <https://dx.doi.org/10.12998/wjcc.v7.i24.4321>

INTRODUCTION

The brown tumor is a kind of complication of hyperparathyroidism (HPT), and it may sometimes be the initial symptom of HPT. The ultimate therapy is the resolution of HPT. Here, we reported an interesting case of unlocatable HPT that involved a resection of a huge brown tumor of the rib, and experienced “self-recovered” serum parathyroid hormone (PTH) and calcium.

CASE PRESENTATION

Chief complaints

A mass of the left chest wall for about 10 years.

History of present illness

A 34-year-old female came to the General Surgery Department of our hospital with the complaint of a mass of the left chest wall on November 6, 2017. The patient felt transient pain in the left ribs in 2007 after delivery. Then the patient accidentally touched a mass in her left ribs with no special feeling. The patient went to a local hospital in June 2015 for a gradual enlargement in mass volume with epigastric discomfort. Upper abdominal computed tomography (CT) revealed that a 7.3 cm × 8.9 cm × 7.0 cm round low-density area might come from ribs that compress the stomach. They also found that serum PTH (162 pg/mL, normal range 12-88 pg/mL) and calcium (Ca, 2.71 mmol/L, normal range 1.8-2.6 mmol/L) levels were higher than normal ranges. A brown tumor of HPT was not excluded. Single photon emission computed tomography was further conducted, but no abnormality was found in the parathyroid glands of both sides. The patient was preliminarily diagnosed with HPT. However, the patient had no local evidence of primary HPT, and she had no history of chronic kidney disease (CKD). The patient received zoledronic acid for 17 mo and stopped in August 2017. The patient came to the Endocrinology Department of our hospital for further diagnosis on November 6, 2017.

Physical examination

A mass of the left chest wall could be touched with no pain, and the size was about 8 cm × 8 cm.

Laboratory examinations

The retest of serum Ca was 2.14 mmol/L, P 0.90 mmol/L, ALP 72 U/L, PTH 59.5 pg/mL, and 1,25-dihydroxyvitamin D3 105.27 pg/mL, all of which were within normal range. The 24-h urinary calcium was 8.18 mmol/24 h and 24-h urinary phosphorus was 10.01 mmol/24 h, and both were also normal.

Imaging examinations

The test of bone mineral density revealed that there was no obvious osteoporosis. The ultrasound of the parathyroid revealed no abnormal changes in the parathyroid region, nor in ^{99m}Tc -methoxyisobutyl isonitrile (^{99m}Tc -MIBI) imaging (Figure 1). Radionuclide bone imaging presented a tumor likely originating from the 7-9th ribs (Figure 2). Re-examination of the chest and abdomen enhanced CT revealed bone erosion of the left 8th rib, and a local soft tissue mass of 96 mm × 113 mm with strip high density shadow inside. The mass presented irregular enhancement and an oppressed spleen, stomach, pancreas and colon. The boundary of the mass and spleen was unclear (Figure 3).

FINAL DIAGNOSIS

The diagnosis of a brown tumor was considered, but a malignancy could not be ruled out.

TREATMENT

The patient was admitted into the General Surgery Department on December 25, 2017. A mass resection was performed. A thoracoabdominal incision was chosen, and the mass was found originating from the 9-10th ribs. The mass was separated from the compressed tissues, and was excised completely with part of the 9-10th ribs (Figure 4). Then the diaphragm was repaired and the incision was closed. The pathology was a brown tumor of HPT.

OUTCOME AND FOLLOW-UP

The patient did not receive medication after the surgery, and was discharged without complications on the 7th d after operation. Serum PTH (54.6 pg/mL) and Ca (2.28 mmol/L) were in the normal range on July 9, 2019.

DISCUSSION

Brown tumors are giant-cell lesions due to primary or secondary HPT, and may occur in about 4.5% of primary HPT patients and 1.5% of secondary HPT patients^[1]. The common locations of brown tumors are pelvis, ribs, long bone shaft, clavicle, and jaw^[2]. Brown tumors may sometimes be the first manifestation of HPT, and should be differentially diagnosed with solitary bone lesions, such as metabolic osteopathy, multiple myeloma, Langerhans' cell histiocytosis, leukemia, multiple bone cysts, multiple non-ossifying fibroma, and fibrous dysplasia^[2,3]. In our case, although the patient has a temporary increase of serum Ca and PTH, the serum or urinary Ca and serum PTH were normal when she came to our hospital. The results of cervical ultrasound and ^{99m}Tc -MIBI were also negative. Thus, the diagnosis should be made more prudently. The resection of the mass could not only relieve symptoms, but also exclude the possibility of malignancy.

However, the diagnosis of primary HPT may be inerrant when considering the pathology of the bone lesion and past medical history. The patient realized the mass of the left chest wall 10 years ago, but HPT was considered about 8 years later when high levels of serum Ca and PTH were found. She received zoledronic acid treatment for hypercalcemia for a period of time, which was then discontinued. The preoperative laboratory tests revealed normal serum/urinary Ca and PTH, with negative results from imaging examinations. For a suspicious primary HPT, cervical ultrasound and ^{99m}Tc -MIBI are usually used for location, and the sensitivities are 54% and 59%, respectively^[2]. However, combined imaging of the two methods could reach a sensitivity of about 90%^[2,4]. The main reasons for false-negative ultrasound include abnormal migration of the inferior parathyroid glands (substernal, retrotracheal or retroesophageal)^[5], obesity^[6], and interference of thyroid lesions^[7]. The imaging of ^{99m}Tc -MIBI depends on the percentage of mitochondria-rich oxyphil cells, growth

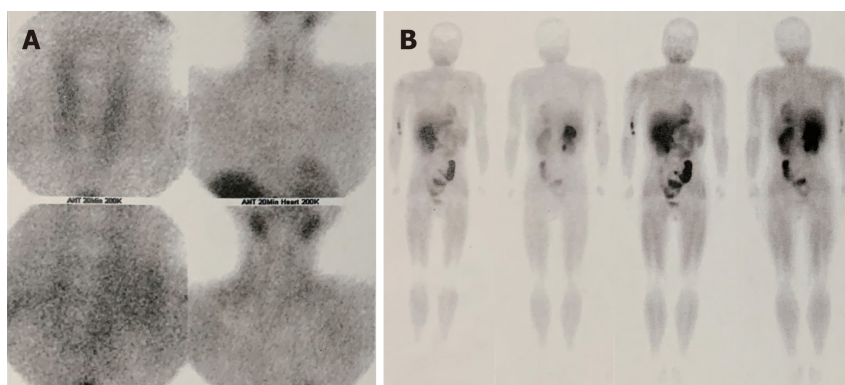


Figure 1 Ultrasound of parathyroid revealed no abnormal changes in the region of parathyroids, nor in ^{99m}Tc -methoxyisobutyl isonitrile imaging. A-B showed that there was no abnormality of parathyroid in ^{99m}Tc -methoxyisobutyl isonitrile imaging, nor any other abnormal radioactivity concentrations.

phase of glands, and P-glycoprotein levels^[6]. PTH level and gland volume are important factors that influence imaging sensitivity^[6,8].

When there are no positive results in all of the imaging examinations except for hypercalcemia, and high levels of PTH occur, surgical exploration may be tried. According to the study of Amin *et al*^[2], hyperfunctioning glands are not more frequently located on a particular side or anatomical position. Therefore, intraoperative parathyroid hormone monitoring can be used to guide the resection. Considering that the serum Ca and PTH levels of our patient are within the normal ranges, the patient did not receive the exploratory surgery. However, she needs long-term follow-up to monitor laboratory tests and dynamic changes of primary lesions. The transient HPT with “self-recovery” of PTH is rare. Kim^[9] reported an adult female patient with acute kidney injury (AKI) who experienced a transient elevation of PTH. However, the PTH elevation resolved after several weeks, in parallel with improving renal function, and the patient did not develop a brown tumor during this short time period. Our patient has no history of AKI or CKD, and the formation of the brown tumor suggests that the HPT may have existed for a long time. Thus, unlocatable primary HPT should be considered. There has been evidence that zoledronic acid could reduce the level of PTH in HPT of CKD^[10], but a similar efficacy in primary HPT is unclear. Close follow-up should therefore be performed in case of recurrent elevation of PTH in the future.

CONCLUSION

Although there are some unlocatable HPT reports, cases involving a huge brown tumor of the rib and “self-recovered” serum PTH and Ca are relatively rare. An exploratory operation may be deferred for these patients, and long-term follow-up should be performed.

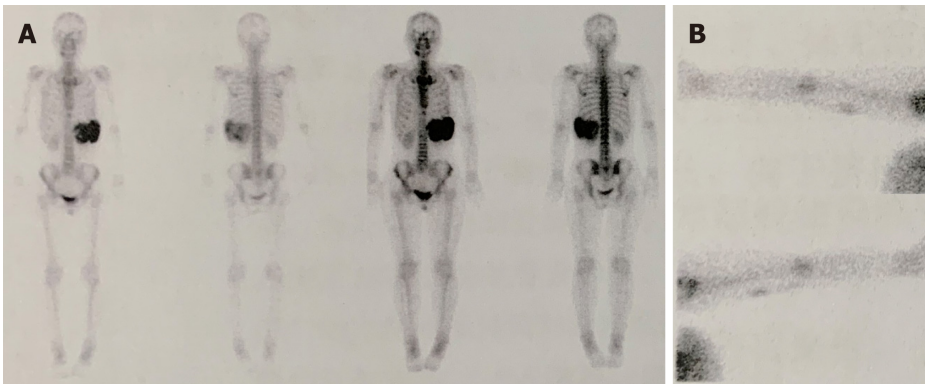


Figure 2 The whole-body bone imaging of the patient. A: There was abnormal radioactivity concentrations at the position of the left 7-9th ribs; B: The tracer extravasation was shown in the right arm.

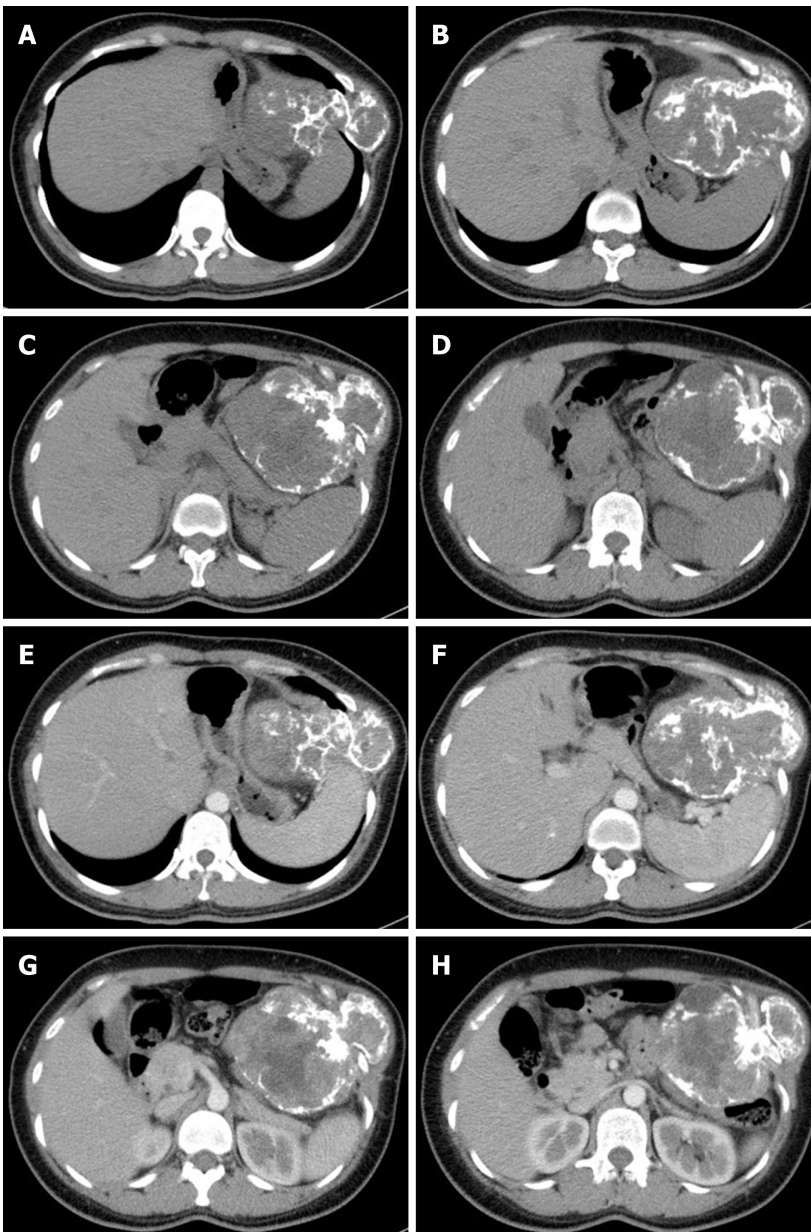


Figure 3 Enhanced chest and abdominal computed tomography revealed the rib mass. A-D: Plain scan; E-H: Enhanced scan.

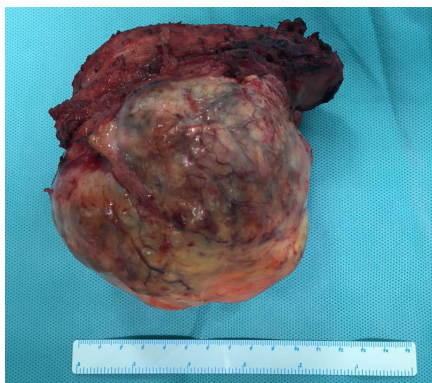

Figure 4 Gross pathology of the mass originating from the 9-10th ribs.

REFERENCES

- 1 **Mori H**, Okada Y, Arai T, Shimaziri S, Tanaka Y. A case of multiple brown tumors with primary hyperparathyroidism. *J Bone Miner Metab* 2013; **31**: 123-127 [PMID: [22714091](#) DOI: [10.1007/s00774-012-0364-2](#)]
- 2 **Amin AL**, Wang TS, Wade TJ, Quiroz FA, Hellman RS, Evans DB, Yen TW. Nonlocalizing imaging studies for hyperparathyroidism: where to explore first? *J Am Coll Surg* 2011; **213**: 793-799 [PMID: [22014659](#) DOI: [10.1016/j.jamcollsurg.2011.09.011](#)]
- 3 **Fraker DL**, Harsono H, Lewis R. Minimally invasive parathyroidectomy: benefits and requirements of localization, diagnosis, and intraoperative PTH monitoring. long-term results. *World J Surg* 2009; **33**: 2256-2265 [PMID: [19763685](#) DOI: [10.1007/s00268-009-0166-4](#)]
- 4 **Zhou J**, Lu DY, Xia L, Cheng XJ. Diagnosis performance of ^{99m}Tc-MIBI and multimodality imaging for hyperparathyroidism. *J Huazhong Univ Sci Technolog Med Sci* 2017; **37**: 582-586 [PMID: [28786065](#) DOI: [10.1007/s11596-017-1776-y](#)]
- 5 **Erbil Y**, Barbaros U, Tükenmez M, İşsever H, Salmaslıoğlu A, Adalet I, Ozarmağan S, Tezelman S. Impact of adenoma weight and ectopic location of parathyroid adenoma on localization study results. *World J Surg* 2008; **32**: 566-571 [PMID: [18210183](#) DOI: [10.1007/s00268-007-9389-4](#)]
- 6 **Berber E**, Parikh RT, Ballem N, Garner CN, Milas M, Siperstein AE. Factors contributing to negative parathyroid localization: an analysis of 1000 patients. *Surgery* 2008; **144**: 74-79 [PMID: [18571587](#) DOI: [10.1016/j.surg.2008.03.019](#)]
- 7 **Kamaya A**, Quon A, Jeffrey RB. Sonography of the abnormal parathyroid gland. *Ultrasound Q* 2006; **22**: 253-262 [PMID: [17146333](#) DOI: [10.1097/01.ruq.0000237260.33509.4f](#)]
- 8 **Amin AL**, Wang TS, Wade TJ, Yen TW. Normal PTH levels in primary hyperparathyroidism: still the same disease? *Ann Surg Oncol* 2011; **18**: 3437-3442 [PMID: [21537864](#) DOI: [10.1245/s10434-011-1744-x](#)]
- 9 **Lim AK**. Transient secondary hyperparathyroidism in acute kidney injury. *Intern Med J* 2016; **46**: 857-858 [PMID: [27405896](#) DOI: [10.1111/imj.13095](#)]
- 10 **Moe SM**, Chen NX, Newman CL, Gattone VH 2nd, Organ JM, Chen X, Allen MR. A comparison of calcium to zoledronic acid for improvement of cortical bone in an animal model of CKD. *J Bone Miner Res* 2014; **29**: 902-910 [PMID: [24038306](#) DOI: [10.1002/jbmr.2089](#)]



Published By Baishideng Publishing Group Inc
7041 Koll Center Parkway, Suite 160, Pleasanton, CA 94566, USA
Telephone: +1-925-2238242
E-mail: bpgoffice@wjgnet.com
Help Desk: <https://www.f6publishing.com/helpdesk>
<https://www.wjgnet.com>

