

World Journal of *Clinical Cases*

World J Clin Cases 2023 February 6; 11(4): 719-978



MINIREVIEWS

- 719 Development and refinement of diagnostic and therapeutic strategies for managing patients with cardiogenic stroke: An arduous journey
Fan ZX, Liu RX, Liu GZ
- 725 Portal vein aneurysm-etiology, multimodal imaging and current management
Kurtcehajic A, Zerem E, Alibegovic E, Kunosic S, Hujdurovic A, Fejzic JA

ORIGINAL ARTICLE**Clinical and Translational Research**

- 738 CD93 serves as a potential biomarker of gastric cancer and correlates with the tumor microenvironment
Li Z, Zhang XJ, Sun CY, Fei H, Li ZF, Zhao DB

Retrospective Study

- 756 Chest computed tomography findings of the Omicron variants of SARS-CoV-2 with different cycle threshold values
Ying WF, Chen Q, Jiang ZK, Hao DG, Zhang Y, Han Q
- 764 Major depressive disorders in patients with inflammatory bowel disease and rheumatoid arthritis
Haider MB, Basida B, Kaur J
- 780 Selective laser trabeculoplasty as adjunctive treatment for open-angle glaucoma *vs* following incisional glaucoma surgery in Chinese eyes
Zhu J, Guo J
- 788 Efficacy of transvaginal ultrasound-guided local injections of absolute ethanol for ectopic pregnancies with intrauterine implantation sites
Kakinuma T, Kakinuma K, Matsuda Y, Yanagida K, Ohwada M, Kaijima H

Clinical Trials Study

- 797 Efficacy of incremental loads of cow's milk as a treatment for lactose malabsorption in Japan
Hasegawa M, Okada K, Nagata S, Sugihara S

Observational Study

- 809 Transdiagnostic considerations of mental health for the post-COVID era: Lessons from the first surge of the pandemic
Goldstein Ferber S, Shoval G, Rossi R, Trezza V, Di Lorenzo G, Zalsman G, Weller A, Mann JJ
- 821 Effect of patient COVID-19 vaccine hesitancy on hospital care team perceptions
Caspi I, Freund O, Pines O, Elkana O, Ablin JN, Bornstein G

Randomized Clinical Trial

- 830 Improvement of inflammatory response and gastrointestinal function in perioperative of cholelithiasis by Modified Xiao-Cheng-Qi decoction
Sun BF, Zhang F, Chen QP, Wei Q, Zhu WT, Ji HB, Zhang XY

CASE REPORT

- 844 Metagenomic next-generation sequencing for pleural effusions induced by viral pleurisy: A case report
Liu XP, Mao CX, Wang GS, Zhang MZ
- 852 *Clostridium perfringens* gas gangrene caused by closed abdominal injury: A case report and review of the literature
Li HY, Wang ZX, Wang JC, Zhang XD
- 859 Is lymphatic invasion of microrectal neuroendocrine tumors an incidental event?: A case report
Ran JX, Xu LB, Chen WW, Yang HY, Weng Y, Peng YM
- 866 *Pneumocystis jirovecii* diagnosed by next-generation sequencing of bronchoscopic alveolar lavage fluid: A case report and review of literature
Cheng QW, Shen HL, Dong ZH, Zhang QQ, Wang YF, Yan J, Wang YS, Zhang NG
- 874 Identification of 1q21.1 microduplication in a family: A case report
Huang TT, Xu HF, Wang SY, Lin WX, Tung YH, Khan KU, Zhang HH, Guo H, Zheng G, Zhang G
- 883 Double pigtail catheter reduction for seriously displaced intravenous infusion port catheter: A case report
Liu Y, Du DM
- 888 Thyroid storm in a pregnant woman with COVID-19 infection: A case report and review of literatures
Kim HE, Yang J, Park JE, Baek JC, Jo HC
- 896 Computed tomography diagnosed left ovarian venous thrombophlebitis after vaginal delivery: A case report
Wang JJ, Hui CC, Ji YD, Xu W
- 903 Preoperative 3D reconstruction and fluorescent indocyanine green for laparoscopic duodenum preserving pancreatic head resection: A case report
Li XL, Gong LS
- 909 Unusual presentation of systemic lupus erythematosus as hemophagocytic lymphohistiocytosis in a female patient: A case report
Peng LY, Liu JB, Zuo HJ, Shen GF
- 918 Polyarteritis nodosa presenting as leg pain with resolution of positron emission tomography-images: A case report
Kang JH, Kim J
- 922 Easily misdiagnosed complex Klippel-Trenaunay syndrome: A case report
Li LL, Xie R, Li FQ, Huang C, Tuo BG, Wu HC

- 931** Benign lymphoepithelial cyst of parotid gland without human immunodeficiency virus infection: A case report
Liao Y, Li YJ, Hu XW, Wen R, Wang P
- 938** Epithelioid trophoblastic tumor of the lower uterine segment and cervical canal: A case report
Yuan LQ, Hao T, Pan GY, Guo H, Li DP, Liu NF
- 945** Treatment of portosystemic shunt-borne hepatic encephalopathy in a 97-year-old woman using balloon-occluded retrograde transvenous obliteration: A case report
Nishi A, Kenzaka T, Sogi M, Nakaminato S, Suzuki T
- 952** Development of Henoch-Schoenlein purpura in a child with idiopathic hypereosinophilia syndrome with multiple thrombotic onset: A case report
Xu YY, Huang XB, Wang YG, Zheng LY, Li M, Dai Y, Zhao S
- 962** Three cases of jejunal tumors detected by standard upper gastrointestinal endoscopy: A case series
Lee J, Kim S, Kim D, Lee S, Ryu K
- 972** Omental infarction diagnosed by computed tomography, missed with ultrasonography: A case report
Hwang JK, Cho YJ, Kang BS, Min KW, Cho YS, Kim YJ, Lee KS

ABOUT COVER

Editorial Board Member of *World Journal of Clinical Cases*, Sahand Samieirad, DDS, MS, MSc, Associate Professor, Oral and Maxillofacial Surgery Department, Mashhad Dental School, Mashhad University of Medical Sciences, Mashhad 9178613111, Iran. samieerads@mums.ac.ir

AIMS AND SCOPE

The primary aim of *World Journal of Clinical Cases* (WJCC, *World J Clin Cases*) is to provide scholars and readers from various fields of clinical medicine with a platform to publish high-quality clinical research articles and communicate their research findings online.

WJCC mainly publishes articles reporting research results and findings obtained in the field of clinical medicine and covering a wide range of topics, including case control studies, retrospective cohort studies, retrospective studies, clinical trials studies, observational studies, prospective studies, randomized controlled trials, randomized clinical trials, systematic reviews, meta-analysis, and case reports.

INDEXING/ABSTRACTING

The WJCC is now abstracted and indexed in Science Citation Index Expanded (SCIE, also known as SciSearch®), Journal Citation Reports/Science Edition, Current Contents®/Clinical Medicine, PubMed, PubMed Central, Scopus, Reference Citation Analysis, China National Knowledge Infrastructure, China Science and Technology Journal Database, and Superstar Journals Database. The 2022 Edition of Journal Citation Reports® cites the 2021 impact factor (IF) for WJCC as 1.534; IF without journal self cites: 1.491; 5-year IF: 1.599; Journal Citation Indicator: 0.28; Ranking: 135 among 172 journals in medicine, general and internal; and Quartile category: Q4. The WJCC's CiteScore for 2021 is 1.2 and Scopus CiteScore rank 2021: General Medicine is 443/826.

RESPONSIBLE EDITORS FOR THIS ISSUE

Production Editor: Si Zhao; Production Department Director: Xu Guo; Editorial Office Director: Jin-Lei Wang.

NAME OF JOURNAL

World Journal of Clinical Cases

ISSN

ISSN 2307-8960 (online)

LAUNCH DATE

April 16, 2013

FREQUENCY

Thrice Monthly

EDITORS-IN-CHIEF

Bao-Gan Peng, Jerzy Tadeusz Chudek, George Kontogeorgos, Maurizio Serati, Ja Hyeon Ku

EDITORIAL BOARD MEMBERS

<https://www.wjgnet.com/2307-8960/editorialboard.htm>

PUBLICATION DATE

February 6, 2023

COPYRIGHT

© 2023 Baishideng Publishing Group Inc

INSTRUCTIONS TO AUTHORS

<https://www.wjgnet.com/bpg/gerinfo/204>

GUIDELINES FOR ETHICS DOCUMENTS

<https://www.wjgnet.com/bpg/GerInfo/287>

GUIDELINES FOR NON-NATIVE SPEAKERS OF ENGLISH

<https://www.wjgnet.com/bpg/gerinfo/240>

PUBLICATION ETHICS

<https://www.wjgnet.com/bpg/GerInfo/288>

PUBLICATION MISCONDUCT

<https://www.wjgnet.com/bpg/gerinfo/208>

ARTICLE PROCESSING CHARGE

<https://www.wjgnet.com/bpg/gerinfo/242>

STEPS FOR SUBMITTING MANUSCRIPTS

<https://www.wjgnet.com/bpg/GerInfo/239>

ONLINE SUBMISSION

<https://www.f6publishing.com>



Portal vein aneurysm-etiology, multimodal imaging and current management

Admir Kurtcehajic, Enver Zerem, Ervin Alibegovic, Suad Kunosic, Ahmed Hujdurovic, Jasmin A Fejzic

Specialty type: Gastroenterology and hepatology

Provenance and peer review: Invited article; Externally peer reviewed.

Peer-review model: Single blind

Peer-review report's scientific quality classification

Grade A (Excellent): 0
Grade B (Very good): 0
Grade C (Good): C
Grade D (Fair): D
Grade E (Poor): 0

P-Reviewer: Ding X, China; Sripongpun P, Thailand

Received: November 6, 2022

Peer-review started: November 6, 2022

First decision: December 11, 2022

Revised: December 24, 2022

Accepted: January 12, 2023

Article in press: January 12, 2023

Published online: February 6, 2023



Admir Kurtcehajic, Department of Gastroenterology and Hepatology, Plava Medical Group, Tuzla 75000, Tuzla Kanton, Bosnia and Herzegovina

Enver Zerem, Department of Medical Sciences, The Academy of Sciences and Arts of Bosnia and Herzegovina, Sarajevo 71000, Bosnia and Herzegovina

Ervin Alibegovic, Department of Gastroenterology and Hepatology, University Clinical Center Tuzla, Tuzla 75000, Tuzla Kanton, Bosnia and Herzegovina

Suad Kunosic, Department of Physics, Faculty of Natural Sciences and Mathematics, University of Tuzla, Tuzla 75000, Tuzla Kanton, Bosnia and Herzegovina

Ahmed Hujdurovic, Department of Internal Medicine, Plava Medical Group, Tuzla 75000, Tuzla Kanton, Bosnia and Herzegovina

Jasmin A Fejzic, Department of Internal Medicine, General Hospital Tesanj, Tesanj 74260, Bosnia and Herzegovina

Corresponding author: Admir Kurtcehajic, PhD, Academic Research, Research Assistant, Research Scientist, Department of Gastroenterology and Hepatology, Plava Medical Group, No. 10 Crnogorcevica, Tuzla 75000, Tuzla Kanton, Bosnia and Herzegovina.
admireg7@gmail.com

Abstract

Portal vein aneurysm (PVA) is a rare vascular abnormality, representing 3% of all venous aneurysms in the human body, and is not well understood. It can be congenital or acquired, located mainly at the level of confluence, main trunk, branches and bifurcation. A PVA as an abnormality of the portal venous system was first reported in 1956 by Barzilai and Kleckner. A review from 2015 entitled "Portal vein aneurysm: What to know" considered fewer than 200 cases. In the last seven years, there has been an increase in the number of PVAs diagnosed thanks to routine abdominal imaging. The aim of this review is to provide a comprehensive update of PVA, including aetiology, epidemiology, and clinical assessment, along with an evaluation of advanced multimodal imaging features of aneurysm and management approaches.

Key Words: Aneurysm; Portal vein; Abdominal imaging; Treatment; Follow-up

©The Author(s) 2023. Published by Baishideng Publishing Group Inc. All rights reserved.

Core Tip: The number of reported portal vein aneurysms (PVAs) across the world with this review stands at about 280. In relation to a new acquired aetiology of PVA, the following conditions are noted: Budd-Chiari syndrome, splenomegaly in thalassaemia major, giant splenic artery aneurysm and a long-term cholelithiasis. Percentage of 30 to 50 of patients experienced non-specific abdominal pain, the most frequent complications of PVA are thrombosis and biliopathy. Recently, endoscopic ultrasound and intraductal ultrasonography, as an additional tool have also been used for assessment of PVA in more detail. With this review we have highlighted treatment of PVA with comorbidities based on the transjugular intrahepatic portosystemic shunt, percutaneous approach, and endoscopic approach.

Citation: Kurtcehajic A, Zerem E, Alibegovic E, Kunosic S, Hujdurovic A, Fejzic JA. Portal vein aneurysm-etiology, multimodal imaging and current management. *World J Clin Cases* 2023; 11(4): 725-737

URL: <https://www.wjgnet.com/2307-8960/full/v11/i4/725.htm>

DOI: <https://dx.doi.org/10.12998/wjcc.v11.i4.725>

INTRODUCTION

A portal vein aneurysm (PVA) is the abnormal focal saccular or fusiform dilatation of the portal venous system, and it is defined as a PV diameter exceeding 19 mm in cirrhotic patients and 15 mm in a normal liver. It is a rare vascular abnormality, representing 3% of all venous aneurysms in the human body, and is not well understood[1-7].

Douglass *et al*[8] studied 92 autopsies and reported that the diameter of the PV was between 0.64 mm and 12.1 mm in patients without cirrhosis and those without portal hypertension. In 1976, Doust *et al*[9] conducted a vascular study of 53 patients to assess the size of the PV and underlying liver status through abdominal ultrasound, and they detected that the maximum calibre of the PV was 19 mm in cirrhotic patients and 15 mm in patients with normal livers. Hence, a portal vein diameter of > 20 mm is universally regarded as the threshold for diagnosis of a PVA.

In a retrospective study by Koc *et al*[10], involving 4186 patients who had undergone routine abdominal contrast-enhanced computed tomography (CT), the prevalence of PVAs was 0.43%. The location of a PVA can be extrahepatic or intrahepatic. Extrahepatic PVAs often occur in the main trunk of the PV, the splenomesenteric confluence, at the level of the PV bifurcation, the main branches of the PV, the splenic vein (SV) and the superior mesenteric vein (SMV). A study by Doust *et al*[9] characterized intrahepatic PVAs as having a diameter measuring more than 7 mm in normal patients and 8.5 mm in cirrhotic patients. PVA as an abnormality of portal venous system firstly was reported 1956 by Barzilai and Kleckner[11]. A review from 2015 entitled “Portal vein aneurysm: What to know” considered 96 reports and included 190 patients[1].

Aiming to clarify novelty as regards this visceral vascular abnormality, we performed a literature search of the PubMed database for all articles relating to PVA between January 2015 and July 2022[12-68]. We collected 57 reports, involving 62 patients with a PVA[3-7,12-16,19,21-25,27,29-68]; we also found one retrospective study with 18 PVA patients[2], and three cases of PV pseudoaneurysm[69-71].

ETIOLOGY, MULTIMODAL IMAGING AND CURRENT MANAGEMENT

Epidemiological characteristics

Of the 62 patients in the review, 33 (53%) were male; the patients were between 1 (youngest) and 95 (oldest) years of age, and the mean patient age at diagnosis was 54.85 years (\pm 21.72). A number of reported PVA cases per year is shown in Figure 1.

In terms of aetiology, the frequency of congenital PVAs was 29 (46.7%), and it was 17 (27.4%) for acquired PVAs. In 16 (25.8%) patients, the aetiology of the PVAs was unclear. Regarding the location of PVAs, 27.41% were at the level of the splenomesenteric confluence; 19.35% were at the main trunk; 17.74% were at branches; 6.45% were at the PV bifurcation; 6.45% were at the SV; and 4.83% were at the SMV; 14.51% were classified as intrahepatic PVAs. A retrospective study by Ahmed *et al*[2] included 18 patients [13 of whom were female (72.2%)], aged between 20 years and 101 years, with an average age of 56 years. Our review also covered three patients (all male) with a PV pseudoaneurysm resulting from trauma.

Etiopathogenesis

The aetiology of PVA is not clear. Postulated origins include both congenital and acquired causes. It is well known that the main cause of acquired PVA is chronic liver disease (cirrhosis and fibrosis) with portal hypertension. Long-standing portal hypertension causes intimal thickening with compensatory

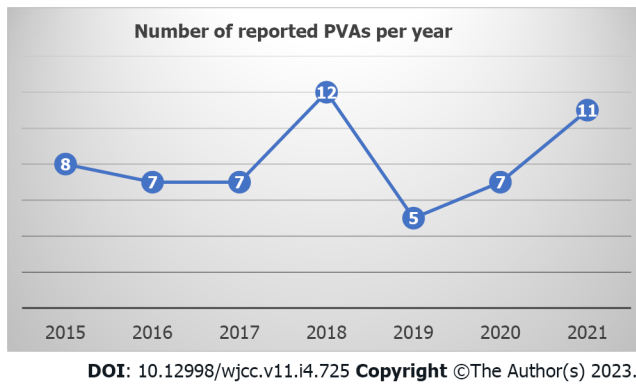


Figure 1 Number of reported portal vein aneurysms per year, from January 2015 until December 2021. PVA: Portal vein aneurysms.

medial hypertrophy of the PV. Over time, medial hypertrophy is replaced by fibrous tissue, leading to weakening of the vein wall, thus making it susceptible to aneurysmal dilatation[12,13]. However, the incidence of portal hypertension and PVA is disproportionate, suggesting the existence of other contributory factors.

Acquired PVA can also be part of severe acute pancreatitis, likely to be due to leakage of digestive enzymes, causing localized inflammation of the PV. Malignancy was also noted as a cause of acquired PVA[1].

In several reports[69-71] a pseudoaneurysm of the PV is defined as post-traumatic (surgical pancreatic procedure, liver transplantation, or other rare clinical situations) uncommon finding (dilation) of the portal venous system. It is a serious condition followed life-threatening complications requiring an interventional approach.

In relation to a new acquired aetiology of PVA, the following conditions were noted: Budd-Chiari syndrome[14], splenomegaly in thalassaemia major[15] and giant splenic artery aneurysm[16]. Long-term cholelithiasis was also considered as a possible cause of PVA[17].

Some PVAs are congenital. During gestation, three pairs of veins are developed: The cardinal veins, umbilical veins and vitelline veins. The PV, hepatic veins and part of the inferior cava vein (ICV) come from umbilical veins and vitelline veins. Generally, cranial segments of the left vitelline vein and caudal segments of the right vitelline vein regress during the foetal period, and the SV and SMV are derived from the left vitelline vein[18].

Evidence supporting a congenital cause includes reported cases of *in utero* diagnosis of PVA, evidence of PVA in patients with histologically proven normal livers (particularly in children and young adults), normal portal venous pressure in the presence of a PVA, and the frequent stability of aneurysms at follow-up imaging. Theories for a congenital cause involve inherent weakness in the vessel wall or incomplete regression of the distal right primitive vitelline vein, leading to a vascular diverticulum that ultimately develops into an aneurysm. Congenital PVAs are usually incidentally diagnosed later in life (not in neonatal or paediatric age groups) when an abdominal ultrasound is carried out because of some other indication[4,6,19]. Burdall *et al*[20] evaluated the relation between trisomy 21 (Down's syndrome) and congenital vascular malformation of the liver in a study of 45 children, seven of whom had vascular malformation and two of whom had evidence of a PVA.

Clinical presentation of patients with a PVA

The clinical presentation of PVA is controversial and poorly understood. According to the review article by Laurenzi *et al*[1], 30% of patients with a PVA were asymptomatic, and 50% experienced non-specific abdominal pain. In our review, we found that up to 25% of patients were asymptomatic; for 15% of patients, the authors did not provide clear presenting symptoms relating to the PVA, and approximately 30% of patients experienced non-specific abdominal pain. In patients with a PVA, the nature of non-specific abdominal pain should be clarified. The main question is whether PVA low-pressure truly the source of the pain; gastritis, duodenitis and cholecystitis, *etc.*, should be ruled out. A retrospective study by Ahmed *et al*[2] showed that in eight (44.4%) patients with abdominal pain, a PVA was actually the source of the pain in only one patient.

Up to 10% of cases involve portal hypertension, gastrointestinal bleeding (varices) or presenting symptoms related to compression of adjacent organs (abdominal swelling or jaundice)[1]. With a PVA, presenting symptoms or complications such as portal hypertension and bleeding are discussible. One thing that should be clarified is whether a PVA is a consequence of portal hypertension or whether the PVA is causing portal hypertension. Khan *et al*[16] found coexistence of a giant splenic artery aneurysm, portal hypertension without liver cirrhosis and a PVA at the level of bifurcation. In this case, the PVA and portal hypertension were presumed to be secondary to the pressure effect from the splenic artery aneurysm. Güngör *et al*[21] presented an 11-mo-old girl with a congenital PVA, and oesophageal and

fundal varices with bleeding. This was the only case in our review where PVA caused portal hypertension complications.

Clinical presentation has a close relation with morphology, size and location of the PVA. When it grows, there can be contact with the biliary tract, the ICV and duodenum, *etc.*, and complications can arise from compression of these organs. Six patients in our review (9.67%) had compression complications, including four biliopathies[22-25], one thrombosis in the ICV[7] and one intestinal obstruction [19].

Laurenzi *et al*[1] reported PVA complications such as thrombosis (which happened in 20% of cases) and a rupture (which occurred twice). A recent retrospective study by Ahmed *et al*[2] reported 18 patients with a PVA; 22.22% of patients had thrombosis, and no ruptures were reported. PVA with a complication of thrombosis is reported in the literature as nearly always being symptomatic, with 91% of patients reporting abdominal pain, 53% reporting fever and 38% presenting with ascites[26].

In our review, thrombosis occurred in 12 (19.35%) patients (six of whom were female), with a median age of 38.33 years. Abdominal pain was reported in 10 of 12 patients; in a one-year-old girl, the symptoms manifested as haematemesis and melena[21]; a 69-year-old female with a congenital PVA followed by thrombosis did not experience any symptoms[5]. In five patients, treatment was based on anticoagulation medication; seven patients underwent open surgery or invasive radiology procedures. In our review, a rupture as a complication of a PVA was not reported.

Patients with a PVA have a normal laboratory results, including complete blood count, inflammatory parameters, basic metabolic profile and liver function tests[1].

Imaging of PVA

Increased use of abdominal cross-sectional imaging in recent years has led to a growing number of cases describing PVA, and as such, proper handling of this lesion is increasingly relevant to both diagnostic and interventional radiologists. Evaluation of PVA by multiple imaging modalities is important because a PVA can mimic solid, cystic or hypervascular abdominal masses[1-7].

Sonography assessment can be performed for differential diagnosis to determine whether anechoic area or cyst at porta hepatis are PVA, hepatic artery aneurysm or choledochal cyst. Abdominal ultrasound based on the greyscale of the PVA produces an anechoic structure with a “smoke effect” within, which simulates a natural contrast agent, determined by slowed venous flow (Figure 2A). Spectral Doppler sonography reveals the presence of a monophasic, non-pulsatile venous flow pattern inside the aneurysm (Figure 2B). With colour Doppler sonography of a PVA, anechoic areas will be completely filled, looking like the Korean flag or a “yin-yang” sign. Hepatic artery aneurysms show a colour flow with arterial waveform, but choledochal cysts do not show such colour flow and are connected to biliary channels[6,15].

Contrast-enhanced CT with angiography shows the filling of PVA. On a CT and magnetic resonance imaging (MRI) scan, a PVA will appear as a well-defined contrast-enhanced focal saccular anomaly or fusiform dilatation of the portal venous system during the portal venous phase[4,27].

In one case, CT angiography facilitated better assessment of the portal venous system, which contained some thin calcifications in the aneurysmal wall and the main portal trunk[13]. Iimuro *et al*[28] presented “computational fluid dynamics software”, analyzing the haemodynamics of the portal venous system, including congenital saccular PVA at the level of confluence. Turbulent flow was obvious in PVA, and the wall shear stress against the upper-posterior part of the aneurysm wall was greater than in other parts of the aneurysm. In order to prevent the PVA from growing and avoid thrombosis or a rupture, an aneurysmectomy of the PVA was performed.

The diagnostic role of endoscopic ultrasound (EUS) was highlighted in congenital PVA at the level of the splenomesenteric confluence. EUS confirmed the presence of anechoic lesions adjacent to the neck of the pancreas[29]. EUS as a diagnostic tool was also used for assessment of an intrahepatic aneurysmal portosystemic venous shunt[30].

“Intraductal ultrasonography” (IDU) was used for the first time to identify an adjacent PVA as the cause of a common hepatic duct stricture, showing a lobulated hypoechoic mass containing a mobile echogenic substance, outside of the biliary tract, highly suggestive of a vascular lesion[24].

Management and treatment of PVA

Because of their rarity, the natural history of PVA remains unclear, and the optimal strategy for management is controversial. Following diagnosis of a PVA, treatment will depend on the size, presenting symptoms and location of the PVA, and comorbidities.

If the PVA is asymptomatic (as in 30% of cases), it does not require any active treatment, and monitoring (a policy of “wait and see”) should be adopted[1]. While asymptomatic aneurysms smaller than 30 mm can be clinically observed, surgical intervention may be necessary in large asymptomatic aneurysms (> 30 mm)[1,10]. The origin, morphology and symptomatology of a PVA, along with comorbidities and conservative treatment, are shown in Table 1.

Where there is thrombosis due to a PVA, anticoagulation treatment should be considered. In a recently published case, a 10-year-old boy with PVA thrombosis was treated with enoxaparin. The thrombosis disappeared completely after 6 mo[31]. In a case involving biliopathy, where the PVA comprised hepatic ducts, ursodeoxycholic acid was used to decrease the level of conjugated bilirubin

Table 1 Clinical features of the patients with portal vein aneurysm, regards the conservative treatment

Year	Ref.	Gender	Age	Etiology	Location	Morphology/size	Symptomatology	Complications	Comorbidity	Imaging	Treatment	Follow-up
2015	Prabhakar <i>et al</i> [48]	Male	47	None	Intrahepatic, left br	18 mm			Shunt	CT	Surveillance	Alive
2015	Srikanth <i>et al</i> [49]	Female	12	Congenital	Right branch	Saccular				US, CT	Surveillance	
2015	Starikov <i>et al</i> [50]	Male	27	None	SMV aneurysm	86 mm	Abdominal pain	Thrombosis CTPV	Acute pancreatitis	CT, MRI	Anticoagulation	24 mo
2016	Gaba <i>et al</i> [3]	Female	61	None	Confluence	50 mm			Ca colon; surgery	US, CT	Surveillance	
2016	Hanafiah <i>et al</i> [12]	Male	70	Acquired	Right branch	Fusiform, 22 mm			HBV; cirrhosis, HCC	US, CT	No treatment	Died
2016	Nayman <i>et al</i> [51]	Female	48	Congenital	Intrahepatic, two br	Right 43, left 13 mm	Abdominal pain			US, CT	Surveillance	
2016	Kurtcehajic <i>et al</i> [22]	Female	75	Congenital	Bifurcation	Saccular	Jundice	Biliopathy		US, CT, MRI	Usodeoxolic acid	Alive
2016	Khairallah <i>et al</i> [13]	Female	68	Acquired	Bifurcation	Fusiform, 40 mm	Bleeding		Cirrhosis; portal Hyp	US, CT	No treatment	
2017	Jaiswal <i>et al</i> [52]	Female	59	Congenital	Confluence	53.7 mm	Abdominal pain		Cholelithias	US, CT	Surveillance	18 mo
2017	Guilbaud <i>et al</i> [53]	Male	88	Congenital	Main trunk	Saccular, 59 mm			Cholecystectomy	CT	Surveillance	
2018	Maia <i>et al</i> [54]	Female	67	Congenital	Main trunk	35 mm	Abdominal pain		Diabetes, arterial Hyp	US, CT	Surveillance	12 mo
2018	Ashmore <i>et al</i> [55]	Female	62	None	Confluence		Abdominal pain			CT	Surveillance	
2018	Martínez <i>et al</i> [56]	Female	29	Congenital	Left branch	Saccular, 28 mm				US, CT	Surveillance	
2018	Hirji <i>et al</i> [57]	Male	62	Congenital	Confluence	50 mm			Diabetes, Parkinson	CT	Surveillance	6 mo
2018	Alur <i>et al</i> [58]	Female	45	Congenital	Left branch	21.5 mm				US, MRI	Surveillance	
2018	Chaubard <i>et al</i> [59]	Male	66	Congenital	Confluence	Saccular, 40 mm	Abdominal pain		T-cell hemopathy	US, CT	Surveillance	
2019	Ramamoorthy <i>et al</i> [60]	Female	42	Congenital	Confluence	Fusiform, 26 mm	Abdominal pain			US, MRI	Surveillance	Alive
2019	De Vloo <i>et al</i> [4]	Male	67	None	Confluence	Fusiform, 55 mm	Abdominal pain	Thrombosis CTPV	Neuroendocrine tm	US, CT	Anticoagulation	
2020	Kabir <i>et al</i> [61]	Male	77	Congenital	Intrahepatic, left br	28 mm	Abdominal pain		Abd. aortic aneurysm	US, MRI	Surveillance	3 mo
2020	Rana <i>et al</i> [29]	Female	51	Congenital	Confluence	38 mm	Abdominal pain			US, EUS, CT	Surveillance	30 mo
2020	Shams <i>et al</i> [62]	Male	67	None	SMV aneurysm		Abdominal pain	Thrombosis			Anticoagulation	12 mo
2020	Watanabe <i>et al</i> [5]	Female	69	Congenital	Right branch	35 mm		Thrombosis		US, CT	Surveillance	120 mo
2020	Schilardi <i>et al</i> [6]	Male	86	Congenital	Right branch	55 mm			Heart failure; COPD	US, CT	Surveillance	24 mo
2021	Hernando <i>et al</i> [63]	Female	51	Congenital	Right branch	25 mm	Abd. pain, jundice		Choledocholithiasis	US, MRI	Surveillance	

2021	Priadko <i>et al</i> [32]	Male	81	Acquired		48 mm		HBV, cirrhosis	US	Surveillance	36 mo
		Female	52	None		Saccular, 42.3 mm			US, CT, MRI	Surveillance	60 mo
		Male	73	None	Intrahepatic, right br	27 mm			US	Surveillance	12 mo
2021	Tan <i>et al</i> [64]	Male		Congenital	Main trunk	26 mm			CT	Surveillance	Alive
2021	López <i>et al</i> [65]	Female	41	None	SMV aneurysm	43 mm	Abdominal pain	Splenorenal shunt	CT	Surveillance	
2022	Tri <i>et al</i> [31]	Male	10	Congenital	Main trunk	36 mm	Abdominal pain	Thrombosis	CT	Anticoagulation	6 mo
2022	Villani <i>et al</i> [66]	Male	73	Acquired	Main trunk	Saccular, 40 mm		Cirrhosis, ascites	US, CT	Surveillance	
2022	Mortazavi <i>et al</i> [67]	Male	49	Congenital	Main trunk	21 mm	Abdominal pain	Cholelithias	CT	Surveillance	
2022	Mohamadnejad <i>et al</i> [30]	Female	76	None	Intrahepatic, left br	25 mm		Aneurysm, shunt	CT, EUS	Surveillance	
2022	Kanamalla <i>et al</i> [7]	Male	95	Congenital	Confluence	Saccular, 35 mm		Thrombosis of ICV	Diabetes, arterial Hyp	CT	Anticoagulation

Abd: Abdominal; br: Branch; Ca: Carcinoma; COPD: Chronic obstructive pulmonary disease; CT: Computed tomography; CTPV: Cavernous transformation of the portal vein; EUS: Endoscopic ultrasound; HBV: Hepatitis B virus; HCC: Hepatocellular carcinoma; Hyp: Hypertension; ICV: Inferior cava vein; MRI: Magnetic resonance imaging; SMV: Superior mesenteric vein; tm: tumor; US: Ultrasound.

[22].

While, in some studies, a CT scan every 12 mo was the preferred monitoring strategy, most published studies indicate that sonography is the preferred imaging technique for monitoring PVA growth, as it is relatively inexpensive and does not involve radiation exposure[32].

Open surgery approach: If the PVA is growing and constricting adjacent organs, thrombosis occurs, aiming to prevent potential rupture, open surgery methods should be considered. An aneurysmectomy for fusiform aneurysms (aneurysm resection, followed by insertion of a synthetic or cadaveric graft as a replacement conduit) and an aneurysmorrhaphy for saccular aneurysms (restores the normal diameter of the portal vein, if the remaining venous wall is of good quality) are considered for symptomatic aneurysms and to prevent a negative PVA prognosis.

The origin, morphology, PVA symptomatology and comorbidities as regards invasive treatment are shown in Table 2.

Fleming *et al*[33] demonstrated the efficacy of open surgery (aneurysmectomy) in three cases (two patients with an autograft and one with ePTFE). The two women with an autogenous graft remained asymptomatic at 85 mo and 65 mo, respectively; the third woman with ePTFE got thrombosis during pregnancy. The same report also included an aneurysmorrhaphy as the chosen treatment in one woman with a PVA.

Kim *et al*[34] presented a case with a PVA at the level of the main trunk, growing and with thrombosis complications. An aneurysm excision with an interposition bypass was successfully performed. The patient's postoperative recovery was rapid and uneventful, with normal portal flow revealed by colour Doppler ultrasonography and a contrast-enhanced CT scan.

Table 2 Clinical features of the patients with portal vein aneurysm, regards the surgery/invasive treatment

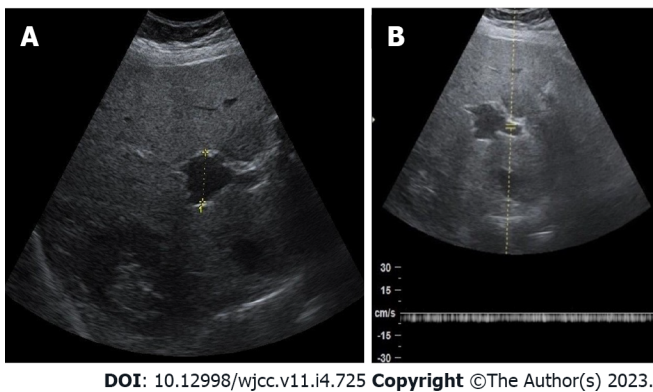
Year	Ref.	Gender	Age	Etiology	Location	Morphology /size	Symptomatology	Complications	Comorbidity	Imaging	Treatment	Follow-up
2015	Fleming <i>et al</i> [33]	Female	70	None	Confluence, SMV	From 30 mm to 50 mm				CT	Aneurysmectomy	85 mo
		Female	47	None	Confluence, SMV	From 35 mm to 60 mm	Abdominal pain		HCV	US, CT	Aneurysmectomy	65 mo
		Female	29	None		40 mm	Abdominal pain	Thrombosis/CTPV		CT	Aneurysmectomy	144 mo
		Female	49	None	Confluence, SMV	40 mm	Abdominal pain				Aneurysmorrhaphy	17 mo
2015	Tsauo <i>et al</i> [14]	Female	65	Acquired	Right branch	Saccular, 32 mm	Abdominal pain		Budd Chiari Sy	CT	TIPS	12 mo
2016	Khan <i>et al</i> [16]	Female	40	Acquired	Bifurcation	34 mm			Splenic artery aneurysm	US, CT	Aneurysmectomy	Alive
2016	Ierardi <i>et al</i> [69]	Male	42	Car accident	Confluence	PSA, 23 mm	Abdominal pain		Liver trauma	CT	Expanding stent graft	13 d
2016	Shukla <i>et al</i> [39]	Male	55	None	Intrahepatic, right br	Saccular, 30 mm			Sigmoid hemicolectomy	CT	Percut embolisation	Alive
2017	Shrivastava <i>et al</i> [27]	Male	55	Acquired	Intrahepatic, right br	62 mm			Portal Hyp, pancreatitis	US, CT	Percut embolisation	12 mo
2017	Ding <i>et al</i> [45]	Male	48	Acquired	Bifurcation	70 mm			HBV, cirrhosis	CT	TIPS	72 mo
2017	Kim <i>et al</i> [34]	Female	34	Congenital	Main trunk	Fusiform, from 57 mm to 62 mm	Abdominal pain	Thrombosis	Celiac artery dissection	US, CT	Aneurysmectomy	6 mo
2017	Das <i>et al</i> [15]	Female	18	None	Confluence	Fusiform, 30 mm			Thalassemia major	US, CT	Splenectomy	
2017	Ding <i>et al</i> [23]	Male	80	Acquired	Left branch	Fusiform	Abd. pain, jaundice	Biliopathy	Cirrhosis, portal Hyp.	US, CT, MRI	ERCP, biliary stent	3 mo
2018	Walton <i>et al</i> [70]	Male	42	Percut Biopsy	Main trunk	PSA, 13 mm	Haemobilia		Lymphomatosis of pancreas		Percut, covered stent	
2018	Kimura <i>et al</i> [44]	Male	62	Acquired	Branch	40 mm			HCV, HCC, art portal fistula	MRI	Selective embolisation	
2018	Sun <i>et al</i> [24]	Male	85	Congenital	Main trunk	32 mm	Abdominal pain	Cholangitis	Diabetes, ulcer disease	IDUS, CT	ERCP, biliary stent	42 mo
2018	Chandran <i>et al</i> [19]	Male	1	Congenital				Colonic obstruction			Ligation of PVA	3 mo
2018	Chadha <i>et al</i> [35]	Male	66	Acquired	SV aneurysm	39 mm			HCV, cirrhosis		External Sundt carotid shunt	6 mo

2018	Güngör <i>et al</i> [21]	Female	1	Congenital	Intrahepatic, right br	Fusiform	Hematemesis, melena	Portal Hyp, thrombosis		US, CT	Sugiura oper	
2018	Ktenidis <i>et al</i> [36]	Male	43	Acquired	SV aneurysm	98 mm			Splenectomy, AV shunt	CT	Open surgery	Alive
2019	Cleveland <i>et al</i> [71]	Male	68	Vehicle collision		PSA	Abdominal pain	Shock bowel		CT		Dead
2019	Juscafresa <i>et al</i> [40]	Female	77	Acquired	SV aneurysm	45 mm			Pancreatitis	CT	Percut, Viabahn stent	12 mo
2019	Bremer <i>et al</i> [42]	Male	65	Acquired	Intrahepatic, right br	64 mm	Abdominal pain		Cirrhosis, transplantation		TAE, stent graft exclusion	6 mo
2019	Oguslu <i>et al</i> [43]	Female	58	Acquired	Left branch	Saccular, 130 mm	Abdominal pain	Thrombosis	Art. portal fistula, portal Hyp	US, CT	Percut embolisation	9 mo
2020	Field <i>et al</i> [25]	Male	25	Congenital	Main trunk	55 mm	Abdominal pain	Biliopathy, thrombosis		CT, MRI	Thrombolysis, thrombectomy	12 mo
2021	Sura <i>et al</i> [38]	Male	80	Congenital	Main trunk	Saccular, 37 mm			Diaphragmatic hernia	CT	Open surgery	6 mo
2021	Marmor <i>et al</i> [41]	Male	67	Congenital	SV aneurysm	Saccular, 40 mm			Ca bladder	CT	Balloon expandable stent	12 mo
2021	Matsumoto <i>et al</i> [68]	Male	75	Acquired	Main trunk	42 mm	Abdominal pain		Ca pancreas	CT	Open surgery, omental graft	3 mo
2021	Gorolay <i>et al</i> [37]	Female	36	Congenital	Confluence	Saccular, from 45 mm to 65 mm	Abdominal pain	Thrombosis		US, CT	Hybrid operative repair	36 mo
2021	Dunlap <i>et al</i> [46]	Male	32	Acquired	Confluence	From 52 mm to 57 mm			Cirrhosis, portal Hyp		TIPS	6 mo
2022	Kohlbrener <i>et al</i> [47]	Male	37	Congenital	Confluence	Fusiform, 51 mm	Abdominal pain	Thrombosis, ischemia		CT	Thrombolysis, TIPS	24 mo

Abd: Abdominal; art: Artery; br: Branch; Ca: Carcinoma; CT: Computed tomography; CTPV: Cavernous transformation of the portal vein; ERCP: Endoscopic retrograde cholangiopancreatography; HBV: Hepatitis B virus; HCC: Hepatocellular carcinoma; HCV: Hepatitis C virus; Hyp: Hypertension; IDUS: Intraductal ultrasonography; MRI: Magnetic resonance imaging; percut: percutaneous; PSA: Pseudoaneurysm; PVA: Portal vein aneurysm; SMV: Superior mesenteric vein; SV: Splenic vein; Sy: Syndrome; TAE: Transarterial embolisation; TIPS: Transjugular intrahepatic portosystemic shunt; US: Ultrasound.

Khan *et al*[16] presented a case where splenomegaly, a giant splenic artery aneurysm and a PVA were found to coexist. The patient underwent a splenectomy and excision of the splenic artery aneurysm. It was determined that her PVA shrank considerably. Das *et al*[15] presented a case with thalassaemia major, splenomegaly and a PVA. After a splenectomy (necessitated by the existence of hypersplenism), the PVA significantly reduced.

Chadha *et al*[35] reported the case of a 66-year-old male with an acquired SV aneurysm and described novel use of a “Sundt external carotid endarterectomy shunt” as a temporary portacaval shunt to control portomesenteric hypertension, before transplantation of the liver. A giant SV aneurysm 98 mm in size



DOI: 10.12998/wjcc.v11.i4.725 Copyright ©The Author(s) 2023.

Figure 2 Sonography assessment of portal vein aneurysm. A: Abdominal ultrasound shows portal vein aneurysm (PVA) at the level of bifurcation; B: Spectral Doppler sonography shows nonpulsatile blood flow through the portal venous system with PVA.

developed as a consequence of a splenectomy, an arteriovenous fistula and portal hypertension; this aneurysm was treated successfully with open surgery[36].

Male and female patients, both of whom had a congenital PVA and subsequent thrombosis complications, were treated with a hybrid operative repair involving a transhepatic catheter thrombectomy, and their aneurysms were operated on in open surgery[25,37].

The limited number of PVAs that have been reported means that there are no clear indications for open surgery on PVA. Koc *et al*[10] studied the size of PVA and concluded that aneurysms larger than 30 mm should be surgically treated with the aim of preventing thrombosis or rupture. On the other hand, a recently reported case of a patient with a congenital PVA 35 mm in size, with subsequent thrombosis complications, showed spontaneous resolution after 10 years[5].

Sura *et al*[38] reported the case of an 80-year-old man who had open surgery on a 37-mm PVA at the level of the main trunk. The reasons for PVA surgery were not postulated, but given the congenital origin, advanced age of the patient and absence of symptoms or thrombosis, it is our view that surgery was not the best treatment choice.

Interventional radiology procedures: In cases where a PVA is a consequence of portal hypertension and/or coexists with life-threatening conditions (injuries), the high risk associated with open surgery methods means that interventional radiology procedures *via* a percutaneous approach, endovascular approach and even more endoscopic approach should be considered[1,2].

Percutaneous approach: Shukla *et al*[39] successfully demonstrated percutaneous embolization of a saccular intrahepatic PVA, which prevented further growth or other clinical sequelae. Shrivastava *et al* [27] presented the largest intrahepatic PVA and the first case where the endovascular technique was used for treatment of the same. Under sonography and fluoroscopy guidance, the PVA was directly punctured with an 18G needle and embolized with a Lipiodol-Glue combination.

Juscafresa *et al*[40] reported the case of an elderly female treated for an acquired SV aneurysm 45 mm in size, through a transhepatic percutaneous approach, using a Viabahn covered stent. Marmor *et al*[41] presented the case of a patient with a congenital SV aneurysm 40 mm in size. Because the aneurysm was getting larger, it was treated with an expandable stent *via* a transhepatic approach.

In one case, after liver transplantation necessitated by HCV cirrhosis, the patient subsequently developed an arteriportal fistula with an intrahepatic PVA. The first step of the treatment was transarterial embolization, and the second step was stent graft exclusion of the PVA. As there was leakage, the patient underwent liver re-transplantation[42]. Oguslu *et al*[43] demonstrated two techniques for treatment of an arteriportal fistula with a giant saccular PVA at the level of the left branch. After failure of an endovascular approach due to tortuosity and angulation of the celiac artery, access to the hepatic artery was obtained directly *via* a percutaneous transhepatic route, and the fistula site was embolized with an Amplatzer Vascular Plug II and coils.

Treatment of portal vein pseudoaneurysm: Our review covered three patients (all males) with a PV pseudoaneurysm, all of which were a consequence of abdominal trauma or injury. In a patient with a traumatic pseudoaneurysm at the level of the splenomesenteric confluence, Ierardi *et al*[69] demonstrated a novel management strategy with a percutaneous transhepatic self-expanding stent graft.

A patient with a PV pseudoaneurysm at the level of the main trunk, resulting from invasive medical procedures [*e.g.*, a percutaneous biopsy or endoscopic retrograde cholangiopancreatography (ERCP)] to address lymphomatous infiltration of the pancreatic head (with symptoms of haemobilia), was treated using percutaneous transhepatic covered stenting[70].

In the last case, involving a patient with a pseudoaneurysm of the portal venous system resulting from a motor vehicle collision, the patient was brought into the emergency department with diffuse abdominal pain and bowel shock. Unfortunately, the patient soon succumbed to his injuries[71].

Endovascular approach: Gaining access to the treatment zone can be challenging, and the target vessel may have tortuosity and elongation due to haemodynamic changes created by the hyperdynamic flow. Kimura *et al*[44] presented a case involving a hepatectomy (hepatocellular carcinoma), where the patient subsequently developed an arteriportal fistula with hepatofugal flow and a 40-mm-diameter PVA. After selective embolization of the anterior hepatic artery, the PVA disappeared, and portal flow was normalized.

An endovascular approach includes creation of a transjugular intrahepatic portosystemic shunt (TIPS). In patients with portal hypertension, an attempt may be made to decrease portal venous pressure in order to reduce the size of the aneurysm. Our review covered four patients with a PVA where the treatment of choice was a TIPS. Tsao *et al*[14] presented a case involving a PVA resulting from portal hypertension associated with Budd-Chiari syndrome. For the first time, a TIPS was created without complications. The patient's abdominal pain completely ceased within two days, and she remained asymptomatic during the one-year follow-up. Ding *et al*[45] presented a case with a PVA at the level of bifurcation, with comorbidities such as portal hypertension, liver cirrhosis and HBV chronica. A TIPS successfully decreased the patient's portal hypertension and reduced the size of the PVA from 53 mm × 76 mm to 23 mm × 25 mm. Two years later, a CT scan and digital subtraction angiography revealed that the aneurysm had disappeared. The patient remained asymptomatic for 72 mo[45]. Dunlap *et al*[46] also used a TIPS successfully to treat a PVA resulting from portal hypertension and liver cirrhosis. Kohlbrenner *et al*[47] demonstrated transhepatic pharmacomechanical thrombolysis of a large thrombosed PVA. This was followed by insertion of a TIPS, along with an additional trans-TIPS thrombectomy to improve sluggish portal outflow and prevent re-thrombosis. Nine months later, an MRI showed complete resolution of the thrombosis.

Endoscopic approach via ERCP: In older patients with a PVA and complication of biliopathy and jaundice, ERCP with biliary stenting can be an appropriate treatment choice. In an 80-year-old male with liver cirrhosis and portal hypertension, an acquired PVA at the level of the left branch was found. The patient had developed biliopathy due to compression of the common bile duct; this complication was successfully treated endoscopically via ERCP with a biliary stent[23]. Sun *et al*[24] reported the case of an 85-year-old man with cholangitis complications from PVA-induced compression. Given the age of the patient, surgery was not considered, and instead an ERCP biliary stent was deployed several times.

CONCLUSION

PVA is a rare morphological abnormality of the portal venous system, accounting for 3% of all venous aneurysms in the human body. The number of reported PVAs across the world now stands at about 280: The 200 PVAs covered in the previous review published in 2015[1], the 18 cases in the retrospective study[2] and the 62 PVAs in our review covering the last seven years. PVA can be congenital or acquired, located mainly at the level of confluence, main trunk, branches and bifurcation. Up to 30% of patients can be asymptomatic, and non-specific abdominal pain should be investigated to exclude other pathological causes, such as cholecystitis or peptic ulcer disease, *etc.* Thrombosis complications occur in approximately 19%-23% of patients, and biliopathy occurs in approximately 4%-6% of patients. Other complications can also arise from compression due to a PVA, including thrombosis of the ICV and intestinal obstruction. Diagnosis of a PVA is based on spectral and colour Doppler sonography, and CT and MRI. EUS and IDU have also been used as a diagnostic tool. If a PVA is asymptomatic, it does not require any active treatment, and monitoring (a policy of "wait and see") should be adopted. The first choice for treatment of PVA thrombosis is anticoagulation medication. If the PVA is getting larger and compressing adjacent organs, thrombosis will occur, so to prevent a potential rupture, open surgery methods such as an aneurysmectomy or an aneurysmorrhaphy should be considered. Given the risk associated with open surgery methods, interventional radiology procedures via a percutaneous approach, endovascular approach or, better still, an endoscopic approach should be considered for cases where a PVA is a consequence of portal hypertension and/or coexists with life-threatening conditions (injuries).

FOOTNOTES

Author contributions: Kurtcehajic A, Alibegovic E, and Fejzic AJ designed, edited and wrote the manuscript; Kunosic S and Hujdurovic A performed the collection of the data and designed appearance of the tables; Zerem E contributed to the critical revision and editing of the paper; all authors wrote, read, and approved the final version of the manuscript.

Conflict-of-interest statement: There are no conflicts of interest to report.

Open-Access: This article is an open-access article that was selected by an in-house editor and fully peer-reviewed by external reviewers. It is distributed in accordance with the Creative Commons Attribution NonCommercial (CC BY-NC 4.0) license, which permits others to distribute, remix, adapt, build upon this work non-commercially, and license their derivative works on different terms, provided the original work is properly cited and the use is non-commercial. See: <https://creativecommons.org/licenses/by-nc/4.0/>

Country/Territory of origin: Bosnia and Herzegovina

ORCID number: Admir Kurtcehajic 0000-0002-6445-4090; Enver Zerem 0000-0001-6906-3630; Suad Kunosic 0000-0002-5211-4099.

S-Editor: Chen YL

L-Editor: A

P-Editor: Chen YL

REFERENCES

- 1 **Laurenzi A**, Ettore GM, Lionetti R, Meniconi RL, Colasanti M, Vennarecci G. Portal vein aneurysm: What to know. *Dig Liver Dis* 2015; **47**: 918-923 [PMID: 26188840 DOI: 10.1016/j.dld.2015.06.003]
- 2 **Ahmed O**, Ohman JW, Vachharajani N, Yano M, Sanford DE, Hammill C, Fields RC, Hawkins WG, Strasberg SM, Doyle MB, Chapman WC, Khan AS. Feasibility and safety of non-operative management of portal vein aneurysms: a thirty-five year experience. *HPB (Oxford)* 2021; **23**: 127-133 [PMID: 32561177 DOI: 10.1016/j.hpb.2020.05.006]
- 3 **Gaba RC**, Hardman JD, Bobra SJ. Extrahepatic Portal Vein Aneurysm. *Radiol Case Rep* 2009; **4**: 291 [PMID: 27307811 DOI: 10.2484/rcr.v4i2.291]
- 4 **De Vloo C**, Matton T, Meersseman W, Maleux G, Houthoofd S, Op de Beeck K, Laleman W, Van Malenstein H, Nevens F, Verbeke L, Van der Merwe S, Verslype C. Thrombosis of a portal vein aneurysm: a case report with literature review. *Acta Clin Belg* 2019; **74**: 115-120 [PMID: 30147008 DOI: 10.1080/17843286.2018.1511298]
- 5 **Watanabe Y**, Takase K, Okada K, Aikawa M, Okamoto K, Koyama I. Portal vein aneurysm with complete spontaneous regression after 10 years using conservative treatment. *Clin J Gastroenterol* 2020; **13**: 940-945 [PMID: 32449089 DOI: 10.1007/s12328-020-01131-6]
- 6 **Schilardi A**, Ciavarella A, Carbone M, Antonica G, Berardi E, Sabbà C. A large asymptomatic portal vein aneurysm in an old man. *Clin Case Rep* 2021; **9**: 15-18 [PMID: 33489127 DOI: 10.1002/ccr3.3365]
- 7 **Kanamalla K**, Alwakka H. Thrombosis of the inferior vena cava secondary to incidental portal vein aneurysm. *Radiol Case Rep* 2022; **17**: 1532-1535 [PMID: 35282317 DOI: 10.1016/j.radcr.2022.02.006]
- 8 **Douglass BE**, Baggenstoss AH, Hollinshead WH. The anatomy of the portal vein and its tributaries. *Surg Gynecol Obstet* 1950; **91**: 562-576 [PMID: 14787850]
- 9 **Doust BD**, Pearce JD. Gray-scale ultrasonic properties of the normal and inflamed pancreas. *Radiology* 1976; **120**: 653-657 [PMID: 948601 DOI: 10.1148/120.3.653]
- 10 **Koc Z**, Oguzkurt L, Ulsan S. Portal venous system aneurysms: imaging, clinical findings, and a possible new etiologic factor. *AJR Am J Roentgenol* 2007; **189**: 1023-1030 [PMID: 17954635 DOI: 10.2214/AJR.07.2121]
- 11 **BARZILAI R**, KLECKNER MS Jr. Hemocholecyst following ruptured aneurysm of portal vein; report of a case. *AMA Arch Surg* 1956; **72**: 725-727 [PMID: 13301133 DOI: 10.1001/archsurg.1956.01270220173023]
- 12 **Hanafiah M**, Johari B, Koshy M, Misni MN. Intrahepatic Portal Vein Aneurysm with Concurrent Hepatocellular Carcinoma. *Sultan Qaboos Univ Med J* 2016; **16**: e115-e116 [PMID: 26909202 DOI: 10.18295/squmj.2016.16.01.023]
- 13 **Khairallah S**, Elmansouri A, Jalal H, Idrissi MO, Ganouni NC. Calcified wall portal venous aneurysm: a case report. *Pan Afr Med J* 2016; **25**: 93 [PMID: 28292056 DOI: 10.11604/pamj.2016.25.93.9896]
- 14 **Tsao J**, Li X. Portal vein aneurysm associated with Budd-Chiari syndrome treated with transjugular intrahepatic portosystemic shunt: a case report. *World J Gastroenterol* 2015; **21**: 2858-2861 [PMID: 25759562 DOI: 10.3748/wjg.v21.i9.2858]
- 15 **Das S**, Dey M, Kumar V, Lal H. Portal vein aneurysm in thalassaemia. *BMJ Case Rep* 2017; **2017** [PMID: 28801322 DOI: 10.1136/bcr-2016-218551]
- 16 **Khan A**, Ayub M, Haider I, Humayun M, Shah Z, Ajmal F. Coexisting giant splenic artery and portal vein aneurysms leading to non-cirrhotic portal hypertension: a case report. *J Med Case Rep* 2016; **10**: 270 [PMID: 27686495 DOI: 10.1186/s13256-016-1059-4]
- 17 **Kurtcehajic A**, Alibegovic E, Hujdurovic A, Vele E, Kurtcehajic D. Role of Cholelithiasis in Development of Portal Vein Aneurysm. *Am J Med* 2018; **131**: e119 [PMID: 29454428 DOI: 10.1016/j.amjmed.2017.09.004]
- 18 **Kim SH**, Yu HW, Kim HY, Jo HS. Neonatal vitelline vein aneurysm with thrombosis: prompt treatment should be needed. *Ann Surg Treat Res* 2015; **89**: 334-337 [PMID: 26665130 DOI: 10.4174/ast.2015.89.6.334]
- 19 **Chandran S**, Kumar M, Jacob TJK, Mohamed F. Intestinal obstruction with a twist: a rare case of congenital portal vein aneurysm causing intestinal obstruction. *BMJ Case Rep* 2018; **2018** [PMID: 30244223 DOI: 10.1136/bcr-2018-225689]
- 20 **Burdall OC**, Grammatikopoulos T, Sellars M, Hadzic N, Davenport M. Congenital Vascular Malformations of the Liver: An Association With Trisomy 21. *J Pediatr Gastroenterol Nutr* 2016; **63**: e141-e146 [PMID: 27602703 DOI: 10.1097/MPG.0000000000001405]

- 21 **Güngör Ş**, Varol Fİ, Kutlu R, Yılmaz S, Selimoğlu MA. An intrahepatic Portal Vein Aneurysm Presenting with Esophageal Variceal Bleeding in a Pediatric Patient: A Rare Clinical Entity. *Balkan Med J* 2018; **35**: 442-444 [PMID: 29966998 DOI: 10.4274/balkanmedj.2017.1776]
- 22 **Kurtcehajic A**, Vele E, Hujdurovic A. Portal vein aneurysm and portal biliopathy. *J Hepatobiliary Pancreat Sci* 2016; **23**: 658 [PMID: 27561886 DOI: 10.1002/jhbp.383]
- 23 **Ding F**, Li Q, Duan X, Ye J. Hepatobiliary and Pancreatic: Ruptured aneurysm of intra-hepatic portal vein causing obstructive jaundice. *J Gastroenterol Hepatol* 2017; **32**: 1666 [PMID: 28948704 DOI: 10.1111/jgh.13837]
- 24 **Sun J**, Sun CK. Repeated Plastic Stentings of Common Hepatic Duct for Portal Vein Aneurysm Compression in a Patient Unsuitable for Surgery. *Case Rep Gastroenterol* 2018; **12**: 570-577 [PMID: 30323732 DOI: 10.1159/000492812]
- 25 **Field Z**, Madruga M, Carlan SJ, Abdalla R, Carbone J, Al Salihi H. Portal vein aneurysm with acute portal vein thrombosis masquerading as a pancreatic mass. *Hematol Oncol Stem Cell Ther* 2020 [PMID: 32561224 DOI: 10.1016/j.hemonc.2020.05.010]
- 26 **Chawla YK**, Bodh V. Portal vein thrombosis. *J Clin Exp Hepatol* 2015; **5**: 22-40 [PMID: 25941431 DOI: 10.1016/j.jceh.2014.12.008]
- 27 **Shrivastava A**, Rampal JS, Nageshwar Reddy D. Giant Intrahepatic Portal Vein Aneurysm: Leave it or Treat it? *J Clin Exp Hepatol* 2017; **7**: 71-76 [PMID: 28348475 DOI: 10.1016/j.jceh.2016.08.013]
- 28 **Imuro Y**, Suzumura K, Ohashi K, Tanaka H, Iijima H, Nishiguchi S, Hao H, Fujimoto J. Hemodynamic analysis and treatment of an enlarging extrahepatic portal aneurysm: report of a case. *Surg Today* 2015; **45**: 383-389 [PMID: 24633932 DOI: 10.1007/s00595-014-0882-8]
- 29 **Rana SS**, Dhalaria L, Sharma R, Gupta R. Extra-hepatic portal vein aneurysm diagnosed by EUS. *Endosc Ultrasound* 2020; **9**: 270-271 [PMID: 32687073 DOI: 10.4103/eus.eus_40_20]
- 30 **Mohamadnejad M**, Al-Haddad M. Intrahepatic aneurysmal portosystemic venous shunt diagnosed on EUS. *VideoGIE* 2022; **7**: 138-139 [PMID: 35937191 DOI: 10.1016/j.vgie.2021.12.010]
- 31 **Tri TT**, Duy HP, Trung BH, Thuan LA, Thach PN, Hien NX, Duc NM. A rare pediatric case of portal vein aneurysm thrombosis. *Radiol Case Rep* 2022; **17**: 286-289 [PMID: 34876951 DOI: 10.1016/j.radcr.2021.10.065]
- 32 **Priadko K**, Romano M, Vitale LM, Niosi M, De Sio I. Asymptomatic portal vein aneurysm: Three case reports. *World J Hepatol* 2021; **13**: 515-521 [PMID: 33959231 DOI: 10.4254/wjgh.v13.i4.515]
- 33 **Fleming MD**, Lall P, Nagorney DM, Gloviczki P, Kalra M, Duncan A, Oderich G, Toomey B, Bower TC. Operative interventions for extrahepatic portomesenteric venous aneurysms and long-term outcomes. *Ann Vasc Surg* 2015; **29**: 654-660 [PMID: 25770384 DOI: 10.1016/j.avsg.2015.01.029]
- 34 **Kim HJ**, Ha TY, Ko GY, Noh M, Kwon TW, Cho YP, Lee SG. A Case of Extrahepatic Portal Vein Aneurysm Complicated by Acute Thrombosis. *Ann Vasc Surg* 2017; **43**: 311.e9-311.e13 [PMID: 28478175 DOI: 10.1016/j.avsg.2017.01.020]
- 35 **Chadha RM**, Dougherty MK, Musto KR, Harnois DM, Nguyen JH. Temporary Portomesenteric Decompression for Splenic Vein Aneurysm During Orthotopic Liver Transplant. *Liver Transpl* 2018; **24**: 1485-1488 [PMID: 30129118 DOI: 10.1002/lt.25295]
- 36 **Ktenidis K**, Manaki V, Kapoulas K, Kourtellari E, Gionis M. Giant Splenic Aneurysm with Arteriovenous (A-V) Shunt, Portal Hypertension, and Ascites. *Am J Case Rep* 2018; **19**: 1410-1415 [PMID: 30478253 DOI: 10.12659/AJCR.911106]
- 37 **Gorolay V**, Nguyen D, Samra J, Neale M. Asymptomatic thrombosis of extrahepatic portal vein aneurysm necessitating hybrid operative repair. *Vascular* 2021; **29**: 762-766 [PMID: 33270525 DOI: 10.1177/1708538120976977]
- 38 **Sura TA**, Boutrous ML, Ruiz MI, Williams MS. Operative management of an incidental portal vein aneurysm in the setting of an incarcerated congenital diaphragmatic hernia. *J Vasc Surg Cases Innov Tech* 2021; **7**: 64-67 [PMID: 33665534 DOI: 10.1016/j.jvscit.2020.10.009]
- 39 **Shukla PA**, Kolber MK, Kumar A, Patel RI. Percutaneous Embolization of an Intrahepatic Portal Vein Aneurysm. *J Vasc Interv Radiol* 2016; **27**: 1747-1749 [PMID: 27926409 DOI: 10.1016/j.jvir.2016.01.132]
- 40 **Juscáfresa LC**, Alfaro MP, Grochowicz L, Lorenzo JIL, Jaureguizar JIB. Endovascular treatment of a splenic vein aneurysm through a transhepatic approach. *Diagn Interv Radiol* 2019; **25**: 166-168 [PMID: 30774093 DOI: 10.5152/dir.2019.18057]
- 41 **Marmor RA**, Goodman S, Parsa P. Endovascular Repair of Splenic Vein Aneurysm with Balloon Expandable Stent Placement. *Ann Vasc Surg* 2021; **73**: 554-556 [PMID: 33556510 DOI: 10.1016/j.avsg.2020.12.051]
- 42 **Bremer WA**, Lokken RP, Gaba RC, Bui JT. Arterial-portal fistula treated with hepatic arterial embolization and portal venous aneurysm stent-graft exclusion complicated by type 2 endoleak. *Radiol Case Rep* 2019; **14**: 1301-1305 [PMID: 31467626 DOI: 10.1016/j.radcr.2019.08.005]
- 43 **Ogustu U**, Uyanik SA, Gümüş B. Endovascular treatment of hepatic arteriportal fistula complicated with giant portal vein aneurysm via percutaneous transhepatic US guided hepatic artery access: a case report and review of the literature. *CVIR Endovasc* 2019; **2**: 39 [PMID: 32026997 DOI: 10.1186/s42155-019-0084-y]
- 44 **Kimura Y**, Hori T, Machimoto T, Ito T, Hata T, Kadokawa Y, Kato S, Yasukawa D, Aisu Y, Takamatsu Y, Kitano T, Yoshimura T. Portal vein aneurysm associated with arteriportal fistula after hepatic anterior segmentectomy: Thought-provoking complication after hepatectomy. *Surg Case Rep* 2018; **4**: 57 [PMID: 29904893 DOI: 10.1186/s40792-018-0465-9]
- 45 **Ding PX**, Han XW, Hua ZH. Extrahepatic Portal Vein Aneurysm at the Portal Bifurcation Treated with Transjugular Intrahepatic Portosystemic Shunt. *J Vasc Interv Radiol* 2017; **28**: 764-766 [PMID: 28431653 DOI: 10.1016/j.jvir.2016.12.1228]
- 46 **Dunlap R**, Golden S, Lyons GR. Portal Vein Aneurysm Treated With Trans-Jugular Intrahepatic Porto-Systemic Shunt. *Vasc Endovascular Surg* 2021; **55**: 885-888 [PMID: 34114524 DOI: 10.1177/15385744211023291]
- 47 **Kohlbreunner R**, Schwertner AB, Vogel AR, Conrad M, Lokken RP. Large thrombosed portomesenteric venous aneurysm treated with pharmacomechanical thrombolysis combined with TIPS placement. *CVIR Endovasc* 2022; **5**: 11 [PMID: 35133515 DOI: 10.1186/s42155-022-00288-0]
- 48 **Prabhakar N**, Vyas S, Taneja S, Khandelwal N. Intrahepatic aneurysmal portohepatic venous shunt: what should be done?

- Ann Hepatol* 2015; **14**: 118-120 [PMID: [25536649](#)]
- 49 **Srikanth KP**, Thapa BR. Aneurysm of Right Branch of Portal Vein in a Child. *Indian Pediatr* 2015; **52**: 440 [PMID: [26061939](#)]
 - 50 **Starikov A**, Bartolotta RJ. Massive superior mesenteric venous aneurysm with portal venous thrombosis. *Clin Imaging* 2015; **39**: 908-910 [PMID: [26001660](#) DOI: [10.1016/j.clinimag.2015.05.001](#)]
 - 51 **Nayman A**, Guler I, Koplay M, Erdogan H, Cebeci H. Intrahepatic Portal Vein Aneurysm : An Unusual Entity. *Acta Gastroenterol Belg* 2016; **79**: 385 [PMID: [27821039](#)]
 - 52 **Jaiswal P**, Yap JE, Attar BM, Wang Y, Devani K, Jaiswal R, Basu A, Mishra S. Massive Asymptomatic Extrahepatic Portal Vein Aneurysm. *Am J Med* 2017; **130**: e383-e386 [PMID: [28454904](#) DOI: [10.1016/j.amjmed.2017.04.002](#)]
 - 53 **Guilbaud T**, Birnbaum DJ, Duconseil P, Soussan J, Moutardier V. Portal vein aneurysm incidentaloma. *Surgery* 2017; **162**: 1177-1178 [PMID: [27871687](#) DOI: [10.1016/j.surg.2016.10.016](#)]
 - 54 **Maia L**, Castro-Poças FM, Pedoto I. Portal Vein Aneurysm Mimicking a Liver Nodule. *GE Port J Gastroenterol* 2018; **25**: 105-106 [PMID: [29662938](#) DOI: [10.1159/000480244](#)]
 - 55 **Ashmore S**, Stacy K. Aneurysm of the Splenomesenteric Portal Venous Confluence: A Case Report. *S D Med* 2018; **71**: 199-201 [PMID: [29999605](#)]
 - 56 **Martínez D**, Belmonte MT, Kosny P, Gómez MR, Hellin D. Aneurysm of the Left Portal Branch. *Eur J Case Rep Intern Med* 2018; **5**: 000868 [PMID: [30756043](#) DOI: [10.12890/2018_000868](#)]
 - 57 **Hirji SA**, Robertson FC, Casillas S, McPhee JT, Gupta N, Martin MC, Raffetto JD. Asymptomatic portal vein aneurysms: To treat, or not to treat? *Phlebology* 2018; **33**: 513-516 [PMID: [28950753](#) DOI: [10.1177/0268355517733375](#)]
 - 58 **Alur İ**, Us M. An incidental intrahepatic portal vein aneurysm. *Türk Gogus Kalp Damar Cerrahisi Derg* 2018; **26**: 681-682 [PMID: [32082819](#) DOI: [10.5606/tgkdc.dergisi.2018.16454](#)]
 - 59 **Chaubard S**, Lacroix P, Kennel C, Jaccard A. [Aneurysm of the portal venous system: A rare and unknown pathology]. *Rev Med Interne* 2018; **39**: 946-949 [PMID: [30146175](#) DOI: [10.1016/j.revmed.2018.07.007](#)]
 - 60 **Ramamoorthy E**, Kumar H, Gupta P. An Uncommon Portal Vein Abnormality. *Clin Gastroenterol Hepatol* 2019; **17**: e19-e20 [PMID: [29360510](#) DOI: [10.1016/j.cgh.2018.01.010](#)]
 - 61 **Kabir T**, Choke ETC, Kam JH. Unusual discovery in the liver: intrahepatic portal vein aneurysm. *ANZ J Surg* 2020; **90**: E28-E29 [PMID: [30977216](#) DOI: [10.1111/ans.15113](#)]
 - 62 **Shams T**, Hug M, Wolff T, Roduit J. [Superior mesenteric vein aneurysm, a rare case]. *Rev Med Suisse* 2020; **16**: 1652-1655 [PMID: [32914597](#)]
 - 63 **Hernando Sanz A**, Navarro-Aguilar V, López-Andújar R. Portal vein aneurysm, an update on the subject. A case report. *Rev Esp Enferm Dig* 2021; **113**: 77-78 [PMID: [33226247](#) DOI: [10.17235/reed.2020.6842/2019](#)]
 - 64 **Tan RLW**, Ng ZQ. Portal venous aneurysm. *BMJ Case Rep* 2021; **14** [PMID: [34330734](#) DOI: [10.1136/bcr-2021-244704](#)]
 - 65 **López-Fernández J**, García Plaza G, García Quesada SM, Hernández Hernández JR. Superior mesenteric vein aneurysm. *Rev Esp Enferm Dig* 2021; **113**: 615-616 [PMID: [33761751](#) DOI: [10.17235/reed.2021.7932/2021](#)]
 - 66 **Villani R**, Lupo P, Angeletti AG, Sacco AF, Macarini L, Serviddio G. Asymptomatic saccular portal vein aneurysm: a case report and review of the literature. *J Ultrasound* 2022; **25**: 799-803 [PMID: [35113392](#) DOI: [10.1007/s40477-022-00659-2](#)]
 - 67 **Mortazavi S**, Trinder M, Li R, Abdul Aziz F. Extrahepatic portal vein aneurysm identification during cholecystectomy. *ANZ J Surg* 2022; **92**: 921-922 [PMID: [34559442](#) DOI: [10.1111/ans.17206](#)]
 - 68 **Matsumoto T**, Aoki T, Kubota K. Pancreatic Head Adenocarcinoma Complicated by Portal Venous Aneurysm. *J Gastrointest Surg* 2021; **25**: 1628-1630 [PMID: [33169326](#) DOI: [10.1007/s11605-020-04865-3](#)]
 - 69 **Ierardi AM**, Berselli M, Cuffari S, Castelli P, Coccozza E, Carrafiello G. Uncommon Case of a Post-Traumatic Portal Vein Pseudoaneurysm Treated with Percutaneous Transhepatic Stent Grafting. *Cardiovasc Intervent Radiol* 2016; **39**: 1506-1509 [PMID: [27230514](#) DOI: [10.1007/s00270-016-1373-7](#)]
 - 70 **Walton H**, Yu D, Imber C, Webster G. Portal vein pseudoaneurysm secondary to pancreatic lymphoma and biliary stent insertion: a rare cause of haemobilia. *CVIR Endovasc* 2018; **1**: 5 [PMID: [30652138](#) DOI: [10.1186/s42155-018-0011-7](#)]
 - 71 **Cleveland NC**, Nguyen DN, Tran CD, Maheshwary RK, Hartman MS. Traumatic Injury to the Portal Vein With Shock Bowel. *Curr Probl Diagn Radiol* 2019; **48**: 97-99 [PMID: [29107397](#) DOI: [10.1067/j.cpradiol.2017.09.011](#)]



Published by **Baishideng Publishing Group Inc**
7041 Koll Center Parkway, Suite 160, Pleasanton, CA 94566, USA

Telephone: +1-925-3991568

E-mail: bpgoffice@wjgnet.com

Help Desk: <https://www.f6publishing.com/helpdesk>

<https://www.wjgnet.com>

