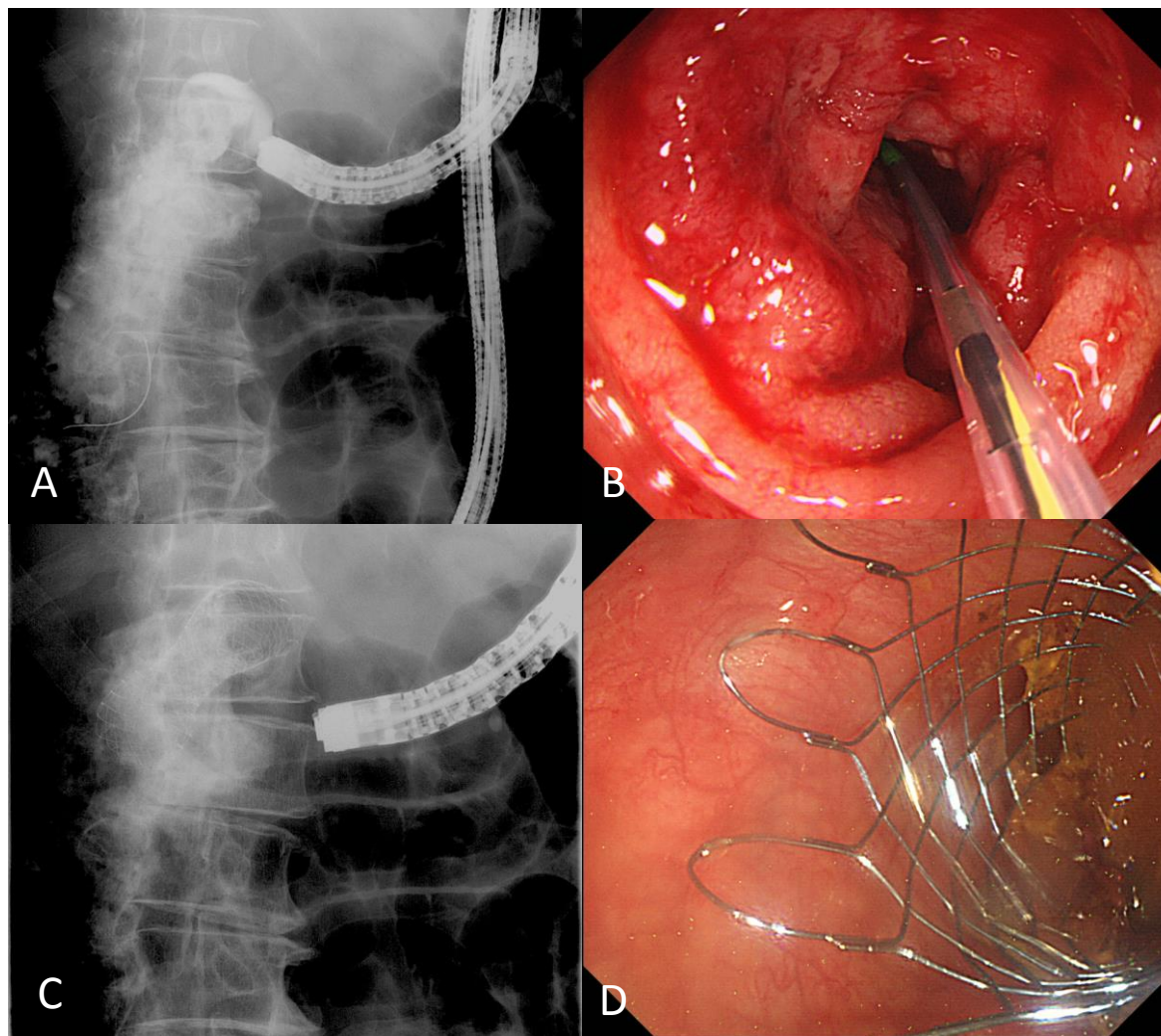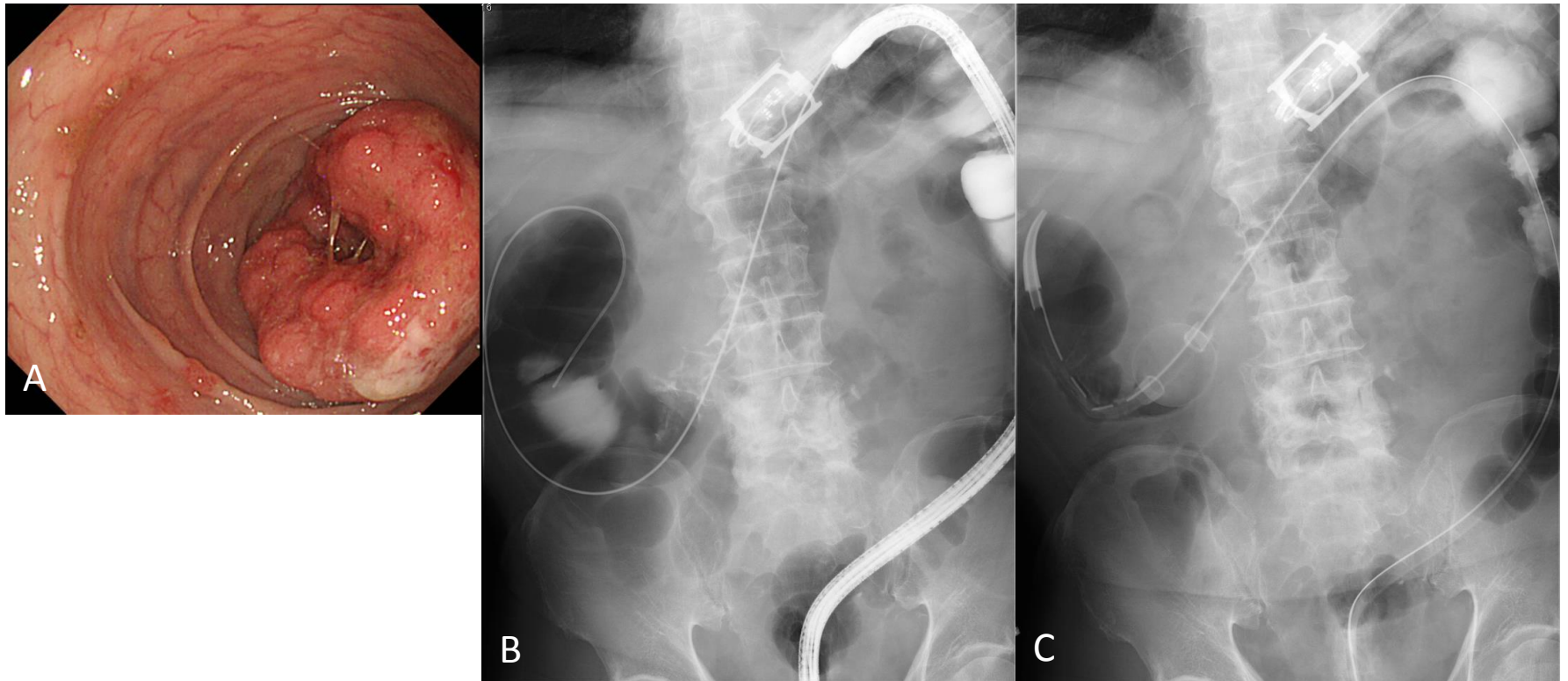


Supplemental Figure 1 Placement of self-expandable metallic stent. A: Under radiological guidance, the endoscope was introduced up to the site of the obstruction. The length of the stenosis was assessed fluoroscopically and guide wire was introduced through the tumor; B: The stent was advanced through the endoscope over a guide wire until it passed the proximal end of the stricture; C-D: The stent was deployed under continuous radiographic control.



Supplemental Figure 2 Placement of trans-anal decompression tube. A-B: Under endoscopic and radiological guidance, guide wire was introduced through the tumor beyond the point of the obstruction; C: Subsequently, the endoscope was removed and a trans-anal decompression tube was introduced over the guide wire. After confirming that the balloon part of the tube had passed the lesion, the balloon was inflated with 15-20 mL of sterilized water, and the position of the tube was fixed.