

World Journal of *Gastrointestinal Surgery*

World J Gastrointest Surg 2020 February 27; 12(2): 34-84





ORIGINAL ARTICLE

Retrospective Cohort Study

- 34 Retrospective cohort study of statin therapy effect on resected colorectal liver metastases
Alabraba E, Ibrahim H, Oлару A, Cameron I, Gomez D, Group NHS

Retrospective Study

- 45 Hyponatremia is associated with more severe biliary disease
Zobel MJ, Stewart L

SYSTEMATIC REVIEWS

- 55 Splenic injuries secondary to colonoscopy: Rare but serious complication
Ullah W, Rashid MU, Mehmood A, Zafar Y, Hussain I, Sarvepalli D, Hasan MK

CASE REPORT

- 68 Left hepatic trisectionectomy for perihilar cholangiocarcinoma with a right-sided round ligament: A case report
Ishida T, Nara S, Akahoshi K, Takamoto T, Kishi Y, Esaki M, Hiraoka N, Shimada K
- 77 Appendicitis-mimicking presentation in fishbone induced microperforation of the distal duodenum: A case report
Lim D, Ho CM

Contents

World Journal of Gastrointestinal Surgery
Volume 12 Number 2 February 27, 2020

ABOUT COVER

Editorial Board Member of *World Journal of Gastrointestinal Surgery*, Eva Lieto, MD, PhD, Assistant Professor, Department of Transitional Medicine, University of Campania Luigi Vanvitelli, Naples 80131, Italy

AIMS AND SCOPE

The primary aim of *World Journal of Gastrointestinal Surgery* (WJGS, *World J Gastrointest Surg*) is to provide scholars and readers from various fields of gastrointestinal surgery with a platform to publish high-quality basic and clinical research articles and communicate their research findings online. WJGS mainly publishes articles reporting research results and findings obtained in the field of gastrointestinal surgery and covering a wide range of topics including biliary tract surgical procedures, biliopancreatic diversion, colectomy, esophagectomy, esophagoplasty, esophagostomy, fundoplication, gastrectomy, gastroenterostomy, gastropexy, hepatectomy, jejunioileal bypass, liver transplantation, pancreas transplantation, pancreatectomy, pancreaticoduodenectomy, and pancreaticojejunostomy, etc.

INDEXING/ABSTRACTING

The WJGS is now abstracted and indexed in Science Citation Index Expanded (SCIE, also known as SciSearch®), Current Contents/Clinical Medicine, Journal Citation Reports/Science Edition, PubMed, PubMed Central, China National Knowledge Infrastructure (CNKI), China Science and Technology Journal Database (CSTJ), and Superstar Journals Database.

RESPONSIBLE EDITORS FOR THIS ISSUE

Responsible Electronic Editor: *Yu-Jie Ma*
Proofing Production Department Director: *Xiang Li*

NAME OF JOURNAL

World Journal of Gastrointestinal Surgery

ISSN

ISSN 1948-9366 (online)

LAUNCH DATE

November 30, 2009

FREQUENCY

Monthly

EDITORS-IN-CHIEF

Varut Lohsiriwat, Shu-You Peng

EDITORIAL BOARD MEMBERS

<https://www.wjgnet.com/1948-9366/editorialboard.htm>

EDITORIAL OFFICE

Ruo-Yu Ma, Director

PUBLICATION DATE

February 27, 2020

COPYRIGHT

© 2020 Baishideng Publishing Group Inc

INSTRUCTIONS TO AUTHORS

<https://www.wjgnet.com/bpg/gerinfo/204>

GUIDELINES FOR ETHICS DOCUMENTS

<https://www.wjgnet.com/bpg/GerInfo/287>

GUIDELINES FOR NON-NATIVE SPEAKERS OF ENGLISH

<https://www.wjgnet.com/bpg/gerinfo/240>

PUBLICATION MISCONDUCT

<https://www.wjgnet.com/bpg/gerinfo/208>

ARTICLE PROCESSING CHARGE

<https://www.wjgnet.com/bpg/gerinfo/242>

STEPS FOR SUBMITTING MANUSCRIPTS

<https://www.wjgnet.com/bpg/GerInfo/239>

ONLINE SUBMISSION

<https://www.f6publishing.com>

© 2020 Baishideng Publishing Group Inc. All rights reserved. 7041 Koll Center Parkway, Suite 160, Pleasanton, CA 94566, USA

E-mail: bpgoffice@wjgnet.com <https://www.wjgnet.com>



Splenic injuries secondary to colonoscopy: Rare but serious complication

Waqas Ullah, Mamoon Ur Rashid, Asif Mehmood, Yousaf Zafar, Ishtiaq Hussain, Deepika Sarvepalli, Muhammad Khalid Hasan

ORCID number: Waqas Ullah (0000-0002-4850-0309); Mamoon Ur Rashid (0000-0002-3843-4352); Asif Mehmood (0000-0002-8426-7751); Yousaf Zafar (0000-0003-3237-8510); Ishtiaq Hussain (0000-0002-2574-9156); Deepika Sarvepalli (0000-0002-3678-5060); Muhammad Khalid Hasan (0000-0001-8608-7386).

Author contributions: All authors equally contributed to this paper with conception and design of the study, literature review and analysis, drafting and critical revision and editing, and final approval of the final version.

Conflict-of-interest statement: No potential conflicts of interest. No financial support.

PRISMA 2009 Checklist statement: The authors have read the PRISMA 2009 Checklist, and the manuscript was prepared and revised according to the PRISMA 2009 Checklist.

Open-Access: This article is an open-access article which was selected by an in-house editor and fully peer-reviewed by external reviewers. It is distributed in accordance with the Creative Commons Attribution Non Commercial (CC BY-NC 4.0) license, which permits others to distribute, remix, adapt, build upon this work non-commercially, and license their derivative works on different terms, provided the original work is properly cited and the use is non-commercial. See:

Waqas Ullah, Department of Internal Medicine, Abington Hospital, Abington, PA 19001, United States

Mamoon Ur Rashid, Deepika Sarvepalli, Department of Internal Medicine, Advent Health Hospital, Orlando, FL 32804, United States

Asif Mehmood, Department of Internal Medicine, Geisinger Medical Center, Danville, PA 17822, United States

Yousaf Zafar, Department of Internal Medicine, UMKC, 5100 Rockhill Rd, Kansas City, MO 64110, United States

Ishtiaq Hussain, Department of Gastroenterology, Cleveland Clinic, Weston, FL 33331, United States

Muhammad Khalid Hasan, Department of Gastroenterology, Advent Health Hospital, Orlando, FL 32804, United States

Corresponding author: Mamoon Ur Rashid, MBBS, MD, Doctor, Medical Resident, Department of Internal Medicine, Advent Health Hospital, 2501 North Orange Avenue, Orlando, FL 32804, United States. mamoon.rashid.md@adventhealth.com

Abstract

BACKGROUND

Colonoscopy is a safe and routine diagnostic and therapeutic procedure for evaluation of large bowel diseases. Most common procedure related complications include bleeding and perforation but rarely a splenic Injury.

AIM

To investigate the reason for colonoscopy, presentation of patient with spleen injury, types of injury, diagnosis, management and outcomes of patients

METHODS

A structured search on four databases was done and 45 articles with 68 patients were selected. The reason for colonoscopy, presentation of patient with spleen injury, types of injury, diagnosis, management and outcomes of patients were identified and analyzed using SPSS.

RESULTS

The mean age of the patients was 62.7 years with 64% females. Twenty two

<http://creativecommons.org/licenses/by-nc/4.0/>

Manuscript source: Unsolicited manuscript

Received: September 6, 2019

Peer-review started: September 6, 2019

First decision: September 28, 2019

Revised: November 23, 2019

Accepted: December 14, 2019

Article in press: December 14, 2019

Published online: February 27, 2020

P-Reviewer: Horesh N, Wasserberg N

S-Editor: Yan JP

L-Editor: A

E-Editor: Ma YJ



percent had a complete splenic rupture with colonoscopy while 63% had subcapsular hematoma, spleen laceration and spleen avulsion. The most common reason for colonoscopy was screening (46%) followed by diagnostic colonoscopy (28%). Eighty seven percent of patients presented with abdominal pain. Patients with spleen rupture mostly required splenectomy (47%), while minor spleen hematomas and lacerations were managed conservatively (38%). Six percent of the patients were managed with proximal splenic artery splenic embolization and 4% were managed with laparoscopic repair. The overall mortality was 10% while 77% had complete recovery. The reason of colonoscopy against presentation specifically, abdominal pain showed no statistical significance $P = 0.69$. The indication of colonoscopy had no significant impact on incidence of splenic injury ($P = 0.89$). Majority of the patients (47%) were managed with splenectomy while the rest were managed conservatively ($P = 0.04$). This association was moderately strong at a cramer's V test (0.34). The Fisher exact test showed a higher mortality with spleen rupture ($P = 0.028$).

CONCLUSION

Spleen rupture due to colonoscopy is a significant concern and is associated with high mortality. The management of the patients can be individualized based on clinical presentation.

Key words: Colonoscopy; Spleen; Splenic rupture; Systematic review; Splenic injuries

©The Author(s) 2020. Published by Baishideng Publishing Group Inc. All rights reserved.

Core tip: Colonoscopy is a safe diagnostic and therapeutic procedure for evaluation of large bowel diseases. Rarely, a splenic Injury can occur. We perform a structured search on four databases and selected 45 articles with 68 patients. The reason for colonoscopy, presentation of patient with spleen injury, types of injury, diagnosis, management and outcomes of patients were identified and analyzed. The most common reason for colonoscopy was screening (46%) followed by diagnostic colonoscopy (28%). Eighty seven percent of patients presented with abdominal pain. Patients with spleen rupture mostly required splenectomy (47%), while minor spleen hematomas and lacerations were managed conservatively (38%). Six percent of the patients were managed with proximal splenic artery splenic embolization and 4% were managed with laparoscopic repair. The overall mortality was 10% while 77% had complete recovery. Spleen rupture due to colonoscopy is a significant concern and is associated with high mortality. The management of the patients can be individualized based on clinical presentation.

Citation: Ullah W, Rashid MU, Mehmood A, Zafar Y, Hussain I, Sarvepalli D, Hasan MK. Splenic injuries secondary to colonoscopy: Rare but serious complication. *World J Gastrointest Surg* 2020; 12(2): 55-67

URL: <https://www.wjgnet.com/1948-9366/full/v12/i2/55.htm>

DOI: <https://dx.doi.org/10.4240/wjgs.v12.i2.55>

INTRODUCTION

Colonoscopy is a safe and routine procedure performed for evaluation of large bowel diseases. The most common post procedure complications include bleeding and perforation. Splenic Injury, a rare complication after colonoscopy was first reported by Wherry and Zehner^[1] in 1974. Since then, the reported incidence is on the rise and is estimated to be 1 in 100000 procedures. Possible reasons include increased utilization of colonoscopy for management of gastrointestinal disorders including polypectomy and increased rate of screening colonoscopies from 38% in 2000 to 59% in 2013 in adults ≥ 50 years^[2]. Previously reported risks of splenic injury include female sex, advanced age, history of abdominal/pelvic surgeries, anti-platelet or anti-coagulant therapy and polypectomies/biopsies performed during colonoscopies, but it is unclear if these factors are purely associations or represent a contributing cause^[3].

Even though, splenic injury is a rare complication, it is associated with significantly high mortality rate (5%)^[1,4-6]. In order to ensure the timely management of splenic

injuries there should be a high index of suspicion of splenic trauma in any patient presenting with severe abdominal pain and hemodynamic instability after colonoscopy. Here, we performed a systematic review to identify the risks, diagnostic factors, clinical course and management of splenic injury with colonoscopy that may help predict splenic complications after colonoscopy.

MATERIALS AND METHODS

Search strategy and selection criteria

A literature search for relevant articles was performed through April 25, 2019, using MEDLINE (PubMed, Ovid), Embase and Cochrane databases (Figure 1). There was no language or time restrictions placed on the search. The search strategies included various combinations of text-words and medical subject headings (MeSH) to generate two subsets of citations: One for spleen injury, using the MeSH and terms like “spleen rupture”, “spleen injury”, “spleen laceration”, “spleen trauma”, “spleen insult”, “spleen” and “spleen disease” and the other for colonoscopy using terms and MeSH like “colonoscopy”, “endoscopy”, “sigmoidoscopy”, “rigid colonoscopy”, “flexible endoscopy”, “rigid endoscopy”, “flexible colonoscopy”. The terms from the two subsets were combined in 1:1 combination and finally results from all the possible combinations were downloaded. Based on our research question, we also manually searched the references in all known articles to identify studies that were missed by the initial search.

The selection criteria for the included studies was: (1) Recruited subjects with any type of spleen injury secondary to colonoscopy; and (2) Discussed the mechanism, diagnosis and outcome of spleen injury. Studies with insufficient data, posters and conference papers were excluded, as were studies with not enough description of its subjects.

Study selection

The titles and abstracts of the selected articles were reviewed independently by three authors and the articles which met the inclusion criteria were reviewed by the fourth author. Full-text articles that were potentially relevant to the study were also reviewed by all the four authors to confirm the eligibility. Disagreements were resolved by mutual consensus and after a detailed group discussion.

Data abstraction and analysis

Three reviewers extracted data^[3,4,7-63] (Table 1) into the excel sheet identifying the reason of colonoscopy, presentation of patient with spleen injury, types of injury, diagnosis, management and outcome of all patients with spleen injury. After carefully assessing the extracted data, all categorical data was coded into binary numbers. Frequencies and proportions were obtained for nominal and ordinal data while means and standard deviation was calculated for continuous data. Inferential statistics for categorical data was performed using Pearson Chi-square test and the alpha criterion for significance was set at a value less than 0.05. Analysis was performed using SPSS v22.

RESULTS

The mean age of the patients was 62.7 (Standard deviation 15.7 years). Of the reported cases of splenic injury majority were females 64% ($n = 41/64$), there was no gender data available for four patients. Twenty two percent of the patients ($n = 15/68$) had a complete rupture of the spleen secondary to colonoscopy while the remaining 63% ($n = 43/68$) had a variety of spleen injuries such as subcapsular hematoma, spleen laceration and spleen avulsion. Details on the type of spleen injury was not available in 15% patients ($n = 10/68$). The diagnosis of any kind of spleen insult was made using the computed tomography (CT) in all patients (98.5%, $n = 67/68$) except one patient who was diagnosed with CT angiography.

The most common reason for colonoscopy was screening for colon cancer 46% ($n = 31/68$) followed by evaluation for the cause of gastrointestinal bleeding 28% ($n = 19/68$). Other rationales for colonoscopy were polypectomy (13%, $n = 9/68$), abdominal pain (3%, $n = 2/68$) and weight loss (1.5%, $n = 1/68$). There was no mention of indication of colonoscopy in 6 (9%) (Table 2).

The most common clinical presentation of splenic insult was abdominal pain either generalized or in the left hypochondrium in 87% of patients ($n = 59/68$). Other minor presentations included dizziness, syncope, back pain, chest pain and symptoms of

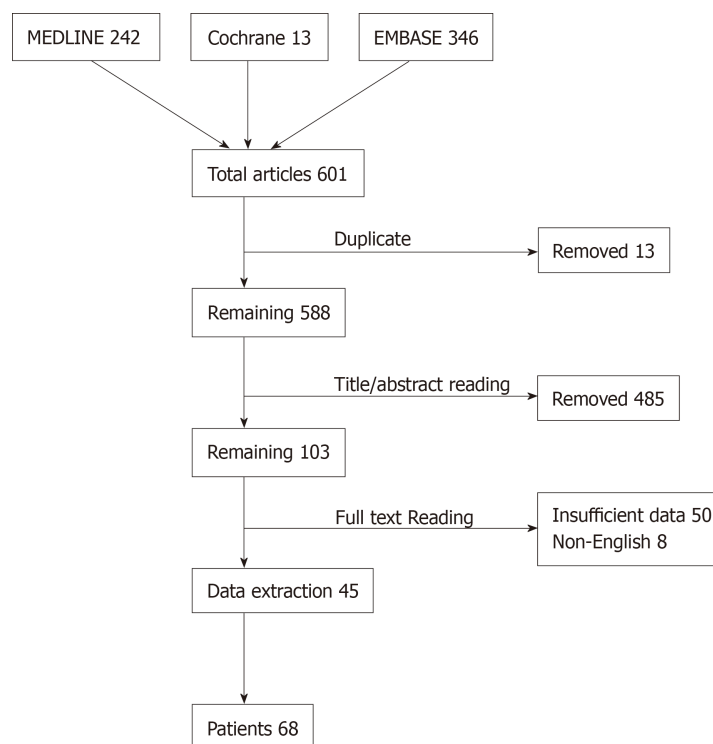


Figure 1 Flow chart for literature search.

anemia (Table 2, Figure 2).

Management in all cases was tailored according to the clinical presentation and CT scan findings. Majority of the patients required laparotomy and splenectomy 47% ($n = 32/68$). While patients with minor spleen hematomas and lacerations were managed conservatively with intravenous fluids, pain control and vitals monitoring 38% ($n = 26/68$). Interestingly, 6% ($n = 4/68$) patients were managed with proximal splenic artery splenic embolization (PSAE) and 4% ($n = 3/68$) were managed with laparoscopy. There was no outcome reported in 4.4% ($n = 3/68$) patients.

Despite the wide array of spleen insults ranging from mild hematoma to rupture, majority of patients survived with different management modalities. The overall mortality rate however, was significant at 10% ($n = 7/68$) while 77% ($n = 52/68$) had successful recovery. There was no outcome reported in 13% ($n = 9/68$) patients (Table 3).

The reason of colonoscopy against presentation specifically abdominal pain showed no statistical significance $P = 0.69$. For all patients with spleen rupture and injury the most common reason was screening colonoscopy followed by colonoscopy done for gastrointestinal bleeding evaluation. This association between screening colonoscopy and spleen injury was analyzed by likelihood ratio as the number of expected count in more than 20% of the cells for more than 2 variables was less than 5. The association was robust with a value of 2.3, degree of freedom (df) of 4 but not statistically significant ($P = 0.667$). Similarly, Chi-Square analysis and cross tabulation for the management of spleen injury was tested for any association with reason of colonoscopy. The likelihood ratio was interpreted based on the same rationale as mentioned above, there was no significant association found between the all type of colonoscopy and the management of spleen injury (splenectomy $P = 0.89$ and splenorrhaphy = 0.91). The alpha criteria of less than 0.05 was taken as a cutoff for significance (Figure 3).

To assess the association of outcome (survival/mortality) with reason of colonoscopy we cross tabulated these groups and did a chi-square test. The likelihood ratio was 3.17, df 4 and P value was not significant (screening colonoscopy 0.52, diagnostic colonoscopy 0.61) indicating there was no association between the two variables (Table 4).

We compared the type of spleen injury and its association with the type of management performed. It is interesting to note that 74% of the spleen rupture patients were managed with splenectomy through exploratory laparotomy. About 45% for spleen injury group had splenectomy, an equal number of patients (45%) were managed with conservative management. These results are indicating that laparotomy was a common management strategy in both groups. Only 14% patients

Table 1 Details of case reports and Clavein-Dindo Classification of Post-Operative complication (computed tomography)

Ref.	Age	Sex	Reason for colonoscopy	Type of injury	Diagnosis	Management	Clavein-Dindo classification of Post-Operative complication
Keeven <i>et al</i> ^[7]	52	Male	Screening	Splenic rupture	CT	Laparotomy / splenectomy	Grade III
Suliman <i>et al</i> ^[8]	59	Female	Screening	Splenic injury/hematoma	CT	Conservative management	Grade I
Diéguez Castillo <i>et al</i> ^[9]	53	Female	Bleeding	Splenic rupture	CT	Laparotomy / splenectomy	Grade III
Zhang <i>et al</i> ^[11]	63	Female	Weight Loss	Splenic injury/hematoma	CT	Conservative management	Grade I
Chime <i>et al</i> ^[12]	51	Female	Screening	Splenic injury/hematoma	CT	Laparotomy / splenectomy	Grade III
Ungprasert <i>et al</i> ^[13]	59	Male	Screening	Splenic injury/hematoma	CT	Conservative management	Grade I
Laiz Díez <i>et al</i> ^[14]	40	Female	Screening	Splenic injury/hematoma	CT	Conservative management	Grade I
Laiz Díez <i>et al</i> ^[14]	80	Female	Screening	Splenic rupture	CT	Laparotomy / splenectomy	Grade III
Barbeiro <i>et al</i> ^[15]	73	Female	Bleeding	Splenic rupture	CT	Laparotomy / splenectomy	Grade III
Li <i>et al</i> ^[16]	65	Female	Screening	Splenic injury/hematoma	CT	Conservative management	Grade I
Nallayici <i>et al</i> ^[17]	71	Male	Screening	Splenic rupture	CT	Laparotomy / splenectomy	Grade III
Pavlidis <i>et al</i> ^[19]	74	Male	Screening	Splenic rupture	CT	Laparotomy / splenectomy	Grade III
Steele <i>et al</i> ^[20]	60	Female	Screening	Splenic rupture	CT	Conservative management	Grade I
Ozogul <i>et al</i> ^[21]	69	Female	Polypectomy	Splenic injury/hematoma	CT	Conservative management	Grade I
Mccarty <i>et al</i> ^[24]	71	Male	Bleeding	Splenic injury/hematoma	CT	Conservative management	Grade I
Jehangir <i>et al</i> ^[22]	76	Female	Bleeding	Splenic injury/hematoma	CT	Laparotomy / splenectomy	Grade III
Zappa <i>et al</i> ^[26]	73	Male	Abdominal pain	Splenic injury/hematoma	CT	Laparotomy / splenectomy	Grade III
Lahat <i>et al</i> ^[4]	61	Male	Screening	Splenic injury/hematoma	CT	Laparotomy / splenectomy	Grade III
Lahat <i>et al</i> ^[4]	68	Male	Screening	Splenic injury/hematoma	CT	Conservative management	Grade I
Lahat <i>et al</i> ^[4]	85	Female	Polypectomy	Splenic injury/hematoma	CT	Laparotomy / splenectomy	Grade III
Lahat <i>et al</i> ^[4]	54	Male	Polypectomy	Splenic injury/hematoma	CT	Laparotomy / splenectomy	Grade III
Lahat <i>et al</i> ^[4]	65	Male	Screening	Splenic injury/hematoma	CT	Laparotomy / splenectomy	Grade III
Lahat <i>et al</i> ^[4]	59	Male	Polypectomy	Splenic injury/hematoma	CT	Laparoscopy	Grade III
Mulkerin <i>et al</i> ^[27]	NA	NA	Screening	Splenic injury/hematoma	CT	Laparoscopy	Grade III
García García <i>et al</i> ^[28]	58	Female	Screening	Splenic injury/hematoma	CT	Laparoscopy	Grade III
Sbai <i>et al</i> ^[29]	70	Male	Bleeding	Splenic injury/hematoma	CT	Laparotomy / splenectomy	Grade III
Ng <i>et al</i> ^[31]	63	Female	Screening	Splenic injury/hematoma	CT-Angiogram	Conservative management	Grade I
Mazulis <i>et al</i> ^[32]	88	Female	Bleeding	Splenic injury/hematoma	CT	Laparotomy / splenectomy	Grade III
Kapur <i>et al</i> ^[33]	76	Female	Bleeding	Splenic rupture	CT	Laparotomy / splenectomy	Grade III

Han <i>et al</i> ^[34]	77	Male	Polypectomy	Splenic rupture	CT	Laparotomy/ splenectomy	Grade III
Brennan <i>et al</i> ^[38]	75	Female	Screening	Splenic injury/hematoma	CT	Proximal splenic artery embolization	Grade III
Herreros de Tejada <i>et al</i> ^[39]	65	Female	Submucosal Dissection of tumor	Splenic rupture	CT	Laparotomy/ splenectomy	Grade III
Lauretta <i>et al</i> ^[40]	61	Male	Screening	Splenic rupture	CT	Laparotomy/ splenectomy	Grade III
Jamorabo <i>et al</i> ^[42]	63	Male	Screening	Splenic rupture	CT	Laparotomy/ splenectomy	Grade III
Guner <i>et al</i> ^[44]	53	Male	Abdominal Pain	Splenic injury/hematoma	CT	Bed rest, blood transfusion, observation	Grade II
McBride <i>et al</i> ^[45]	64	Female	Bleeding	Splenic injury/hematoma	CT	Laparotomy/ splenectomy	Grade III
Rex <i>et al</i> ^[46]	68	Female	NA	NA	CT	Conservative management	Grade I
Rex <i>et al</i> ^[46]	52	Female	Polypectomy	Splenic injury/hematoma	CT	Conservative management	Grade I
Rex <i>et al</i> ^[46]	61	Female	NA	NA	CT	Conservative management	Grade I
Rex <i>et al</i> ^[46]	58	Female	NA	NA	CT	Conservative management	Grade I
Rex <i>et al</i> ^[46]	74	Female	NA	NA	CT	Conservative management	Grade I
Rex <i>et al</i> ^[46]	85	Female	NA	NA	CT	Conservative management	Grade I
Chow <i>et al</i> ^[47]	84	Female	Bleeding	Splenic injury/hematoma	CT	Fluids/blood/ splenic artery embolization	Grade III
Pineda <i>et al</i> ^[48]	62	Female	Screening	Splenic rupture	CT	Laparotomy/ splenectomy	Grade III
Corcillo <i>et al</i> ^[49]	66	Male	Bleeding	Splenic rupture	CT	Proximal splenic artery embolization	Grade III
Corcillo <i>et al</i> ^[49]	77	Female	Polypectomy	Splenic rupture	CT	Proximal splenic artery embolization	Grade III
Abunnaja <i>et al</i> ^[50]	62	Female	Screening	Splenic injury/hematoma	CT	Ringers lactate, blood, splenectomy, vaccinations	Grade II
González-Soler <i>et al</i> ^[51]	67	Male	Screening	Splenic rupture	CT	Laparotomy/ splenectomy	Grade III
Seifman <i>et al</i> ^[52]	41	Female	Screening	Splenic injury/hematoma	CT	Laparotomy/ splenectomy	Grade III
Singla <i>et al</i> ^[54]	NA	NA	Screening	NA	CT	NA	NA
Shankar <i>et al</i> ^[56]	47	Female	Bleeding	Splenic injury/hematoma	CT	Laparotomy/ splenectomy	Grade III
Fishback <i>et al</i> ^[58]	64	Female	Screening	Splenic injury/hematoma	CT	Conservative management	Grade I
Fishback <i>et al</i> ^[58]	59	Female	Bleeding	Splenic injury/hematoma	CT	Conservative management	Grade I
Fishback <i>et al</i> ^[58]	55	Female	Bleeding	Splenic injury/hematoma	CT	Laparotomy/ splenectomy	Grade III
Fishback <i>et al</i> ^[58]	65	Male	Polypectomy	NA	CT	Laparotomy/ splenectomy	Grade III
Fishback <i>et al</i> ^[58]	56	Female	Screening	Splenic injury/hematoma	CT	Conservative management	Grade I
Fishback <i>et al</i> ^[58]	51	Female	Screening	Splenic injury/hematoma	CT	Laparotomy/ splenectomy	Grade III
Fishback <i>et al</i> ^[58]	54	Female	Screening	Splenic injury/hematoma	CT	Conservative management	Grade I
Fishback <i>et al</i> ^[58]	68	Female	Screening	Splenic injury/hematoma	CT	Laparotomy/ splenectomy	Grade III

Fishback <i>et al</i> ^[58]	84	Female	Bleeding	Splenic injury/hematoma	CT	Conservative management	Grade I
Fishback <i>et al</i> ^[58]	64	Male	Bleeding	Splenic injury/hematoma	CT	Conservative management	Grade I
Fishback <i>et al</i> ^[58]	64	Male	Screening	Splenic injury/hematoma	CT	Proximal splenic artery embolization/spl enectomy	Grade III
Bertoglio <i>et al</i> ^[59]	70	Male	Bleeding	Splenic injury/hematoma	CT	Laparotomy/splenectomy	Grade III
Sachdev <i>et al</i> ^[61]	68	Female	Bleeding	Splenic injury/hematoma	CT	Laparotomy/splenectomy	Grade III
Meier <i>et al</i> ^[62]	68	Female	Bleeding	NA	CT	Laparotomy/splenectomy	Grade III

NA: Not available; CT: Computed tomography.

in spleen rupture group had conservative management and PSAE due to multiple comorbidities or surgery denial. The likelihood ratio for splenectomy association with spleen rupture was 8.1, *df* 3 and the *P* value was significant at 0.04 (< 0.05). The strength of association between these variables was moderately strong at a cramer's *V* 0.34.

The type of spleen injury was analyzed with the outcomes. An 80% of the spleen rupture and 97% of the spleen injury group survived. However, in the remaining patients, the mortality was 3 times more with spleen rupture rather than minor injury about 75% $n = 3/4$ and 25% $n = 1/4$ respectively. The Fisher exact test was used as in 50% cells the expected count was less than 5 and the *P* value was 0.028 (statistically significant) indicating higher mortality with spleen rupture. The estimate of measure size was calculated using the Phi test and it was 0.28 (< 0.3) indicating a weak association between the type of spleen rupture and mortality (Table 5, Figure 4).

DISCUSSION

Colonoscopy is considered a safe procedure with low risk of complications. Common procedure related complications include perforation and bleeding^[6]. A retrospective study by Levin *et al*^[64] reported 16318 colonoscopies of which the overall complication rate was 0.5% (perforation rate 0.09%, post- biopsy/polypectomy bleeding rate 0.48%). Splenic injury after colonoscopy procedure is rare but a serious complication. During a study at a single institution, the incidence of splenic injury was 0.2 in 10000 procedures (7 out of 296248) for all the colonoscopies done between 1980 and 2008^[65]. Another study reported a rate of 0.72 per 10000 procedures (12 of 165527 colonoscopies)^[66]. Furthermore, a recent study by Laanani *et al*^[10] reported an incidence of 0.20–0.34 splenic injuries per 10000 first colonoscopy procedures. The discordance of incidence rates in various reports possibly could be due to underreporting and underdiagnosis of the cases. Even though there are a few explanations for splenic trauma during colonoscopy, the mechanism is yet to be fully understood. One of the hypotheses is excessive traction on the splenocolic ligament or on splenocolic adhesions, secondary to previous abdominal surgery or intra-abdominal inflammatory processes^[1,49,58,67,68]. Another possible reason could be a direct blunt trauma when navigating the colonoscope through the splenic flexure^[56]. Other known risk factors for splenic trauma include older age, less experienced endoscopists, being female, polypectomy and biopsies during the procedure^[1,3,5,6,69].

Nearly 2/3 of the patients (64%) with splenic trauma were females. The higher rate in females can be partly explained by the slightly better participation of women in the colorectal cancer screening process^[2]. Saunders *et al*^[70] described colonoscopy being a more complicated procedure in females compared to males because of inherently long transverse colon in females. Nonetheless, there is no evidence to support that anatomic difference could be a reason for higher incidence in females.

In our systematic review, 46% of the people that presented with splenic injury underwent colonoscopy for routine surveillance while an equal number of cases (46%) occurred when colonoscopy was done for diagnostic reasons (gastrointestinal bleed, abdominal pain, weight loss) and polypectomy together. The higher incidence in screening group can be related to increased colonoscopy rates due to public awareness^[2]. In regard to the extent of injury to spleen, complete splenic rupture was seen only in 22%, whereas majority (63%) suffered a variety of spleen injuries such as

Table 2 Reason for colonoscopy and types of injury

	Frequency	Valid percent	Colonoscopy reason	Frequency	Valid percent
Gender					
Male	23	35.9	Screening	31	45.6
Female	41	64.1	Bleeding	19	27.9
Injury					
			Polypectomy	9	13.2
Rupture	15	22	Abdominal pain	2	2.9
Injury	43	63.2	Weight loss	1	1.5

sub-capsular hematoma, spleen laceration and spleen avulsion. Moreover, we did not find any association of reason for colonoscopy with either presentation, management or outcome of the patients.

In our review, CT was sensitive in diagnosing almost all cases (98.5%) of splenic trauma. This was higher than the findings of previous literature, which was 81.8%^[22]. These findings reinforce the importance of performing a timely CT abdomen in all symptomatic patients suspected of post colonoscopy splenic trauma. Early diagnosis can aid in prompt management of the patients, which in turn may translate into lower mortality rate. Interestingly, until 1987 majority of splenic injuries were diagnosed during laparotomy^[71,72]. It was since 1989, when CT and ultrasound came into existence, these became the major diagnostic tools^[71,73]. CT is very sensitive and specific in diagnosing and grading the extent of splenic injury and thereby determines the management options. Nevertheless, the single most factor that appears to determine the management is the hemodynamic status of the patient.

Abdominal pain either generalized or in left upper quadrant was the chief complaint in most patients (85%), only 15% presented with signs of hemodynamic instability such as dizziness and syncope. Nearly half of the patients (47%) required laparotomy with splenectomy, 38% had conservative treatment (IV fluids, pain medication and blood transfusion), 4% had laparoscopy and only 6% received spleen saving splenic artery embolization. Here, we further classified management based on the degree of injury. Whereas 75% of patients with splenic rupture required laparotomy with splenectomy, the other group received either splenectomy or conservative management in equal proportions of 45% each. Here, a point worth mentioning was the favorable results shown by PSAE in grade I-II splenic injuries, though it is not widely available but reiterates the idea of increased utilization of minimally invasive treatment strategies^[49,74].

The mortality rate of bleeding and perforation after colonoscopy have either trended down or stayed stable in the last few years. However, our review indicated an alarming rise in the mortality rate from splenic trauma post-colonoscopy. The overall mortality rose to 10% with 7 deaths out of 68 reviewed cases. This was twice the previously reported rate of 5.4%^[56]. In addition, the mortality was 3 times higher with spleen rupture than with other forms of splenic injury. The survival rate of these groups was 80% and 97% respectively. To understand the rising mortality rates, we reviewed existing literature on the incidence of the complication but unfortunately it was limited to case reports and case series.

We could not do meta analysis as there were not enough evidence available and our review was mostly based on the individual reported cases. There were no randomized control trials or large scale observational studies available to justify further comprehensive analysis.

In conclusion, colonoscopy overall is a safer procedure and is rarely associated with splenic injuries. The incidence and management of splenic complications is not affected by the indication of colonoscopy. However, the management of spleen injury should be tailored according to the type of injury with splenectomy being reserved mostly for unstable patients with spleen rupture as it has been associated with a significantly higher mortality rate.

Table 3 Presentation, diagnosis and management of splenic injury

Presentation	Diagnosis and outcome				Management			
	Female	Percent (%)	Female	Percent (%)	Female	Percent (%)	Female	Percent (%)
Abdominal pain	59	87	CT	67	98.5	Laparotomy	32	47.1
Syncope	4	6	CTPA	1	1.5	PSAE	4	5.9
Dizziness	3	5	Survived	52	76.5	Conservative	26	38.2
Chest pain	1	1.5	Died	7	10.3	Laparoscopy	3	4.4

CTPA: Computed tomography pulmonary angiography; CT: Computed tomography; PSAE: Proximal splenic artery splenic embolization.

Table 4 Likelihood ratios for different comparisons

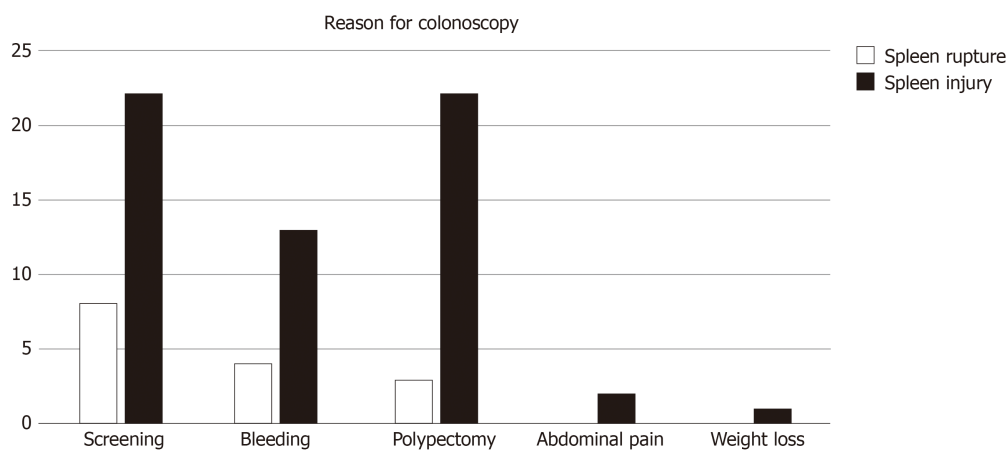
Comparison	Value	df	P value
Abdominal pain and colonoscopy	2.20	4	0.69
Spleen Injury and colonoscopy	2.37	4	0.66
Splenectomy and colonoscopy	6.4	12	0.89
Splenorrhaphy and colonoscopy	6.8	12	0.91
Outcome and screening colonoscopy	3.17	4	0.52
Outcome and diagnostic colonoscopy	3.21	4	0.61

df: Degree of freedom.

Table 5 Likelihood ratios and Fisher's test for different comparisons

Comparison	Value	df	P value
Splenectomy and spleen rupture (Likelihood ratio)	8.1	3	0.04
Mortality and spleen rupture (Fisher's test)	4.8	1	0.028

df: Degree of freedom.

**Figure 2** Graphical representation of splenic injury and reason for colonoscopy.

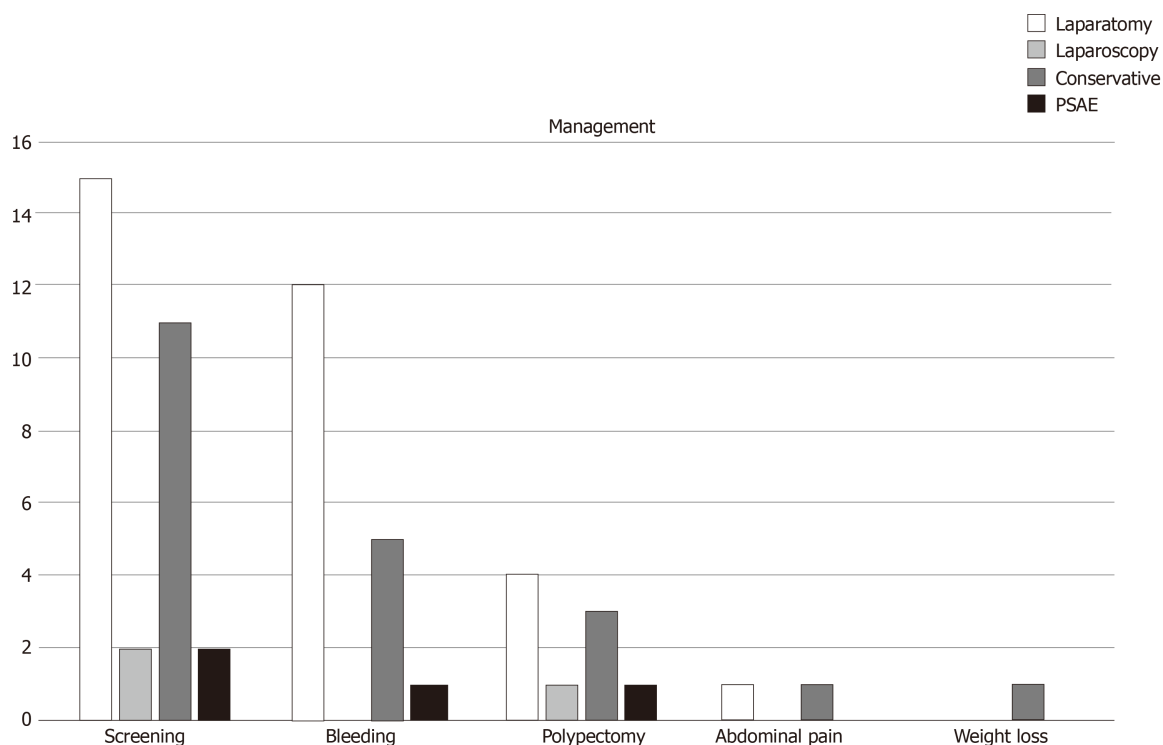


Figure 3 Graphical representation of reason for colonoscopy and management of splenic injury. PSAE: Proximal splenic artery splenic embolization.

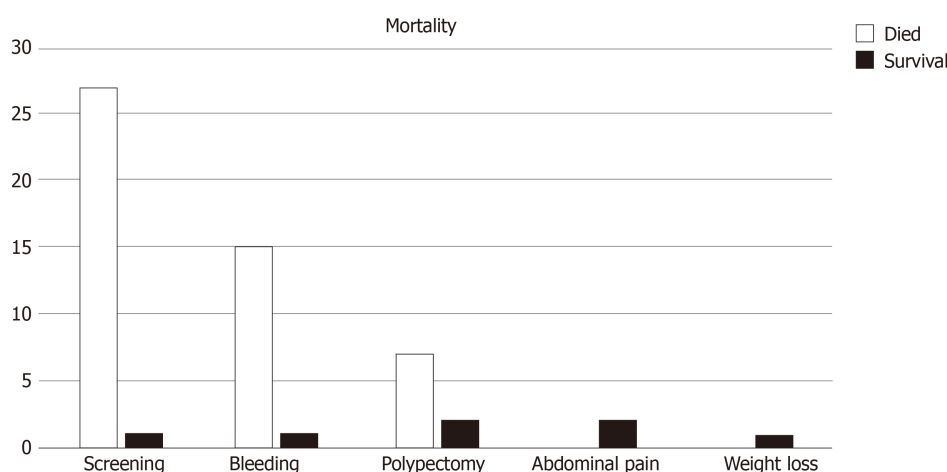


Figure 4 Relation of splenic injury with outcome.

ARTICLE HIGHLIGHTS

Research background

Colonoscopy is a routine diagnostic and therapeutic procedure. Rarely, colonoscopy can cause splenic Injury.

Research motivation

Splenic injury is a rare but fatal complication of colonoscopy. We wanted to study the various research manuscripts published on splenic injuries during colonoscopy and find out the most common indications for colonoscopy, various presentations of patient with spleen injury, different types of injury, diagnosis and management of splenic injury.

Research objectives

The main objectives were to investigate the reason for colonoscopy, presentation of patient with spleen injury, types of injury, diagnosis, management and outcomes of patients

Research methods

A structured search on four databases was done and 45 articles with 68 patients were selected. and analyzed using SPSS. A literature search for relevant articles was performed through April 25, 2019, using MEDLINE (PubMed, Ovid), Embase and Cochrane databases. We selected manuscripts which included subjects with any type of spleen injury secondary to colonoscopy and discussed the mechanism, diagnosis and outcome of spleen injury.

Research results

We found that the mean age of the patients was 62.7 years with females predominance. Some of the patient (20%) had a complete splenic rupture, while majority (63%) had subcapsular hematoma, spleen laceration and spleen avulsion. We noticed that the most common reason for colonoscopy was screening (46%) followed by diagnostic colonoscopy (28%). Most common presentation was with abdominal pain. Patients with spleen rupture mostly required splenectomy (47%), while minor spleen hematomas and lacerations were managed conservatively (38%). Few patients (6%) were managed with proximal splenic artery splenic embolization and 4% were managed with laparoscopic repair. The overall mortality was 10% while 77% had complete recovery. Majority of the patients with splenic rupture were managed with splenectomy while the rest were managed conservatively ($P = 0.04$). This association was moderately strong at a cramer's V test (0.34). The Fisher exact test showed a higher mortality with spleen rupture ($P = 0.028$).

Research conclusions

We found that the most common reason for colonoscopy among patients with splenic injuries was screening colonoscopy. The most common presentation was with abdominal pain. Computed tomography abdomen was diagnostic mode of choice. Majority of the patients with splenic rupture were managed with splenectomy and overall mortality was 10%. Recently, monitored anesthesia care has been used in majority of the patients for anesthesia during colonoscopy. Propofol has been used as a part of the protocol. It has been postulated that compared to conscious sedation, deep sedation is expected to blunt patient responses to painful stimuli which can lead to traumatic injuries during colonoscopy like splenic injury and perforation. Majority of the manuscripts did not have information on anesthesia protocol, which would have provided valuable information.

Research perspectives

Further studies are needed to find the likely etiology of splenic injury during. Anesthesia with propofol has been postulated to be one of the reasons for splenic injury as it might blunt patient responses to painful stimuli.

REFERENCES

- 1 Wherry DC, Zehner H. Colonoscopy-fiberoptic endoscopic approach to the colon and polypectomy. *Med Ann Dist Columbia* 1974; **43**: 189-192 [PMID: 4524804]
- 2 Siegel RL, Fedewa SA, Anderson WF, Miller KD, Ma J, Rosenberg PS, Jemal A. Colorectal Cancer Incidence Patterns in the United States, 1974-2013. *J Natl Cancer Inst* 2017; **109** [PMID: 28376186 DOI: 10.1093/jnci/djw322]
- 3 Piccolo G, Di Vita M, Cavallaro A, Zanghi A, Lo Menzo E, Cardì F, Cappellani A. Presentation and management of splenic injury after colonoscopy: a systematic review. *Surg Laparosc Endosc Percutan Tech* 2014; **24**: 95-102 [PMID: 24686342 DOI: 10.1097/SLE.0b013e3182a83493]
- 4 Lahat E, Nevler A, Batumsky M, Shapiro R, Zmora O, Gutman M. Diagnosis and management of splenic injury following colonoscopy: algorithm and case series. *Tech Coloproctol* 2016; **20**: 163-169 [PMID: 26757901 DOI: 10.1007/s10151-015-1422-2]
- 5 Macrae FA, Tan KG, Williams CB. Towards safer colonoscopy: a report on the complications of 5000 diagnostic or therapeutic colonoscopies. *Gut* 1983; **24**: 376-383 [PMID: 6601604 DOI: 10.1136/gut.24.5.376]
- 6 Ha JF, Minchin D. Splenic injury in colonoscopy: a review. *Int J Surg* 2009; **7**: 424-427 [PMID: 19638324 DOI: 10.1016/j.ijssu.2009.07.010]
- 7 Keeven N, Inboriboon PC. A Case of Splenic Laceration Presenting as a Delayed Complication of Colonoscopy. *J Emerg Med* 2019; **56**: 437-440 [PMID: 30826082 DOI: 10.1016/j.jemermed.2019.01.003]
- 8 Suliman I, Guirguis J, Chyshkevych I, Dabage NF. Splenic Injury with Subsequent Pleural Effusion: An Underreported Complication of Colonoscopy. *Case Rep Gastroenterol* 2019; **13**: 6-11 [PMID: 30792617 DOI: 10.1159/000494917]
- 9 Diéguez Castillo C, López de Hierro M, Redondo-Cerezo E. Splenic rupture: an infrequent but potentially severe complication after colonoscopy. *Rev Esp Enferm Dig* 2019; **111**: 82-83 [PMID: 30345780 DOI: 10.17235/reed.2018.5719/2018]
- 10 Laanani M, Coste J, Blotière PO, Carbonnel F, Weill A. Patient, Procedure, and Endoscopist Risk Factors for Perforation, Bleeding, and Splenic Injury After Colonoscopies. *Clin Gastroenterol Hepatol* 2019; **17**: 719-727.e13 [PMID: 30099110 DOI: 10.1016/j.cgh.2018.08.005]
- 11 Zhang AN, Sherigar JM, Guss D, Mohanty SR. A delayed presentation of splenic laceration and hemoperitoneum following an elective colonoscopy: A rare complication with uncertain risk factors. *SAGE Open Med Case Rep* 2018; **6**: 2050313X18791069 [PMID: 30083323 DOI: 10.1177/2050313X18791069]
- 12 Chime C, Ishak C, Kumar K, Kella V, Chilimuri S. Splenic Trauma during Colonoscopy: The Role of Intra-Abdominal Adhesions. *Case Rep Gastrointest Med* 2018; **2018**: 4879413 [PMID: 29862094 DOI: 10.1155/2018/4879413]
- 13 Ungprasert P, Jaruvongvanich V. Splenic Injury: An Unusual Complication of Colonoscopy. *Chin Med J (Engl)* 2018; **131**: 372-373 [PMID: 29363661 DOI: 10.4103/0366-6999.223864]
- 14 Laiz Díez B, García Muñoz Najara A, Durán Poveda M. A rare complication after colonoscopy: a splenic rupture. *Rev Esp Enferm Dig* 2018; **110**: 209 [PMID: 29332403 DOI: 10.17235/reed.2018.5362/2017]

- 15 **Barbeiro S**, Atalaia-Martins C, Marcos P, Nobre J, Gonçalves C, Aniceto C. Splenic Rupture as a Complication of Colonoscopy. *GE Port J Gastroenterol* 2017; **24**: 188-192 [PMID: [29255749](#) DOI: [10.1159/000452695](#)]
- 16 **Li S**, Gupta N, Kumar Y, Mele F. Splenic laceration after routine colonoscopy, a case report of a rare iatrogenic complication. *Transl Gastroenterol Hepatol* 2017; **2**: 49 [PMID: [28616605](#) DOI: [10.21037/tgh.2017.04.11](#)]
- 17 **Nallayici EG**, de Groot R, van Zanten RAA, Lutke Holzik MF. Shock due to Splenic Injury after Colonoscopy. *Case Rep Gastroenterol* 2017; **11**: 127-133 [PMID: [28611565](#) DOI: [10.1159/000455940](#)]
- 18 **Cullinane C**, Gudyma J, McArdle G. Emergency splenectomy postelective colonoscopy. *BMJ Case Rep* 2017; 2017 [PMID: [28473360](#) DOI: [10.1136/bcr-2016-219083](#)]
- 19 **Pavlidis E**, Gkizas I, Mavromati O, Milonakis N, Syrianos K. Splenic injury following elective colonoscopy: a rare complication. *J Surg Case Rep* 2016; 2016 [PMID: [28003318](#) DOI: [10.1093/jscr/rjw214](#)]
- 20 **Steele DC**, Mohamed AM, Kaza A, McCarthy D. Splenic Rupture Following Colonoscopy. *Dig Dis Sci* 2017; **62**: 72-75 [PMID: [27822772](#) DOI: [10.1007/s10620-016-4364-2](#)]
- 21 **Ozogul B**, Kisaoglu A, Bayramoglu A, Kara S, Aksungur N. Laparoscopic Splenectomy Due to Splenic Injury after Colonoscopy. *Eurasian J Med* 2016; **48**: 153-155 [PMID: [27551182](#) DOI: [10.5152/eurasian-jmed.2015.15040](#)]
- 22 **Jehangir A**, Poudel DR, Masand-Rai A, Donato A. A systematic review of splenic injuries during colonoscopies: Evolving trends in presentation and management. *Int J Surg* 2016; **33** Pt A: 55-59 [PMID: [27479605](#) DOI: [10.1016/j.ijsu.2016.07.067](#)]
- 23 **Kelly B**, Heneghan H, Carroll P, McDermott E. A complicated case of splenic injury after colonoscopy - a video vignette. *Colorectal Dis* 2016; **18**: 920-921 [PMID: [27454078](#) DOI: [10.1111/codi.13469](#)]
- 24 **McCarty TR**, Liu A, Njei B. Splenic Injury and Hemoperitoneum as a Complication of Colonoscopy: A Case Report and Literature Review. *Conn Med* 2016; **80**: 217-221 [PMID: [27265925](#)]
- 25 **Kapur V**, Krikhely M, Leitman IM. Operative Management of Splenic Rupture and Hepatic Flexure Injury during Diagnostic Colonoscopy in a Patient with Adenocarcinoma of the Cecum and Pulmonary Embolism. *J Am Coll Surg* 2016; **222**: e9 [PMID: [27222892](#) DOI: [10.1016/j.jamcollsurg.2015.11.023](#)]
- 26 **Zappa MA**, Aiolfi A, Antonini I, Musolino CD, Porta A. Splenic rupture following colonoscopy: Case report and literature review. *Int J Surg Case Rep* 2016; **21**: 118-120 [PMID: [26971282](#) DOI: [10.1016/j.ijscr.2016.02.038](#)]
- 27 **Mulkerin W**, Mitarai T, Gharahbaghian L, Perera P. Splenic Rupture Diagnosed with Bedside Ultrasound in a Patient with Shock in the Emergency Department Following Colonoscopy. *West J Emerg Med* 2015; **16**: 758-759 [PMID: [26587104](#) DOI: [10.5811/westjem.2015.6.27548](#)]
- 28 **García García MJ**, Castañera González R, Martín Rivas B, Gómez Ruiz M, Rivero Tirado M. Splenic rupture after colorectal cancer screening. *Rev Esp Enferm Dig* 2015; **107**: 705-706 [PMID: [26541662](#) DOI: [10.17235/reed.2015.3714/2015](#)]
- 29 **Sbai H**, Boukatta B, El Bouazzaoui A, Youssfi M, Mellouki I, Benajeh DA, Bobo M, Bohadouti H, Tizniti S, Ibrahim A, Taleb KA, Kanjaa N. [Rare complication of colonoscopy in a patient on anticoagulant: haemoperitoneum by rupture of a subcapsular hematoma of the spleen, clinical case]. *Pan Afr Med J* 2015; **21**: 232 [PMID: [26523174](#) DOI: [10.11604/pamj.2015.21.232.1920](#)]
- 30 **Asadi H**, Rhodes A, Mitchell P, Dowling R. Colonoscopic blunt splenic injury: a rare but an important complication. *ANZ J Surg* 2018; **88**: E218-E219 [PMID: [26464080](#) DOI: [10.1111/ans.13327](#)]
- 31 **Ng P**. Splenic injury as a complication of colonoscopy: more common than we think? *BMJ Case Rep* 2015; 2015 [PMID: [26354835](#) DOI: [10.1136/bcr-2015-209707](#)]
- 32 **Mazulis A**, Lakha A, Qazi B, Shapiro A. Delayed Presentation of Splenic Rupture After Endoscopy in a Patient With Hemophilia A: Case Report and Review of the Literature. *ACG Case Rep J* 2014; **1**: 175-177 [PMID: [26157867](#) DOI: [10.14309/crj.2014.43](#)]
- 33 **Kapur V**, Krikhely M, Leitman IM. Operative management of splenic rupture and hepatic flexure injury during diagnostic colonoscopy in a patient with adenocarcinoma of the cecum. *J Surg Case Rep* 2015; 2015 [PMID: [25786438](#) DOI: [10.1093/jscr/rjv021](#)]
- 34 **Han SH**, Lee JH, Kim SH. Splenic rupture following colon polypectomy: a case report and review of literature. *Korean J Gastroenterol* 2015; **65**: 123-126 [PMID: [25716716](#) DOI: [10.4166/kjg.2015.65.2.123](#)]
- 35 **Afshari K**, Stender MT, Thorlacius-Ussing O. [Splenic injury after sigmoidoscopy]. *Ugeskr Laeger* 2015; **177**: 64-65 [PMID: [25612971](#)]
- 36 **Meseguer Ripollés Á**, Fernández Ruiz C. [Splenic laceration: a rare complication of optical colonoscopy]. *Radiologia* 2015; **57**: 360-361 [PMID: [25554117](#) DOI: [10.1016/j.rx.2014.11.002](#)]
- 37 **Hettema M**, Wolt S, van der Neut FW. [Splenic injury as a complication of colonoscopy]. *Ned Tijdschr Geneesk* 2014; **158**: A8006 [PMID: [25336313](#)]
- 38 **Brennan IM**, Faintuch S, Sacks B. Supraselective splenic artery embolization for the management of splenic laceration following colonoscopy. *Acta Radiol Short Rep* 2014; **3**: 2047981614524199 [PMID: [25298862](#) DOI: [10.1177/2047981614524199](#)]
- 39 **Herreros de Tejada A**, Giménez-Alvira L, Van den Brule E, Sánchez-Yuste R, Matallanos P, Blázquez E, Calleja JL, Abreu LE. Severe splenic rupture after colorectal endoscopic submucosal dissection. *World J Gastroenterol* 2014; **20**: 9618-9620 [PMID: [25071360](#) DOI: [10.3748/wjg.v20.i28.9618](#)]
- 40 **Lauretta A**, Busuito G, Bellomo RE. Splenic injury during colonoscopy: a complication hardly thought hence hardly sought. *Am Surg* 2014; **80**: E111-E113 [PMID: [24887654](#)]
- 41 **Chen SH**, Ong JR, Ma HP, Chen PS. Hemoperitoneum due to Splenic Laceration Caused by Colonoscopy: A Rare and Catastrophic Complication. *Case Rep Emerg Med* 2014; **2014**: 985648 [PMID: [24826357](#) DOI: [10.1155/2014/985648](#)]
- 42 **Jamorabo D**, Feller E. Syncope as the presenting feature of splenic rupture after colonoscopy. *Case Rep Gastrointest Med* 2014; **2014**: 825892 [PMID: [24782929](#) DOI: [10.1155/2014/825892](#)]
- 43 **Primavesi F**, Holzinger J, Öfner D, Hutter J. [Splenic Rupture after Colonoscopy: Case Series and Review of the Literature]. *Zentralbl Chir* 2015; **140**: 453-455 [PMID: [23824610](#) DOI: [10.1055/s-0032-1328355](#)]
- 44 **Guner A**, Kaya U, Kece C, Kucuktulu U. Is non-operative management feasible for splenic injury due to colonoscopy? *BMJ Case Rep* 2013; 2013 [PMID: [23774704](#) DOI: [10.1136/bcr-2013-009286](#)]
- 45 **McBride R**, Dasari B, Magowan H, Mullan M, Yousaf M, Mackle E. Splenic injury after colonoscopy requiring splenectomy. *BMJ Case Rep* 2013; 2013 [PMID: [23737576](#) DOI: [10.1136/bcr-2013-009126](#)]
- 46 **Rex DK**. Colonoscopic splenic injury warrants more attention. *Gastrointest Endosc* 2013; **77**: 941-943 [PMID: [23477750](#) DOI: [10.1016/j.gie.2013.01.045](#)]
- 47 **Chow MD**, Shih RD. Acute colonoscopy-induced splenic rupture presenting to the emergency department.

- Case Rep Emerg Med* 2013; **2013**: 436874 [PMID: 23476824 DOI: 10.1155/2013/436874]
- 48 **Pineda L**, Sarhan M, Suman P, Lloyd-Smith A, Chua A. Splenic rupture after screening colonoscopy. *Am Surg* 2013; **79**: E43-E44 [PMID: 23317606 DOI: 10.2106/JBJS.K.01219]
 - 49 **Corcillo A**, Aellen S, Zingg T, Bize P, Demartines N, Denys A. Endovascular treatment of active splenic bleeding after colonoscopy: a systematic review of the literature. *Cardiovasc Intervent Radiol* 2013; **36**: 1270-1279 [PMID: 23262476 DOI: 10.1007/s00270-012-0539-1]
 - 50 **Abunnaja S**, Panait L, Palesty JA, Macaron S. Laparoscopic splenectomy for traumatic splenic injury after screening colonoscopy. *Case Rep Gastroenterol* 2012; **6**: 624-628 [PMID: 23139653 DOI: 10.1159/000343428]
 - 51 **González-Soler R**, Castro-Ortiz E, Lancho-Seco Á, García-Suárez C, Santos-Blanco E, Carral-Martínez D, Avila-Nasi S, González-Ramírez A, López-Rosés L. Splenic rupture following diagnostic colonoscopy. *Rev Esp Enferm Dig* 2012; **104**: 219-220 [PMID: 22537374 DOI: 10.4321/S1130-01082012000400011]
 - 52 **Seifman MA**, Freeman LA, Tryfonopoulos J. Delayed splenectomy following colonoscopy-associated splenic injury. *ANZ J Surg* 2012; **82**: 96-97 [PMID: 22507520 DOI: 10.1111/j.1445-2197.2011.05948.x]
 - 53 **Buchwald P**, Lindmark G. [Splenic injury in colonoscopy--potentially fatal complications]. *Lakartidningen* 2011; **108**: 2436-2437 [PMID: 22468385]
 - 54 **Singla S**, Keller D, Thirunavukarasu P, Tamandl D, Gupta S, Gaughan J, Dempsey D. Splenic injury during colonoscopy--a complication that warrants urgent attention. *J Gastrointest Surg* 2012; **16**: 1225-1234 [PMID: 22450952 DOI: 10.1007/s11605-012-1871-0]
 - 55 **Yagnik VD**. Splenic rupture following routine colonoscopy. *Dig Endosc* 2012; **24**: 51 [PMID: 22211415 DOI: 10.1111/j.1443-1661.2011.01130.x]
 - 56 **Shankar S**, Rowe S. Splenic injury after colonoscopy: case report and review of literature. *Ochsner J* 2011; **11**: 276-281 [PMID: 21960762]
 - 57 **Ghevariya V**, Kevorkian N, Asarian A, Anand S, Krishnaiah M. Splenic injury from colonoscopy: a review and management guidelines. *South Med J* 2011; **104**: 515-520 [PMID: 21886052 DOI: 10.1097/SMJ.0b013e31821e9283]
 - 58 **Fishback SJ**, Pickhardt PJ, Bhalla S, Menias CO, Congdon RG, Macari M. Delayed presentation of splenic rupture following colonoscopy: clinical and CT findings. *Emerg Radiol* 2011; **18**: 539-544 [PMID: 21887533 DOI: 10.1007/s10140-011-0982-3]
 - 59 **Bertoglio C**, Roscio F, De Luca A, Colico C, Scandroglio I. Delayed presentation of splenic injury following diagnostic colonoscopy. *Updates Surg* 2012; **64**: 77-79 [PMID: 21660616 DOI: 10.1007/s13304-011-0086-3]
 - 60 **Casanova Martínez L**, Martín Arranz E, Vázquez López P, Jaquotot Herranz M, Mora Sanz P, Segura Cabral JM. [Splenic rupture after colonoscopy. An unusual complication]. *Gastroenterol Hepatol* 2011; **34**: 588-589 [PMID: 21592621 DOI: 10.1016/j.gastrohep.2011.03.010]
 - 61 **Sachdev S**, Thangarajah H, Keddington J. Splenic rupture after uncomplicated colonoscopy. *Am J Emerg Med* 2012; **30**: 515.e1-515.e2 [PMID: 21450434 DOI: 10.1016/j.ajem.2011.01.013]
 - 62 **Meier RP**, Toso C, Volonte F, Mentha G. Splenic rupture after colonoscopy. *Am J Emerg Med* 2011; **29**: 241.e1-241.e2 [PMID: 20825894 DOI: 10.1016/j.ajem.2010.02.025]
 - 63 **Monzón Vázquez TR**, Ruiz Yagüe M, Jiménez R. [Post-colonoscopy spleen rupture]. *Med Clin (Barc)* 2011; **136**: 89 [PMID: 20045137 DOI: 10.1016/j.medcli.2009.11.008]
 - 64 **Levin TR**, Zhao W, Conell C, Seeff LC, Manninen DL, Shapiro JA, Schulman J. Complications of colonoscopy in an integrated health care delivery system. *Ann Intern Med* 2006; **145**: 880-886 [PMID: 17179057 DOI: 10.7326/0003-4819-145-12-200612190-00004]
 - 65 **Kamath AS**, Iqbal CW, Sarr MG, Cullinane DC, Zietlow SP, Farley DR, Sawyer MD. Colonoscopic splenic injuries: incidence and management. *J Gastrointest Surg* 2009; **13**: 2136-2140 [PMID: 19830501 DOI: 10.1007/s11605-009-1064-7]
 - 66 **Cooper GS**, Kou TD, Rex DK. Complications following colonoscopy with anesthesia assistance: a population-based analysis. *JAMA Intern Med* 2013; **173**: 551-556 [PMID: 23478904 DOI: 10.1001/jamainternmed.2013.2908]
 - 67 **Janes SE**, Cowan IA, Dijkstra B. A life threatening complication after colonoscopy. *BMJ* 2005; **330**: 889-890 [PMID: 15831876 DOI: 10.1136/bmj.330.7496.889]
 - 68 **Sarhan M**, Ramcharan A, Ponnappalli S. Splenic injury after elective colonoscopy. *JSLs* 2009; **13**: 616-619 [PMID: 20202406]
 - 69 **Skipworth JR**, Raptis DA, Rawal JS, Olde Damink S, Shankar A, Malago M, Imber C. Splenic injury following colonoscopy--an underdiagnosed, but soon to increase, phenomenon? *Ann R Coll Surg Engl* 2009; **91**: W6-11 [PMID: 19416579 DOI: 10.1308/147870809X400994]
 - 70 **Saunders BP**, Fukumoto M, Halligan S, Jobling C, Moussa ME, Bartram CI, Williams CB. Why is colonoscopy more difficult in women? *Gastrointest Endosc* 1996; **43**: 124-126 [PMID: 8635705 DOI: 10.1016/s0016-5107(06)80113-6]
 - 71 **Shatz DV**, Rivas LA, Doherty JC. Management options of colonoscopic splenic injury. *JSLs* 2006; **10**: 239-243 [PMID: 16882428]
 - 72 **Duarte CG**. Splenic rupture after colonoscopy. *Am J Emerg Med* 2008; **26**: 117.e1-117.e3 [PMID: 18082812 DOI: 10.1016/j.ajem.2007.07.020]
 - 73 **Colarian J**, Alousi M, Calzada R. Splenic trauma during colonoscopy. *Endoscopy* 1991; **23**: 48-49 [PMID: 2009840 DOI: 10.1055/s-2007-1010608]
 - 74 **van der Vlies CH**, Hoekstra J, Ponsen KJ, Reekers JA, van Delden OM, Goslings JC. Impact of splenic artery embolization on the success rate of nonoperative management for blunt splenic injury. *Cardiovasc Intervent Radiol* 2012; **35**: 76-81 [PMID: 21431976 DOI: 10.1007/s00270-011-0132-z]



Published By Baishideng Publishing Group Inc
7041 Koll Center Parkway, Suite 160, Pleasanton, CA 94566, USA
Telephone: +1-925-3991568
E-mail: bpgoffice@wjgnet.com
Help Desk: <https://www.f6publishing.com/helpdesk>
<https://www.wjgnet.com>

