

Challenges of liver cancer: Future emerging tools in imaging and urinary biomarkers

Francesca M Trovato, Joshua M Tognarelli, Mary ME Crossey, Daniela Catalano, Simon D Taylor-Robinson, Guglielmo M Trovato

Francesca M Trovato, Daniela Catalano, Guglielmo M Trovato, Dipartimento di Medicina Clinica e Sperimentale, Scuola di Medicina, Università di Catania, 95100 Catania, Italy

Joshua M Tognarelli, Mary ME Crossey, Simon D Taylor-Robinson, Department of Medicine, Imperial College London, St Mary's Campus, London W2 1NY, United Kingdom

Author contributions: All authors contributed to this manuscript.

Conflict-of-interest statement: No relevant or potential conflict of interest is present for any of the authors.

Open-Access: This article is an open-access article which was selected by an in-house editor and fully peer-reviewed by external reviewers. It is distributed in accordance with the Creative Commons Attribution Non Commercial (CC BY-NC 4.0) license, which permits others to distribute, remix, adapt, build upon this work non-commercially, and license their derivative works on different terms, provided the original work is properly cited and the use is non-commercial. See: <http://creativecommons.org/licenses/by-nc/4.0/>

Correspondence to: Guglielmo M Trovato, MD, Dipartimento di Medicina Clinica e Sperimentale, Scuola di Medicina, Università di Catania, Via Santa Sofia 78, 95100 Catania, Italy. guglielmotrovato@unict.it
Telephone: +39-09-5371533

Received: June 22, 2015

Peer-review started: June 22, 2015

First decision: August 25, 2015

Revised: September 24, 2015

Accepted: October 23, 2015

Article in press: October 27, 2015

Published online: November 18, 2015

obesity and alcohol misuse. Over the past three decades, in the United Kingdom alone, deaths from chronic liver disease have increased both in men and in women. Currently, 2.5% of deaths worldwide are attributed to liver disease and projected figures suggest a doubling in hospitalisation and associated mortality by 2020. Chronic liver diseases vary for clinical manifestations and natural history, with some individuals having relatively indolent disease and others with a rapidly progressive course. About 30% of patients affected by hepatitis C has a progressive disease and develop cirrhosis over a 20 years period from the infection, usually 5-10 years after initial medical presentation. The aim of the current therapeutic strategies is preventing the progression from hepatitis to fibrosis and subsequently, cirrhosis. Hepatic steatosis is a risk factor for chronic liver disease and is affecting about the half of patients who abuse alcohol. Moreover non-alcoholic fatty liver disease is part of the metabolic syndrome, associated with obesity, hypertension, type II diabetes mellitus and dyslipidaemia, and a subgroup of patients develops non-alcoholic steatohepatitis and fibrosis with subsequent cirrhosis. The strengths and pitfalls of liver biopsy are discussed and a variety of new techniques to assess liver damage from transient elastography to experimental techniques, such as *in vitro* urinary nuclear magnetic resonance spectroscopy. Some of the techniques and tests described are already suitable for more widespread clinical application, as is the case with ultrasound-based liver diagnostics, but others, such as urinary metabolomics, requires a period of critical evaluation or development to take them from the research arena to clinical practice.

Key words: Virus hepatitis; Liver cancer; Ultrasound; Fibrosis; Urinary biomarkers

© The Author(s) 2015. Published by Baishideng Publishing Group Inc. All rights reserved.

Core tip: There is an increasing need for non-invasive

Abstract

Chronic liver disease has become a global health problem as a result of the increasing incidence of viral hepatitis,

assessment of liver disease. New techniques to assess liver damage from transient elastography to experimental techniques, such as *in vitro* urinary nuclear magnetic resonance spectroscopy are currently investigated. The guidelines of sustainability in countries with limited resources, facilities and low financial income can be seen as an opportunity for addressing research toward low-cost diagnostics and for driving clinical practice toward more streamlined technology, with ultimate benefits for the populations of poorer countries around the world. In this perspective, urinary biomarkers of liver cancer and ultrasound imaging are two complementary models.

Trovato FM, Tognarelli JM, Crossey MME, Catalano D, Taylor-Robinson SD, Trovato GM. Challenges of liver cancer: Future emerging tools in imaging and urinary biomarkers. *World J Hepatol* 2015; 7(26): 2664-2675 Available from: URL: <http://www.wjgnet.com/1948-5182/full/v7/i26/2664.htm> DOI: <http://dx.doi.org/10.4254/wjh.v7.i26.2664>

INTRODUCTION

“Nothing strengthens authority so much as silence”:

Leonardo da Vinci

Many relevant reviews are available on chronic liver disease and on one of its major complications, hepatocellular carcinoma (HCC), and the most significant advances in diagnosis, management, and long-term outcome are appropriately considered and well-focused^[1]. By contrast, this brief overview has the aim of summarizing some epidemiological and clinical concepts, highlighting some of the current diagnostic criteria used for addressing personalized therapeutic choices, and discussing briefly some practical and ethical challenges. The latter problems are also the consequence of a global economy and of the current research approach, which we have to consider from the perspective of sustainability^[2].

The most frequent liver cancer, accounting for 80%-90% of all primary liver cancers, is HCC, but there are critical differences in the diagnostic algorithms. Differences are due not only to the skills and knowledge of pathologists, but also to the actual availability of such diagnostic facilities in most countries, particularly where liver cancer is more frequent. Sadly, there are countries in which only one surgical pathology laboratory is available: This is the case of Zambia, a country with 12 million inhabitants, while until recently, Liberia had no diagnostic laboratory services, owing to the ravages of a prolonged civil war. With this limitation and shortage of expertise, frequent even in developed countries, surrogate tools for reliable diagnosis are warranted, beside the fact that reducing the number of invasive procedures also has great appeal. The Italian Association of Pathologists, “Patologi Oltre Frontiera”, has been working in Africa since 2004 to create a virtual laboratory with telemedicine^[3]. This is a very important approach,

equally useful in countries with large populations, such as China^[4]. The use of this approach as a continuous tool for training, by plain e-learning technology, provides valuable results in both the developed and the developing world^[5,6], while new developments using emerging e-learning technologies and smartphone applications are steadily becoming a reality. In general, international research partnerships and potential clinical applications are receiving ever greater attention, given that technology has diminished the restriction of geographical barriers with the effects of globalisation becoming more evident, and populations increasingly more mobile^[7].

The implications are manifold, and among them, the opportunity of assessing new diagnostic tools where there are emerging or more prevalent diseases, such as viral hepatitis, non-alcoholic fatty liver disease (NAFLD) and liver cancer. In this setting, international collaboration should move research goals away from pure market forces and towards humanitarian aims. Indeed, encompassing this second aim, the profession and the mission of medical intervention will contribute to peaceful cohesion and ultimately to shared economic profits.

The pathophysiology of HCC has been attributed to chronic inflammation associated with a variety of disease processes, but on a worldwide scale, mainly due to viral hepatitis B virus (HBV) and hepatitis C virus (HCV). Nonetheless, cirrhosis is not the absolute pre-condition for the further development of cancer. HCC onset is associated with active HBV or HCV infection, but also its incidence increases with age, alcohol consumption, smoking, human immunodeficiency virus (HIV) infection, obesity and diabetes. In this regard, the concurrent effect of NAFLD is becoming all the more important, owing to an increasingly obese population, not only in Western Europe and North America, but also in the developing world^[8]. Since it is possible to reverse much of the pathology seen in fatty liver disease through lifestyle change, such as exercise and dietary modification^[9,10], it is quite surprising that the two paths of research and therapeutic intervention are not more closely allied in a translational approach, as in many places they are still separated, much like the tracks of a railroad^[11].

The increase seen in chronic liver disease and HCC, confirmed and increasing in Europe for 20 years or more, is due to a multiplicity of factors, and not just to HCV-induced hepatitis^[12]. The same increasing trend of incidence, possibly due to improved diagnostic tools, is reported worldwide for cholangiocarcinoma^[13], the causes of which^[14] are even less directly attributable to the same factors as HCC^[15]. Cholangiocarcinoma is more insidious in its onset, with elusive clinical features devastating and scarcely responsive clinical progress.

It is clear that a strategy for eradication of HBV and prevention of its consequences must include an effective campaign of successful widespread vaccination, with birth dose vaccination in the developing world, owing to the high prevalence of mother to baby transmission. As this is not possible yet for HCV infection, antiviral therapy regimens for HCV have been burdensome for

the patient and expensive for healthcare systems, and until recently, with poor sustained viral response rates to antiviral medications. Nonetheless, overall there is only weak evidence, if any, of a beneficial effect of viral eradication on the subsequent occurrence of liver cancer in such treated patients with cirrhosis^[16].

The mainstay of diagnosis has been liver biopsy for many years, but now a variety of alternatives are beginning to emerge.

Liver biopsy techniques

A liver aspirate was performed for the first time in 1883 by a German physician, Paul Ehrlich, while the percutaneous liver biopsy technique dates back to the 1920s. Fifty years later the radiologist Charles Dotter invented the transjugular approach^[17]. Several pre-procedural precautions need to be taken, including prior knowledge of the patient's anatomy with a screening liver ultrasound, an up-to-date platelet count and a clotting screen. Many conditions, such as high bleeding risk, are contraindications to standard percutaneous approaches, partially or completely^[18]. However, liver biopsy remains the gold-standard for assessing the severity of chronic liver diseases.

Requirement for biomarkers of liver fibrosis

Effective antiviral therapies and the advent of antifibrotic drugs have led to an increasing demand for non-invasive, accurate and reliable biomarkers of hepatic disease severity. It is recognised that the current "gold standard" for monitoring the severity of fibrosis, histological analysis of liver biopsy, has limitations and engenders risk to the patient with a defined morbidity, including pain, bleeding, time off work and a mortality rate of between one in 1000 and one in 10000 cases^[18]. The specimen retrieved by standard liver biopsy is just 1/50000 of the total volume of the liver, and in about 16% of cases the sample exceeds the optimal length for adequate histological assessment of 25 mm^[19]. This causes sampling variability and errors since inflammation, hepatic fibrosis and steatosis may all have an irregular distribution within the liver. In addition, as histological scoring systems are semi-quantitative categorical assessments of a continuous process (fibrogenesis), there is appreciable intra- and inter- observer variability.

A safe, reliable, non-invasive imaging approach for detecting hepatic fibrosis would obviate the hazards associated with liver biopsy and allow patients to be monitored serially with a view to prevent the decline towards cirrhosis and its complications. Accordingly, there are potential health economic benefits from prevention of end-stage disease and the reversal of less severe fibrosis.

Non-invasive assessment of chronic liver diseases

The non-invasive assessment of the severity of chronic liver disease includes the development of serum (or blood) markers, which may be divided into direct or indirect tests, either singly, or combined as serum panel

markers, and the application of imaging-based technologies, such as ultrasound and magnetic resonance (MR) techniques.

Serum markers

Serum may be obtained at routine venepuncture, making it quick and acceptable to most patients. Sampling variability is negated, although site-specificity to hepatic processes may be questioned. Serum markers may broadly be divided into indirect and direct markers of hepatic fibrosis. Indirect markers are those where the indices measured correlate with fibrosis stage, but are not integral to the pathogenesis of disease. Such markers include "so-called" liver function tests, such as aspartate aminotransferase (AST) and alanine aminotransferases, and composite or panel markers, such as the AST-to-platelet ratio index (APRI) and the fibrotest/actitest markers.

On the other hand, direct markers are those measuring intermediates or metabolites of fibrogenesis, such as hyaluronic acid and panel markers such as the Enhanced Liver Fibrosis test, consisting of metalloproteinase-1, procollagenase 3 and hyaluronic acid. The performance of a number of these tests for the detection of cirrhosis is displayed in Table 1^[20].

Imaging-based markers

Imaging techniques, particularly those based on ultrasound and MR, often provide hepatic structural information. Although a number of structural changes are associated with cirrhosis and portal hypertension, these signs alone are neither sensitive nor specific enough to stage chronic liver disease. A number of specialized applications have, however, shown promise and imaging techniques have the added benefit of providing real-time information to the operator and patient.

Transient elastography

Transient elastography is an ultrasound based technique that evaluates the velocity of propagation of a low-frequency shear wave through the liver (Figure 1). This is dependent on the "stiffness" of the liver and reflects the degree of fibrosis. FibroScan® (Echosens, Paris, France) is the equipment dedicated to apply this technology and its performance has been scrutinised in a large number of studies over the last decade^[21].

However, while transient elastography performs well for the assessment of cirrhosis, with sensitivity and specificity quoted between 77% and 100%, there has been less clear separation of stages of pre-cirrhotic disease^[21]. Cut-off values reported by different studies to assess histological stages are variable according to the kind of patients selected and aetiology of disease.

More recently, liver stiffness has been shown to increase in flares of viral hepatitis and in acute hepatitis, even up to the levels seen in cirrhosis, but in the absence of clinically significant fibrosis. Further studies have demonstrated a compelling correlation between liver stiffness and portal pressure, while cardiac failure,

Table 1 Examples of serum markers for the assessment of fibrosis

Name	Constituents	Accuracy (%)			
		Se	Sp	PPV	NPV
Indirect markers					
APRI	AST, platelets	41	95	88	64
FibroTest	$\alpha 2$ macroglobulin, $\alpha 2$ and γ globulin, total bilirubin, apolipoprotein A1, γ GT	87	59	63	85
Direct markers					
ELF	P III NP, HA, TIMP-1, (age)	90.5	41	99	92
FibroSpect	HA, TIMP-1, $\gamma 2$ macroglobulin	77	73	74	76

APRI: Aspartate aminotransferase (AST) to platelet ratio index; γ GT: γ -glutamyl transpeptidase; HA: Hyaluronic acid; P III NP: Amino terminal of procollagenase III; TIMP-1: Tissue inhibitor of matrix metalloproteinase 1; ELF: Enhanced Liver Fibrosis test; Se: Sensitivity; Sp: Specificity; PPV: Positive predictive value; NPV: Negative predictive value.

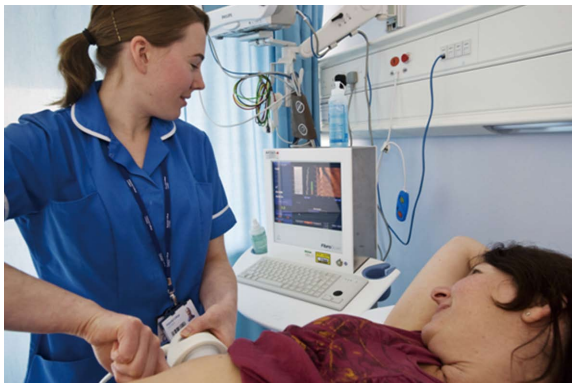

Figure 1 Transient elastography. A specialist nurse places the probe perpendicular to the surface of the liver. A low frequency shear wave is generated along the same axis as the ultrasound transducer. The velocity of the shear wave through the liver is measured by a high frequency ultrasound signal and the output displayed as stiffness, in kPa, alongside a two-dimensional "elastogram". The output is the median of 10 measurements, with a success rate of > 66% and an interquartile range of measurements < 1/3 of the median considered satisfactory.

infiltrative conditions and even hepatic steatosis may affect stiffness values.

On the contrary of what was initially assumed, the sole liver stiffness cannot be considered a measure of hepatic fibrosis, but rather the result of different processes including fibrosis. Thus the results should be interpreted according to the clinical context and corroborated by other non-invasive techniques.

Use of ultrasound contrast agents

Microbubble contrast agents are small, stabilised gas-filled phospholipid bubbles (about 3 μ m) that resonate when subjected to ultrasound, amplifying the reflected signal, thus enhancing intravascular signal for several minutes after intravenous injection and increasing signal from vessels and tissues. Safety and tolerance with current agents is excellent. When quantified, the resultant signal intensity change is proportional to microbubble concentration^[22].

A simple microbubble-enhanced ultrasound test to measure hepatic vascular transit time (HVTT) by timing the arrival of contrast agent in the hepatic artery and subsequently the hepatic vein has been developed. A curve of signal intensity against time can be plotted,

with shorter arrival times correlating with increased severity of liver disease due to circulatory changes, such as arterialisatation of liver sinusoids, hyperdynamic circulation and extra- and intra-hepatic shunting (Figure 2). A study on 85 chronic hepatitis C patients assessed by HVTT showed 100% sensitivity and 80% specificity for cirrhosis^[22]. Moreover microbubbles allowed to stratify mild and moderate disease (95% sensitivity and 86% specificity) suggesting that other processes, besides portal hypertension, may contribute to effects observed.

MR techniques

Both MR imaging (MRI) and MR spectroscopy (MRS) techniques have been applied to assess the severity of chronic liver diseases^[23]. MRI techniques include dynamic superparamagnetic iron oxide and gadolinium enhanced studies, which have been shown to demonstrate reticular-nodular patterns, thought to represent septal hepatic fibrosis, allowing the qualitative discrimination of moderate to severe, from mild fibrosis. Objective stratification of fibrosis severity in patients with chronic hepatitis C has been reported using diffusion-weighted MRI^[24]. Furthermore, MR elastography, which like transient elastography measures liver stiffness, allows visualisation of a map of hepatic liver stiffness^[25]. MRS examines the chemico-physical environment of nuclei in a region of interest, providing metabolic information in the form of a spectrum, of relevance in chronic liver disease.

MR spectroscopy

In vivo ^{31}P MRS is a safe, reproducible technique which provides biochemical information on hepatic metabolic processes. Typical *in vivo* ^{31}P MR liver spectra contain phosphomonoester (PME), phosphodiester (PDE), inorganic phosphate (Pi) and ATP resonances, reflecting cellular energy state, intermediates of carbohydrate metabolism, precursors of cell membrane synthesis and breakdown. These resonances are multicomponent, but more detailed biochemical information may be obtained with *in vitro* MRS at higher magnetic field strengths (11.7 T-14.0 T) than in clinical studies (1.5 T-3.0 T).

In vivo phosphorus-31 (^{31}P) MRS provides metabolic information useful to evaluate fibrogenesis. The PME/PDE ratio has been used as an index of cell membrane

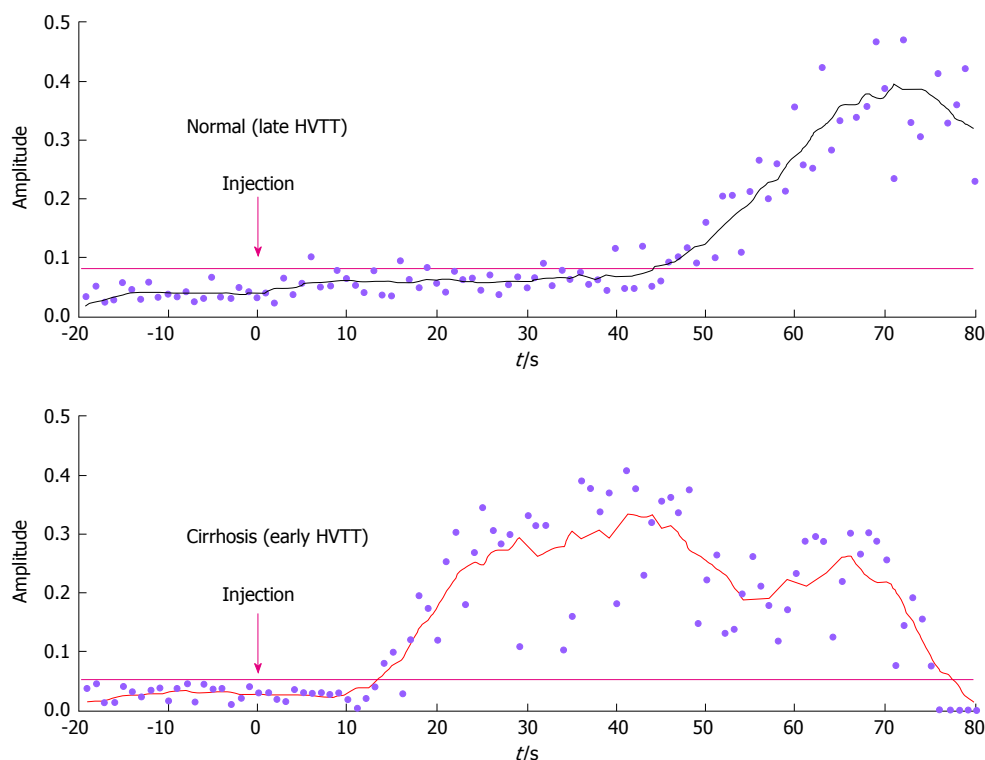


Figure 2 Hepatic vascular transit times. Time intensity curves from the hepatic vein plotted in a normal patient and a patient with cirrhosis, showing earlier arrival of contrast in the cirrhotic liver. Adapted from Lim *et al*^[22] 2005. HVTT: Hepatic vascular transit times.

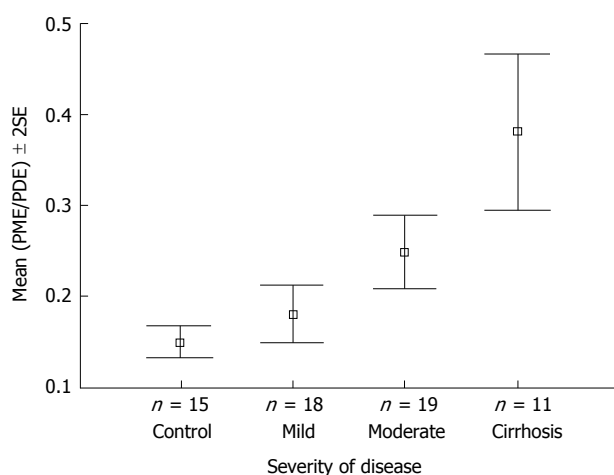


Figure 3 ³¹P magnetic resonance spectroscopy. PME/PDE ratios obtained from *in vivo* hepatic ³¹P MRS varying with severity of hepatitis C-associated liver disease. Adapted from Lim *et al*^[26] 2003. MRS: Magnetic resonance spectroscopy; PME: Phosphomonoester; PDE: Phosphodiester.

turnover and correlates with histological stages. MRS has good sensitivity (82%) and specificity (81%) to detect cirrhosis and could differentiate it from mild hepatitis and moderate hepatitis^[26] (Figure 3).

Recent longitudinal work in chronic hepatitis C has demonstrated a change in PME/PDE ratios in response to antiviral treatment, separating virological responders from non-responders.

MRS in hepatic steatosis

In hepatic steatosis, proton (¹H) MRS can provide

information on the amount of liver fat^[27]. More recent studies have demonstrated the potential to measure lipid composition non-invasively, which may change with disease state and with dietary intervention. Typical hepatic spectra contain water, fat and choline resonances, which can be quantified using external reference standards or expressed as a percentage relative to the total MR signal (Figure 4). ¹H MRS is readily accessible to all centres that have an MR scanner and most machines have the capability to perform such sequences as an addition to a standard MRI examination.

The future of biomarkers of chronic liver disease

Inflammation, steatosis and fibrosis are complex multistep processes. It would be surprising if a single biomarker were able to describe liver disease completely. Accordingly, combinations of markers and modalities may describe disease more accurately and reproducibly than one marker alone. Studies of marker combinations should be performed to establish optimal combinations, in terms of numbers of tests, accuracy of combinations and the provision of complementary information from the test components. Candidate markers differ widely in the equipment and expertise required, so cost-benefit analyses compared to routine liver biopsy are warranted. Serum markers and imaging techniques need to be investigated longitudinally in response to intervention in a number of disease states. As histological assessment of liver biopsy is itself a surrogate marker of liver disease, the challenge is to develop and validate protocols correlated to clinically meaningful outcome measures.

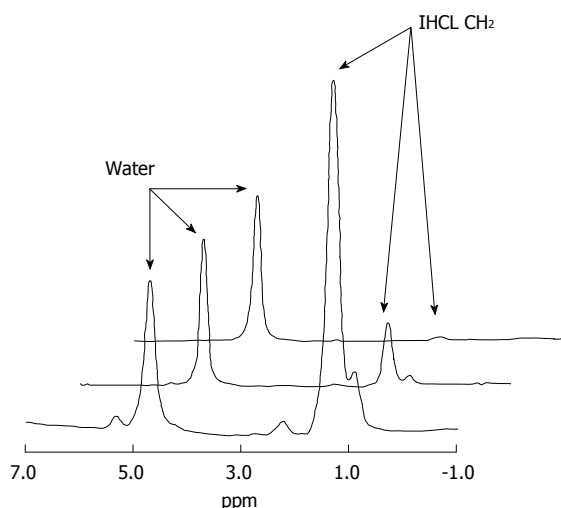


Figure 4 ^1H magnetic resonance spectroscopy. Proton (^1H) MR Spectra (left to right) from: (1) a patient with significant hepatic steatosis; (2) a patient with mild hepatic steatosis; and (3) a healthy volunteer. The intrahepatocellular (IHCL) lipid resonance is many times larger in (1) than (3), with the hepatic water resonance scaled to the same height for comparative purposes. Candidate markers for hepatocellular carcinoma which have been proposed in the literature. Most reflect high cellular turnover exhibited by tumours, but the majority lack sensitivity and specificity (see text for further explanations). Reproduced from Thomas *et al*^[27] 2005. ppm: Parts per million; IHCL CH₂: Intrahepatocellular lipid.

Further research into non-invasive technologies for the assessment of chronic liver disease is required to correlate these techniques with clinical outcomes and to optimise them, in order to create validated management algorithms.

The challenge of a reliable diagnosis by non-invasive imaging

“Don’t spend time beating on a wall, hoping to transform it into a door” Coco Chanel: According to the United States Center for Disease Control, May 2015, (<http://www.cdc.gov/hepatitis/HCV/HCVfaq.htm#section1>) every 100 persons infected with HCV, 75-85 will go on to develop chronic infection, 60-70 will develop chronic liver disease and over a period of 20-30 years 5%-20% will become cirrhotic. The death for liver disease, for cirrhosis or liver cancer involves the 1%-5% of patients infected, since the yearly incidence of HCC in people with cirrhosis is 3%-5%. This is very similar to the recommendation of WHO, which specifies that development of HCC is rare in patients with chronic hepatitis C not complicated by cirrhosis (<http://www.who.int/csr/disease/hepatitis/whocdscsrlyo2003/en/index3.html>).

The current treatment indications for HCV are under a state of flux, owing to the advent of a raft of new directly-acting antiviral agents (DAAs). The current modus vivendi is to allow the use of new drugs according to the presence of severe grades of fibrosis in some countries, but decompensating cirrhosis in others^[17,28]. The grade of fibrosis can be assessed by liver biopsy, but modern algorithms now allow the use of non-invasive ultrasound

procedures, such as transient elastography (Fibroscan[®]) and Acoustic Radiation Force Impulse (ARFI), two methods suitable for measuring the “stiffness” of the liver (LSM).

In the United States, as in Italy, there are reference criteria, *i.e.*, cut-off values, for defining the presence of severe fibrosis. For instance, according to the criteria of the Harvard Pilgrim Health Care, LSM of ≥ 7.5 kPa on Fibroscan[®] should allow the use of DAAs; while according to the Idaho criteria Fibroscan[®] measurement > 12.5 kPa or ARFI value > 1.75 m/s or APRI score > 1.5 should be used. These striking differences are mirrored by the different results reported in the past and are well discussed in the EASL-AASLD clinical practice guidelines^[29]. These variances in cut-off values for treatment are all the more complicated, given how prone the “gold standard”, liver biopsy, is to sampling error and underscoring of fibrosis^[18,19].

With this in mind, we set out to define the non-invasive measures most suitable to be used as cut-off values to define cirrhosis in a prospective case-control study, taking into account co-temporaneous liver biopsies, ARFI and TE measurements in chronic liver disease with different severity of fibrosis, measured by the Ishak grading system. Patients with liver cancer were excluded. According to the results in our patients, there is optimal correlation of the non-invasive measures of fibrosis, either ARFI or Fibroscan[®], with each other and with the Ishak score. The cut-off values for cirrhosis that we identified are: ≥ 10.25 kPa for Fibroscan[®], and ARFI of the left liver lobe m/s 1.77, ARFI of the right liver lobe m/s. 1.92 for the overall group of patients. These cut-off values for the presence of cirrhosis were lower in subjects with previous HBV, compared to HCV, and even lower in subjects without any evidence of viral hepatitis, such as NAFLD. This observation strengthens the need of using the chosen cut-off for specific disease groups.

Differently, detection of liver nodules by any imaging method, particularly by ultrasound, is a defensible screening procedure, even if it encounters several limitations. It is suggested that combining alpha-fetoprotein (AFP) with ultrasound is the method of choice for screening patients at high risk for developing HCC, but this is not a widely accepted criterion due to the lack of sensitivity and specificity^[30]. The use of plain ultrasound, even without contrast, is still the most suitable approach. Small nodules (< 1 cm) should be followed up in 3 subsequent months repeating ultrasound. If the lesion is no longer detectable, or if it is stable, it should be watched every 3 mo according to a monitoring strategy. In the case that the nodule enlarges, further imaging is needed. Equally, nodules that are > 1 cm require an immediate work up with computed tomography or MRI^[31]. Despite the great interest and intervention aimed at screening HCC in high-risk populations^[32-34], the actual results are controversial and, more importantly, the cost-benefit ratio in terms of outcome is still disputed^[35,36]. This is the current situation, despite the benefits of the use of effective drugs^[37-39] and, to a lesser degree, of

United States-guided treatments. Of course, surgical procedures are still the first line therapy in appropriate settings. Unfortunately, this is not the most frequent situation, less than 20% are suitable candidates for resection due to either multifocal unresectable tumors or their underlying chronic liver disease^[1]. In this subset pharmacological therapy, with the current available drugs and other emerging molecules or associations, which will be available in the future, remains the more sustainable and rewarding option. The use of biomarkers, also derived from proteomic profiles, was found to have some utility in the prediction of clinical response to therapy^[40], but other investigations in this field are needed.

SUSTAINABLE AND RELIABLE DIAGNOSIS: THE PLACE OF URINARY BIOMARKERS FOR LIVER CANCER DIAGNOSIS

Better three hours too soon than a minute too late.
William Shakespeare

Urine has long been known to possess diagnostic features; Indian scriptures reporting its sweet taste are probably the earliest proof of this. In the XVII century, Thomas Willis identified the sweet taste of urine in diabetic polyuria. These characteristics have been used in daily practice since the diagnostic potential of urine has been applied in dipstick reagents. Some examples are the diagnosis of proteinuria, through detection of protein amine groups; haematuria, thanks to peroxidase activity of lysis-released haemoglobin; infection, through the detection of leukocyte esterase and nitrites; glycosuria, thanks to the conversion to hydrogen peroxide by glucose oxidase and pregnancy, with a strip-based immunoassay for rapid determination of beta human chorionic gonadotropin^[41,42].

Urinary biomarkers

To be a urinary biomarker, a substance must pass through the renal collecting system avoiding tubular re-absorption, after plasma filtration through the renal glomerulus thanks to its size and ionic charge. Indeed the renal glomerulus is a barrier for larger or negatively charged plasma proteins, like albumin, since only molecules of < 20 kDa or 1.8 nm in size may pass through. Only after these passages can a molecule finally be found in enough quantities in urine to allow a diagnosis.

How select a good diagnostic test?

A good test must have high sensitivity (ideally 100%) and specificity, whilst also detecting the disease in its early stages, in order to allow the best treatment. "Gold standard" is the term used for the most accurate test that unfortunately is often expensive or time consuming to use for rapid diagnostics in the daily practice. So a good test must also be cheap, minimally invasive with low risk for the patient, and rapid, providing the needed

information quickly, and allowing a management plan. In particular for HCC the early diagnosis is important as lesions detected below 2 cm are treatable with surgical resection or liver transplantation. Moreover HCC affects different populations, and the test should, be applicable across different patients and ethnicities.

The prevalence of HCC is high in the developing world^[43], particularly in sub-Saharan Africa, where the attention to expense is of most importance, since often patients spent many days to reach a hospital and have limited resources to move. A urine dipstick test for HCC potentially would fulfil many of these criteria.

How detect cancer through the urine?

A urine biomarker must have three main features: first, correct size (less than 20 kDa) and ionic charge to pass through the renal glomerulus and be not re-absorbed by the tubules. Second, the biomarker should not be a molecule produced as a secondary effect of cancer, but needs to be specific for the type of cancer. Third, the amount of biomarker secreted should be adequate for early detection. The research of markers must be focused on small molecules (50-1000 Da) called metabolites, including bile acids, amino acids, peptides and nucleotides. Different combinations of metabolites could be specific for different conditions, while individually, since they are ubiquitous and involved in most cellular processes, they have minimal diagnostic potential. So a metabolic profile of different altered metabolites in combination may be highly specific for a type of cancer. This field of research has been termed "metabonomics"^[44].

Urinary biomarkers of HCC

Nucleosides: The research for a urinary biomarker of HCC dates back to the 1970s when high levels of methylated purines (7-methylguanine, 1-methylhypoxanthine, N-dimethylguanine, 1-methylguanine and adenine) were detected in the urine of patients with HCC compared to both cirrhotic patients and healthy controls^[45] (Table 2). This suggested that a rapid ribonucleic acid (RNA) turnover is involved in HCC pathogenesis and the methylation of nucleic acid could be a potentially involved in carcinogenesis. Later, a study using immunoassay technique showed high urinary levels of cyclic guanosine 3':5' monophosphate (cGMP) in rats with implanted liver and kidney tumours^[46]. These findings were confirmed in 1982 by Dusheiko *et al.*^[47] in a clinical study on humans. The urinary cGMP excretion, as well as the plasma and ascitic fluid levels of cGMP, were found to be increased in patients with HCC, hepatic disease and other neoplasms^[47]. These findings supported the hypothesis of a shift in cyclic nucleotide metabolism toward cGMP in cancer. However, urinary cGMP is not accurate to detect progression of cirrhosis to HCC, nor to differentiate HCC from other cancers.

The case for nucleoside derivatives as tumour markers was supported in 1986 by Tamura *et al.*^[48] in their study in HCC patients using high performance

Table 2 Urinary markers of hepatocellular carcinoma

Year	Urinary biomarker
Nucleosides and nucleotides	
1974	Methylated purines ^[45]
1976	Cyclic GMP ^[46,47]
1986	Pseudouridine ^[48,49]
Proteins and polyamines	
1990	TGF α and β ^[50-52]
1998	Neopterin ^[53-56]
2004	Urinary trypsin inhibitor ^[59,60]
1998	Spermine, putrescine, spermidine ^[58]
Metabolite profiles	
2009	Octanedioic acid, glycine and hypoxanthine ^[61]
2010	Creatinine, carnitine, creatine ^[62]

GMP: Guanosine 3':5' monophosphate; TGF: Transforming growth factor.

liquid chromatography (HPLC). They detected high level of urinary pseudouridine, a C-glycoside isomer of the nucleoside uridine, that showed a high sensitivity (83%) for HCC diagnosis if combined with serum AFP levels^[48]. Urinary pseudouridine levels probably reflect the overall cellular proliferation in tumorigenesis and are not specific for HCC, since have also been shown to be elevated in other cancers, such as non-Hodgkin's lymphoma.

Jeng *et al.*^[49] showed, with an HPLC-based study in Taiwanese subjects, that the nucleosides adenosine, cytidine and inosine were elevated in the urine of patients affected by HCC and if joined with serum levels of AFP, the diagnosis of cancer was reached with a sensitivity of 80%^[49]. However this study evaluated the potential markers of HCC comparing only with a healthy control group, not considering cirrhotic patients, decreasing the reliability of the study.

Transforming growth factor α and β

In 1990, a study using a modified ELISA assay, showed the presence of transforming growth factor α (TGF α) in the urine of patients affected by HCC^[50]. The following year a small study by Chuang *et al.*^[51] identified low molecular weight epidermal growth factor-related TGFs with functional activity in the urine of a similar group of patients. The same author corroborated their results in a larger study in 1997, showing a correlation of urinary TGF β 1 with the outcome of HCC patients^[52]. A functional explanation of TGFs role in carcinogenesis comes from the ability to stimulate non-transformed cells to grow as colonies *in vitro*. However further studies are needed to confirm if these findings are specific for HCC compared to other malignancies.

Neopterin

Neopterin is a protein released from macrophages during the inflammatory response. In 1998 authors showed increased urinary levels of neopterin in Japanese patients with advanced HCC, correlating with lesion size but not with AFP. However this protein was not detected in patients with early HCC^[53,54]. Unfortunately, neopterin has been found to be elevated in several

cancers and other inflammatory diseases such as HIV infection^[55], thus it is not specific for the diagnosis of HCC. Conversely, the combination of HPLC urinary levels of neopterin, pseudouridine and creatinine is a reliable indicator of RNA turnover, indicating neoplastic growth, in adenocarcinoma, non-Hodgkin's lymphoma and HCC^[56].

Polyamines

The exact role of the polyamines (putrescine, spermine and spermidine) is unclear, although they are involved in cellular proliferation. Putrescine acts on S-adenosylmethionine (SAME), a methylating molecule, to produce spermine, which in turn acts on further SAME molecules to produce spermidine^[57]. Antonello *et al.*^[58], in their study based on reverse phase liquid chromatography, found increased levels of free and acetylated polyamines in the urine of patients affected by HCC compared to both healthy and disease controls (cirrhotic patients)^[58]. As other biomarkers polyamines are not specific to HCC and not sensitive enough for early-stage diagnosis.

Urinary trypsin inhibitor

Urinary trypsin inhibitor (UTI) is a 25 kDa trypsin inhibitor used as a marker of hepatocyte function, it is believed to be produced by hepatocytes. A study in 2004 failed to show a significant difference in levels of UTI in liver cirrhosis and HCC patients^[59] reducing its usefulness in the early diagnosis of cancer. Other authors demonstrated that there is a correlation with the severity of liver disease, indeed Kikuchi *et al.*^[60] found a reduction of UTI plasmatic levels after HCC surgical treatment. Moreover the levels of UTI were correlated also with risk of tumour recurrence. Thus, UTI may be considered a biomarker of hepatic disorders and HCC but, also in this case, it lacks sensitivity for the early detection of cancer.

Metabolic profiling

Wu *et al.*^[61], in their study based on urinary gas chromatography mass spectrometry of 20 HCC patients, found a marker set of 18 metabolites (including octanedioic acid, glycine and hypoxanthine) distinguishing HCC and healthy Chinese controls, but a disease control group of cirrhotic patients was not considered^[61]. This reduces the reliability of those findings in the principal at risk population.

A recent proton magnetic resonance (¹H-NMR) spectroscopy study by Shariff *et al.*^[62] reported a panel of urinary metabolites discriminating patients affected by HCC from both healthy controls and cirrhotic ones, with high sensitivity and specificity, respectively 100% and 93% in the first case and 89.5% and 88.9% in the second one, in a Nigerian groups of patients (Figure 5)^[62]. This panel included creatine, creatinine, carnitine and acetone, that mirror an alteration of energy metabolism and cellular growth in such group of patients. Moreover, creatine is a biomarker of cachexia and sarcopenia related to the malignancy condition. These results need to be corroborated by larger studies on different ethnicity,

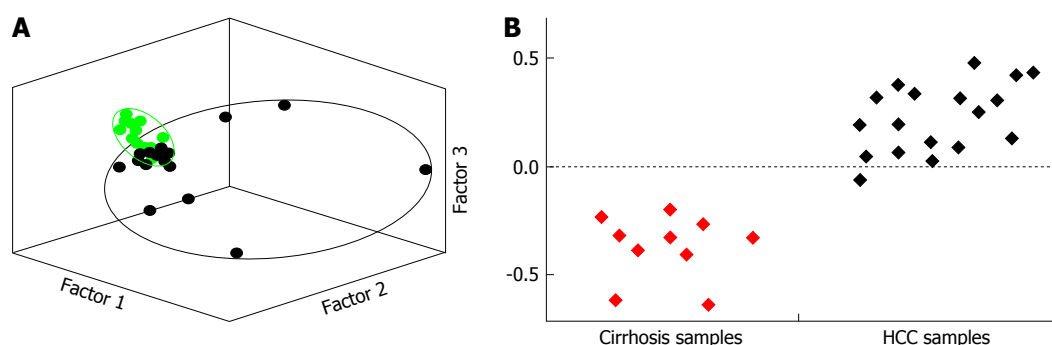


Figure 5 Principal components multivariate statistical analysis (A) and partial least squared discriminant multivariate statistical analysis (B). A: Principal components multivariate statistical analysis scatter plot showing statistical separation of data sets of urinary nuclear magnetic (NMR) spectroscopy information of hepatocellular carcinoma (HCC) subjects (small black spots), compared to urinary data sets from healthy controls (small green spots); B: Partial least squared discriminant multivariate statistical analysis showing statistical differentiation of metabolite information from HCC subjects obtained using NMR spectroscopy, compared to similar urinary data sets from patients with cirrhosis. These are the essential *raison d'être* for searching and using urinary biomarkers for the early and reliable diagnosis of HCC, but promising research is still being undertaken to this end (Figure 6).

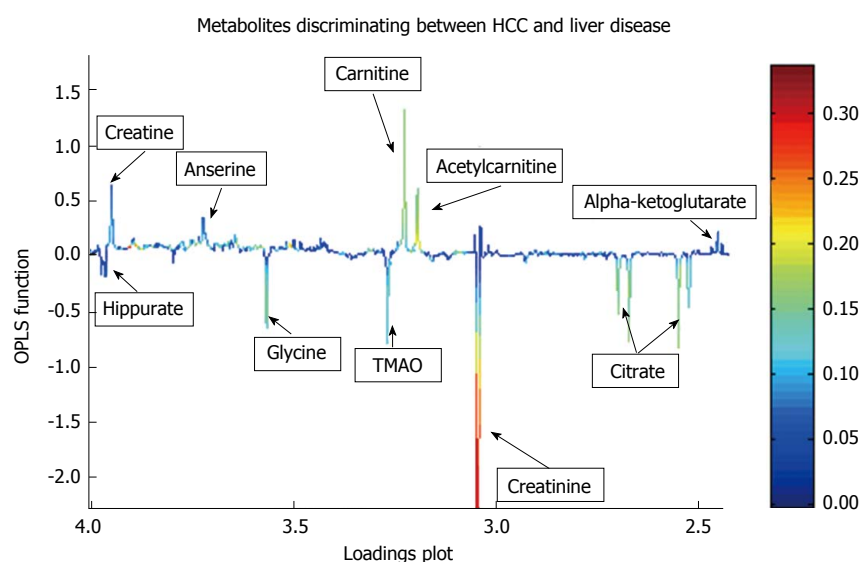


Figure 6 Statistical "loadings plot" of information obtained from an urinary nuclear magnetic resonance spectroscopy data set showing metabolites upregulated in hepatocellular carcinoma (upward peaks: Carnitine, anserine, creatine, acetylcarnitine, alpha-ketoglutarate) and downregulated in hepatocellular carcinoma (downward pointing peaks: Hippurate, glycine, trimethylamineoxide, creatinine, citrate), compared to urinary nuclear magnetic resonance spectroscopy data from patients with cirrhosis. Most metabolites represent alternative energy metabolites as liver tumours are not solely dependent on glycolysis for an energy source. HCC: Hepatocellular carcinoma; TMA: Trimethylamineoxide; OPLS: Orthogonal partial least squares discriminant analysis.

before this panel could be applicable and extended to the varying range of patients affected by HCC.

The information contained in the urine is useful to reach the diagnosis and urinary dipsticks are used in daily practice, allowing the physician to institute rapid management of an underlying condition, ranging from urinary tract infections to pregnancy. A new urinary dipstick test for the diagnosis of HCC would be of great value both in developed countries, where the first screening could be done by general practitioners, and in the resource-poor settings, where patients may not have easy access to serological tests or imaging facilities.

These are the essential *raison d'être* for searching and using urinary biomarkers for the early and reliable diagnosis of HCC, but promising research is still being undertaken to this end (Figure 6).

After preliminary studies^[62-64] using urinary ¹H-NMR

spectroscopy in African populations, multiple marker metabolites in the urine do provide clues for the implication of altered energy-related pathways in the pathogenesis and progression of HCC^[63]. More importantly from a clinical perspective, metabotypic changes seem to characterize HCC patients with enhanced sensitivity and specificity compared to serum AFP in the published studies to date, although much work needs to be performed on validation of this^[64]. These findings suggest panel of urinary metabolites may prove useful for screening HCC in at-risk populations.

Moreover, further investigation in high risk populations for other liver cancers, such as cholangiocarcinoma^[64], notably in Northeast Thailand^[65], may be a worthwhile direction to pursue, potentially providing an answer to the difficult challenge of early diagnosis of primary cholangiocarcinoma and of monitoring the effects of

treatment, whenever available^[66-68]. Furthermore, the rising trend of prevalence of cholangiocarcinoma in Europe, although of uncertain origin^[69,70], is a matter of serious concern, but the lesson learnt by the long history of HCC can be useful for future research and applications.

CONCLUSION

Urinary biomarkers have been studied for almost half century, including nucleosides, small proteins, polyamines and recently, metabolites. Some of the techniques and tests described are already suitable for more widespread clinical application, as is the case with ultrasound-based liver diagnostics, but others, such as urinary metabonomics, requires a period of critical evaluation or development to take them from the research arena to clinical practice. The guidelines of sustainability in countries with limited resources, facilities and low financial income can be seen as an opportunity for addressing research toward low-cost diagnostics and for driving clinical practice toward more streamlined technology, with ultimate benefits for the populations of poorer countries around the world^[70]. Also medicine, as "science, after all, is essentially international, and it is only through lack of the historical sense that national qualities have been attributed to it" (Marie Curie). Medicine should not exist as a "medical science" with different priorities for low and high-income populations^[71]. The most important discoveries and advancements in the field of medicine have required, and probably still require, more focus to the clinical problems along with a sustainable analytical investigation of all the physiological and pathological details.

ACKNOWLEDGMENTS

Tognarelli JMT, Crossey MME and Taylor-Robinson SD are grateful to the United Kingdom National Institute for Health Research (NIHR) Biomedical Facility at Imperial College London for infrastructure support. Mary ME Crossey is supported by a Fellowship grant from the Sir Halley Stewart Foundation (Cambridge, United Kingdom). Tognarelli JMT, Crossey MME and Taylor-Robinson SD participant workers in the European Union Framework 7-funded "PROLIFICA" (Prevention of Liver Fibrosis and Cancer in Africa) project in West Africa, which aims to diagnose, treat and follow-up a cohort of hepatitis B-positive patients in The Gambia, Senegal and Nigeria (EC FP7, P34114; www.prolifica.eu). No relevant or potential conflict of interest is present for any of the authors.

REFERENCES

- 1 **Bodzin AS**, Busuttill RW. Hepatocellular carcinoma: Advances in diagnosis, management, and long term outcome. *World J Hepatol* 2015; **7**: 1157-1167 [PMID: 26019732 DOI: 10.4254/wjh.v7.i9.1157]
- 2 **Trovato GM**. Sustainable medical research by effective and comprehensive medical skills: overcoming the frontiers by predictive, preventive and personalized medicine. *EPMA J* 2014; **5**: 14 [PMID: 25250099 DOI: 10.1186/1878-5085-5-14]
- 3 **Pagni F**, Bono F, Di Bella C, Faravelli A, Cappellini A. Virtual surgical pathology in underdeveloped countries: The Zambia Project. *Arch Pathol Lab Med* 2011; **135**: 215-219 [PMID: 21284441 DOI: 10.1043/1543-2165-135.2.215]
- 4 **Chen J**, Jiao Y, Lu C, Zhou J, Zhang Z, Zhou C. A nationwide telepathology consultation and quality control program in China: implementation and result analysis. *Diagn Pathol* 2014; **9** Suppl 1: S2 [PMID: 25565398 DOI: 10.1186/1746-1596-9-S1-S2]
- 5 **Hetzmann Z**, Mostafa MG, Dalquen P. Computational Pathology and Telepathology: SY05-1 telecytology only an advantage for countries with underserved setting? *Pathology* 2014; **46** Suppl 2: S7
- 6 **Ayad E**, Sicurello F. Telepathology in emerging countries pilot project between Italy and Egypt. *Diagn Pathol* 2008; **3** Suppl 1: S2 [PMID: 18673508 DOI: 10.1186/1746-1596-3-S1-S2]
- 7 **Chetwood JD**, Ladep NG, Taylor-Robinson SD. Research partnerships between high and low-income countries: are international partnerships always a good thing? *BMC Med Ethics* 2015; **16**: 36 [PMID: 26017015 DOI: 10.1186/s12910-015-0030-z]
- 8 **Simonetti RG**, Cammà C, Fiorello F, Politi F, D'Amico G, Pagliaro L. Hepatocellular carcinoma. A worldwide problem and the major risk factors. *Dig Dis Sci* 1991; **36**: 962-972 [PMID: 1649041]
- 9 **Catalano D**, Trovato GM, Martines GF, Randazzo M, Tonzuso A. Bright liver, body composition and insulin resistance changes with nutritional intervention: a follow-up study. *Liver Int* 2008; **28**: 1280-1287 [PMID: 18435716 DOI: 10.1111/j.1478-3231.2008.01742.x]
- 10 **Trovato FM**, Catalano D, Martines GF, Pace P, Trovato GM. Mediterranean diet and non-alcoholic fatty liver disease: the need of extended and comprehensive interventions. *Clin Nutr* 2015; **34**: 86-88 [PMID: 24529325 DOI: 10.1016/j.clnu.2014.01.018]
- 11 **Trovato FM**, Catalano D, Garozzo A, Martines GF, Pirri C, Trovato GM. ADV36 adipogenic adenovirus in human liver disease. *World J Gastroenterol* 2014; **20**: 14706-14716 [PMID: 25356033 DOI: 10.3748/wjg.v20.i40.14706]
- 12 **Taylor-Robinson SD**, Foster GR, Arora S, Hargreaves S, Thomas HC. Increase in primary liver cancer in the UK, 1979-94. *Lancet* 1997; **350**: 1142-1143 [PMID: 9343506]
- 13 **Taylor-Robinson SD**, Thomas HC, Arora S, Hargreaves S. Increased mortality from liver cancer in England and Wales is not related to hepatitis C. *BMJ* 1999; **319**: 640 [PMID: 10473489 DOI: 10.1136/bmj.319.7210.640]
- 14 **Khan SA**, Thomas HC, Davidson BR, Taylor-Robinson SD. Cholangiocarcinoma. *Lancet* 2005; **366**: 1303-1314 [PMID: 16214602]
- 15 **Khan SA**, Davidson BR, Goldin RD, Heaton N, Karani J, Pereira SP, Rosenberg WM, Tait P, Taylor-Robinson SD, Thillainayagam AV, Thomas HC, Wasan H. Guidelines for the diagnosis and treatment of cholangiocarcinoma: an update. *Gut* 2012; **61**: 1657-1669 [PMID: 22895392 DOI: 10.1136/gutjnl-2011-301748]
- 16 **Hsu CS**, Chao YC, Lin HH, Chen DS, Kao JH. Systematic Review: Impact of Interferon-based Therapy on HCV-related Hepatocellular Carcinoma. *Sci Rep* 2015; **5**: 9954 [PMID: 25963067 DOI: 10.1038/srep09954]
- 17 **Angulo P**. Nonalcoholic fatty liver disease. *N Engl J Med* 2002; **346**: 1221-1231 [PMID: 11961152]
- 18 **Neuberger J**, Grant A, Day CP, Saxseena S. Guidelines on the use of liver biopsy in clinical practice. *BSG Guidelines in Gastroenterology*, 2004: 1-15
- 19 **Bedossa P**, Dargère D, Paradis V. Sampling variability of liver fibrosis in chronic hepatitis C. *Hepatology* 2003; **38**: 1449-1457 [PMID: 14647056]
- 20 **Manning DS**, Afdhal NH. Diagnosis and quantitation of fibrosis. *Gastroenterology* 2008; **134**: 1670-1681 [PMID: 18471546 DOI: 10.1053/j.gastro.2008.03.001]
- 21 **Friedrich-Rust M**, Ong MF, Martens S, Sarrazin C, Bojunga J, Zeuzem S, Herrmann E. Performance of transient elastography for the staging of liver fibrosis: a meta-analysis. *Gastroenterology* 2008;

- 134: 960-974 [PMID: 18395077 DOI: 10.1053/j.gastro.2008.01.034]
- 22 **Lim AK**, Taylor-Robinson SD, Patel N, Eckersley RJ, Goldin RD, Hamilton G, Foster GR, Thomas HC, Cosgrove DO, Blomley MJ. Hepatic vein transit times using a microbubble agent can predict disease severity non-invasively in patients with hepatitis C. *Gut* 2005; **54**: 128-133 [PMID: 15591518]
 - 23 **Talwalkar JA**, Yin M, Fidler JL, Sanderson SO, Kamath PS, Ehman RL. Magnetic resonance imaging of hepatic fibrosis: emerging clinical applications. *Hepatology* 2008; **47**: 332-342 [PMID: 18161879]
 - 24 **Lewin M**, Poujol-Robert A, Boëlle PY, Wendum D, Lasnier E, Viallon M, Guéchet J, Hoeffel C, Arrivé L, Tubiana JM, Poupon R. Diffusion-weighted magnetic resonance imaging for the assessment of fibrosis in chronic hepatitis C. *Hepatology* 2007; **46**: 658-665 [PMID: 17663420]
 - 25 **Yin M**, Talwalkar JA, Glaser KJ, Manduca A, Grimm RC, Rossman PJ, Fidler JL, Ehman RL. Assessment of hepatic fibrosis with magnetic resonance elastography. *Clin Gastroenterol Hepatol* 2007; **5**: 1207-1213.e2 [PMID: 17916548]
 - 26 **Lim AK**, Patel N, Hamilton G, Hajnal JV, Goldin RD, Taylor-Robinson SD. The relationship of in vivo 31P MR spectroscopy to histology in chronic hepatitis C. *Hepatology* 2003; **37**: 788-794 [PMID: 12668971]
 - 27 **Thomas EL**, Hamilton G, Patel N, O'Dwyer R, Doré CJ, Goldin RD, Bell JD, Taylor-Robinson SD. Hepatic triglyceride content and its relation to body adiposity: a magnetic resonance imaging and proton magnetic resonance spectroscopy study. *Gut* 2005; **54**: 122-127 [PMID: 15591516]
 - 28 **Ishak K**, Baptista A, Bianchi L, Callea F, De Groote J, Gudan F, Denk H, Desmet V, Korb G, MacSween RN. Histological grading and staging of chronic hepatitis. *J Hepatol* 1995; **22**: 696-699 [PMID: 7560864]
 - 29 **European Association for Study of Liver; Asociacion Latinoamericana para el Estudio del Hígado**. EASL-ALEH Clinical Practice Guidelines: Non-invasive tests for evaluation of liver disease severity and prognosis. *J Hepatol* 2015; **63**: 237-264 [PMID: 25911335 DOI: 10.1016/j.jhep.2015.04.006]
 - 30 **Ransohoff DF**, Feinstein AR. Problems of spectrum and bias in evaluating the efficacy of diagnostic tests. *N Engl J Med* 1978; **299**: 926-930 [PMID: 692598]
 - 31 **Kirstein MM**, Vogel A. The pathogenesis of hepatocellular carcinoma. *Dig Dis* 2014; **32**: 545-553 [PMID: 25034287 DOI: 10.1159/000360499]
 - 32 **Koh C**, Zhao X, Samala N, Sakiani S, Liang TJ, Talwalkar JA. AASLD clinical practice guidelines: a critical review of scientific evidence and evolving recommendations. *Hepatology* 2013; **58**: 2142-2152 [PMID: 23775835 DOI: 10.1002/hep.26578]
 - 33 **Leoni S**, Piscaglia F, Serio I, Terzi E, Pettinari I, Croci L, Marinelli S, Benevento F, Golfieri R, Bolondi L. Adherence to AASLD guidelines for the treatment of hepatocellular carcinoma in clinical practice: experience of the Bologna Liver Oncology Group. *Dig Liver Dis* 2014; **46**: 549-555 [PMID: 24630947 DOI: 10.1016/j.dld.2014.02.012]
 - 34 **Cucchetti A**, Trevisani F, Pecorelli A, Erroi V, Farinati F, Ciccarese F, Rapaccini GL, Di Marco M, Caturelli E, Giannini EG, Zoli M, Borzio F, Cabibbo G, Felder M, Gasbarrini A, Sacco R, Foschi FG, Missale G, Morisco F, Baroni GS, Virdone R, Bernardi M, Pinna AD. Estimation of lead-time bias and its impact on the outcome of surveillance for the early diagnosis of hepatocellular carcinoma. *J Hepatol* 2014; **61**: 333-341 [PMID: 24717522 DOI: 10.1016/j.jhep.2014.03.037]
 - 35 **Del Poggio P**, Olmi S, Ciccarese F, Di Marco M, Rapaccini GL, Benvegnù L, Borzio F, Farinati F, Zoli M, Giannini EG, Caturelli E, Chiamonte M, Trevisani F. Factors that affect efficacy of ultrasound surveillance for early stage hepatocellular carcinoma in patients with cirrhosis. *Clin Gastroenterol Hepatol* 2014; **12**: 1927-33.e2 [PMID: 24582947 DOI: 10.1016/j.cgh.2014.02.025]
 - 36 **Sherman M**, Bruix J, Porayko M, Tran T. Screening for hepatocellular carcinoma: the rationale for the American Association for the Study of Liver Diseases recommendations. *Hepatology* 2012; **56**: 793-796 [PMID: 22689409 DOI: 10.1002/hep.25869]
 - 37 **Taylor-Robinson SD**, Wong J, Crossey MM, Khan SA. Evidence is weak to support hepatocellular carcinoma screening in chronic liver disease. *Evid Based Med* 2015; **20**: 59 [PMID: 25694341 DOI: 10.1136/ebmed-2014-110107]
 - 38 **Iavarone M**, Cabibbo G, Piscaglia F, Zavaglia C, Grieco A, Villa E, Cammà C, Colombo M. Field-practice study of sorafenib therapy for hepatocellular carcinoma: a prospective multicenter study in Italy. *Hepatology* 2011; **54**: 2055-2063 [PMID: 21898496 DOI: 10.1002/hep.24644]
 - 39 **Abou-Alfa GK**. Sorafenib use in hepatocellular carcinoma: more questions than answers. *Hepatology* 2014; **60**: 15-18 [PMID: 24493250 DOI: 10.1002/hep.27044]
 - 40 **Perdomo AB**, Ciccocanti F, Iacono OL, Angeletti C, Corazzari M, Daniele N, Testa A, Pisa R, Ippolito G, Antonucci G, Fimia GM, Piacentini M. Liver protein profiling in chronic hepatitis C: identification of potential predictive markers for interferon therapy outcome. *J Proteome Res* 2012; **11**: 717-727 [PMID: 22098443 DOI: 10.1021/pr2006445]
 - 41 **Simerville JA**, Maxted WC, Pahlira JJ. Urinalysis: a comprehensive review. *Am Fam Physician* 2005; **71**: 1153-1162 [PMID: 15791892]
 - 42 **Subramonian K**, MacDonald H, Vijapurapu R, Yadav S. Urine Dipstick Tests. *Student BMJ* 2009; **17**: b260 [DOI: 10.1136/sbmj.b260]
 - 43 **Shariff MI**, Cox IJ, Gomaa AI, Khan SA, Gedroyc W, Taylor-Robinson SD. Hepatocellular carcinoma: current trends in worldwide epidemiology, risk factors, diagnosis and therapeutics. *Expert Rev Gastroenterol Hepatol* 2009; **3**: 353-367 [PMID: 19673623 DOI: 10.1586/egh.09.35]
 - 44 **Nicholson JK**, Lindon JC. Systems biology: Metabonomics. *Nature* 2008; **455**: 1054-1056 [PMID: 18948945 DOI: 10.1038/4551054a]
 - 45 **Ho Y**, Lin HJ. Patterns of excretion of methylated purines in hepatocellular carcinoma. *Cancer Res* 1974; **34**: 986-990 [PMID: 4363066]
 - 46 **Criss WE**, Murad F. Urinary excretion of cyclic guanosine 3': 5'-monophosphate and cyclic adenosine 3': 5'-monophosphate in rats bearing transplantable liver and kidney tumors. *Cancer Res* 1976; **36**: 1714-1716 [PMID: 178429]
 - 47 **Dushenko GM**, Levin J, Kew MC. Cyclic nucleotides in biological fluids in hepatocellular carcinoma. *Cancer* 1981; **47**: 113-118 [PMID: 6257369]
 - 48 **Tamura S**, Amuro Y, Nakano T, Fujii J, Moriaki Y, Yamamoto T, Hada T, Higashino K. Urinary excretion of pseudouridine in patients with hepatocellular carcinoma. *Cancer* 1986; **57**: 1571-1575 [PMID: 2418945]
 - 49 **Jeng LB**, Lo WY, Hsu WY, Lin WD, Lin CT, Lai CC, Tsai FJ. Analysis of urinary nucleosides as helper tumor markers in hepatocellular carcinoma diagnosis. *Rapid Commun Mass Spectrom* 2009; **23**: 1543-1549 [PMID: 19399767 DOI: 10.1002/rcm.4034]
 - 50 **Katoh M**, Inagaki H, Kurosawa-Ohsawa K, Katsuura M, Tanaka S. Detection of transforming growth factor alpha in human urine and plasma. *Biochem Biophys Res Commun* 1990; **167**: 1065-1072 [PMID: 2157422]
 - 51 **Chuang LY**, Tsai JH, Yeh YC, Chang CC, Yeh HW, Guh JY, Tsai JF. Epidermal growth factor-related transforming growth factors in the urine of patients with hepatocellular carcinoma. *Hepatology* 1991; **13**: 1112-1116 [PMID: 1646759]
 - 52 **Tsai JF**, Jeng JE, Chuang LY, Yang ML, Ho MS, Chang WY, Hsieh MY, Lin ZY, Tsai JH. Clinical evaluation of urinary transforming growth factor-beta1 and serum alpha-fetoprotein as tumour markers of hepatocellular carcinoma. *Br J Cancer* 1997; **75**: 1460-1466 [PMID: 9166938]
 - 53 **Kawasaki H**, Watanabe H, Yamada S, Watanabe K, Suyama A. Prognostic significance of urinary neopterin levels in patients with hepatocellular carcinoma. *Tohoku J Exp Med* 1988; **155**: 311-318 [PMID: 2852855]
 - 54 **Daito K**, Suou T, Kawasaki H. Clinical significance of serum and urinary neopterin levels in patients with various liver diseases. *Am J Gastroenterol* 1992; **87**: 471-476 [PMID: 1313206]

- 55 **Sucher R**, Schroecksnadel K, Weiss G, Margreiter R, Fuchs D, Brandacher G. Neopterin, a prognostic marker in human malignancies. *Cancer Lett* 2010; **287**: 13-22 [PMID: 19500901 DOI: 10.1016/j.canlet.2009.05.008]
- 56 **Motyl T**, Traczyk Z, Holska W, Daniewska-Michalska D, Cieśluk S, Kukulska W, Kałużny Z, Podgurniak M. Comparison of urinary neopterin and pseudouridine in patients with malignant proliferative diseases. *Eur J Clin Chem Clin Biochem* 1993; **31**: 205-209 [PMID: 8318566]
- 57 **Wishart DS**, Tzur D, Knox C, Eisner R, Guo AC, Young N, Cheng D, Jewell K, Arndt D, Sawhney S, Fung C, Nikolai L, Lewis M, Coutouly MA, Forsythe I, Tang P, Shrivastava S, Jeroncic K, Stothard P, Amegbey G, Block D, Hau DD, Wagner J, Miniaci J, Clements M, Gebremedhin M, Guo N, Zhang Y, Duggan GE, Macinnis GD, Weljie AM, Dowlatabadi R, Bamforth F, Clive D, Greiner R, Li L, Marrie T, Sykes BD, Vogel HJ, Querengesser L. HMDB: the Human Metabolome Database. *Nucleic Acids Res* 2007; **35**: D521-D526 [PMID: 17202168]
- 58 **Antonello S**, Auletta M, Magri P, Pardo F. Urinary excretion of free and acetylated polyamines in hepatocellular carcinoma. *Int J Biol Markers* 1998; **13**: 92-97 [PMID: 9803357]
- 59 **Lin SD**, Endo R, Kuroda H, Kondo K, Miura Y, Takikawa Y, Kato A, Suzuki K. Plasma and urine levels of urinary trypsin inhibitor in patients with chronic liver diseases and hepatocellular carcinoma. *J Gastroenterol Hepatol* 2004; **19**: 327-332 [PMID: 14748881]
- 60 **Kikuchi I**, Uchinami H, Nanjo H, Hashimoto M, Nakajima A, Kume M, Mencin A, Yamamoto Y. Clinical and prognostic significance of urinary trypsin inhibitor in patients with hepatocellular carcinoma after hepatectomy. *Ann Surg Oncol* 2009; **16**: 2805-2817 [PMID: 19636634 DOI: 10.1245/s10434-009-0622-2]
- 61 **Wu H**, Xue R, Dong L, Liu T, Deng C, Zeng H, Shen X. Metabolomic profiling of human urine in hepatocellular carcinoma patients using gas chromatography/mass spectrometry. *Anal Chim Acta* 2009; **648**: 98-104 [PMID: 19616694 DOI: 10.1016/j.aca.2009.06.033]
- 62 **Shariff MI**, Ladep NG, Cox IJ, Williams HR, Okeke E, Malu A, Thillainayagam AV, Crossey MM, Khan SA, Thomas HC, Taylor-Robinson SD. Characterization of urinary biomarkers of hepatocellular carcinoma using magnetic resonance spectroscopy in a Nigerian population. *J Proteome Res* 2010; **9**: 1096-1103 [PMID: 19968328 DOI: 10.1021/pr901058t]
- 63 **Ladep NG**, Dona AC, Lewis MR, Crossey MM, Lemoine M, Okeke E, Shimakawa Y, Duguru M, Njai HF, Fye HK, Taal M, Chetwood J, Kasstan B, Khan SA, Garside DA, Wijeyesekera A, Thillainayagam AV, Banwat E, Thursz MR, Nicholson JK, Njie R, Holmes E, Taylor-Robinson SD. Discovery and validation of urinary metabolotypes for the diagnosis of hepatocellular carcinoma in West Africans. *Hepatology* 2014; **60**: 1291-1301 [PMID: 24923488 DOI: 10.1002/hep.27264]
- 64 **Shariff MI**, Gomaa AI, Cox IJ, Patel M, Williams HR, Crossey MM, Thillainayagam AV, Thomas HC, Waked I, Khan SA, Taylor-Robinson SD. Urinary metabolic biomarkers of hepatocellular carcinoma in an Egyptian population: a validation study. *J Proteome Res* 2011; **10**: 1828-1836 [PMID: 21275434 DOI: 10.1021/pr101096f]
- 65 **Songserm N**, Promthet S, Sithithaworn P, Pientong C, Ekalaksananan T, Chopjitt P, Parkin DM. Risk factors for cholangiocarcinoma in high-risk area of Thailand: role of lifestyle, diet and methylenetetrahydrofolate reductase polymorphisms. *Cancer Epidemiol* 2012; **36**: e89-e94 [PMID: 22189445 DOI: 10.1016/j.canep.2011.11.007]
- 66 **Trovato FM**, Catalano D, Ragusa A, Martines GF, Pirri C, Buccheri MA, Di Nora C, Trovato GM. Relationship of MTHFR gene polymorphisms with renal and cardiac disease. *World J Nephrol* 2015; **4**: 127-137 [PMID: 25664255 DOI: 10.5527/wjn.v4.i1.127]
- 67 **Catalano D**, Trovato GM, Ragusa A, Martines GF, Tonzuso A, Pirri C, Buccheri MA, Trovato FM. Non-alcoholic fatty liver disease (NAFLD) and MTHFR 1298A > C gene polymorphism. *Eur Rev Med Pharmacol Sci* 2014; **18**: 151-159 [PMID: 24488901]
- 68 **Wadsworth CA**, Dixon PH, Wong JH, Chapman MH, McKay SC, Sharif A, Spalding DR, Pereira SP, Thomas HC, Taylor-Robinson SD, Whittaker J, Williamson C, Khan SA. Genetic factors in the pathogenesis of cholangiocarcinoma. *Dig Dis* 2011; **29**: 93-97 [PMID: 21691113 DOI: 10.1159/000324688]
- 69 **Khan SA**, Emadossadaty S, Ladep NG, Thomas HC, Elliott P, Taylor-Robinson SD, Toledano MB. Rising trends in cholangiocarcinoma: is the ICD classification system misleading us? *J Hepatol* 2012; **56**: 848-854 [PMID: 22173164 DOI: 10.1016/j.jhep.2011.11.015]
- 70 **Ladep NG**, Khan SA, Crossey MM, Thillainayagam AV, Taylor-Robinson SD, Toledano MB. Incidence and mortality of primary liver cancer in England and Wales: changing patterns and ethnic variations. *World J Gastroenterol* 2014; **20**: 1544-1553 [PMID: 24587630 DOI: 10.3748/wjg.v20.i6.1544]
- 71 **Trovato FM**, Catalano D, Musumeci G, Trovato GM. 4Ps medicine of the fatty liver: the research model of predictive, preventive, personalized and participatory medicine-recommendations for facing obesity, fatty liver and fibrosis epidemics. *EPMA J* 2014; **5**: 21 [PMID: 25937854 DOI: 10.1186/1878-5085-5-21]

P- Reviewer: Ding MX, Sims OT **S- Editor:** Ji FF
L- Editor: A **E- Editor:** Liu SQ





Published by **Baishideng Publishing Group Inc**

8226 Regency Drive, Pleasanton, CA 94588, USA

Telephone: +1-925-223-8242

Fax: +1-925-223-8243

E-mail: bpgoffice@wjgnet.com

Help Desk: <http://www.wjgnet.com/esps/helpdesk.aspx>

<http://www.wjgnet.com>

