

# World Journal of *Clinical Cases*

*World J Clin Cases* 2022 June 6; 10(16): 5124-5517



## Contents

Thrice Monthly Volume 10 Number 16 June 6, 2022

### OPINION REVIEW

- 5124** Malignant insulinoma: Can we predict the long-term outcomes?  
*Cigrovski Berkovic M, Ulamec M, Marinovic S, Balen I, Mrzljak A*

### MINIREVIEWS

- 5133** Practical points that gastrointestinal fellows should know in management of COVID-19  
*Sahin T, Simsek C, Balaban HY*
- 5146** Nanotechnology in diagnosis and therapy of gastrointestinal cancer  
*Liang M, Li LD, Li L, Li S*
- 5156** Advances in the clinical application of oxycodone in the perioperative period  
*Chen HY, Wang ZN, Zhang WY, Zhu T*

### ORIGINAL ARTICLE

#### Clinical and Translational Research

- 5165** Circulating miR-627-5p and miR-199a-5p are promising diagnostic biomarkers of colorectal neoplasia  
*Zhao DY, Zhou L, Yin TF, Zhou YC, Zhou GYJ, Wang QQ, Yao SK*

#### Retrospective Cohort Study

- 5185** Management and outcome of bronchial trauma due to blunt *versus* penetrating injuries  
*Gao JM, Li H, Du DY, Yang J, Kong LW, Wang JB, He P, Wei GB*

#### Retrospective Study

- 5196** Ovarian teratoma related anti-N-methyl-D-aspartate receptor encephalitis: A case series and review of the literature  
*Li SJ, Yu MH, Cheng J, Bai WX, Di W*
- 5208** Endoscopic surgery for intraventricular hemorrhage: A comparative study and single center surgical experience  
*Wang FB, Yuan XW, Li JX, Zhang M, Xiang ZH*
- 5217** Protective effects of female reproductive factors on gastric signet-ring cell carcinoma  
*Li Y, Zhong YX, Xu Q, Tian YT*
- 5230** Risk factors of mortality and severe disability in the patients with cerebrovascular diseases treated with perioperative mechanical ventilation  
*Zhang JZ, Chen H, Wang X, Xu K*

- 5241** Awareness of initiative practice for health in the Chinese population: A questionnaire survey based on a network platform

*Zhang YQ, Zhou MY, Jiang MY, Zhang XY, Wang X, Wang BG*

- 5253** Effectiveness and safety of chemotherapy for patients with malignant gastrointestinal obstruction: A Japanese population-based cohort study

*Fujisawa G, Niikura R, Kawahara T, Honda T, Hasatani K, Yoshida N, Nishida T, Sumiyoshi T, Kiyotoki S, Ikeya T, Arai M, Hayakawa Y, Kawai T, Fujishiro M*

### Observational Study

- 5266** Long-term outcomes of high-risk percutaneous coronary interventions under extracorporeal membrane oxygenation support: An observational study

*Huang YX, Xu ZM, Zhao L, Cao Y, Chen Y, Qiu YG, Liu YM, Zhang PY, He JC, Li TC*

- 5275** Health care worker occupational experiences during the COVID-19 outbreak: A cross-sectional study

*Li XF, Zhou XL, Zhao SX, Li YM, Pan SQ*

### Prospective Study

- 5287** Enhanced recovery after surgery strategy to shorten perioperative fasting in children undergoing non-gastrointestinal surgery: A prospective study

*Ying Y, Xu HZ, Han ML*

- 5297** Orthodontic treatment combined with 3D printing guide plate implant restoration for edentulism and its influence on mastication and phonic function

*Yan LB, Zhou YC, Wang Y, Li LX*

### Randomized Controlled Trial

- 5306** Effectiveness of psychosocial intervention for internalizing behavior problems among children of parents with alcohol dependence: Randomized controlled trial

*Omkarappa DB, Rentala S, Nattala P*

### CASE REPORT

- 5317** Crouzon syndrome in a fraternal twin: A case report and review of the literature

*Li XJ, Su JM, Ye XW*

- 5324** Laparoscopic duodenojejunostomy for malignant stenosis as a part of multimodal therapy: A case report

*Murakami T, Matsui Y*

- 5331** Chordoma of petrosal mastoid region: A case report

*Hua JJ, Ying ML, Chen ZW, Huang C, Zheng CS, Wang YJ*

- 5337** Pneumatosis intestinalis after systemic chemotherapy for colorectal cancer: A case report

*Liu H, Hsieh CT, Sun JM*

- 5343** Mammary-type myofibroblastoma with infarction and atypical mitosis-a potential diagnostic pitfall: A case report

*Zeng YF, Dai YZ, Chen M*

- 5352** Comprehensive treatment for primary right renal diffuse large B-cell lymphoma with a renal vein tumor thrombus: A case report  
*He J, Mu Y, Che BW, Liu M, Zhang WJ, Xu SH, Tang KF*
- 5359** Ectopic peritoneal paragonimiasis mimicking tuberculous peritonitis: A care report  
*Choi JW, Lee CM, Kim SJ, Hah SI, Kwak JY, Cho HC, Ha CY, Jung WT, Lee OJ*
- 5365** Neonatal hemorrhage stroke and severe coagulopathy in a late preterm infant after receiving umbilical cord milking: A case report  
*Lu Y, Zhang ZQ*
- 5373** Heel pain caused by os subcalcis: A case report  
*Saijilafu, Li SY, Yu X, Li ZQ, Yang G, Lv JH, Chen GX, Xu RJ*
- 5380** Pulmonary lymphomatoid granulomatosis in a 4-year-old girl: A case report  
*Yao JW, Qiu L, Liang P, Liu HM, Chen LN*
- 5387** Idiopathic membranous nephropathy in children: A case report  
*Cui KH, Zhang H, Tao YH*
- 5394** Successful treatment of aortic dissection with pulmonary embolism: A case report  
*Chen XG, Shi SY, Ye YY, Wang H, Yao WF, Hu L*
- 5400** Renal papillary necrosis with urinary tract obstruction: A case report  
*Pan HH, Luo YJ, Zhu QG, Ye LF*
- 5406** Glomangiomas - immunohistochemical study: A case report  
*Wu RC, Gao YH, Sun WW, Zhang XY, Zhang SP*
- 5414** Successful living donor liver transplantation with a graft-to-recipient weight ratio of 0.41 without portal flow modulation: A case report  
*Kim SH*
- 5420** Treatment of gastric hepatoid adenocarcinoma with pembrolizumab and bevacizumab combination chemotherapy: A case report  
*Liu M, Luo C, Xie ZZ, Li X*
- 5428** Ipsilateral synchronous papillary and clear renal cell carcinoma: A case report and review of literature  
*Yin J, Zheng M*
- 5435** Laparoscopic radical resection for situs inversus totalis with colonic splenic flexure carcinoma: A case report  
*Zheng ZL, Zhang SR, Sun H, Tang MC, Shang JK*
- 5441** PIGN mutation multiple congenital anomalies-hypotonia-seizures syndrome 1: A case report  
*Hou F, Shan S, Jin H*

- 5446** Pediatric acute myeloid leukemia patients with i(17)(q10) mimicking acute promyelocytic leukemia: Two case reports  
*Yan HX, Zhang WH, Wen JQ, Liu YH, Zhang BJ, Ji AD*
- 5456** Fatal left atrial air embolism as a complication of percutaneous transthoracic lung biopsy: A case report  
*Li YW, Chen C, Xu Y, Weng QP, Qian SX*
- 5463** Diagnostic value of bone marrow cell morphology in visceral leishmaniasis-associated hemophagocytic syndrome: Two case reports  
*Shi SL, Zhao H, Zhou BJ, Ma MB, Li XJ, Xu J, Jiang HC*
- 5470** Rare case of hepatocellular carcinoma metastasis to urinary bladder: A case report  
*Kim Y, Kim YS, Yoo JJ, Kim SG, Chin S, Moon A*
- 5479** Osteotomy combined with the trephine technique for invisible implant fracture: A case report  
*Chen LW, Wang M, Xia HB, Chen D*
- 5487** Clinical diagnosis, treatment, and medical identification of specific pulmonary infection in naval pilots: Four case reports  
*Zeng J, Zhao GL, Yi JC, Liu DD, Jiang YQ, Lu X, Liu YB, Xue F, Dong J*
- 5495** Congenital tuberculosis with tuberculous meningitis and situs inversus totalis: A case report  
*Lin H, Teng S, Wang Z, Liu QY*
- 5502** Mixed large and small cell neuroendocrine carcinoma of the stomach: A case report and review of literature  
*Li ZF, Lu HZ, Chen YT, Bai XF, Wang TB, Fei H, Zhao DB*

**LETTER TO THE EDITOR**

- 5510** Pleural involvement in cryptococcal infection  
*Georgakopoulou VE, Damaskos C, Sklapani P, Trakas N, Gkoufa A*
- 5515** Electroconvulsive therapy plays an irreplaceable role in treatment of major depressive disorder  
*Ma ML, He LP*

**ABOUT COVER**

Editorial Board Member of *World Journal of Clinical Cases*, Shivanshu Misra, MBBS, MCh, MS, Assistant Professor, Surgeon, Department of Minimal Access and Bariatric Surgery, Shivani Hospital and IVF, Kanpur 208005, Uttar Pradesh, India. shivanshu\_medico@rediffmail.com

**AIMS AND SCOPE**

The primary aim of *World Journal of Clinical Cases* (WJCC, *World J Clin Cases*) is to provide scholars and readers from various fields of clinical medicine with a platform to publish high-quality clinical research articles and communicate their research findings online.

WJCC mainly publishes articles reporting research results and findings obtained in the field of clinical medicine and covering a wide range of topics, including case control studies, retrospective cohort studies, retrospective studies, clinical trials studies, observational studies, prospective studies, randomized controlled trials, randomized clinical trials, systematic reviews, meta-analysis, and case reports.

**INDEXING/ABSTRACTING**

The WJCC is now indexed in Science Citation Index Expanded (also known as SciSearch®), Journal Citation Reports/Science Edition, Scopus, PubMed, and PubMed Central. The 2021 Edition of Journal Citation Reports® cites the 2020 impact factor (IF) for WJCC as 1.337; IF without journal self cites: 1.301; 5-year IF: 1.742; Journal Citation Indicator: 0.33; Ranking: 119 among 169 journals in medicine, general and internal; and Quartile category: Q3. The WJCC's CiteScore for 2020 is 0.8 and Scopus CiteScore rank 2020: General Medicine is 493/793.

**RESPONSIBLE EDITORS FOR THIS ISSUE**

Production Editor: Xu Guo; Production Department Director: Xiang Li; Editorial Office Director: Jin-Lei Wang.

**NAME OF JOURNAL**

*World Journal of Clinical Cases*

**ISSN**

ISSN 2307-8960 (online)

**LAUNCH DATE**

April 16, 2013

**FREQUENCY**

Thrice Monthly

**EDITORS-IN-CHIEF**

Bao-Gan Peng, Jerzy Tadeusz Chudek, George Kontogeorgos, Maurizio Serati, Ja Hyeon Ku

**EDITORIAL BOARD MEMBERS**

<https://www.wjgnet.com/2307-8960/editorialboard.htm>

**PUBLICATION DATE**

June 6, 2022

**COPYRIGHT**

© 2022 Baishideng Publishing Group Inc

**INSTRUCTIONS TO AUTHORS**

<https://www.wjgnet.com/bpg/gerinfo/204>

**GUIDELINES FOR ETHICS DOCUMENTS**

<https://www.wjgnet.com/bpg/GerInfo/287>

**GUIDELINES FOR NON-NATIVE SPEAKERS OF ENGLISH**

<https://www.wjgnet.com/bpg/gerinfo/240>

**PUBLICATION ETHICS**

<https://www.wjgnet.com/bpg/GerInfo/288>

**PUBLICATION MISCONDUCT**

<https://www.wjgnet.com/bpg/gerinfo/208>

**ARTICLE PROCESSING CHARGE**

<https://www.wjgnet.com/bpg/gerinfo/242>

**STEPS FOR SUBMITTING MANUSCRIPTS**

<https://www.wjgnet.com/bpg/GerInfo/239>

**ONLINE SUBMISSION**

<https://www.f6publishing.com>



## Osteotomy combined with the trephine technique for invisible implant fracture: A case report

Liang-Wen Chen, Min Wang, Hai-Bin Xia, Dong Chen

**Specialty type:** Dentistry, oral surgery and medicine

**Provenance and peer review:** Unsolicited article; Externally peer reviewed.

**Peer-review model:** Single blind

**Peer-review report's scientific quality classification**

Grade A (Excellent): 0  
Grade B (Very good): B  
Grade C (Good): 0  
Grade D (Fair): 0  
Grade E (Poor): 0

**P-Reviewer:** Papotto G, Italy

**Received:** October 21, 2021

**Peer-review started:** October 21, 2021

**First decision:** March 3, 2022

**Revised:** March 15, 2022

**Accepted:** April 21, 2022

**Article in press:** April 21, 2022

**Published online:** June 6, 2022



**Liang-Wen Chen, Min Wang, Hai-Bin Xia, Dong Chen,** Department of Oral Implantology, School and Hospital of Stomatology, Wuhan University, Wuhan 430079, Hubei Province, China

**Corresponding author:** Dong Chen, DDS, MD, PhD, Attending Doctor, Department of Oral Implantology, School and Hospital of Stomatology, Wuhan University, No. 237 Luoyu Road, Hongshan District, Wuhan 430079, Hubei Province, China. [kq000508@whu.edu.cn](mailto:kq000508@whu.edu.cn)

### Abstract

#### BACKGROUND

Implant fracture is one of the most serious mechanical complications of dental implants. Conventional treatment necessitates visibility of the apical portion of the fractured implant, whereas for deep and invisible implant fractures, the traditional trephine method has been ineffective. Surgical removal of the marginal bone to expose the fracture surface would be a time-consuming and extensively damaging procedure. Here, we propose a novel technique to address invisible implant fractures.

#### CASE SUMMARY

A 50-year-old woman was referred to our department with the chief complaint that her right mandibular implant tooth had fallen out 3 mo earlier. Cone-beam computed tomography examination showed an implant fracture with a fracture surface 5.1 mm below the crestal ridge. The patient was treated with osteotomy combined with the trephine technique to expose the surgical field and remove the implant. The invisible fractured implant was successfully removed, with minimal trauma. A modified Wafer technique-supported guided bone regeneration treatment was then administered to restore the buccal bone wall and preserve the bone mass. Six months later, fine regenerative bone and a wide alveolar crest in the edentulous area were observed, and a new implant was placed. Four months later, restoration was completed using a cemented ceramic prosthesis. Clinical and radiographic examinations 12 mo after loading fulfilled the success criteria. The patient reported no complaints and was satisfied.

#### CONCLUSION

Osteotomy combined with the trephine technique can be effectively used to address deep and invisible implant fractures.

**Key Words:** Dental implant; Invisible implant fracture; Osteotomy; Explanation trephine; Transformed Wafer technique; Case report

**Core Tip:** This article provides up-to-date knowledge regarding the clinical presentation, incidence, risk factors, diagnosis, and management of implant fractures. Conventional treatment requires that the apical portion of the fractured implant be visible. For deep and invisible implant fractures, the traditional trephine method has been ineffective. We developed a novel method of osteotomy combined with the trephine technique that can effectively address deep and invisible implant fractures. Meanwhile, modified Wafer technique-supported guided bone regeneration treatment was conducted simultaneously to preserve the bone mass in the surgical area.

**Citation:** Chen LW, Wang M, Xia HB, Chen D. Osteotomy combined with the trephine technique for invisible implant fracture: A case report. *World J Clin Cases* 2022; 10(16): 5479-5486

**URL:** <https://www.wjgnet.com/2307-8960/full/v10/i16/5479.htm>

**DOI:** <https://dx.doi.org/10.12998/wjcc.v10.i16.5479>

## INTRODUCTION

### *Clinical presentation*

Implant fracture is a kind of destructive mechanical complication, which is generally accompanied by the following clinical characteristics: Loss of retention, marginal bone resorption[1], soft tissue inflammation[2], and occlusal disorder[3]. Consequently, implant fracture can cause significant loss to patients' economies, time, and emotions. According to research involving large amounts of data and long-term follow-up, the incidence of implant fracture was between 0.4% [4] and 0.92% [5] after over 5 years of loading.

### *Diagnosis*

The diagnosis of implant fractures requires the detection of implant mobility by clinical examination and of the fracture line by X-ray images[1]. Once diagnosed as an implant fracture, conventional treatment options are: (1) Complete removal of the remaining fractured implant using trephines[6]; (2) Removal and replacement of the coronal portion of the fractured implant with a new prosthetic restoration[7]; (3) Leaving the remaining apical part integrated into the bone and placing a fixed bridge instead[8,9]; and (4) Using a computer-aided design/computer-aided manufacturing surgical guide to remove the buried implant[10].

### *Treatment*

However, conventional treatments necessitate visibility of the fractured implant. In case of deep and invisible implant fractures, the position and orientation of the implants are not perceptible. No effective solution has been reported for invisible implant fractures. Surgical removal of the marginal bone to expose the fracture surface could be time-consuming and extensively damaging. Herein, we report a novel method to address invisible implant fractures, as an attempt to form new treatment modalities for such cases. This manuscript was prepared according to the CARE checklist[11].

## CASE PRESENTATION

### *Chief complaints*

A 50-year-old non-smoking woman was referred to our clinic in August 2017 with the chief complaint that her mandibular right implant tooth (tooth 46) had fallen out 3 mo earlier.

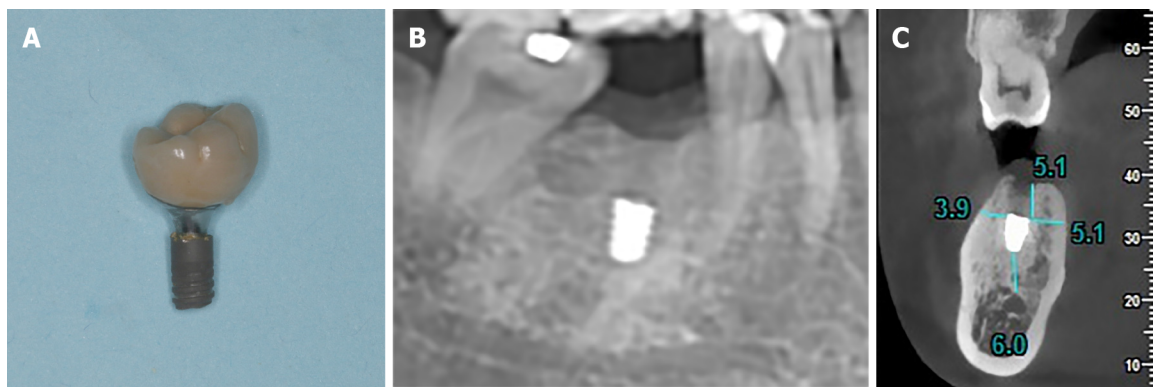
### *History of present illness*

According to the medical record, the implant (Ankylos®, 4.5 mm × 9.5 mm, Germany) was placed in the tooth 46 position in October 2013 and loaded after 6 mo. The patient complained of implant restoration mobility after 2 years of function, with the symptoms worsening while chewing. In May 2017, the patient experienced a foreign body in her mouth, which was the fractured portion of the implant connected to the prosthesis (Figure 1A).

### *History of past illness*

The patient reported no history of systemic diseases, long-term medication, or family genetic history.





DOI: 10.12998/wjcc.v10.i16.5479 Copyright ©The Author(s) 2022.

**Figure 1** The condition of the fractured implant when the patient came to the clinic. A: Fractured portion of the implant connected to the prosthesis; B: Panoramic radiograph showed no signs of peri-implantitis; C: CBCT showed that the remaining implant was 6.0 mm away from the inferior alveolar nerve canal, 3.9 mm away from the buccal cortical bone wall, 5.1 mm away from the lingual bone wall and 5.1 mm beneath the crestal ridge.

### Personal and family history

No smoking and drinking history, and no hereditary family history were reported.

### Physical examination

The patient's blood pressure was 110/70 mmHg, with a pulse rate of 80 beats per minute (bpm).

### Laboratory examinations

The routine blood indicators and coagulation profile were within normal range.

### Imaging examinations

Cone-beam computed tomography (CBCT) examination showed that the residual portion of the implant was osseointegrated with no signs of peri-implantitis. Moreover, there appeared to be a high-density image above the fracture surface of the implant. The remaining apical portion of the implant was 6.0 mm away from the inferior alveolar nerve canal, 3.9 mm away from the buccal cortical bone wall, 5.1 mm away from the lingual bone wall, and 5.1 mm away from the crestal ridge (Figure 1B and C).

## FINAL DIAGNOSIS

The patient was diagnosed with implant fracture.

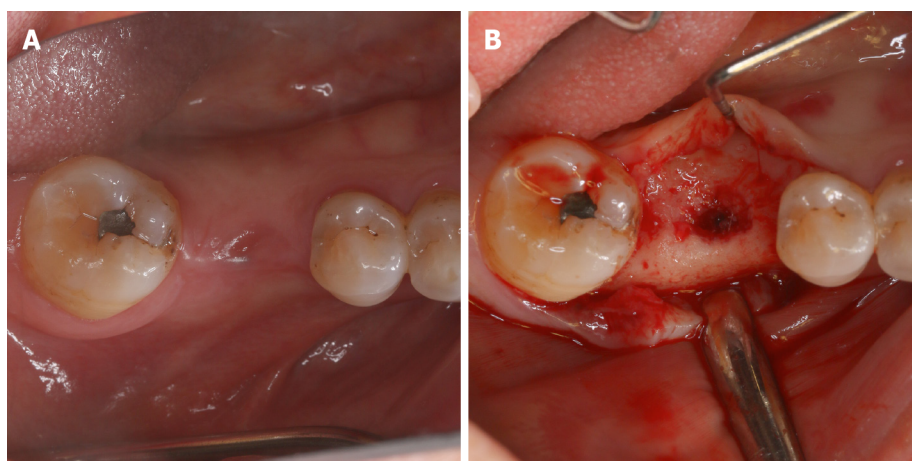
## TREATMENT

### Treatment planning

The risks and benefits of each treatment option were discussed in detail with the patient. The first plan was the fabrication of a three-dimensional (3D) surgical guide for the trephine to achieve precise removal of the remaining implant. However, the 3D surgical guide required at least 20 mm of the trephine with the graduated part, whereas the existing trephines measured only 16 mm. The second plan involved fixed partial restoration, leaving the apical portion of the fractured implant integrated into the bone. However, the patient rejected this plan as she was unwilling to risk damage to her healthy teeth. Consequently, a third treatment plan to perform osteotomy combined with the trephine technique to remove the invisible fractured implant was devised, which was approved by the patient. Informed consent was obtained before treatment.

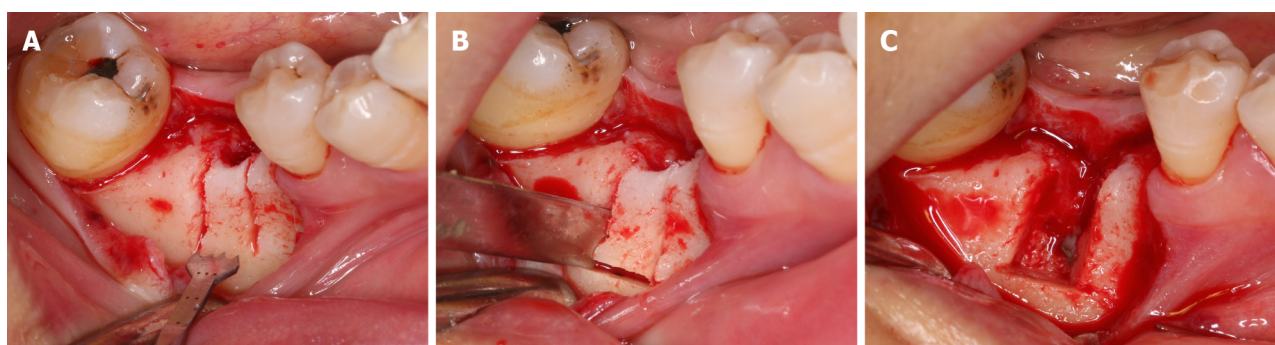
### Surgical procedure

The rapidly growing gingiva had closed the gingival outlet of the implant (Figure 2A). After local anesthesia was administered, a crestal full-thickness flap was raised and an implant hole filled with granulation tissue was observed (Figure 2B). Granulation tissue was removed using a dental excavator and a turbine drill. Thereafter, two vertical incisions and one horizontal incision were made using an ultrasonic osteotome on the buccal side of the alveolar bone where the remaining implant was located (Figure 3A). The buccal bone plate was removed using a bone chisel and hammer (Figure 3B) and soaked in saline temporarily. After the buccal bone plate was removed, the broken end of the fractured



DOI: 10.12998/wjcc.v10.i16.5479 Copyright ©The Author(s) 2022.

**Figure 2 Occlusal view before remaining implant removal.** A: The rapidly growing gingiva had closed the gingival outlet of the implant; B: After a crestal full-thickness flap was raised, the implant hole filled with granulation tissue was observed.



DOI: 10.12998/wjcc.v10.i16.5479 Copyright ©The Author(s) 2022.

**Figure 3 The osteotomy procedure.** A: Two vertical incisions and one horizontal incision were made using an ultrasonic osteotome on the buccal plate; B: The buccal bone plate was removed with a bone chisel and a hammer; C: The broken end of the fractured implant was clearly exposed.

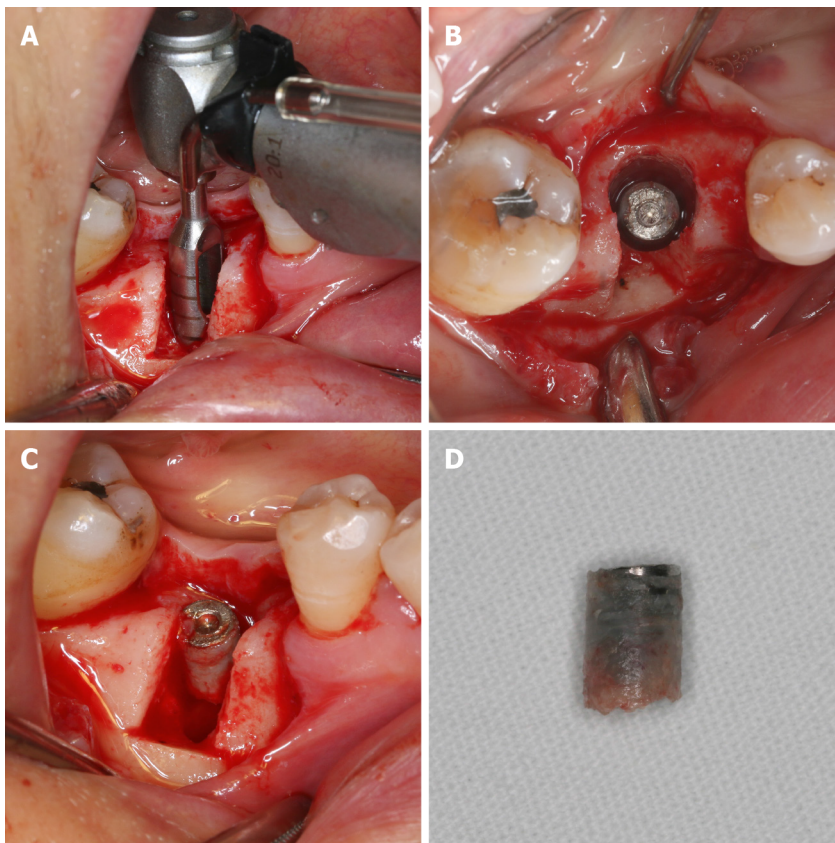
implant was clearly exposed (Figure 3C).

Next, the remaining implant was completely removed with a graduated trephine (Nobel Biocare®, Figure 4A), with the inner diameter of the trephine slightly larger than the outer diameter of the implant. From the occlusal view, a ring of uniform thickness was created around the remaining implant, which did not cause any unnecessary bone defects of the lateral wall and was achieved with minimal bone removal (Figure 4B). The remaining implant was then removed (Figure 4C). The surface of the implant was covered with a thin layer of osseointegrated alveolar bone (Figure 4D). After the surgery, a modified Wafer technique was performed; the buccal bone plate was repositioned *in situ* using a titanium screw with slight rotation (Figure 5A) to build the external wall of the osteogenic space. Guided bone regeneration (GBR) was performed. The alveolar bone defect was filled with demineralized bovine bone matrix (DBBM; Geistlich Bio-Oss), and the filled defect was covered with a biological membrane (Geistlich Bio-Gide). Finally, the wound was closed up tightly (Figure 5B).

## OUTCOME AND FOLLOW-UP

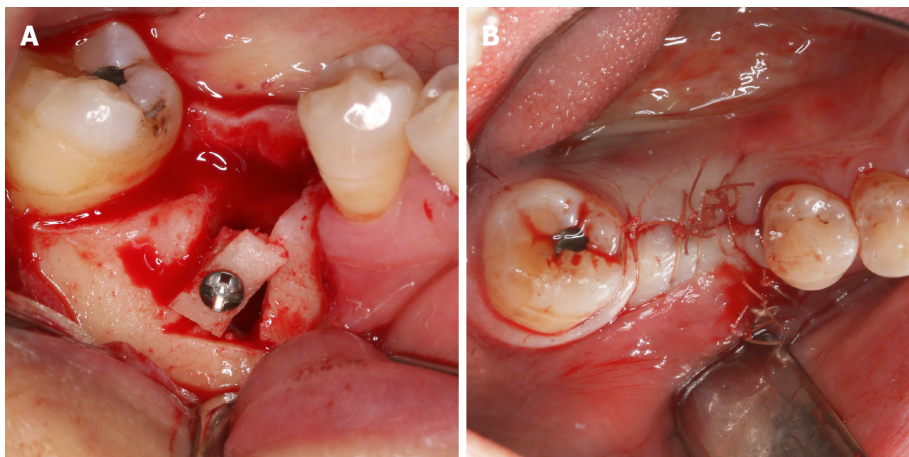
Six months after GBR, fine regenerative bone and wide alveolar crest in the edentulous area were observed. A new implant (Ankylos®, 4.5 mm × 9.5 mm, Germany) was placed in the #30 position. Four months later, restoration was completed using a cemented ceramic prosthesis. Periapical radiographic examination immediately after crown restoration showed a well-osseointegrated implant (Figure 6A). Furthermore, the clinical and radiographic examinations performed 12 mo after loading fulfilled the success criteria outlined by Papaspyridakos *et al* [13] (Figure 6B) [12,13]. The patient reported no complaints and was very satisfied.





DOI: 10.12998/wjcc.v10.i16.5479 Copyright ©The Author(s) 2022.

**Figure 4 Removal of the fractured implant with a trephine.** A: The remaining implant was completely removed with a graduated trephine; B: A ring of uniform thickness was created around the remaining implant from the occlusal view; C: The remaining segment was moved out; D: The surface of the implant was covered with a thin layer of osseointegrated alveolar bone.

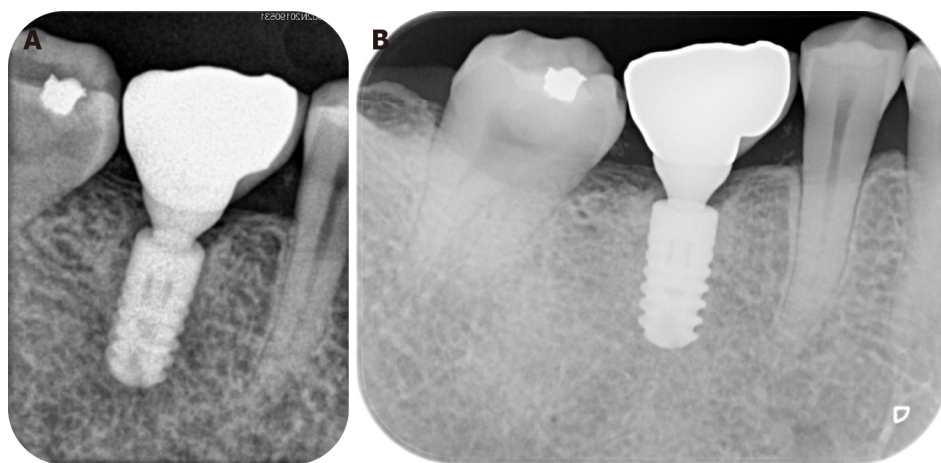


DOI: 10.12998/wjcc.v10.i16.5479 Copyright ©The Author(s) 2022.

**Figure 5 A modified Wafer technique-supported guided bone regeneration treatment was conducted simultaneously to preserve the horizontal alveolar dimension.** A: The buccal bone plate was repositioned in situ using a titanium nail with slight rotation; B: The wound was closed up tightly.

## DISCUSSION

The risk factors for implant fractures remain unclear. The possible risk factors include: (1) Implant diameter and length[5,14]—it is considered that the smaller the diameter, the lower the resistance of the implant to fracture; (2) Implant location (*i.e.*, type of bone)[5,15,16], as implants placed in the anterior or premolar region bear less mechanical overloading than those in the posterior region; (3) Direct adjacency to cantilever[17]; (4) Parafunctional habits (teeth clenching and bruxism)[9,18]; and (5) Patient-related factors (smoking and alcohol intake)[19,20].



DOI: 10.12998/wjcc.v10.i16.5479 Copyright ©The Author(s) 2022.

**Figure 6** The periapical radiographic examination. A: Immediately after the crown restoration showed a well-osseointegrated new implant; B: After 12 mo of function.

This case presents a novel method for managing invisible implant fractures. In brief, buccal bone plate osteotomy was conducted at the fractured implant site, followed by complete removal of the implant with a trephine to achieve minimal trauma. Subsequently, the modified Wafer technique was used to preserve the horizontal alveolar dimension. It is worth mentioning that the incision of the buccal bone plate was based on the CBCT results. Accurate osteotomy depth control was achieved by marking the ultrasonic osteotome in advance. In the present case, the surface of the removed implant was covered with a thin layer of osseointegrated alveolar bone. It was assumed that the trephine did not cut into the implant, and no titanium particles remained in the operation area.

The use of cortical bone plate supported GBR for bone mass preservation was inspired by the 3D bone reconstruction technique named the Bilaminar cortical tenting grafting technique proposed by Yu *et al*[21] and the Wafer technique proposed by Merli *et al*[22]. According to the bilaminar cortical tenting grafting technique, an autogenic bone block is bisected into two cortical laminae to construct the buccal and palatal walls of an alveolar ridge defect, and the inter-laminar space is filled with bone graft. In the Wafer technique, an autogenous plate is horizontally harvested and vertically fixed, partially supported by the residual bone wall, and the biomaterial is filled in. Both the techniques provide sufficient bone mass. We used the modified Wafer technique at the implant removal defect site to reconstruct the horizontal alveolar dimension, with the buccal bone plate obtained from the bone defect, thus avoiding a second surgical area[23].

Osteotomy combined with the trephine technique has many advantages in addressing deep and invisible implant fractures. This procedure avoids excessive bone removal or titanium particles, which can affect wound healing. The limitation of this technique is that immediate implantation cannot be achieved owing to insufficient primary stability. Therefore, this technique must be used in conjunction with delayed implantation, which is more time-consuming.

## CONCLUSION

This article proposes a novel osteotomy combined with the trephine technique, which effectively addressed an invisible implant fracture 5.1 mm beneath the alveolar crest. In addition, this article provides up-to-date knowledge regarding the clinical presentation, incidence, risk factors, diagnosis, and management of dental implant fractures.

## FOOTNOTES

**Author contributions:** Chen LW collected the data and drafted the article; Xia HB and Wang M collected the data; Chen D designed the study and revised the manuscript; and all authors approved the final version to be submitted.

**Informed consent statement:** The patient voluntarily provided written informed consent for publication of this report, personal medical information, and the accompanying images.

**Conflict-of-interest statement:** The authors declare no conflicts of interest.

**CARE Checklist (2016) statement:** The authors have read the CARE Checklist (2016), and the manuscript was prepared and revised according to the CARE Checklist (2016).

**Open-Access:** This article is an open-access article that was selected by an in-house editor and fully peer-reviewed by external reviewers. It is distributed in accordance with the Creative Commons Attribution NonCommercial (CC BY-NC 4.0) license, which permits others to distribute, remix, adapt, build upon this work non-commercially, and license their derivative works on different terms, provided the original work is properly cited and the use is non-commercial. See: <https://creativecommons.org/licenses/by-nc/4.0/>

**Country/Territory of origin:** China

**ORCID number:** Liang-Wen Chen 0000-0001-6455-0368; Min Wang 0000-0003-0085-6995; Hai-Bin Xia 0000-0003-2550-1146; Dong Chen 0000-0002-1075-8291.

**S-Editor:** Liu JH

**L-Editor:** A

**P-Editor:** Liu JH

## REFERENCES

- 1 Liaw K, Delfini RH, Abrahams JJ. Dental Implant Complications. *Semin Ultrasound CT MR* 2015; **36**: 427-433 [PMID: 26589696 DOI: 10.1053/j.sult.2015.09.007]
- 2 Jung RE, Zembic A, Pjetursson BE, Zwahlen M, Thoma DS. Systematic review of the survival rate and the incidence of biological, technical, and aesthetic complications of single crowns on implants reported in longitudinal studies with a mean follow-up of 5 years. *Clin Oral Implants Res* 2012; **23** Suppl 6: 2-21 [PMID: 23062124 DOI: 10.1111/j.1600-0501.2012.02547.x]
- 3 Jung RE, Pjetursson BE, Glauser R, Zembic A, Zwahlen M, Lang NP. A systematic review of the 5-year survival and complication rates of implant-supported single crowns. *Clin Oral Implants Res* 2008; **19**: 119-130 [PMID: 18067597 DOI: 10.1111/j.1600-0501.2007.01453.x]
- 4 Lee JH, Kim YT, Jeong SN, Kim NH, Lee DW. Incidence and pattern of implant fractures: A long-term follow-up multicenter study. *Clin Implant Dent Relat Res* 2018; **20**: 463-469 [PMID: 29761926 DOI: 10.1111/cid.12621]
- 5 Lee DW, Kim NH, Lee Y, Oh YA, Lee JH, You HK. Implant fracture failure rate and potential associated risk indicators: An up to 12-year retrospective study of implants in 5,124 patients. *Clin Oral Implants Res* 2019; **30**: 206-217 [PMID: 30672029 DOI: 10.1111/clr.13407]
- 6 Balshi TJ. An analysis and management of fractured implants: a clinical report. *Int J Oral Maxillofac Implants* 1996; **11**: 660-666 [PMID: 8908866]
- 7 Jin SY, Kim SG, Oh JS, You JS, Jeong MA. Incidence and Management of Fractured Dental Implants: Case Reports. *Implant Dent* 2017; **26**: 802-806 [PMID: 28846561 DOI: 10.1097/ID.0000000000000653]
- 8 Sánchez-Pérez A, Moya-Villaescusa MJ, Jornet-García A, Gomez S. Etiology, risk factors and management of implant fractures. *Med Oral Patol Oral Cir Bucal* 2010; **15**: e504-e508 [PMID: 20038899 DOI: 10.4317/medoral.15.e504]
- 9 Gealh WC, Mazzo V, Barbi F, Camarini ET. Osseointegrated implant fracture: causes and treatment. *J Oral Implantol* 2011; **37**: 499-503 [PMID: 20553152 DOI: 10.1563/AAID-JOI-D-09-00135.1]
- 10 Deeb G, Koerich L, Whitley D 3rd, Bencharit S. Computer-guided implant removal: A clinical report. *J Prosthet Dent* 2018; **120**: 796-800 [PMID: 29807745 DOI: 10.1016/j.prosdent.2017.10.032]
- 11 Gagnier JJ, Kienle G, Altman DG, Moher D, Sox H, Riley D; CARE Group. The CARE guidelines: consensus-based clinical case report guideline development. *J Clin Epidemiol* 2014; **67**: 46-51 [PMID: 24035173 DOI: 10.1016/j.jclinepi.2013.08.003]
- 12 Voza I, Barone A, Quaranta M, De Paolis G, Covani U, Quaranta A. A comparison between endodontics and implantology: an 8-year retrospective study. *Clin Implant Dent Relat Res* 2013; **15**: 29-36 [PMID: 22082010 DOI: 10.1111/j.1708-8208.2011.00397.x]
- 13 Papaspyridakos P, Chen CJ, Singh M, Weber HP, Gallucci GO. Success criteria in implant dentistry: a systematic review. *J Dent Res* 2012; **91**: 242-248 [PMID: 22157097 DOI: 10.1177/0022034511431252]
- 14 Chrcanovic BR, Kisch J, Albrektsson T, Wennerberg A. Factors influencing the fracture of dental implants. *Clin Implant Dent Relat Res* 2018; **20**: 58-67 [PMID: 29210188 DOI: 10.1111/cid.12572]
- 15 Miyamoto I, Takahashi T, Tanaka T, Hirayama B, Tanaka K, Yamazaki T, Morimoto Y, Yoshioka I. Dense cancellous bone as evidenced by a high HU value is predictive of late implant failure: a preliminary study. *Oral Radiol* 2018; **34**: 199-207 [PMID: 30484029 DOI: 10.1007/s11282-017-0299-3]
- 16 Rangert B, Krogh PH, Langer B, Van Roekel N. Bending overload and implant fracture: a retrospective clinical analysis. *Int J Oral Maxillofac Implants* 1995; **10**: 326-334 [PMID: 7615329]
- 17 Zurdo J, Romão C, Wennström JL. Survival and complication rates of implant-supported fixed partial dentures with cantilevers: a systematic review. *Clin Oral Implants Res* 2009; **20** Suppl 4: 59-66 [PMID: 19663951 DOI: 10.1111/j.1600-0501.2009.01773.x]
- 18 Anitua E, Saracho J, Almeida GZ, Duran-Cantolla J, Alkhraisat MH. Frequency of Prosthetic Complications Related to Implant-Borne Prosthesis in a Sleep Disorder Unit. *J Oral Implantol* 2017; **43**: 19-23 [PMID: 27700231 DOI: 10.1563/aaid-joi-D-16-00100]
- 19 Rani S, Devi J, Verma M. Implant success lies in complications management: A report of two cases. *Contemp Clin Dent*

- 2016; **7**: 226-228 [PMID: [27307672](#) DOI: [10.4103/0976-237X.183045](#)]
- 20 **Sridhar S**, Abidi Z, Wilson TG, Jr., Valderrama P, Wadhvani C, Palmer K and Rodrigues DC. In Vitro Evaluation of the Effects of Multiple Oral Factors on Dental Implants Surfaces. *J Oral Implantol* 2016; **42**: 248-257 [PMID: [26829492](#) DOI: [10.1563/aaid-joi-D-15-00165](#)]
- 21 **Yu H**, Chen L, Zhu Y, Qiu L. Bilamina cortical tenting grafting technique for three-dimensional reconstruction of severely atrophic alveolar ridges in anterior maxillae: A 6-year prospective study. *J Craniomaxillofac Surg* 2016; **44**: 868-875 [PMID: [27235152](#) DOI: [10.1016/j.jcms.2016.04.018](#)]
- 22 **Merli M**, Moscatelli M, Mariotti G, Motroni A, Mazzoni A, Mazzoni S, Breschi L, Nieri M. A Novel Approach to Bone Reconstruction: The Wafer Technique. *Int J Periodontics Restorative Dent* 2017; **37**: 317-325 [PMID: [28402341](#) DOI: [10.11607/prd.3055](#)]
- 23 **Xia HB**, Zhang YF, Shi B, Wang M. Two bone blocks sandwich technique for horizontal reconstruction of severely atrophic alveolar ridge in anterior maxilla: A case report. *World J Clin Cases* 2020; **8**: 971-979 [PMID: [32190635](#) DOI: [10.12998/wjcc.v8.i5.971](#)]



Published by **Baishideng Publishing Group Inc**  
7041 Koll Center Parkway, Suite 160, Pleasanton, CA 94566, USA

**Telephone:** +1-925-3991568

**E-mail:** [bpgoffice@wjgnet.com](mailto:bpgoffice@wjgnet.com)

**Help Desk:** <https://www.f6publishing.com/helpdesk>

<https://www.wjgnet.com>

