

# World Journal of *Gastroenterology*

*World J Gastroenterol* 2017 October 7; 23(37): 6747-6922



**EDITORIAL**

- 6747 Microbial dysbiosis in spouses of ulcerative colitis patients: Any clues to disease pathogenesis?  
*Sorrentino D*

**REVIEW**

- 6750 Road to stemness in hepatocellular carcinoma  
*Flores-Téllez TNJ, Villa-Treviño S, Piña-Vázquez C*
- 6777 Intrahepatic vascular changes in non-alcoholic fatty liver disease: Potential role of insulin-resistance and endothelial dysfunction  
*Pasarin M, Abalde JG, Liguori E, Kok B, La Mura V*
- 6788 Epidemiological and clinical perspectives on irritable bowel syndrome in India, Bangladesh and Malaysia: A review  
*Rahman MM, Mahadeva S, Ghoshal UC*

**ORIGINAL ARTICLE****Basic Study**

- 6802 Estrogen receptor expression in chronic hepatitis C and hepatocellular carcinoma pathogenesis  
*Iyer JK, Kalra M, Kaul A, Payton ME, Kaul R*
- 6817 Glycosylation-related gene expression in HT29-MTX-E12 cells upon infection by *Helicobacter pylori*  
*Cairns MT, Gupta A, Naughton JA, Kane M, Clyne M, Joshi L*
- 6833 STAT3 deficiency prevents hepatocarcinogenesis and promotes biliary proliferation in thioacetamide-induced liver injury  
*Abe M, Yoshida T, Akiba J, Ikezono Y, Wada F, Masuda A, Sakaue T, Tanaka T, Iwamoto H, Nakamura T, Sata M, Koga H, Yoshimura A, Torimura T*
- 6845 Performance verification and comparison of TianLong automatic hypersensitive hepatitis B virus DNA quantification system with Roche CAP/CTM system  
*Li M, Chen L, Liu LM, Li YL, Li BA, Li B, Mao YL, Xia LF, Wang T, Liu YN, Li Z, Guo TS*

**Case Control Study**

- 6854 Association of insertion-deletions polymorphisms with colorectal cancer risk and clinical features  
*Marques D, Ferreira-Costa LR, Ferreira-Costa LL, Correa RS, Borges AMP, Ito FR, Ramos CCO, Bortolin RH, Luchessi AD, Ribeiro-dos-Santos A, Santos S, Silbiger VN*

**Retrospective Cohort Study**

- 6868** Hospital readmissions in decompensated cirrhotics: Factors pointing toward a prevention strategy

*Seraj SM, Campbell EJ, Argyropoulos SK, Wegermann K, Chung RT, Richter JM*

- 6877** Measurement of biological age may help to assess the risk of colorectal adenoma in screening colonoscopy

*Kim SJ, Kim BJ, Kang H*

**Retrospective Study**

- 6884** Prognostic factors of response to endoscopic treatment in painful chronic pancreatitis

*Tantau A, Mandrutiu A, Leucuta DC, Ciobanu L, Tantau M*

- 6894** *In vivo* histological diagnosis for gastric cancer using endocytoscopy

*Tsurudome I, Miyahara R, Funasaka K, Furukawa K, Matsushita M, Yamamura T, Ishikawa T, Ohno E, Nakamura M, Kawashima H, Watanabe O, Nakaguro M, Satou A, Hirooka Y, Goto H*

**CASE REPORT**

- 6902** Achalasia after bariatric Roux-en-Y gastric bypass surgery reversal

*Abu Ghanimeh M, Qasrawi A, Abughanimeh O, Albadarin S, Clarkston W*

- 6907** Persistent severe hypomagnesemia caused by proton pump inhibitor resolved after laparoscopic fundoplication

*Semb S, Helgstrand F, Hjørne F, Bytzer P*

- 6911** Rupture of small cystic pancreatic neuroendocrine tumor with many microtumors

*Sagami R, Nishikiori H, Ikuyama S, Murakami K*

**LETTERS TO THE EDITOR**

- 6920** Resistance of *Helicobacter pylori* to furazolidone and levofloxacin: A viewpoint

*Zamani M, Rahbar A, Shokri-Shirvani J*

## ABOUT COVER

Editorial board member of *World Journal of Gastroenterology*, Toru Mizuguchi, MD, PhD, Associate Professor, Surgeon, Department of Surgery, Surgical Oncology and Science, Sapporo Medical University Hospital, Sapporo 060-8543, Hokkaido, Japan

## AIMS AND SCOPE

*World Journal of Gastroenterology* (*World J Gastroenterol*, *WJG*, print ISSN 1007-9327, online ISSN 2219-2840, DOI: 10.3748) is a peer-reviewed open access journal. *WJG* was established on October 1, 1995. It is published weekly on the 7<sup>th</sup>, 14<sup>th</sup>, 21<sup>st</sup>, and 28<sup>th</sup> each month. The *WJG* Editorial Board consists of 1375 experts in gastroenterology and hepatology from 68 countries.

The primary task of *WJG* is to rapidly publish high-quality original articles, reviews, and commentaries in the fields of gastroenterology, hepatology, gastrointestinal endoscopy, gastrointestinal surgery, hepatobiliary surgery, gastrointestinal oncology, gastrointestinal radiation oncology, gastrointestinal imaging, gastrointestinal interventional therapy, gastrointestinal infectious diseases, gastrointestinal pharmacology, gastrointestinal pathophysiology, gastrointestinal pathology, evidence-based medicine in gastroenterology, pancreatology, gastrointestinal laboratory medicine, gastrointestinal molecular biology, gastrointestinal immunology, gastrointestinal microbiology, gastrointestinal genetics, gastrointestinal translational medicine, gastrointestinal diagnostics, and gastrointestinal therapeutics. *WJG* is dedicated to become an influential and prestigious journal in gastroenterology and hepatology, to promote the development of above disciplines, and to improve the diagnostic and therapeutic skill and expertise of clinicians.

## INDEXING/ABSTRACTING

*World Journal of Gastroenterology* (*WJG*) is now indexed in Current Contents<sup>®</sup>/Clinical Medicine, Science Citation Index Expanded (also known as SciSearch<sup>®</sup>), Journal Citation Reports<sup>®</sup>, Index Medicus, MEDLINE, PubMed, PubMed Central and Directory of Open Access Journals. The 2017 edition of Journal Citation Reports<sup>®</sup> cites the 2016 impact factor for *WJG* as 3.365 (5-year impact factor: 3.176), ranking *WJG* as 29<sup>th</sup> among 79 journals in gastroenterology and hepatology (quartile in category Q2).

## FLYLEAF

## I-IX Editorial Board

## EDITORS FOR THIS ISSUE

Responsible Assistant Editor: *Xiang Li*  
Responsible Electronic Editor: *Yan Huang*  
Proofing Editor-in-Chief: *Lian-Sheng Ma*

Responsible Science Editor: *Li-Juan Wei*  
Proofing Editorial Office Director: *Jin-Lei Wang*

NAME OF JOURNAL  
*World Journal of Gastroenterology*

ISSN  
ISSN 1007-9327 (print)  
ISSN 2219-2840 (online)

LAUNCH DATE  
October 1, 1995

FREQUENCY  
Weekly

EDITORS-IN-CHIEF  
**Damian Garcia-Olmo, MD, PhD, Doctor, Professor, Surgeon**, Department of Surgery, Universidad Autonoma de Madrid; Department of General Surgery, Fundacion Jimenez Diaz University Hospital, Madrid 28040, Spain

**Stephen C Strom, PhD, Professor**, Department of Laboratory Medicine, Division of Pathology, Karolinska Institutet, Stockholm 141-86, Sweden

**Andrzej S Tarnawski, MD, PhD, DSc (Med), Professor of Medicine, Chief Gastroenterology**, VA Long Beach Health Care System, University of California, Irvine, CA, 5901 E. Seventh Str., Long Beach,

CA 90822, United States

EDITORIAL BOARD MEMBERS  
All editorial board members resources online at <http://www.wjgnet.com/1007-9327/editorialboard.htm>

EDITORIAL OFFICE  
Jin-Lei Wang, Director  
Yuan Qi, Vice Director  
Ze-Mao Gong, Vice Director  
*World Journal of Gastroenterology*  
Baishideng Publishing Group Inc  
7901 Stoneridge Drive, Suite 501,  
Pleasanton, CA 94588, USA  
Telephone: +1-925-2238242  
Fax: +1-925-2238243  
E-mail: [editorialoffice@wjgnet.com](mailto:editorialoffice@wjgnet.com)  
Help Desk: <http://www.f6publishing.com/helpdesk>  
<http://www.wjgnet.com>

PUBLISHER  
Baishideng Publishing Group Inc  
7901 Stoneridge Drive, Suite 501,  
Pleasanton, CA 94588, USA  
Telephone: +1-925-2238242  
Fax: +1-925-2238243  
E-mail: [bpoffice@wjgnet.com](mailto:bpoffice@wjgnet.com)  
Help Desk: <http://www.f6publishing.com/helpdesk>

<http://www.wjgnet.com>


PUBLICATION DATE  
October 7, 2017

COPYRIGHT  
© 2017 Baishideng Publishing Group Inc. Articles published by this Open-Access journal are distributed under the terms of the Creative Commons Attribution Non-commercial License, which permits use, distribution, and reproduction in any medium, provided the original work is properly cited, the use is non commercial and is otherwise in compliance with the license.

SPECIAL STATEMENT  
All articles published in journals owned by the Baishideng Publishing Group (BPG) represent the views and opinions of their authors, and not the views, opinions or policies of the BPG, except where otherwise explicitly indicated.

INSTRUCTIONS TO AUTHORS  
Full instructions are available online at <http://www.wjgnet.com/bpg/gerinfo/204>

ONLINE SUBMISSION  
<http://www.f6publishing.com>



## Persistent severe hypomagnesemia caused by proton pump inhibitor resolved after laparoscopic fundoplication

Synne Semb, Frederik Helgstrand, Flemming Hjørne, Peter Bytzer

Synne Semb, Peter Bytzer, Department of Gastroenterology, Zealand University Hospital, 4600 Køge, Denmark

Frederik Helgstrand, Flemming Hjørne, Department of Surgery, Zealand University Hospital, 4600 Køge, Denmark

Frederik Helgstrand, Department of Clinical Medicine, University of Copenhagen, 2200 Copenhagen N, Denmark

Peter Bytzer, Department of Clinical Medicine, University of Copenhagen, 2200 Copenhagen N, Denmark

**Author contributions:** Semb S drafted the manuscript; Helgstrand F, Hjørne F, Bytzer P revised the manuscript.

**Informed consent statement:** The patient has given (verbal) informed consent prior to publication.

**Conflict-of-interest statement:** None to report.

**Open-Access:** This article is an open-access article which was selected by an in-house editor and fully peer-reviewed by external reviewers. It is distributed in accordance with the Creative Commons Attribution Non Commercial (CC BY-NC 4.0) license, which permits others to distribute, remix, adapt, build upon this work non-commercially, and license their derivative works on different terms, provided the original work is properly cited and the use is non-commercial. See: <http://creativecommons.org/licenses/by-nc/4.0/>

**Manuscript source:** Unsolicited manuscript

**Correspondence to:** Synne Semb, MD, Department of Medicine, Division of Gastroenterology and Hepatology, Zealand University Hospital, Lykkebakvej 1, 4600 Køge, Denmark. [sys@regionsjaelland.dk](mailto:sys@regionsjaelland.dk)  
Telephone: +45-23-328029  
Fax: +45-56-631562

Received: February 24, 2017

Peer-review started: February 27, 2017

First decision: April 21, 2017

Revised: May 12, 2017

Accepted: July 12, 2017

Article in press: July 12, 2017

Published online: October 7, 2017

### Abstract

Magnesium deficiency can cause a variety of symptoms, including potentially life-threatening complications such as seizures, cardiac arrhythmias and secondary electrolyte disturbances. Hypomagnesemia can be a serious adverse effect to proton pump inhibitor (PPI) therapy, which is worrying due to the widespread use of PPIs. Current evidence suggest that the mechanism of PPI induced hypomagnesemia is impaired intestinal magnesium absorption. In this report, we present the case of a long-term PPI user with persistent hypomagnesemia with severe symptoms at presentation. He was unable to stop PPI treatment because of severe reflux symptoms, and was dependent on weekly intravenous magnesium infusions, until his magnesium levels finally normalized without the need for supplementation after a successful laparoscopic fundoplication.

**Key words:** Hypomagnesemia; Proton pump inhibitor; Gastroesophageal reflux disease; Drug adverse effect; Laparoscopic fundoplication

© **The Author(s) 2017.** Published by Baishideng Publishing Group Inc. All rights reserved.

**Core tip:** This case illustrates a long-term proton pump inhibitor (PPI) user with persistent hypomagnesaemia causing severe symptoms at presentation. For years, he was dependent on oral and later intravenous magnesium supplementation, until his hypomagnesemia rapidly improved upon PPI discontinuation. He was, however, not able to cope with the resulting reflux symptoms, and was not able to completely stop PPI



treatment until he underwent a successful laparoscopic fundoplication.

Semb S, Helgstrand F, Hjørne F, Bytzer P. Persistent severe hypomagnesemia caused by proton pump inhibitor resolved after laparoscopic fundoplication. *World J Gastroenterol* 2017; 23(37): 6907-6910 Available from: URL: <http://www.wjgnet.com/1007-9327/full/v23/i37/6907.htm> DOI: <http://dx.doi.org/10.3748/wjg.v23.i37.6907>

## INTRODUCTION

Magnesium plays an essential role in several physiological and biochemical bodily processes. Consequently, magnesium deficiency can cause a variety of symptoms, ranging from nonspecific complaints of weakness, fatigue and nausea to potentially life threatening complications such as seizures, cardiac arrhythmias and secondary electrolyte disturbances. Hypomagnesemia can develop due to gastrointestinal and/or renal disease, as well as an adverse effect to several medications. Several reports of severe hypomagnesemia associated with long term proton pump inhibitor (PPI) therapy<sup>[1,2]</sup> is causing concern due to the widespread use of PPIs<sup>[3]</sup>. Current evidence suggest that PPI impair the intestinal magnesium absorption through a molecular effect on magnesium transporters in genetically predisposed individuals<sup>[4]</sup>.

We present the first case of a long-term PPI user with severe and symptomatic persistent hypomagnesemia treated with surgery. Due to severe reflux, the patient was PPI dependent, and needed weekly intravenous magnesium infusions. After a successful laparoscopic fundoplication, the PPI treatment could be discontinued, and the magnesium levels normalized without the need for supplementation.

## CASE REPORT

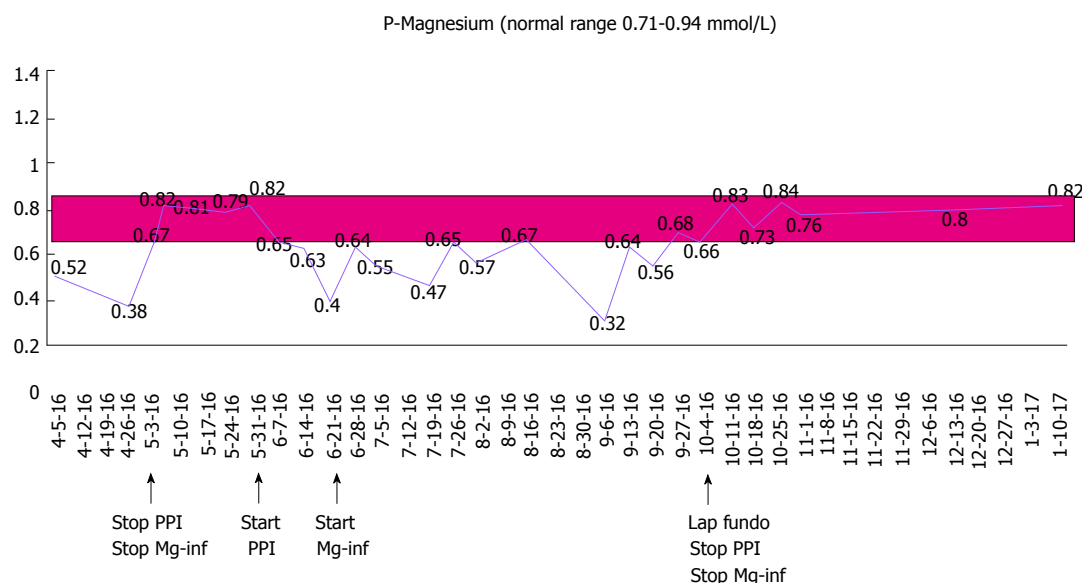
A 67-year-old male with a history of gastroesophageal reflux disease (GERD) and hypertension, first presented with severe hypomagnesemia during a hospital admission in 2012. At that time, he was taking 10 mg amlodipine and 20-40 mg omeprazole daily. Prior to admission, he had suffered from severe dizziness, double sight and vomiting for several weeks, and was initially dehydrated with electrolyte derangement (hypokalemia). A few days after admission he developed general seizures, and additional laboratory tests revealed severe hypomagnesemia [0.23 mmol/L (0.71-0.94 mmol/L)], considered a result of excessive vomiting prior to admission. His serum electrolyte levels normalized upon intravenous treatment. An extensive work-up resulted in a possible diagnosis of viral encephalitis, and after discharge, he underwent a prolonged rehabilitation course. A year later, he

was re-admitted because of dizziness, balance problems and paresthesia. Laboratory results again showed severe hypomagnesemia (0.08 mmol/L). He received intravenous magnesium infusions and his symptoms disappeared. During ambulatory follow-up, he was found to have persistent hypomagnesemia, and oral magnesium was prescribed. He underwent endocrinological and gastrointestinal investigations including colonoscopy, which did not reveal any other cause of his hypomagnesemia. His urinary magnesium level was low (< 0.080 mmol/L). Despite oral magnesium supplementation, magnesium levels continued to stay low, and in 2015, he was started on weekly magnesium infusions to maintain normal magnesium levels. The only medication he was on during these years was omeprazol 20-40 mg daily. He had been advised several times during the years to stop PPI treatment, but was unable to cope with the resulting reflux symptoms. In April 2016, he did, however, agree to stop taking PPI and consequently maintained normal magnesium levels without infusions. 24-h pH testing confirmed reflux disease, and he was offered anti-reflux surgery (laparoscopic fundoplication). While awaiting the operation, he started taking daily PPI again, which resulted in a prompt drop in his serum magnesium levels demanding a resumption of weekly magnesium infusions. The patient underwent a laparoscopic fundoplication and was discharged after an uncomplicated peri- and postoperative course. After the operation, the reflux symptoms as well as the need for PPI disappeared, and his magnesium level maintained normal without supplementation at the follow-up visit. The course of the patient's magnesium levels is illustrated in Figure 1.

## DISCUSSION

This rare case illustrates a long-term PPI user with persistent hypomagnesemia causing severe symptoms at presentation. For years, he was dependent on oral and later weekly intravenous magnesium supplementation, until his hypomagnesemia rapidly improved upon PPI discontinuation. Re-challenge of PPI treatment resulted in a prompt drop in serum magnesium within days, and his magnesium levels again normalized rapidly following PPI withdrawal after laparoscopic fundoplication.

PPI-induced hypomagnesemia (PPIH) was first described by Epstein *et al*<sup>[5]</sup> in 2006, and subsequently several other case reports have demonstrated the association. In 2011, the United States Food and Drug Administration issued a safety announcement regarding the association between long term PPI use and hypomagnesemia, and PPIH is now well-established as a rare, but potentially serious, adverse effect of long term PPI treatment. However, PPIH is still not widely acknowledged, and the frequency and risk



**Figure 1** Course of the patient's magnesium levels. The figure illustrates how the patient's S-Mg level stays persistently below the normal range while he is on PPI therapy despite receiving magnesium infusions. S-Mg normalizes promptly after cessation of PPI therapy. PPI: Proton pump inhibitor.

factors of PPIH are not well recognized.

PPIH has been observed with all different formulations of PPIs and is thus considered a class drug effect. Similar to our case, previous reports have documented only partial effect of oral magnesium supplements in correcting the hypomagnesemia during ongoing PPI-therapy<sup>[2]</sup>, and only short term relief with intravenous magnesium infusions. In contrast, hypomagnesemia is typically improved promptly after the PPI is discontinued, and PPI re-challenge results in rapid recurrence of hypomagnesemia<sup>[1,2]</sup>. The same phenomenon has not been observed with histamine 2 receptor antagonists (H2RAs), although a recent population-based study suggested a similar but weaker association with the use of these drugs<sup>[6]</sup>. Previous reports have suggested that PPIH occurs after long term PPI use<sup>[1]</sup>; however, duration of exposure to PPI therapy is often difficult to quantify retrospectively and the duration of PPI use necessary to cause PPIH remains uncertain.

Magnesium homeostasis is mainly determined by absorption in the small intestine, and renal excretion. Intestinal magnesium absorption is complex, and occurs via both passive and active transport mechanisms. Firstly, magnesium is passively absorbed through a paracellular pathway between the enterocytes of the intestine across a concentration gradient. Secondly, a transcellular active transport mechanism occur by means of a combined action of magnesium channels in the apical membrane of enterocytes on the luminal surface, particularly transient receptor potential melastin (TRPM) 6 and 7. It has been proposed that increased luminal pH in the intestine caused by PPIs may alter the affinity of the TRPM6/7 channel for magnesium, resulting in reduced active transport of magnesium, and that individual genetic variations in the TRPM could explain why PPIH does not develop

in all PPI users<sup>[4]</sup>. Several other drugs can cause hypomagnesemia, where the underlying mechanism is tubular magnesium wasting<sup>[1]</sup>. In contrast, previous case reports of PPIH have documented consistently low urinary excretion coherent with efficient tubular magnesium retention<sup>[1,2]</sup>, which is thought to support the theory of impaired gastrointestinal absorption as the mechanism leading to PPIH.

Some patients might be more susceptible to PPIH due to other coexisting risk factors such as concomitant medication (diuretics) or other medical conditions associated with hypomagnesemia such as diabetes mellitus, inflammatory bowel disease, short-bowel disease, chronic pancreatitis, diarrhea and/or alcoholism. It remains controversial whether serum magnesium should be monitored in all long-term PPI users, or perhaps in specific subsets of patients with additional risk factors. Nonetheless, PPIH should be remembered as a differential diagnosis in patients with PPI use and unexplained hypomagnesemia. Patients with PPIH and persistent troublesome reflux symptoms after PPI discontinuation could be considered for anti-reflux surgery. It should be remembered, however, that a majority of patients treated with anti-reflux surgery have resumed PPI therapy 10-15 years after the operation<sup>[7]</sup>, and it is mandatory to control for hypomagnesemia if patients with previous PPIH resume PPI treatment.

## COMMENTS

### Case characteristics

A 67-year old male with gastroesophageal reflux disease and persistent severe hypomagnesemia demanding weekly intravenous magnesium infusions.

### Clinical diagnosis

Extensive work-up did not reveal any other cause of hypomagnesaemia.

Serum magnesium levels rapidly normalized upon pump inhibitor (PPI) discontinuation, and re-challenge of PPI treatment resulted in a prompt drop in serum magnesium within days. Magnesium levels again normalized following PPI withdrawal after laparoscopic fundoplication.

### Differential diagnosis

Gastrointestinal or renal disease causing either impaired absorption or increased excretion of magnesium.

### Laboratory diagnosis

Initially the patient had severe hypomagnesemia (0.23 mmol/L) with associated hypokalemia, which both resolved with intravenous magnesium infusions. However, the patient had continuously low S-Mg levels during the disease course despite both oral and intravenous magnesium supplementation, where other laboratory tests were normal.

### Imaging diagnosis

Neither colonoscopy nor CT scans revealed any other explanation for the patient's persistent hypomagnesaemia.

### Pathological diagnosis

Biopsies taken from terminal ileum and colon during colonoscopy were normal.

### Treatment

The patient underwent a successful laparoscopic fundoplication, and his serum magnesium levels again normalized following PPI withdrawal after the surgery.

### Related reports

PPI-induced hypomagnesemia (PPIH) was first described in 2006, and subsequently several other case reports have demonstrated the association. In 2011, the US Food and Drug Administration issued a safety announcement regarding the association between long term PPI use and hypomagnesemia, and PPIH is now well-established as a rare, but potentially serious, adverse effect of long term PPI treatment.

### Term explanation

PPIH is a rare, but potentially serious adverse effect where persistent severe hypomagnesemia is associated with of long-term PPI treatment. PPIH is probably caused by impaired intestinal magnesium absorption through a molecular effect on magnesium transporters in genetically predisposed

individuals.

### Experiences and lessons

PPIH should be remembered as a differential diagnosis in patients with PPI use and unexplained hypomagnesemia. Patients with PPIH and persistent troublesome reflux symptoms after PPI discontinuation could be considered for anti-reflux surgery

### Peer-review

The manuscript describes surgical option in the management of hypomagnesemia induced by PPIs. The condition has been described earlier but fundoplication as an option has not been discussed in earlier reports. The manuscript is well written and may be accepted with few clarifications.

## REFERENCES

- 1 Hess MW, Hoenderop JG, Bindels RJ, Drenth JP. Systematic review: hypomagnesaemia induced by proton pump inhibition. *Aliment Pharmacol Ther* 2012; **36**: 405-413 [PMID: 22762246 DOI: 10.1111/j.1365-2036.2012.05201.x]
- 2 Mackay JD, Bladon PT. Hypomagnesaemia due to proton-pump inhibitor therapy: a clinical case series. *QJM* 2010; **103**: 387-395 [PMID: 20378675 DOI: 10.1093/qjmed/hcq021]
- 3 Forgacs I, Loganayagam A. Overprescribing proton pump inhibitors. *BMJ* 2008; **336**: 2-3 [PMID: 18174564 DOI: 10.1136/bmj.39406.449456.BE]
- 4 William JH, Danziger J. Proton-pump inhibitor-induced hypomagnesemia: Current research and proposed mechanisms. *World J Nephrol* 2016; **5**: 152-157 [PMID: 26981439 DOI: 10.5527/wjn.v5.i2.152]
- 5 Epstein M, McGrath S, Law F. Proton-pump inhibitors and hypomagnesemic hypoparathyroidism. *N Engl J Med* 2006; **355**: 1834-1836 [PMID: 17065651 DOI: 10.1056/NEJMc066308]
- 6 Kieboom BC, Kieft-de Jong JC, Eijgelsheim M, Franco OH, Kuipers EJ, Hofman A, Zietse R, Stricker BH, Hoorn EJ. Proton pump inhibitors and hypomagnesemia in the general population: a population-based cohort study. *Am J Kidney Dis* 2015; **66**: 775-782 [PMID: 26123862 DOI: 10.1053/j.ajkd.2015.05.012]
- 7 Lødrup A, Pottegård A, Hallas J, Bytzer P. Use of proton pump inhibitors after antireflux surgery: a nationwide register-based follow-up study. *Gut* 2014; **63**: 1544-1549 [PMID: 24474384 DOI: 10.1136/gutjnl-2013-306532]

P- Reviewer: Hasegawa H S- Editor: Gong ZM L- Editor: A  
E- Editor: Ma YJ







Published by **Baishideng Publishing Group Inc**  
7901 Stoneridge Drive, Suite 501, Pleasanton, CA 94588, USA  
Telephone: +1-925-223-8242  
Fax: +1-925-223-8243  
E-mail: [bpgoffice@wjgnet.com](mailto:bpgoffice@wjgnet.com)  
Help Desk: <http://www.f6publishing.com/helpdesk>  
<http://www.wjgnet.com>



ISSN 1007-9327



9 771007 932045