

# World Journal of *Gastrointestinal Surgery*

*World J Gastrointest Surg* 2020 October 27; 12(10): 407-441



## Contents

Monthly Volume 12 Number 10 October 27, 2020

## REVIEW

- 407 Exosomal noncoding RNAs in cholangiocarcinoma: Laboratory noise or hope?  
*Laschos K, Lampropoulou DI, Aravantinos G, Piperis M, Filippou D, Theodoropoulos G, Gazouli M*

## ORIGINAL ARTICLE

## Retrospective Cohort Study

- 425 Narrow pelvic inlet plane area and obesity as risk factors for anastomotic leakage after intersphincteric resection  
*Toyoshima A, Nishizawa T, Sunami E, Akai R, Amano T, Yamashita A, Sasaki S, Endo T, Moriya Y, Toyoshima O*

## CASE REPORT

- 435 Gastric splenosis mimicking a gastrointestinal stromal tumor: A case report  
*Isopi C, Vitali G, Pieri F, Solaini L, Ercolani G*

## ABOUT COVER

Editorial board member of *World Journal of Gastrointestinal Surgery*, Professor Marcello Donati, MD, PhD, FACS, is an Italian general surgeon, who completed his surgical training in hepatobiliary, advanced abdominal oncologic and emergency surgery in Germany. He is currently Associate Professor of General Surgery at University of Catania (Italy) and has been a Visiting Professor in Hamburg (Germany), Sarajevo (Bosnia-Herzegovina), Malta (Malta International School of Medicine) and Bremen (Germany) as well as an Invited Lecturer in Bialystok (Poland), Minsk (Belarus), and Harvard-Boston (United States). He has spoken in many National and International Congresses and served as editorial board member and reviewer for many international journals of surgery, gastroenterology, and oncology, authoring about 150 papers. (L-Editor: Filipodia)

## AIMS AND SCOPE

The primary aim of *World Journal of Gastrointestinal Surgery* (WJGS, *World J Gastrointest Surg*) is to provide scholars and readers from various fields of gastrointestinal surgery with a platform to publish high-quality basic and clinical research articles and communicate their research findings online.

WJGS mainly publishes articles reporting research results and findings obtained in the field of gastrointestinal surgery and covering a wide range of topics including biliary tract surgical procedures, biliopancreatic diversion, colectomy, esophagectomy, esophagostomy, pancreas transplantation, pancreatectomy, pancreaticoduodenectomy, and pancreaticojejunostomy, etc.

## INDEXING/ABSTRACTING

The WJGS is now abstracted and indexed in Science Citation Index Expanded (SCIE, also known as SciSearch®), Current Contents/Clinical Medicine, Journal Citation Reports/Science Edition, PubMed, and PubMed Central. The 2020 edition of Journal Citation Reports® cites the 2019 impact factor (IF) for WJGS as 1.863; IF without journal self cites: 1.824; Ranking: 109 among 210 journals in surgery; Quartile category: Q3; Ranking: 77 among 88 journals in gastroenterology and hepatology; and Quartile category: Q4.

## RESPONSIBLE EDITORS FOR THIS ISSUE

Production Editor: Ji-Hong Liu; Production Department Director: Xiang Li; Editorial Office Director: Jia-Ping Yan.

### NAME OF JOURNAL

*World Journal of Gastrointestinal Surgery*

### ISSN

ISSN 1948-9366 (online)

### LAUNCH DATE

November 30, 2009

### FREQUENCY

Monthly

### EDITORS-IN-CHIEF

Shu-You Peng, Varut Lohsiriwat, Jin Gu

### EDITORIAL BOARD MEMBERS

<https://www.wjgnet.com/1948-9366/editorialboard.htm>

### PUBLICATION DATE

October 27, 2020

### COPYRIGHT

© 2020 Baishideng Publishing Group Inc

### INSTRUCTIONS TO AUTHORS

<https://www.wjgnet.com/bpg/gerinfo/204>

### GUIDELINES FOR ETHICS DOCUMENTS

<https://www.wjgnet.com/bpg/GerInfo/287>

### GUIDELINES FOR NON-NATIVE SPEAKERS OF ENGLISH

<https://www.wjgnet.com/bpg/gerinfo/240>

### PUBLICATION ETHICS

<https://www.wjgnet.com/bpg/GerInfo/288>

### PUBLICATION MISCONDUCT

<https://www.wjgnet.com/bpg/gerinfo/208>

### ARTICLE PROCESSING CHARGE

<https://www.wjgnet.com/bpg/gerinfo/242>

### STEPS FOR SUBMITTING MANUSCRIPTS

<https://www.wjgnet.com/bpg/GerInfo/239>

### ONLINE SUBMISSION

<https://www.f6publishing.com>

## Retrospective Cohort Study

## Narrow pelvic inlet plane area and obesity as risk factors for anastomotic leakage after intersphincteric resection

Akira Toyoshima, Toshihiro Nishizawa, Eiji Sunami, Ryuji Akai, Takahiro Amano, Akiyoshi Yamashita, Shin Sasaki, Takeshi Endo, Yoshihiro Moriya, Osamu Toyoshima

**ORCID number:** Akira Toyoshima 0000-0002-5697-6251; Toshihiro Nishizawa 0000-0003-4876-3384; Eiji Sunami 0000-0002-3637-9732; Ryuji Akai 0000-0001-7241-6265; Takahiro Amano 0000-0002-0489-7519; Akiyoshi Yamashita 0000-0002-3519-084X; Shin Sasaki 0000-0003-3489-6821; Takeshi Endo 0000-0002-3394-0213; Yoshihiro Moriya 0000-0002-7865-8748; Osamu Toyoshima 0000-0002-6953-6079.

**Author contributions:** Toyoshima A is the lead investigator, performed operations, collected and analyzed the data, and wrote the manuscript; Nishizawa T performed the literature search and statistical analysis and wrote the manuscript; Sunami E performed the operations; Akai R and Amano T assisted the operations; Yamashita A drafted the conception; Sasaki S supervised the study and approved the final manuscript; Toyoshima O contributed to data management, interpretation, and revision.

**Institutional review board**

**statement:** This retrospective study was approved by the ethics review board of the Japanese Red Cross Medical Center on July 31, 2019.

**Informed consent statement:**

Patients were not required to give

**Akira Toyoshima, Ryuji Akai, Takahiro Amano, Shin Sasaki,** Department of Colorectal Surgery, Japanese Red Cross Medical Center, Tokyo 150-8935, Japan

**Toshihiro Nishizawa,** Department of Gastroenterology, International University of Health and Welfare, Narita Hospital, Narita 286-8520, Japan

**Toshihiro Nishizawa, Osamu Toyoshima,** Department of Gastroenterology, Toyoshima Endoscopy Clinic, Tokyo 157-0066, Japan

**Eiji Sunami,** Department of Surgery, The University of Kyorin, Tokyo 113-8655, Japan

**Akiyoshi Yamashita,** Department of Radiology, Japanese Red Cross Medical Center, Tokyo 150-8935, Japan

**Takeshi Endo,** Tokyo Midtown Clinic, Tokyo 107-6206, Japan

**Yoshihiro Moriya,** Miki Hospital, Iwate 029-4201, Japan

**Corresponding author:** Akira Toyoshima, MD, Doctor, Department of Colorectal Surgery, Japanese Red Cross Medical Center, 4-1-22 Hiroo, Shibuya-ku, Tokyo 150-8935, Japan. [toyosanaa@yahoo.co.jp](mailto:toyosanaa@yahoo.co.jp)

**Abstract****BACKGROUND**

Intersphincteric resection (ISR) has been increasingly used as the ultimate sphincter-preserving procedure in extremely low rectal cancer. The most critical complication of this technique is anastomotic leakage. The incidence rate of anastomotic leakage after ISR has been reported to range from 5.1% to 20%.

**AIM**

To investigate risk factors for anastomotic leakage after ISR based on clinicopathological variables and pelvimetry.

**METHODS**

This study was conducted at Department of Colorectal Surgery, Japanese Red Cross Medical Center, Tokyo, Japan, with a total of 117 patients. We enrolled 117 patients with extremely low rectal cancer who underwent laparotomic and laparoscopic ISRs at our hospital. We conducted retrospective univariate and

informed consent to the study because the analysis used anonymous clinical data that were obtained after each patient agreed to treatment by written consent.

**Conflict-of-interest statement:** No conflict of interest.

**Data sharing statement:** No additional data are available.

**STROBE statement:** The manuscript was revised according to the STROBE Statement.

**Open-Access:** This article is an open-access article that was selected by an in-house editor and fully peer-reviewed by external reviewers. It is distributed in accordance with the Creative Commons Attribution NonCommercial (CC BY-NC 4.0) license, which permits others to distribute, remix, adapt, build upon this work non-commercially, and license their derivative works on different terms, provided the original work is properly cited and the use is non-commercial. See: <http://creativecommons.org/licenses/by-nc/4.0/>

**Manuscript source:** Unsolicited manuscript

**Received:** June 19, 2020

**Peer-review started:** June 19, 2020

**First decision:** July 30, 2020

**Revised:** August 12, 2020

**Accepted:** September 14, 2020

**Article in press:** September 14, 2020

**Published online:** October 27, 2020

**P-Reviewer:** Fakhr I, Vignali A, Zhao WT

**S-Editor:** Wang JL

**L-Editor:** Filipodia

**P-Editor:** Li JH



multivariate regression analyses on 33 items to elucidate the risk factors for anastomotic leakage after ISR. Pelvic dimensions were measured using three-dimensional reconstruction of computed tomography images. The optimal cutoff value of the pelvic inlet plane area that predicts anastomotic leakage was determined using a receiver operating characteristic (ROC) curve.

## RESULTS

We observed anastomotic leakage in 10 (8.5%) of the 117 patients. In the multivariate analysis, we identified high body mass index (odds ratio 1.674; 95% confidence interval: 1.087-2.58;  $P = 0.019$ ) and smaller pelvic inlet plane area (odds ratio 0.998; 95% confidence interval: 0.997-0.999;  $P = 0.012$ ) as statistically significant risk factors for anastomotic leakage. According to the receiver operating characteristic curves, the optimal cutoff value of the pelvic inlet plane area was 10074 mm<sup>2</sup>. Narrow pelvic inlet plane area ( $\leq 10074$  mm<sup>2</sup>) predicted anastomotic leakage with a sensitivity of 90%, a specificity of 85.9%, and an accuracy of 86.3%.

## CONCLUSION

Narrow pelvic inlet and obesity were independent risk factors for anastomotic leakage after ISR. Anastomotic leakage after ISR may be predicted from a narrow pelvic inlet plane area ( $\leq 10074$  mm<sup>2</sup>).

**Key Words:** Intersphincteric resection; Anastomotic leakage; Pelvimetry; Pelvic dimensions; Pelvic inlet plane area; Rectal cancer

©The Author(s) 2020. Published by Baishideng Publishing Group Inc. All rights reserved.

**Core Tip:** Intersphincteric resection (ISR) is the ultimate sphincter-preserving procedure in extremely low rectal cancer. We investigated risk factors for anastomotic leakage after ISR based on clinicopathological variables and pelvimetry. Narrow pelvic inlet and obesity were independent risk factors for anastomotic leakage after ISR. Anastomotic leakage after ISR may be predicted from a narrow pelvic inlet plane area ( $\leq 10074$  mm<sup>2</sup>).

**Citation:** Toyoshima A, Nishizawa T, Sunami E, Akai R, Amano T, Yamashita A, Sasaki S, Endo T, Moriya Y, Toyoshima O. Narrow pelvic inlet plane area and obesity as risk factors for anastomotic leakage after intersphincteric resection. *World J Gastrointest Surg* 2020; 12(10): 425-434

**URL:** <https://www.wjgnet.com/1948-9366/full/v12/i10/425.htm>

**DOI:** <https://dx.doi.org/10.4240/wjgs.v12.i10.425>

## INTRODUCTION

Since Schiessel *et al*<sup>[1]</sup> first introduced intersphincteric resection (ISR) in 1994, the procedure has been increasingly accepted as the ultimate sphincter-preserving procedure in extremely low rectal cancer. ISR preserves the natural anus and avoids permanent colostomy. However, ISR is performed in the deep and funnel-shaped pelvic cavity, where access and visualization of the narrow pelvis is difficult<sup>[2,3]</sup>. Anastomotic leakage is the most critical complication that can cause reduced function or narrowing of the anal sphincter, possibly warranting a permanent colostomy<sup>[4-6]</sup>. According to a report from a committee (chaired by N Saito) sponsored by the Ministry of Health, Labour and Welfare of Japan, anastomotic leakage occurred in 23 (10.2%) of 225 patients after ISR<sup>[7]</sup>. The incidence rate of anastomotic leakage after ISR has been reported to range from 5.1% to 20%<sup>[8-10]</sup>.

Akasu *et al*<sup>[11]</sup> have reported on the risk factors for anastomotic leakage after ISR but have not analyzed pelvic size. Pelvic anatomy is a determinant factor of rectal dissection, as the narrow pelvic cavity and bony structures surrounding the rectum may hinder dissection maneuvers<sup>[12]</sup>. Pelvimetry is famous for its use in predicting

obstetric risk. In this study, we used pelvimetry to measure the inlet and outlet plane areas, particularly pelvic dimensions, to investigate risk factors for anastomotic leakage after ISR.

## MATERIALS AND METHODS

### Ethics

This retrospective study was approved by the ethics review board of the Japanese Red Cross Medical Center on July 31, 2019.

### Subjects

This study included subjects who underwent laparotomic and laparoscopic ISR as treatment for extremely low rectal adenocarcinoma with inferior margins less than 5 cm from the anal verge at the Japanese Red Cross Medical Center between 2005 and 2019. The spread of the rectal cancer was quantified in accordance with the clinical tumor-node-metastasis (TNM) classification (8<sup>th</sup> edition)<sup>[13]</sup>. Liver metastases were detected in all patients with stage IV cancer. The patients with peritoneal metastasis, multivisceral resection, gastrointestinal stromal tumor, and carcinoid were excluded.

Our indications for ISR included: (1) An inferior tumor margin less than 5 cm from the anal verge; (2) A moderate- to well-differentiated adenocarcinoma; (3) Local spread restricted to the internal sphincter without involvement of striated muscle; (4) The presence of some amount of T4 tumor (vaginal invasion); (5) Patients with resectable metastases to the liver or lungs; and (6) Normal sphincter function.

### Surgical procedure

The surgical procedure was performed in accordance with the method by Schiessel *et al*<sup>[1]</sup>. Laparotomy was performed with a small incision below the umbilicus, considering minimally invasive surgery. Under either laparotomy or laparoscopy, the inferior mesenteric artery (IMA) root was generally preserved, and the superior rectal artery was severed at the branching site of the left colic artery (LCA) or first branch of the sigmoid colic artery (SCA). When the IMA root was preserved, the lymph node around IMA root was separately resected to improve the curability. If tension was present at the anastomotic site or the color of the colon indicated an inadequate blood supply, the IMA was severed at the root and splenic flexure was mobilized. The rectum was divided transanally, removing a part or the entirety of the internal sphincter. Reconstruction was performed with a hand-sewn coloanal anastomosis from the anus. A closed suction drain was inserted in the left side of the pelvis and brought out at the lower angle of the wound. In some cases, an anal bougie (transanal drain) was inserted. Anastomotic leakage occurred in the second patient; thus, in all the subsequent patients, we constructed a covering stoma. The diverting stoma was closed 3-6 mo after surgery. Before the closure, we performed colonoscopy, contrast enema radiography, or computed tomography (CT). CT was performed each time there was a complication. The operations were performed by 3 staff surgeons (A, B, and C).

### Outcomes

Anastomotic leakage was defined as the presence of an anastomosis fistula during the first postoperative endoscopy or gastrografenema. In addition, anastomotic leakages were classified into three categories according to the clinical management by Rahbari *et al*<sup>[14]</sup> as follows: Grade A requires no active therapeutic intervention; Grade B, an active therapeutic intervention without operation; and Grade C, re-laparotomy.

We conducted retrospective univariate and multivariate regression analyses on 33 items to elucidate the risk factors for anastomotic leakage after ISR. These items were categorized into three groups as follows: Surgery, tumor, and patient related. The surgery-related factors were operation type (laparotomy or laparoscopic surgery), circumferential resection margin (CRM +/-), site of IMA ligature (IMA/LCA or SCA), splenic flexure mobilization (with/without), construction of a diverting stoma (with/without), insertion of an anal bougie (with/without), blood loss, transfusion (with/without)<sup>[15]</sup>, surgeon (A, B, and C), surgical duration, and curability (A, B, or C). Tumor-related factors were tumor size, distance from the anal verge to the inferior margin of the tumor, patient categorization as clinical TNM classification, preoperative radiotherapy (with/without), and neoadjuvant chemotherapy (with/without). The patient related factors were age, sex, body mass index (BMI), American Society of



Anesthesiologists Physical Status (ASA-PS; I, II, or III), serum total protein level, hemoglobin level, prognostic nutritional index<sup>[7]</sup>, diabetes (hemoglobin A1c  $\geq$  5.8 g/dL), and nine pelvimetry measurements.

### Pelvimetry

We used the Synapse Vincent magnifying viewer (Fujifilm Medical Co., Ltd., Tokyo, Japan) to convert CT images into three-dimensional images. By using this imaging system, the anteroposterior (AP) diameter, transverse diameter, and total area were measured at the pelvic inlet and outlet. The length of the pubic symphysis and distance from the sacral promontory to the coccyx were measured to determine the anterior and posterior depths of the pelvis (Figure 1A-C). The lumbosacral (tortuosity) angle at the sacral promontory was also measured (Figure 1D).

### Statistical analyses

Differences between the leakage and non-leakage groups were detected using the Welch's *t*-test or Student *t*-test for continuous data. The  $\chi^2$  test was used for categorical secondary outcomes. The predictors found to be associated with anastomotic leakage in the univariate analysis ( $P < 0.05$ ) were analyzed by subsequent multiple logistic regression method to identify independent factors. If both diameter and area were statistically significant, the area was preferentially used in the multivariate analysis. The optimal cutoff value of the pelvic inlet plane area for predicting anastomotic leakage was determined using the receiver operating characteristic curve. *P* values of  $< 0.05$  were considered statistically significant in this study.

## RESULTS

We enrolled 117 patients [89 men; mean age, 61.3 years (range, 26-86 years)]. We observed anastomotic leakage in 10 (8.5%) of the 117 patients as follows: Grade A in 3 patients (30%), grade B in 5 (50%), and grade C in 2 (20%). In the 3 cases with grade A leakage, it was cured by conservative treatment such as antibiotic treatment. In the 5 patients with grade B leakage, the fistulae were closed using an alpha-cyanoacrylate monomer (Aron Alpha A Sankyo, Toagosei Co., Ltd., Tokyo, Japan), a tissue adhesive. Two patients with grade C leakage needed re-operation. One patient underwent permanent colostomy, and the other underwent nephrostomy for vesicorectal fistula. Closure of the diverting stoma was possible in 8 (80%) of the 10 patients. No operative deaths occurred.

Table 1 shows the correlation between the postoperative anastomotic leakage and clinicopathological variables. The univariate analysis revealed a statistically significant relationship between anastomotic leakage and higher BMI, smaller pelvic inlet area, shorter AP diameter of the inlet plane, shorter transverse diameter of the inlet plane, shorter AP diameter of the outlet plane, longer pubic symphysis, greater lumbosacral angle, and larger amount of bleeding.

In the multivariate analysis, we identified high BMI (odds ratio 1.674; 95% confidence interval: 1.087-2.58;  $P = 0.019$ ) and smaller pelvic inlet plane area (odds ratio 0.998; 95% confidence interval: 0.997-0.999;  $P = 0.012$ ) as statistically significant risk factors for anastomotic leakage (Table 2).

According to the receiver operating characteristic curves, the optimal cutoff value of the pelvic inlet plane area was 10074 mm<sup>2</sup> (Figure 2). Narrow pelvic inlet area ( $\leq 10074$  mm<sup>2</sup>) predicted anastomotic leakage with a sensitivity of 90%, a specificity of 85.9%, and an accuracy of 86.3%. The positive predictive value was 37.5%, and the negative predictive value was 98.9%.

## DISCUSSION

Narrow pelvic inlet and obesity were independent risk factors for anastomotic leakage after ISR. This is the first report of increased anastomotic leakage due to narrow pelvic inlet. Narrow pelvic inlet hinders the surgical procedures with the approach from the abdominal cavity, and the difficulty might lead to anastomotic leakage.

Rullier *et al*<sup>[16]</sup> demonstrated that male sex and obesity were independent risk factors for anastomotic leakage after low anterior resection (LAR). The male pelvis is narrower than the female pelvis; thus, male sex as a risk factor for anastomotic leakage might be due to the narrower pelvis in males.

**Table 1 Univariate analyses of clinicopathological variables related to anastomotic leakage after intersphincteric resection**

	No leakage	Leakage	P value
Patients number	107	10	
Age in yr	61.1 ± 12.7	64.3 ± 9.9	0.436
Male sex, <i>n</i> (%)	80 (74.8)	9 (90)	0.489
Body mass index	22.4 ± 3.3	25.6 ± 2.7	0.004
Anesthesiologists physical status			0.569
1	29	3	
2	75	7	
3	3	0	
Serum total protein level, g/dL	6.9 ± 0.5	7.1 ± 0.5	0.351
Blood hemoglobin level, g/dL	13.5 ± 1.8	14.6 ± 1.4	0.055
Prognostic nutritional index	49.7 ± 6.3	52.4 ± 4.9	0.205
Diabetes mellitus			0.326
No	93	7	
Yes	14	3	
Inlet plane: Antero-posterior diameter, mm	110.3 ± 10.8	100 ± 7.9	0.002
Inlet plane: Transverse diameter, mm	156.3 ± 35.4	136.4 ± 17.7	0.008
Area of the inlet plane, mm <sup>2</sup>	11330 ± 1279	9428 ± 636.1	< 0.001
Outlet plane: Antero-posterior diameter, mm	97.8 ± 8.9	90.6 ± 10.4	0.018
Outlet plane: Transverse diameter, mm	103.4 ± 10.1	102.8 ± 4.4	0.739
Area of the outlet plane, mm <sup>2</sup>	9572 ± 1501	9323 ± 999	0.487
Length of the pubic symphysis, mm	41.9 ± 5.6	45.7 ± 5.2	0.044
Distance from the sacral promontory to the coccyx, mm	125.5 ± 13.3	131.3 ± 14.8	0.193
Tortuosity angle	131.7 ± 8.7	140.4 ± 11.4	0.004
Tumors			
Tumor size, mm	41.3 ± 25.2	33.3 ± 19.7	0.335
Distance from the anal verge, mm	16.8 ± 19.2	20.4 ± 14.6	0.563
TNM stage			0.056
0	3	1	
I	35	6	
II	23	1	
III	34	1	
IV	12	1	
Preoperative radiotherapy			0.972
No	90	9	
Yes	17	1	
Neoadjuvant chemotherapy			0.341
No	89	10	
Yes	18	0	
Surgery			0.341
Laparotomy	89	10	
Laparoscopic surgery	18	0	



Circumferential resection margin			0.809
No	100	9	
Yes	7	1	
Ligated site of the artery			0.583
Inferior mesenteric artery	5	0	
Left colonic artery	41	3	
Sigmoid colon artery	61	7	
Mobilization of the splenic flexure			0.738
No	99	9	
Yes	8	1	
Diverting stoma			0.401
No	1	1	
Yes	106	9	
Anal bougie			0.341
No	89	10	
Yes	18	0	
Bleeding amount, mL	645 ± 709	1380 ± 1166	0.004
Blood transfusion, mL	8 ± 60	292 ± 621	0.181
Operator			0.418
X	87	9	
T	9	1	
S	11	0	
Operation time in min	367 ± 156	387 ± 167	0.698
Curativity			0.54
A	86	9	
B	8	0	
C	13	1	

TNM: Tumor-node-metastasis.

**Table 2 Multivariate analyses of clinicopathological variables related to anastomotic leakage after intersphincteric resection**

Variables	Multivariate analysis		
	Odds ratio	95%CI	P value
Body mass index	1.674	1.087-2.58	0.019
Area of the inlet plane	0.998	0.997-0.999	0.012
Outlet plane: Antero-posterior diameter	0.905	0.811-1.008	0.07
Length of the pubic symphysis	1.125	0.883-1.435	0.341
Tortuosity angle	1.049	0.941-1.17	0.39
Bleeding amount	1.001	0.999-1.003	0.144

CI: Confidence interval.

Zhou *et al*<sup>[17]</sup> evaluated the technical difficulties in LAR or abdominoperineal resection using three-dimensional reconstruction of CT images. Their multivariate analyses revealed that the AP diameter of the pelvic inlet, AP diameter of the pelvic outlet, and height of the pubic symphysis were factors that affect operative time. These results indicate that narrower and deeper pelvises could increase operating times.

Zur Hausen *et al*<sup>[18]</sup> also evaluated the clinical outcomes in LAR or abdominoperineal resection using CT pelvimetry. A shorter AP pelvic inlet diameter was associated with a higher rate of incomplete mesorectal excision. However, the number of cases were relatively small ( $n = 74$ ), and the study failed to show the association between pelvic diameters and incidence of anastomotic leakage. The authors concluded that preoperative pelvimetry may help identify difficult pelvic dissections preoperatively.

The present study shows that narrow pelvic inlet significantly increased the incidence of anastomotic leakage after ISR. Furthermore, narrow pelvic inlet area ( $\leq 10074 \text{ mm}^2$ ) predicted anastomotic leakage with a sensitivity of 90%, a specificity of 85.9%, and an accuracy of 86.3%. Identification of patients at high risk for anastomotic leakage may allow for the selective use of the indocyanine green fluorescence method or more-advanced access methods such as transanal total mesorectal excision or robotic-assisted laparoscopic surgery<sup>[19]</sup> for improving surgical outcomes.

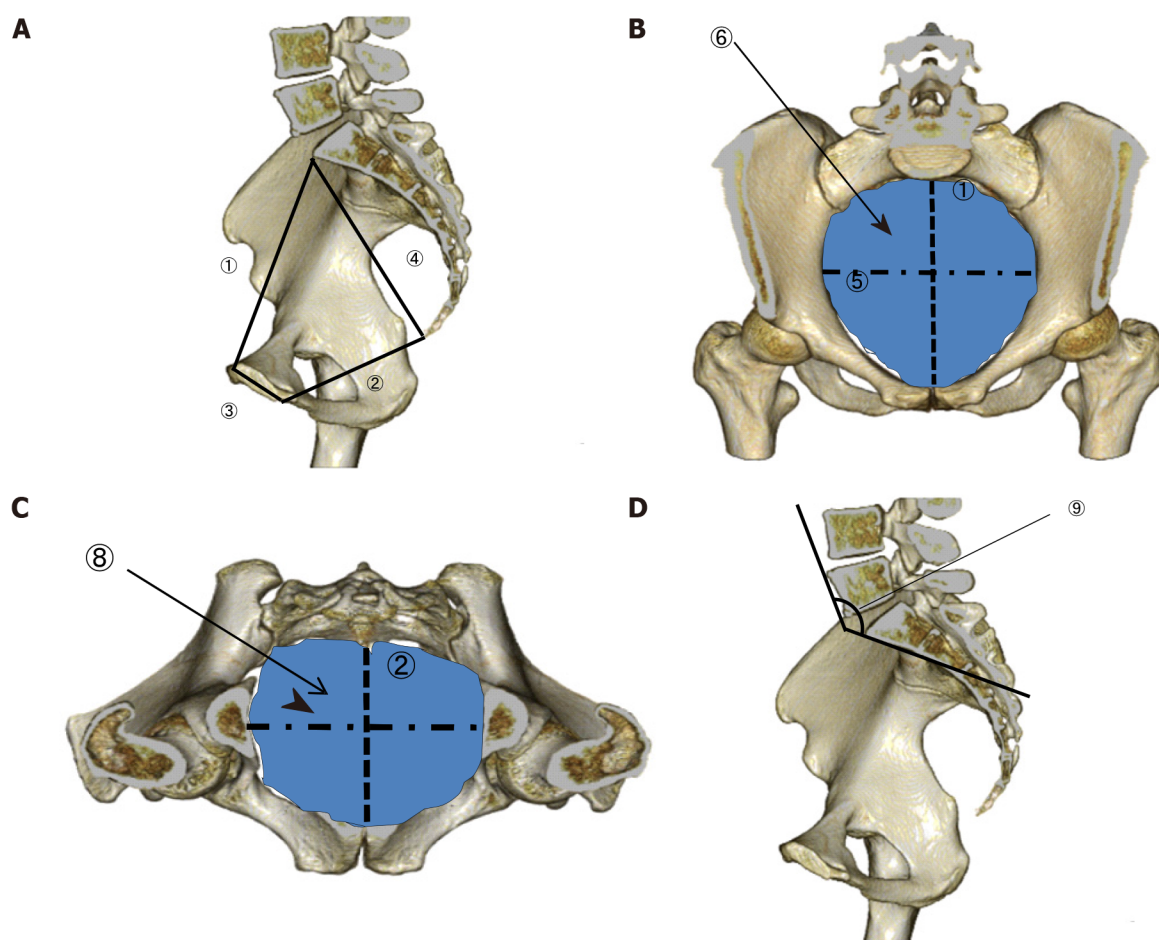
In our study, obesity was also an independent risk factor for anastomotic leakage after ISR. Surgery for obese patients is generally more difficult because obesity contributes to inadequate exposure of the surgical field, which results in accidental injury. Yang *et al*<sup>[20]</sup> and Yamamoto *et al*<sup>[21]</sup> reported that obesity was a risk factor for anastomotic leakage after LAR. Rullier *et al*<sup>[16]</sup> reported that obesity was a risk factor for anastomotic leakage after ISR. A protective stoma is, therefore, suitable after ISR, particularly in obese patients. The first limitation of our study is that it was conducted within a single specialized institution. Second, this study was consecutive but retrospective. Third, the number of laparoscopic cases was small, and the effect of laparoscopic surgery was not determined. A follow-up study should be performed to confirm and clarify the characteristics of anastomotic leakage after ISR including laparoscopic surgery.

---

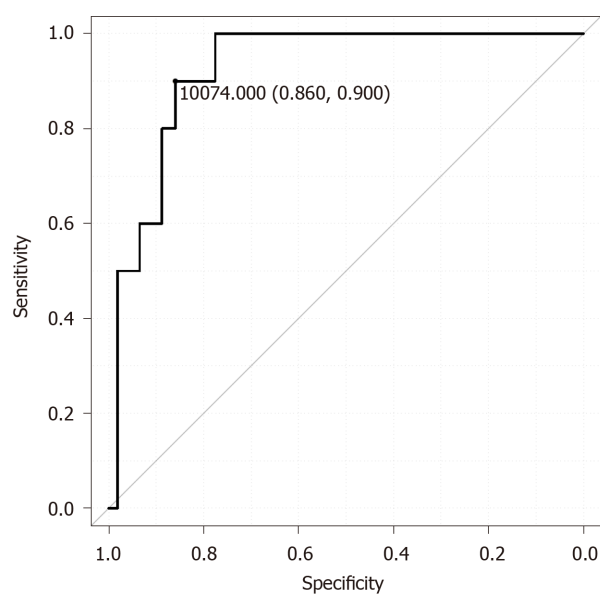
## CONCLUSION

---

In conclusion, narrow pelvic inlet and high BMI were associated with anastomotic leakage after ISR. Anastomotic leakage after ISR may be predicted from a narrow pelvic inlet plane area ( $\leq 10074 \text{ mm}^2$ ).



**Figure 1 Variables identified with three-dimensional pelvimetry.** A: Lateral view; B: pelvic inlet plane; C: Pelvic outlet plane; D: Lateral view. 1: Anteroposterior pelvic inlet diameter; 2: Anteroposterior pelvic outlet diameter; 3: Length of the pubic symphysis; 4: Distance from the sacral promontory to the coccyx; 5: Transverse pelvic inlet diameter; 6: Pelvic inlet area; 7: Transverse pelvic outlet diameter; 8: Pelvic outlet area; 9: Lumbosacral (tortuosity) angle at the sacral promontory.



**Figure 2 Receiver operating characteristic curve for predicting anastomotic leakage based on the pelvic inlet plane area.**

## ARTICLE HIGHLIGHTS

**Research background**

Intersphincteric resection (ISR) has been increasingly used as the ultimate sphincter-preserving procedure in extremely low rectal cancer.

**Research motivation**

Anastomotic leakage is the most critical complication that can cause reduced function or narrowing of the anal sphincter, possibly warranting a permanent colostomy.

**Research objectives**

This study investigated risk factors for anastomotic leakage after ISR based on clinicopathological variables and pelvimetry.

**Research methods**

We enrolled 117 patients with extremely low rectal cancer who underwent laparotomic and laparoscopic ISRs. Risk factors for anastomotic leakage after ISR that were analyzed using a multivariate analysis. Pelvic dimensions were measured using three-dimensional reconstruction of computed tomography images. The optimal cutoff value of the pelvic inlet plane area that predicts anastomotic leakage was determined using a receiver operating characteristic curve.

**Research results**

Higher body mass index and small pelvic inlet plane area were independently associated with anastomotic leakage after ISR. According to the receiver operating characteristic curves, the optimal cutoff value of the pelvic inlet plane area was 10074 mm<sup>2</sup>. Narrow pelvic inlet plane area ( $\leq 10074$  mm<sup>2</sup>) predicted anastomotic leakage with a sensitivity of 90%, a specificity of 85.9%, and an accuracy of 86.3%.

**Research conclusions**

Narrow pelvic inlet and obesity were independent risk factors for anastomotic leakage after ISR.

**Research perspectives**

A follow-up study should be performed to confirm and clarify the characteristics of anastomotic leakage after ISR including laparoscopic surgery.

## REFERENCES

- 1 Schiessel R, Karner-Hanusch J, Herbst F, Teleky B, Wunderlich M. Intersphincteric resection for low rectal tumours. *Br J Surg* 1994; **81**: 1376-1378 [PMID: 7953423 DOI: 10.1002/bjs.1800810944]
- 2 Chin CC, Yeh CY, Huang WS, Wang JY. Clinical outcome of intersphincteric resection for ultra-low rectal cancer. *World J Gastroenterol* 2006; **12**: 640-643 [PMID: 16489683 DOI: 10.3748/wjg.v12.i4.640]
- 3 Dimitriou N, Michail O, Moris D, Griniatsos J. Low rectal cancer: Sphincter preserving techniques-selection of patients, techniques and outcomes. *World J Gastrointest Oncol* 2015; **7**: 55-70 [PMID: 26191350 DOI: 10.4251/wjgo.v7.i7.55]
- 4 Daams F, Wu Z, Lahaye MJ, Jeekel J, Lange JF. Prediction and diagnosis of colorectal anastomotic leakage: A systematic review of literature. *World J Gastrointest Surg* 2014; **6**: 14-26 [PMID: 24600507 DOI: 10.4240/wjgs.v6.i2.14]
- 5 Yamada K, Saiki Y, Takano S, Iwamoto K, Tanaka M, Fukunaga M, Noguchi T, Nakamura Y, Hisano S, Fukami K, Kuwahara D, Tsuji Y, Takano M, Usuku K, Ikeda T, Sugihara K. Long-term results of intersphincteric resection for low rectal cancer in Japan. *Surg Today* 2019; **49**: 275-285 [PMID: 30604217 DOI: 10.1007/s00595-018-1754-4]
- 6 Olavarria OA, Kress RL, Shah SK, Agarwal AK. Novel technique for anastomotic salvage using transanal minimally invasive surgery: A case report. *World J Gastrointest Surg* 2019; **11**: 271-278 [PMID: 31171958 DOI: 10.4240/wjgs.v11.i5.271]
- 7 Saito N, Moriya Y, Shirouzu K, Maeda K, Mochizuki H, Koda K, Hirai T, Sugito M, Ito M, Kobayashi A. Intersphincteric resection in patients with very low rectal cancer: a review of the Japanese experience. *Dis Colon Rectum* 2006; **49**: S13-S22 [PMID: 17106809 DOI: 10.1007/s10350-006-0598-y]
- 8 Schiessel R, Novi G, Holzer B, Rosen HR, Renner K, Hölbling N, Feil W, Urban M. Technique and long-term results of intersphincteric resection for low rectal cancer. *Dis Colon Rectum* 2005; **48**: 1858-1865; discussion 1865 [PMID: 16086223 DOI: 10.1007/s10350-005-0134-5]
- 9 Barisic G, Markovic V, Popovic M, Dimitrijevic I, Gavrilovic P, Krivokapic Z. Function after intersphincteric resection for low rectal cancer and its influence on quality of life. *Colorectal Dis* 2011; **13**: 638-643 [PMID: 20184636 DOI: 10.1111/j.1463-1318.2010.02244.x]

- 10 Akasu T, Takawa M, Yamamoto S, Fujita S, Moriya Y. Incidence and patterns of recurrence after intersphincteric resection for very low rectal adenocarcinoma. *J Am Coll Surg* 2007; **205**: 642-647 [PMID: 17964439 DOI: 10.1016/j.jamcollsurg.2007.05.036]
- 11 Akasu T, Takawa M, Yamamoto S, Yamaguchi T, Fujita S, Moriya Y. Risk factors for anastomotic leakage following intersphincteric resection for very low rectal adenocarcinoma. *J Gastrointest Surg* 2010; **14**: 104-111 [PMID: 19841989 DOI: 10.1007/s11605-009-1067-4]
- 12 Targarona EM, Balague C, Pernas JC, Martinez C, Berindoague R, Gich I, Trias M. Can we predict immediate outcome after laparoscopic rectal surgery? *Ann Surg* 2008; **247**: 642-649 [PMID: 18362627 DOI: 10.1097/SLA.0b013e3181612c6a]
- 13 Fisseler-Eckhoff A. [New TNM classification of malignant lung tumors 2009 from a pathology perspective]. *Pathologie* 2009; **30** Suppl 2: 193-199 [PMID: 19960300 DOI: 10.1007/s00292-009-1195-3]
- 14 Rahbari NN, Weitz J, Hohenberger W, Heald RJ, Moran B, Ulrich A, Holm T, Wong WD, Tiet E, Moriya Y, Laurberg S, den Dulk M, van de Velde C, Büchler MW. Definition and grading of anastomotic leakage following anterior resection of the rectum: a proposal by the International Study Group of Rectal Cancer. *Surgery* 2010; **147**: 339-351 [PMID: 20004450 DOI: 10.1016/j.surg.2009.10.012]
- 15 Rutegård M, Rutegård J. Anastomotic leakage in rectal cancer surgery: The role of blood perfusion. *World J Gastrointest Surg* 2015; **7**: 289-292 [PMID: 26649151 DOI: 10.4240/wjgs.v7.i11.289]
- 16 Rullier E, Laurent C, Garrelon JL, Michel P, Saric J, Parneix M. Risk factors for anastomotic leakage after resection of rectal cancer. *Br J Surg* 1998; **85**: 355-358 [PMID: 9529492 DOI: 10.1046/j.1365-2168.1998.00615.x]
- 17 Zhou XC, Su M, Hu KQ, Su YF, Ye YH, Huang CQ, Yu ZL, Li XY, Zhou H, Ni YZ, Jiang YI, Lou Z. CT pelvimetry and clinicopathological parameters in evaluation of the technical difficulties in performing open rectal surgery for mid-low rectal cancer. *Oncol Lett* 2016; **11**: 31-38 [PMID: 26870163 DOI: 10.3892/ol.2015.3827]
- 18 Zur Hausen G, Gröne J, Kaufmann D, Niehues SM, Aschenbrenner K, Stroux A, Hamm B, Kreis ME, Lauscher JC. Influence of pelvic volume on surgical outcome after low anterior resection for rectal cancer. *Int J Colorectal Dis* 2017; **32**: 1125-1135 [PMID: 28315018 DOI: 10.1007/s00384-017-2793-9]
- 19 Yamaguchi T, Kinugasa Y, Shiomi A, Kagawa H, Yamakawa Y, Furutani A, Manabe S, Yamaoka Y, Hino H. Oncological outcomes of robotic-assisted laparoscopic versus open lateral lymph node dissection for locally advanced low rectal cancer. *Surg Endosc* 2018; **32**: 4498-4505 [PMID: 29721748 DOI: 10.1007/s00464-018-6197-x]
- 20 Yang L, Huang XE, Zhou JN. Risk assessment on anastomotic leakage after rectal cancer surgery: an analysis of 753 patients. *Asian Pac J Cancer Prev* 2013; **14**: 4447-4453 [PMID: 23992018 DOI: 10.7314/apjcp.2013.14.7.4447]
- 21 Yamamoto S, Fujita S, Akasu T, Inada R, Moriya Y, Yamamoto S. Risk factors for anastomotic leakage after laparoscopic surgery for rectal cancer using a stapling technique. *Surg Laparosc Endosc Percutan Tech* 2012; **22**: 239-243 [PMID: 22678320 DOI: 10.1097/SLE.0b013e31824fbb56]



Published by **Baishideng Publishing Group Inc**  
7041 Koll Center Parkway, Suite 160, Pleasanton, CA 94566, USA

**Telephone:** +1-925-3991568

**E-mail:** [bpgoffice@wjgnet.com](mailto:bpgoffice@wjgnet.com)

**Help Desk:** <https://www.f6publishing.com/helpdesk>

<https://www.wjgnet.com>

