

Occlusion of the anterior cerebral artery after head trauma

Wellingson Silva Paiva, Almir Ferreira de Andrade, Matheus Schmidt Soares, Robson Luis Amorim, Eberval Gadelha Figueiredo, Manoel Jacobsen Teixeira

Wellingson Silva Paiva, Almir Ferreira de Andrade, Matheus Schmidt Soares, Robson Luis Amorim, Eberval Gadelha Figueiredo, Manoel Jacobsen Teixeira, Division of Neurological Surgery, Hospital Das Clinicas University of Sao Paulo Medical School, Sao Paulo 05406000, Brazil

Author contributions: Paiva WS, de Andrade AF, Soares MS and Amorim RL had a substantial contributions to conception and design, acquisition and interpretation of data; Figueiredo EG and Teixeira MJ worked in drafting the article and revising it critically for important intellectual content.

Correspondence to: Wellingson Silva Paiva, MD, FRSM, Division of Neurological Surgery, Hospital Das Clinicas University of Sao Paulo Medical School, Eneas Aguiar Street N 255, Sao Paulo 05406000, Brazil. wellingsonpaiva@yahoo.com.br

Telephone: +55-11-25486900 Fax: +55-11-25486906

Received: February 2, 2011 Revised: April 1, 2011

Accepted: April 8, 2011

Published online: May 28, 2013

Abstract

Intracranial arterial occlusion is rarely encountered in association with head injury. Only six cases of traumatic occlusion of the anterior cerebral artery (ACA) have previously been reported. In this paper, the authors describe a case of a posttraumatic occlusion of ACA. A 35-year-old male presented to the emergency room with severe head injury. Computed tomography (CT) scan displayed diffuse brain swelling with multiple skull fractures. Follow up CT scan showed extensive cerebral infarction in the territory of ACA. The patient underwent CT angiography that demonstrated occlusion of the ACA by a fracture of the anterior fossa. He died after 3 d. ACA traumatic occlusion is a rare condition, with poor prognosis. In this case, fracture was responsible for dissection and direct obstruction of the artery.

© 2013 Baishideng. All rights reserved.

Key words: Anterior cerebral artery; Brain vascular trauma; Arterial occlusion; Computed tomography; Neurological diagnostic techniques; Brain injury

Paiva WS, de Andrade AF, Soares MS, Amorim RL, Figueiredo EG, Teixeira MJ. Occlusion of the anterior cerebral artery after head trauma. *World J Radiol* 2013; 5(5): 226-228 Available from: URL: <http://www.wjgnet.com/1949-8470/full/v5/i5/226.htm> DOI: <http://dx.doi.org/10.4329/wjr.v5.i5.226>

INTRODUCTION

Intracranial arterial occlusion is rare associated with head injury^[1,2]. The incidence of this condition with cerebral ischemia in the literature range from 0.2% to 1.6%^[3,4]. Most injuries occur in the internal carotid artery, followed by the middle cerebral artery and the vertebrobasilar vessels^[1,5]. Occlusion of the anterior cerebral artery (ACA) from head trauma is extremely uncommon. Six cases of traumatic occlusion of the ACA have been reported in literature^[1-4,6,7]. In this paper the authors describe a case of severe head injury associated with traumatic occlusion of the ACA.

CASE REPORT

A 35-year-old male was admitted to the emergency room following a motorcycle accident. On admission his Glasgow Coma Score was 4, and he presented isochoric pupils, without systemic lesion. Immediate head multislice computed tomography (CT) scan was performed and showed diffuse brain swelling with multiple skull fractures, included one in the skull base (Figure 1).

The patient developed mydriatic pupils after 24 h and an extensive cerebral infarction in the territory of ACA was found in the CT scan (Figure 2). Patient underwent CT angiography that demonstrated occlusion of the ACA caused by a fracture of the anterior fossa, with partial obstruction of the right and left branches, indicating a traumatic occlusion (Figure 3). Patient deceased after 3 d despite of medical management and intracranial pressure monitoring.

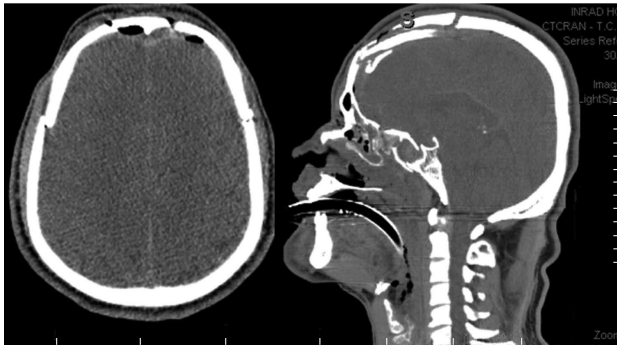


Figure 1 Computed tomography scan showed diffuse brain swelling with multiple skull fractures, including one in the anterior fossa.

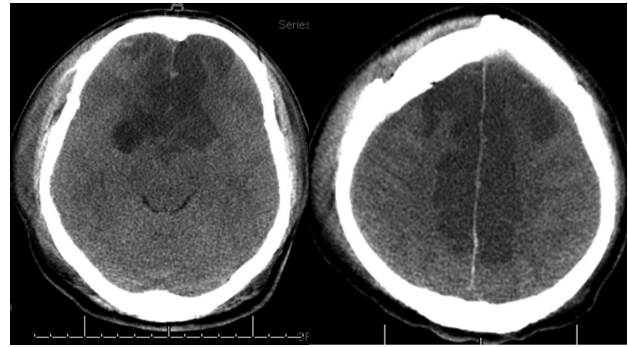


Figure 2 Follow up computed tomography scan showed extensive cerebral infarction in the territory of anterior cerebral artery.

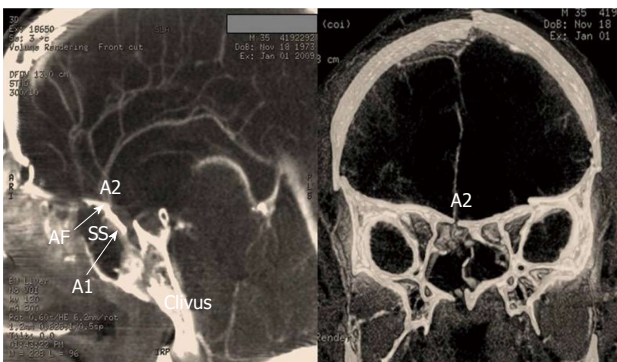


Figure 3 Multislice computed tomography angiography showed occlusion of the anterior cerebral artery adjacent to a fracture in the anterior fossa. AF: Anterior Fossa; A1: First segment of anterior cerebral artery; A2: Second segment of anterior cerebral artery; SS: Sphenoid sinus.

DISCUSSION

Fatal ACA infarct was encountered in half of the reported cases. Only one patient survived without neurological deficits. All patients except one sustained their injury in a road accident. In our patients a severe trauma following motorcycle accident indicates a high energy trauma mechanism.

The initial diagnosis is often delayed because of the low incidence of traumatic ACA occlusion^[1]. Lucid intervals are common in patients with traumatic arterial obstruction^[3,6]. However in this case, the authors believe that axonal diffuse injury associated with arterial lesion were responsible for the coma, with no lucid interval.

Outcome is generally poor. Three patients died, and one remained in persistent vegetative state. Mechanisms such as direct injury, dissecting aneurysm, thrombosis, and embolism have been reported as cause for intracranial vessel occlusion in association with head injury^[1,3]. In this case, occlusion probably was caused by dissection and direct obstruction of artery by fracture. We believe that the extensive line of fracture at the base of the anterior fossa and sella resulted in partial traumatic occlusion by clamping of both anterior cerebral arteries in A1 and A2 segment. The ACA and the terminal branch of internal carotid artery, its first segment, designated A1 presents length ranging from 10 to 20 mm, an aver-

age of 15 mm^[8]. This segment goes on the optic chiasm in 17% and on the nerve in 83%, while the A2 segment goes hand in hand in 26%^[8], as we believe occurred in our patient, which allowed bilateral compression with elevation of bone the fracture and thus clamping these vessels.

Vasospasm is another factor in the pathogenesis of intracranial artery occlusion^[9]. Spasm following traumatic subarachnoid hemorrhage is most common in the distal portion of the internal carotid artery and the proximal portion of the middle cerebral artery and ACA^[10,11]. The reported incidence of intracranial arterial spasm following moderate to severe head injury range from 5% to 10%^[10]. In this patient, presence of early hypodensity on CT skull do not favor spasm as the primary mechanism, nonetheless one may not totally exclude it, mainly in the terminal branches of the anterior cerebral arteries.

REFERENCES

- 1 Amagasa M, Sato S, Shimizu Y, Otabe K, Onuma T. [Post-traumatic occlusion of the anterior cerebral artery]. *No Shinkei Geka* 1988; **16**: 103-107 [PMID: 3362294]
- 2 Dratz HM, Woodhall B. Traumatic dissecting aneurysm of left internal carotid, anterior cerebral and middle cerebral arteries. *J Neuropathol Exp Neurol* 1947; **6**: 286-291 [PMID: 20254509 DOI: 10.1097/00005072-194707000-00009]
- 3 Ishibashi A, Kubota Y, Yokokura Y, Soejima Y, Hiratsuka T. Traumatic occlusion of the anterior cerebral artery: case report. *Neurol Med Chir (Tokyo)* 1995; **35**: 882-885 [DOI: 10.2176/nmc.35.882]
- 4 Iwamoto Y, Fujimoto M, Nakagawa Y, Yamamoto K. Study of the traumatic cerebral infarct on. *Kyoto Furitsu Ikadaigaku Zasshi* 1993; **102**: 965-971
- 5 De Araujo JC, De Moraes GP. [Traumatic occlusion of the middle cerebral artery: report of a case]. *Arq Neuropsiquiatr* 1984; **42**: 50-54 [PMID: 6732535]
- 6 Levin W. Vascular lesions in head injuries. *Brit J Surg* 1968; **55**: 321-331 [DOI: 10.1002/bjs.1800550502]
- 7 Nelson JW. Dissecting subintimal hematomas of the intracranial arteries: report of a case. *J Am Osteopath Assoc* 1968; **67**: 512-527 [PMID: 5183587]
- 8 Perlmutter D, Rhoton AL. Microsurgical anatomy of the anterior cerebral-anterior communicating-recurrent artery complex. *J Neurosurg* 1976; **45**: 259-272 [PMID: 948013 DOI: 10.3171/jns.1976.45.3.0259]
- 9 Mobbs RJ, Chandran KN. Traumatic middle cerebral artery occlusion: case report and review of pathogenesis. *Neurol India* 2001; **49**: 158-161 [PMID: 11447436]

- 10 **Yamada K**, Harada M, Hasegawa S, Ushio Y. Delayed post-traumatic middle cerebral artery vasospasm demonstrated by magnetic resonance angiography: case report. *Neurosurgery* 1998; **43**: 153-156 [PMID: 9657203 DOI: 10.1097/00006123-199807000-00101]
- 11 **Suwanwela C**, Suwanwela N. Intracranial arterial narrowing and spasm in acute head injury. *J Neurosurg* 1972; **36**: 314-323 [PMID: 5059970 DOI: 10.3171/jns.1972.36.3.0314]

P- Reviewer Luo CB **S- Editor** Cheng JX
L- Editor A **E- Editor** Xiong L

