

# World Journal of *Clinical Cases*

*World J Clin Cases* 2024 January 26; 12(3): 466-670



## Contents

Thrice Monthly Volume 12 Number 3 January 26, 2024

## EDITORIAL

- 466 Is medical management useful in Moyamoya disease?  
*Muengtaweepongsa S, Panpattanakul V*
- 474 Metabologenomics and network pharmacology to understand the molecular mechanism of cancer research  
*Tutar Y*

## ORIGINAL ARTICLE

## Case Control Study

- 479 Significance of oxidative stress and antioxidant capacity tests as biomarkers of premature ovarian insufficiency: A case control study  
*Kakinuma K, Kakinuma T*
- 488 Colorectal resections for malignancy: A pilot study comparing conventional *vs* freehand robot-assisted laparoscopic colectomy  
*Cawich SO, Plummer JM, Griffith S, Naraynsingh V*

## Retrospective Study

- 495 Ultrasound diagnosis of congenital Morgagni hernias: Ten years of experience at two Chinese centers  
*Shi HQ, Chen WJ, Yin Q, Zhang XH*

## Observational Study

- 503 Genetic investigation of the ubiquitin-protein ligase E3A gene as putative target in Angelman syndrome  
*Manoubi W, Mahdouani M, Hmida D, Kdissa A, Rouissi A, Turki I, Gueddiche N, Soyah N, Saad A, Bouwkamp C, Elgersma Y, Mougou-Zerelli S, Gribaa M*

## Prospective Study

- 517 Benefit in physical function and quality of life to nonsurgical treatment of varicose veins: Pilot study  
*Kim GM, Kim B, Jang M, Park JH, Bae M, Lee CW, Kim JW, Huh U*

## SYSTEMATIC REVIEWS

- 525 Emerging roles of microRNAs as diagnostics and potential therapeutic interest in type 2 diabetes mellitus  
*Shrivastav D, Singh DD*

## META-ANALYSIS

- 538 Impact of body mass index on adverse kidney events in diabetes mellitus patients: A systematic-review and meta-analysis  
*Wan JF, Chen Y, Yao TH, Wu YZ, Dai HZ*

## CASE REPORT

- 551 Epithelioid malignant peripheral nerve sheath tumor of the bladder and concomitant urothelial carcinoma: A case report  
*Ozden SB, Simsekoglu MF, Sertbudak I, Demirdag C, Gurses I*
- 560 Simultaneous type III congenital esophageal atresia and patent ductus arteriosus in a low-weight patient: A case report  
*Ma YY, Chen JR, Yang SW, Wang SY, Cao X, Wu J*
- 565 Marginal zone lymphoma with severe rashes: A case report  
*Bai SJ, Geng Y, Gao YN, Zhang CX, Mi Q, Zhang C, Yang JL, He SJ, Yan ZY, He JX*
- 575 Inetetamab combined with pyrotinib and chemotherapy in the treatment of breast cancer brain metastasis: A case report  
*Dou QQ, Sun TT, Wang GQ, Tong WB*
- 582 Adult rhabdomyosarcoma combined with acute myeloid leukemia: A case report  
*Zheng L, Zhang FJ*
- 587 Special electromyographic features in a child with paramyotonia congenita: A case report and review of literature  
*Yi H, Liu CX, Ye SX, Liu YL*
- 596 Removal of a guide-wire sliding into abdominal cavity *via* transgastric natural orifice transluminal endoscopic surgery: A case report  
*Chen SJ, Zhang DY, Lv YT, Bai FH*
- 601 Polyneuropathy, organomegaly, endocrinopathy, M-protein, skin changes syndrome with dilated cardiomyopathy: A case report  
*Li JR, Feng LY, Li JW, Liao Y, Liu FQ*
- 607 Ischemic colitis induced by a platelet-raising capsule: A case report  
*Wang CL, Si ZK, Liu GH, Chen C, Zhao H, Li L*
- 616 Brain abscess from oral microbiota approached by metagenomic next-generation sequencing: A case report and review of literature  
*Zhu XM, Dong CX, Xie L, Liu HX, Hu HQ*
- 623 Carrimycin in the treatment of acute promyelocytic leukemia combined with pulmonary tuberculosis: A case report  
*Yang FY, Shao L, Su J, Zhang ZM*
- 630 Rare esophageal carcinoma-primary adenoid cystic carcinoma of the esophagus: A case report  
*Geng LD, Li J, Yuan L, Du XB*
- 637 Early selective enteral feeding in treatment of acute pancreatitis: A case report  
*Kashintsev AA, Anisimov SV, Nadeeva A, Proutski V*

- 643** Pathological diagnosis and immunohistochemical analysis of giant retrosternal goiter in the elderly: A case report  
*Meng YC, Wu LS, Li N, Li HW, Zhao J, Yan J, Li XQ, Li P, Wei JQ*
- 650** Cerebral syphilitic gumma misdiagnosed as brain abscess: A case report  
*Mu LK, Cheng LF, Ye J, Zhao MY, Wang JL*
- 657** Primary anaplastic lymphoma kinase-positive large B-cell lymphoma of the left bulbar conjunctiva: A case report  
*Guo XH, Li CB, Cao HH, Yang GY*
- 665** Porocarcinoma in a palm reconstructed with a full thickness skin graft: A case report  
*Lim SB, Kwon KY, Kim H, Lim SY, Koh IC*



**ABOUT COVER**

Peer Reviewer of *World Journal of Clinical Cases*, Kazuhiro Katada, MD, PhD, Assistant Professor, Molecular Gastroenterology and Hepatology, Graduate School of Medical Science, Kyoto Prefectural University of Medicine, Kyoto 6028566, Japan. katada@koto.kpu-m.ac.jp

**AIMS AND SCOPE**

The primary aim of *World Journal of Clinical Cases* (WJCC, *World J Clin Cases*) is to provide scholars and readers from various fields of clinical medicine with a platform to publish high-quality clinical research articles and communicate their research findings online.

WJCC mainly publishes articles reporting research results and findings obtained in the field of clinical medicine and covering a wide range of topics, including case control studies, retrospective cohort studies, retrospective studies, clinical trials studies, observational studies, prospective studies, randomized controlled trials, randomized clinical trials, systematic reviews, meta-analysis, and case reports.

**INDEXING/ABSTRACTING**

The WJCC is now abstracted and indexed in Science Citation Index Expanded (SCIE, also known as SciSearch®), Journal Citation Reports/Science Edition, Current Contents®/Clinical Medicine, PubMed, PubMed Central, Reference Citation Analysis, China Science and Technology Journal Database, and Superstar Journals Database. The 2023 Edition of Journal Citation Reports® cites the 2022 impact factor (IF) for WJCC as 1.1; IF without journal self cites: 1.1; 5-year IF: 1.3; Journal Citation Indicator: 0.26; Ranking: 133 among 167 journals in medicine, general and internal; and Quartile category: Q4.

**RESPONSIBLE EDITORS FOR THIS ISSUE**

Production Editor: Zi-Hang Xu, Production Department Director: Xiang Li, Editorial Office Director: Jin-Lei Wang.

**NAME OF JOURNAL**

*World Journal of Clinical Cases*

**ISSN**

ISSN 2307-8960 (online)

**LAUNCH DATE**

April 16, 2013

**FREQUENCY**

Thrice Monthly

**EDITORS-IN-CHIEF**

Bao-Gan Peng, Salim Surani, Jerzy Tadeusz Chudek, George Kontogeorgos, Maurizio Serati

**EDITORIAL BOARD MEMBERS**

<https://www.wjgnet.com/2307-8960/editorialboard.htm>

**PUBLICATION DATE**

January 26, 2024

**COPYRIGHT**

© 2024 Baishideng Publishing Group Inc

**INSTRUCTIONS TO AUTHORS**

<https://www.wjgnet.com/bpg/gerinfo/204>

**GUIDELINES FOR ETHICS DOCUMENTS**

<https://www.wjgnet.com/bpg/GerInfo/287>

**GUIDELINES FOR NON-NATIVE SPEAKERS OF ENGLISH**

<https://www.wjgnet.com/bpg/gerinfo/240>

**PUBLICATION ETHICS**

<https://www.wjgnet.com/bpg/GerInfo/288>

**PUBLICATION MISCONDUCT**

<https://www.wjgnet.com/bpg/gerinfo/208>

**ARTICLE PROCESSING CHARGE**

<https://www.wjgnet.com/bpg/gerinfo/242>

**STEPS FOR SUBMITTING MANUSCRIPTS**

<https://www.wjgnet.com/bpg/GerInfo/239>

**ONLINE SUBMISSION**

<https://www.f6publishing.com>



## Inetetamab combined with pyrotinib and chemotherapy in the treatment of breast cancer brain metastasis: A case report

Qing-Qing Dou, Ting-Ting Sun, Guo-Qiang Wang, Wei-Bing Tong

**Specialty type:** Surgery

**Provenance and peer review:**

Unsolicited article; Externally peer reviewed.

**Peer-review model:** Single blind

**Peer-review report's scientific quality classification**

Grade A (Excellent): 0

Grade B (Very good): 0

Grade C (Good): C

Grade D (Fair): 0

Grade E (Poor): 0

**P-Reviewer:** Nag A, India

**Received:** October 26, 2023

**Peer-review started:** October 26, 2023

**First decision:** November 8, 2023

**Revised:** November 21, 2023

**Accepted:** January 2, 2024

**Article in press:** January 2, 2024

**Published online:** January 26, 2024



**Qing-Qing Dou, Ting-Ting Sun, Guo-Qiang Wang,** Graduate Student Institute, Inner Mongolia Medical University, Hohhot 010000, Inner Mongolia Autonomous Region, China

**Wei-Bing Tong,** Central Breast Area B, Beijing University Cancer Hospital Inner Mongolia Hospital, Hohhot 010000, Inner Mongolia Autonomous Region, China

**Corresponding author:** Wei-Bing Tong, MD, Chief Physician, Surgeon, Central Breast Area B, Beijing University Cancer Hospital Inner Mongolia Hospital, No. 42 Zhaowuda Road, Saihan District, Hohhot 010000, Inner Mongolia Autonomous Region, China. [tongwei365@qq.com](mailto:tongwei365@qq.com)

### Abstract

#### BACKGROUND

Breast cancer brain metastasis (BCBM) is an advanced breast disease that is difficult to treat and is associated with a high risk of death. Patient prognosis is usually poor, with reduced quality of life. In this context, we report the case of a patient with HER-2-positive BCBM treated with a macromolecular mAb (inetetamab) combined with a small molecule tyrosine kinase inhibitor (TKI).

#### CASE SUMMARY

The patient was a 58-year-old woman with a 12-year history of type 2 diabetes. She was compliant with regular insulin treatment and had good blood glucose control. The patient was diagnosed with invasive carcinoma of the right breast (T3N1M0 stage IIIa, HER2-positive type) through aspiration biopsy of the ipsilateral breast due to the discovery of a breast tumor in February 2019. Immunohistochemistry showed ER (-), PR (-), HER-2 (3+), and Ki-67 (55-60%+). Preoperative neoadjuvant chemotherapy, *i.e.*, the AC-TH regimen (epirubicin, cyclophosphamide, docetaxel-paclitaxel, and trastuzumab), was administered for 8 cycles. She underwent modified radical mastectomy of the right breast in November 2019 and received tocilizumab targeted therapy for 1 year. Brain metastasis was found 9 mo after surgery. She underwent brain metastasectomy in August 2020. Immunohistochemistry showed ER (-) and PR. (-), HER-2 (3+), and Ki-67 (10-20%+). In November 2020, the patient experienced headache symptoms. After an examination, tumor recurrence in the original surgical region of the brain was observed, and the patient was treated with inetetamab, pyrotinib, and capecitabine. Whole-brain radiotherapy was recommended. The patient and her family refused radiotherapy for personal reasons. In September 2021, a routine examination revealed that the brain tumor was considerably larger. The original systemic treatment was continued and combined with intensity-modulated

radiation therapy for brain metastases, followed by regular hospitalization and routine examinations. The patient's condition is generally stable, and she has a relatively high quality of life. This case report demonstrates that in patients with BCBM and resistance to trastuzumab, inetetamab combined with pyrotinib and chemotherapy can prolong survival.

## CONCLUSION

Inetetamab combined with small molecule TKI drugs, chemotherapy and radiation may be an effective regimen for maintaining stable disease in patients with BCBM.

**Key Words:** Breast cancer brain metastasis; Resistance to trastuzumab; Macromolecule inetetamab; Small molecule tyrosine kinase inhibitor; Radiation therapy; HER2-positive; Case report

©The Author(s) 2024. Published by Baishideng Publishing Group Inc. All rights reserved.

**Core Tip:** Herein, we report the case of a patient with complex breast cancer brain metastasis. She underwent brain metastasis resection and received macromolecular mAbs, small molecule tyrosine kinase inhibitors, combination chemotherapeutic drugs, and radiation therapy. The overall condition of the patient was controlled and stabilized. We propose that combined macromolecule and small molecule chemotherapy and radiotherapy can provide a new option for the treatment of patients with breast cancer brain metastases. Magnetic resonance imaging of the brain of the patient showed that the tumor size was stable, and all the tumor indicators were within the normal range.

**Citation:** Dou QQ, Sun TT, Wang GQ, Tong WB. Inetetamab combined with pyrotinib and chemotherapy in the treatment of breast cancer brain metastasis: A case report. *World J Clin Cases* 2024; 12(3): 575-581

**URL:** <https://www.wjgnet.com/2307-8960/full/v12/i3/575.htm>

**DOI:** <https://dx.doi.org/10.12998/wjcc.v12.i3.575>

## INTRODUCTION

Among malignancies, breast cancer has the highest incidence among women worldwide[1], and most causes of death from breast cancer are attributed to distant metastasis. Common distant metastasis sites of breast cancer include the lungs, bones, liver and brain. In recent years, with improvements in diagnosis and treatment, an increase in the diversity of treatment drugs and an increase in patient survival, the incidence of breast cancer brain metastasis (BCBM) has increased each year, and the probabilities of brain metastases from Her-2-positive breast cancer and triple-negative breast cancer are increasing. Approximately 34% of HER2-positive breast cancers metastasize to the brain[2]. The prognosis of patients with BCBM is poor, with negative impacts on survival time and quality of life, for example, severe neurocognitive impairment and poor physical prognosis. The common treatments for BCBM include local treatment and systemic therapy. Local treatment includes surgery, whole-brain radiotherapy and stereotactic radiotherapy; systemic treatment includes chemotherapy, targeted therapy, endocrine therapy, immunotherapy and other systemic drug treatments. The selection of treatment for patients depends on neuropsychiatric symptoms, the number and size of brain metastatic lesions and previous treatments[3]. Although some progress has been made in the systemic treatment of BCBM, the blood-brain barrier still poses challenges for effective treatment, and the overall results of systemic treatment are unsatisfactory. Current treatments rarely result in substantial prolongation of the life of patients and only provide palliation. There are enormous treatment challenges, and the prognosis of and benefits to patients need to be considered as a whole.

We describe the case of a patient with BCBM who, after trastuzumab treatment failure, was administered inetetamab combined with pyrotinib, capecitabine and radiation therapy; the disease was controlled and remained stable.

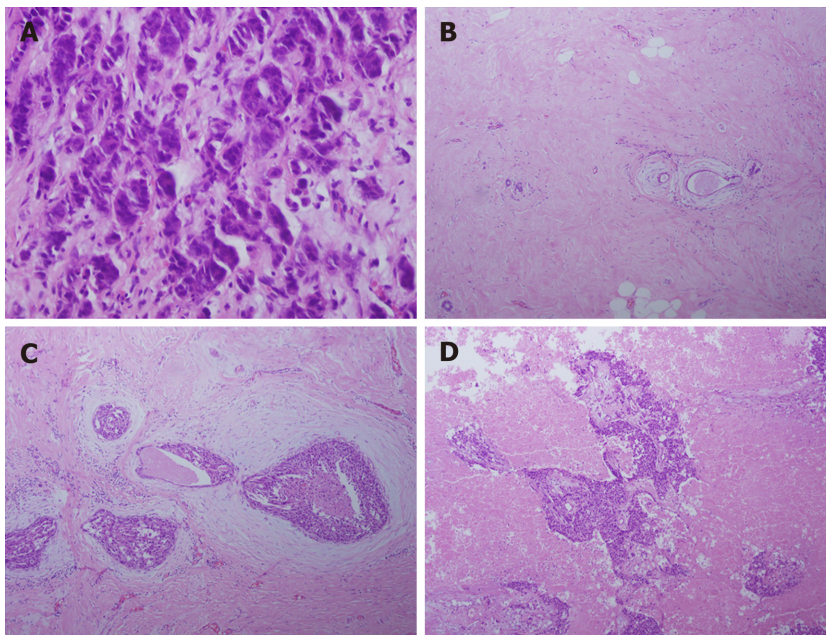
## CASE PRESENTATION

### Chief complaints

A 58-year-old female patient with a 2-year history of breast cancer, a 3-mo history of BCBM and a history of type 2 diabetes mellitus was admitted to our hospital for further evaluation and treatment after modified radical mastectomy for breast cancer.

### History of present illness

The patient was diagnosed with BCBM at the time of admission. One year prior, the patient underwent modified radical mastectomy and, 3 mo ago, underwent unilateral resection of BCBM. The results of an aspiration biopsy of the ipsilateral breast at the first visit were as follows: ER (-), PR (-), HER-2 (3+), HER-2 (3+), and Ki-67 (55%-60%+) (Figure 1A). The results of the biopsy after modified radical mastectomy were as follows: ER (1+, approximately 1%), PR (-), HER-2 (3+),



DOI: 10.12998/wjcc.v12.i3.575 Copyright ©The Author(s) 2024.

**Figure 1 High power microscopic view of lesion tissue.** A: Aspiration biopsy tissue of the ipsilateral breast (40 ×); B: Lesion tissue from modified radical mastectomy after preoperative neoadjuvant treatment (10 ×); C: Lesion tissue from modified radical mastectomy after preoperative neoadjuvant treatment (20 ×); D: Lesion tissue from resected brain metastasis (20 ×).

and Ki-67 (approximately 60%+) (Figure 1B and C). The results of the pathological biopsy after brain metastasis resection were as follows: ER (-), PR (-), HER-2 (3+), and Ki-67 (10%-20%+) (Figure 1D). After the resection of brain metastases, routine magnetic resonance imaging (MRI) of the brain showed irregular and abnormal signals in the right cerebellar hemisphere (original surgical area) with unclear boundaries (size, approx. 25 mm × 20 mm). An enhanced scan showed heterogeneous enhancement. The signal in the right cerebellar hemisphere was abnormal, and metastasis was considered.

### History of past illness

The patient had a 12-year history of diabetes, was compliant with diabetes treatment (regular insulin injections), and had good blood glucose control.

### Personal and family history

The patient denied a family history of malignant tumors.

### Physical examination

The breasts were asymmetrical. The right breast was absent, and a well-healed surgical scar (approximately 20 cm in length) was visible on the right chest wall. The left breast showed normal development. There was no obvious tumor palpable in the left breast, and no superficial swollen lymph nodes were palpable. The patient had an unstable gait and slightly slurred speech, physiological reflexes were present, pathological reflexes were not elicited, and the meningeal irritation sign was weakly positive.

### Laboratory examinations

The levels of tumor markers in the blood did not markedly exceed the normal range during the entire treatment process.

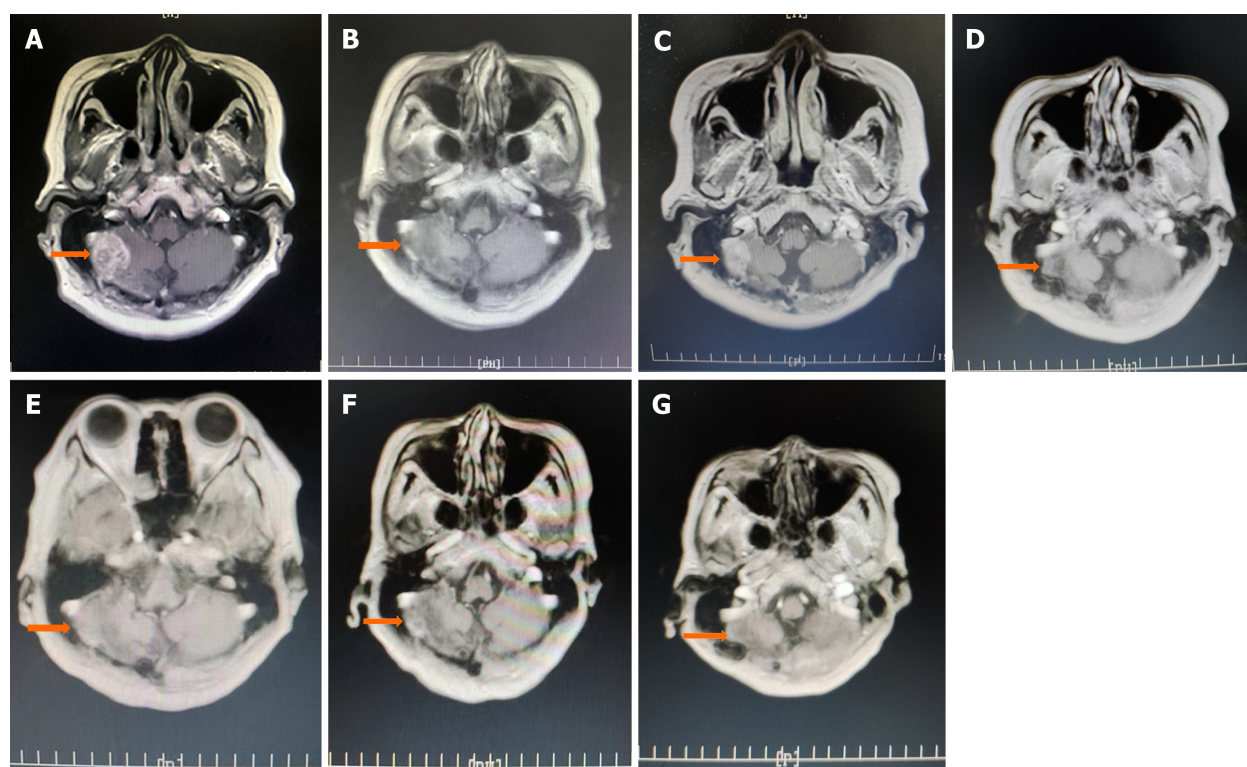
### Imaging examinations

MRI of the brain metastasis, with recurrence in the original brain surgical area, is shown in Figure 2A. After 10 cycles of systemic drug treatment, the tumor size decreased considerably (Figure 2B). The brain tumor was larger after the 16<sup>th</sup> cycle of treatment (Figure 2C). Although the treatment plan was adjusted, the original systemic treatment regimen was generally unchanged; radiotherapy for 12 cycles was added. Brain MRI showed that the tumor was in a stable state (Figure 2D-G). The size of the tumor remained stable at 15 mm × 10 mm (Figure 2E).

## FINAL DIAGNOSIS

After comprehensive laboratory and imaging examinations, the final diagnosis was BCBM (T2N2bM1 stage IV, Her-2 positive type).





DOI: 10.12998/wjcc.v12.i3.575 Copyright ©The Author(s) 2024.

**Figure 2 Magnetic resonance imaging.** A: Recurrence after brain metastasis resection, tumor size, 25 mm × 20 mm (October 29, 2021); B: After 10 cycles of systemic treatment, the tumor shrank considerably (January 26, 2021); C: After 16 cycles of treatment, before 6 cycles of radiation therapy, the tumor size was approximately 27 mm × 18 mm (October 8, 2021); D: The tumor size was approximately 9 mm × 7 mm (May 7, 2022); E: After 10 cycles of treatment, the size of the tumor had not changed notably, i.e., approximately 10 mm × 8 mm (August 1, 2022); F: After 19 cycles of treatment, the size of the tumor was approximately 11 mm × 10 mm (February 8, 2023); G: After 31 cycles of treatment, the tumor size was approximately 11 mm × 9 mm (April 2, 2023).

## TREATMENT

The recommended regimen for patients with brain metastasis and recurrence of breast cancer is the intravenous injection of 400 mg of inotamab for 21 d and 400 mg of oral pyrotinib; due to severe gastrointestinal reactions to the drug, the recommended regimen was changed to 320 mg of oral pyrotinib and capecitabine (2.0 g/time 3 times/day) for the patient in this case study. After consultation with the radiotherapy department, whole-brain radiotherapy was recommended, but the patient and her family refused this option.

Brain metastasis progressed, and the regimen was adjusted: intravenous injection of inotamab 400 mg for 21 d, pyrotinib 320 mg, and capecitabine 1.5 g bid (reduced from 2.0 g bid because of patient intolerance). Intensity-modulated radiation therapy was administered to the intracranial metastatic lesions: 6 MV X-ray IGRT 95% PGTV 52.5 Gy/3.5 Gy/15F.

## OUTCOME AND FOLLOW-UP

After 47 cycles of systemic drug treatment and 31 cycles of radiation therapy, no progression or recurrence of the primary lesions was observed, and the brain metastatic lesions were controlled. Brain MRI showed that the tumor was stable, with no substantial changes from the previous images of the tumor (Figure 2D-G).

## DISCUSSION

Breast cancer is a highly heterogeneous disease. Compared with primary tumors, the HER2 and HR statuses of metastatic lesions are not completely the same[4]. Reevaluations of the molecular typing of brain metastases are key for treatment. Inconsistencies in molecular expression suggest that care needs to be taken when considering the treatment strategy. Additionally, a meta-analysis of patients with HER-2-positive breast cancer found that patients who had previously received adjuvant trastuzumab treatment were more likely than patients who did not receive treatment to develop metastatic recurrence in the central nervous system[5]. At present, anti-HER2 targeted drugs mainly include monoclonal antibodies, small molecule TKIs, and antibody-drug conjugates. For economic reasons in China, the former two are the main drugs used. Trastuzumab is a humanized anti-HER-2 monoclonal antibody that acts on the extracellular portion of

the HER-2 receptor to prevent the activation of intracellular tyrosine kinases and inhibit the proliferation and survival of HER-2-dependent tumor cells; additionally, trastuzumab can mediate the antibody-dependent cellular cytotoxicity (ADCC) effect and kill tumor cells. The ADCC effect is a mechanism in which the Fab fragment of a mAb recognizes and binds to tumor cell surface antigens, and the Fc fragment binds to the Fcγ receptor of NK cells, thereby activating and mediating the killing of tumor cells by NK cells. Studies have shown[6] that compared with trastuzumab, the optimized Fc region has an enhanced ADCC effect on HER2+ tumor cells, including cells that are resistant to trastuzumab and have low HER2 expression. The SOPHIA study[7] showed that in a population with progression after trastuzumab, pertuzumab and T-DM1 treatment, margetuximab, with an optimized and modified Fc region, had a stronger ADCC effect. In patients with advanced breast cancer after multiple lines of treatment, margetuximab, compared with chemotherapy with trastuzumab combined with chemotherapy, improved the progression-free survival (PFS) of HER2-positive advanced breast cancer patients, reducing the risk of disease progression by 24%. To a certain extent, the ADCC effect translates into survival benefits for patients. Inetetamab is an innovative anti-HER2 antibody produced in China. Its Fab fragment is the same as that in trastuzumab, with amino acid modifications of the Fc fragment; the antibody-dependent cell-mediated ADCC effect of inetetamab is better than that of trastuzumab[8]. The HOPES study[9] showed that compared with chemotherapy alone, in first-line advanced breast cancer patients with recurrence and metastasis after surgery, the median PFS was significantly prolonged by 7.8 mo, and the disease control rate was 93.8%, which was 34.4% higher than that in the control group. Inetetamab, which optimizes the ADCC effect, has become a second-line treatment option after trastuzumab failure and has shown good survival benefits. Studies have shown[10,11] that small-molecule TKI-targeted drugs can significantly improve the ADCC effect of macromolecular mAbs. The HER2CLIMB study[12] on chemotherapeutic drugs combined with TKIs and mAbs confirmed that compared with trastuzumab combined with capecitabine, tucatinib combined with trastuzumab and capecitabine significantly prolonged the OS and PFS of patients with HER-2-positive advanced breast cancer recurrence and metastasis; additionally, cancer progression was reduced by 43%, and the risk of death was reduced by 27%. That study illustrates the effectiveness of chemotherapy combined with macromolecular antibodies and small molecule TKIs; however, tucatinib is not available in China. Pyrotinib is a drug similar to tucatinib and was developed in China. The PHOEBE study[13] was a randomized, controlled phase III study of HER2-positive metastatic breast cancer patients who had previously used trastuzumab and taxanes. The results of the PHOEBE study[13] showed that pyrotinib in combination with lapatinib and chemotherapy significantly prolonged PFS by 5.7 mo. Pyrotinib, a representative TKI, not only has powerful HER-2 antagonistic effects but can also synergize with inetetamab to exert a more powerful ADCC effect. The patient in this case study developed recurrence and metastasis 1 year after surgery and was trastuzumab sensitive. For patients in whom trastuzumab treatment fails, the Chinese Society of Clinical Oncology guidelines recommend pyrotinib + capecitabine at level I or level IB T-DM1[14]. Additionally, based on an understanding of the pathological characteristics of brain metastases, in this case, when brain metastases were found, the patient underwent surgical treatment, and histopathology of the lesions was obtained. ADC drugs were not available due to economic conditions; therefore, the macromolecule inetetamab and small molecule TKIs were administered in combination with chemotherapy and radiotherapy. Inotuzumab binds to the extracellular domain of the HER2 molecule, and small molecule TKIs bind to the transmembrane domain of HER2 to block signal transduction, resulting in considerable toxicity related to the inhibition of the epidermal factor growth receptor, thus exerting antitumor effects. The use of TKIs for BCBM patients can improve the survival rate and local control and may reduce distant metastasis[15]. In addition, a review of the entire treatment process of the patient in this case study revealed that the addition of treatment at two key time points may provide benefits. First, anti-HER2 therapy should be added after the first BCBM resection. In addition, patients should receive radiation therapy for breast cancer recurrence after brain metastases. Some studies have shown that radiotherapy after surgical resection may provide a survival benefit for some patients with solitary BCBM[16]. Surgery and systemic treatment can delay disease progression, but it is difficult to remove tumor cells from the body; therefore, the combination of treatment methods is very important. The patient in this case study received radiotherapy after the second MDT, and brain metastases were controlled, yielding a better treatment result. During the follow-up and treatment period, no recurrence was observed. BCBM is a systemic disease, and local treatment combined with systemic treatment can not only improve the control rate of intracranial tumors but also relieve systemic symptoms. In this case, the extracranial treatment was stable, and intracranial treatment progressed. After the first MDT discussion, we continued the original systemic treatment and the same overall plan, with the addition of adjuvant local treatment (radiotherapy). The advantages of interdisciplinary cooperation include the comprehensive evaluation of the actual physical and economic conditions of the patient to focus on improving quality of life, prolonging survival, reducing drug toxicity, and developing a treatment plan that suits each individual patient to achieve disease-free progression. However, the current treatment options are generally not well developed. Our goal is to explore different methods for effectively treating BCBM. However, the overall principle that needs to be followed is precise individualized treatment of patients through the development of optimal plans based on multiple factors to bring maximum benefits to each patient.

## CONCLUSION

Inetetamab combined with small molecule TKI, chemotherapy and radiotherapy may be an effective adjuvant therapy for the treatment of BCBM. Clinicians should provide reasonable treatments based on the real-time condition of each patient.

## FOOTNOTES

**Author contributions:** Dou QQ is the main contributor of this case, mainly responsible for case information collection; Sun TT and Wang GQ have the same contribution to the paper, mainly responsible for picture collection and content verification; Dou QQ integrated the content and wrote the manuscript; Tong WB was mainly responsible for the review and evaluation of the manuscript; all authors have commented on the previous version of the manuscript and approve the final manuscript.

**Informed consent statement:** Written informed consent was obtained from the patient for publication of this report and all accompanying images.

**Conflict-of-interest statement:** All the authors report no relevant conflicts of interest for this article.

**CARE Checklist (2016) statement:** The authors have read the CARE Checklist (2016), and the manuscript was prepared and revised according to the CARE Checklist (2016).

**Open-Access:** This article is an open-access article that was selected by an in-house editor and fully peer-reviewed by external reviewers. It is distributed in accordance with the Creative Commons Attribution NonCommercial (CC BY-NC 4.0) license, which permits others to distribute, remix, adapt, build upon this work non-commercially, and license their derivative works on different terms, provided the original work is properly cited and the use is non-commercial. See: <https://creativecommons.org/licenses/by-nc/4.0/>

**Country/Territory of origin:** China

**ORCID number:** Qing-Qing Dou 0009-0009-1191-758X; Ting-Ting Sun 0009-0003-1002-2692; Guo-Qiang Wang 0009-0009-3290-207X; Wei-Bing Tong 0009-0004-9599-4139.

**S-Editor:** Gong ZM

**L-Editor:** A

**P-Editor:** Zhang YL

## REFERENCES

- 1 Sung H, Ferlay J, Siegel RL, Laversanne M, Soerjomataram I, Jemal A, Bray F. Global Cancer Statistics 2020: GLOBOCAN Estimates of Incidence and Mortality Worldwide for 36 Cancers in 185 Countries. *CA Cancer J Clin* 2021; **71**: 209-249 [PMID: 33538338 DOI: 10.3322/caac.21660]
- 2 Fecci PE, Champion CD, Hoj J, McKernan CM, Goodwin CR, Kirkpatrick JP, Anders CK, Pendergast AM, Sampson JH. The Evolving Modern Management of Brain Metastasis. *Clin Cancer Res* 2019; **25**: 6570-6580 [PMID: 31213459 DOI: 10.1158/1078-0432.CCR-18-1624]
- 3 Ramakrishna N, Temin S, Chandarlapaty S, Crews JR, Davidson NE, Esteva FJ, Giordano SH, Kirshner JJ, Krop IE, Levinson J, Modi S, Patt DA, Perlmutter J, Winer EP, Lin NU. Recommendations on Disease Management for Patients With Advanced Human Epidermal Growth Factor Receptor 2-Positive Breast Cancer and Brain Metastases: ASCO Clinical Practice Guideline Update. *J Clin Oncol* 2018; **36**: 2804-2807 [PMID: 29939840 DOI: 10.1200/JCO.2018.79.2713]
- 4 Chen X, Wang M, Yu K, Xu S, Qiu P, Lyu Z, Zhang X, Xu Y. Chronic stress-induced immune dysregulation in breast cancer: Implications of psychosocial factors. *J Transl Int Med* 2023; **11**: 226-233 [PMID: 37662890 DOI: 10.2478/jtim-2021-0050]
- 5 Lin NU. Better treatments needed for breast cancer brain metastases. *Lancet Oncol* 2015; **16**: 1583-1584 [PMID: 26596673 DOI: 10.1016/S1470-2045(15)00477-5]
- 6 Nordstrom JL, Gorlatov S, Zhang W, Yang Y, Huang L, Burke S, Li H, Ciccarone V, Zhang T, Stavenhagen J, Koenig S, Stewart SJ, Moore PA, Johnson S, Bonvini E. Anti-tumor activity and toxicokinetics analysis of MGAH22, an anti-HER2 monoclonal antibody with enhanced Fcγ receptor binding properties. *Breast Cancer Res* 2011; **13**: R123 [PMID: 22129105 DOI: 10.1186/bcr3069]
- 7 Rugo HS, Im SA, Cardoso F, Cortés J, Curigliano G, Musolino A, Pegram MD, Wright GS, Saura C, Escrivá-de-Romaní S, De Laurentiis M, Levy C, Brown-Glaberman U, Ferrero JM, de Boer M, Kim SB, Petráková K, Yardley DA, Freedman O, Jakobsen EH, Kaufman B, Yerushalmi R, Fasching PA, Nordstrom JL, Bonvini E, Koenig S, Edlich S, Hong S, Rock EP, Gradishar WJ; SOPHIA Study Group. Efficacy of Margetuximab vs Trastuzumab in Patients With Pretreated ERBB2-Positive Advanced Breast Cancer: A Phase 3 Randomized Clinical Trial. *JAMA Oncol* 2021; **7**: 573-584 [PMID: 33480963 DOI: 10.1001/jamaoncol.2020.7932]
- 8 Moore GL, Chen H, Karki S, Lazar GA. Engineered Fc variant antibodies with enhanced ability to recruit complement and mediate effector functions. *MAbs* 2010; **2**: 181-189 [PMID: 20150767 DOI: 10.4161/mabs.2.2.11158]
- 9 Wang T, Zhang P, Di LJ, Wang XJ, Yang JL, Tong ZS, Liu J, Feng JF, Liu DJ, Yu QT, Liu YP, Yu H, Jiang ZF. Efficacy and safety of inotamab in combination with chemotherapy as first-line treatment of HER2-positive metastatic breast cancer: a subgroup analysis in the HOPES study. 2022; **3**: 2218-6778 [DOI: 10.21037/tbcr-21-42]
- 10 Galluzzi L, Zitvogel L, Kroemer G. Immunological Mechanisms Underneath the Efficacy of Cancer Therapy. *Cancer Immunol Res* 2016; **4**: 895-902 [PMID: 27803050 DOI: 10.1158/2326-6066.CIR-16-0197]
- 11 Mimura K, Kamiya T, Shiraishi K, Kua LF, Shabbir A, So J, Yong WP, Suzuki Y, Yoshimoto Y, Nakano T, Fujii H, Campana D, Kono K. Therapeutic potential of highly cytotoxic natural killer cells for gastric cancer. *Int J Cancer* 2014; **135**: 1390-1398 [PMID: 24615495 DOI: 10.1002/ijc.28780]
- 12 Curigliano G, Mueller V, Borges V, Hamilton E, Hurvitz S, Loi S, Murthy R, Okines A, Paplomata E, Cameron D, Carey LA, Gelmon K, Hortobagyi GN, Krop I, Loibl S, Pegram M, Slamon D, Ramos J, Feng W, Winer E. Tucatinib versus placebo added to trastuzumab and capecitabine for patients with pretreated HER2+ metastatic breast cancer with and without brain metastases (HER2CLIMB): final overall survival analysis. *Ann Oncol* 2022; **33**: 321-329 [PMID: 34954044 DOI: 10.1016/j.annonc.2021.12.005]
- 13 Xu B, Yan M, Ma F, Hu X, Feng J, Ouyang Q, Tong Z, Li H, Zhang Q, Sun T, Wang X, Yin Y, Cheng Y, Li W, Gu Y, Chen Q, Liu J, Cheng

- J, Geng C, Qin S, Wang S, Lu J, Shen K, Liu Q, Wang H, Luo T, Yang J, Wu Y, Yu Z, Zhu X, Chen C, Zou J; PHOEBE Investigators. Pyrotinib plus capecitabine versus lapatinib plus capecitabine for the treatment of HER2-positive metastatic breast cancer (PHOEBE): a multicentre, open-label, randomised, controlled, phase 3 trial. *Lancet Oncol* 2021; **22**: 351-360 [PMID: 33581774 DOI: 10.1016/S1470-2045(20)30702-6]
- 14 **Wang FH**, Zhang XT, Li YF, Tang L, Qu XJ, Ying JE, Zhang J, Sun LY, Lin RB, Qiu H, Wang C, Qiu MZ, Cai MY, Wu Q, Liu H, Guan WL, Zhou AP, Zhang YJ, Liu TS, Bi F, Yuan XL, Rao SX, Xin Y, Sheng WQ, Xu HM, Li GX, Ji JF, Zhou ZW, Liang H, Zhang YQ, Jin J, Shen L, Li J, Xu RH. The Chinese Society of Clinical Oncology (CSCO): Clinical guidelines for the diagnosis and treatment of gastric cancer, 2021. *Cancer Commun (Lond)* 2021; **41**: 747-795 [PMID: 34197702 DOI: 10.1002/cac2.12193]
- 15 **Miller JA**, Kotecha R, Ahluwalia MS, Mohammadi AM, Chao ST, Barnett GH, Murphy ES, Vogelbaum MA, Angelov L, Peereboom DM, Suh JH. Overall survival and the response to radiotherapy among molecular subtypes of breast cancer brain metastases treated with targeted therapies. *Cancer* 2017; **123**: 2283-2293 [PMID: 28192598 DOI: 10.1002/cncr.30616]
- 16 **Foreman PM**, Jackson BE, Singh KP, Romeo AK, Guthrie BL, Fisher WS, Riley KO, Markert JM, Willey CD, Bredel M, Fiveash JB. Postoperative radiosurgery for the treatment of metastatic brain tumor: Evaluation of local failure and leptomeningeal disease. *J Clin Neurosci* 2018; **49**: 48-55 [PMID: 29248376 DOI: 10.1016/j.jocn.2017.12.009]





Published by **Baishideng Publishing Group Inc**  
7041 Koll Center Parkway, Suite 160, Pleasanton, CA 94566, USA

**Telephone:** +1-925-3991568

**E-mail:** [office@baishideng.com](mailto:office@baishideng.com)

**Help Desk:** <https://www.f6publishing.com/helpdesk>

<https://www.wjgnet.com>

