

# Transjugular intrahepatic portosystemic shunt for palliative treatment of portal hypertension secondary to portal vein tumor thrombosis

Zai-Bo Jiang, Hong Shan, Xin-Ying Shen, Ming-Sheng Huang, Zheng-Ran Li, Kang-Shun Zhu, Shou-Hai Guan

**Zai-Bo Jiang, Hong Shan, Xin-Ying Shen, Ming-Sheng Huang, Zheng-Ran Li, Kang-Shun Zhu, Shou-Hai Guan**, Department of Radiology, the 3rd Affiliated Hospital of Sun Yat-Sen University, Guangzhou 510630, Guangdong Province, China

**Correspondence to:** Dr. Hong Shan, the 3rd Affiliated Hospital of Sun Yat-Sen University, Guangzhou 510630, Guangdong Province, China. jzb01@163.net

**Telephone:** +86-20-85516867 **Fax:** +86-20-87580725

**Received:** 2003-12-28 **Accepted:** 2004-01-08

## Abstract

**AIM:** To evaluate the palliative therapeutic effects of transjugular intrahepatic portosystemic shunt (TIPS) in portal vein tumor thrombosis (PVTT) complicated by portal hypertension.

**METHODS:** We performed TIPS for 14 patients with PVTT due to hepatocellular carcinoma (HCC). Of the 14 patients, 8 patients had complete occlusion of the main portal vein, 6 patients had incomplete thrombosis, and 5 patients had portal vein cavernous transformation. Clinical characteristics and average survival time of 14 patients were analysed. Portal vein pressure, ascites, diarrhoea, and variceal bleeding and circumference of abdomen were assessed before and after TIPS.

**RESULTS:** TIPS was successful in 10 cases, and the successful rate was about 71%. The mean portal vein pressure was reduced from 37.2 mmHg to 18.2 mmHg. After TIPS, the ascites decreased, hemorrhage stopped and the clinical symptoms disappeared in the 10 cases. The average survival time was 132.3 d. The procedure failed in 4 cases because of cavernous transformation in portal vein and severe cirrhosis.

**CONCLUSION:** TIPS is an effective palliative treatment to control hemorrhage and ascites due to HCC complicated by PVTT.

Jiang ZB, Shan H, Shen XY, Huang MS, Li ZR, Zhu KS, Guan SH. Transjugular intrahepatic portosystemic shunt for palliative treatment of portal hypertension secondary to portal vein tumor thrombosis. *World J Gastroenterol* 2004; 10(13): 1881-1884 <http://www.wjgnet.com/1007-9327/10/1881.asp>

## INTRODUCTION

TIPS is effective in treating patients with hemorrhage, intractable ascites and portal hypertensive gastropathy, and many favorable results and experiences have been obtained as well<sup>[1-7]</sup>. TIPS has been widely used for portal hypertension with portal vein thrombosis (PVT), type-III Budd-Chiari syndrome, even bile duct occlusive diseases, and other portal hypertension<sup>[8-17]</sup>. But how to treat primary hepatocarcinoma

with secondary portal hypertension is a challenge. In 1995, Zhang<sup>[18]</sup> first reported the clinical experiences that TIPS procedure was applied to HCC patients with variceal hemorrhage, but the portal vein must be opened before TIPS. There were no reports about whether TIPS could be a palliative method for portal vein tumor thrombosis (PVTT). Since 1998 we have tried to study TIPS in the treatment of portal hypertension secondary to PVTT.

## MATERIALS AND METHODS

### Clinical data

There were 14 patients with end-stage HCC in our hospital from December 1998 to May 2001, 13 men and one woman. The patients aged from 28 to 75 years, and the average age was 56.3 years. Three patients did not receive any treatment before TIPS and the others were treated with transarterial chemoembolization (TACE) and other procedures. One patient survived for 6 years after 8 times of TACE, and 2 patients emerged ascites and hemorrhage after they were treated by radiofrequency ablation. Of the 14 patients, there were three patients with intractable ascites, one patient with simple hemorrhage and 10 patients with hemorrhage and ascites (Tables 1, 2). Their hepatic function was poor and assigned to Child-Pugh class C. The diagnosis of PVTT was based on contrast-enhanced CT and color Doppler sonography while the cavernous transformation in the portal vein was detected by color Doppler sonography, contrast-enhanced CT and angiography.

### TIPS procedure

TIPS was performed by using the RTPS 100 (Cook, America) portal venous puncture set. After administration of local anesthetic (20 g/L lidocaine hydrochloride) the Colapinto needle (Cook, America) was advanced into the right hepatic vein, and then the right portal vein was punctured. A wire guide (hydrophilic coating wire guide, Terumo) was introduced through the needle. Because of stenosis, occlusion and cavernous transformation of portal vein trunk and its right and left branches, puncture was difficult. So small branches were also available. With a guiding wire the catheter was advanced into the portal vein trunk. After measurement of the portal venous pressure, the needle track was dilated with a balloon (10 mm-diameter, 40 mm-length). Then an expandable stent (8-10 mm-diameter, 6-8 cm-length) was placed. The number of stents was based on the length of the shunt tract to ensure the stents covering all along stenosis segments arising from tumor emboli. The portal venous pressure was also measured after shunt was established.

## RESULTS

The portosystemic shunt was successful in 10 of 14 patients. Shunt tract was achieved with a single stent in four patients, two stents in four patients, and four stents in two patients. The mean portal pressure was 37.2 mmHg and 18.2 mmHg before

and after TIPS. The mean abdomen circumference was 86.3 cm and 77.65 cm before and after the procedure (Table 1). TIPS could be performed for four patients with incomplete occlusion of portal vein trunk as standard TIPS (Figure 1), while it could be performed for six patients with complete occlusion of portal vein trunk by introducing hydrophilic coating wire guide through the potential vascular lumen to superior mesenteric vein (Figure 2). The 4 patients with cavernous transformation in portal vein and severe cirrhosis failed to TIPS procedure, no portal vein trunk and branches but vascular plexus sign was displayed on angiogram. They had no improvement in clinical symptoms and their mean survival time was 34 days, shorter than the successful ones. The needles were punctured out of liver and into the peritoneum cavity in two patients, but they had no severe complications during and after the procedure. The needle tract was passed through the tumor in one patient, but no metastasis was found in 3 mo of follow-up. In all patients the mean content of serum bilirubin and aminotransferase increased transiently after TIPS procedure,

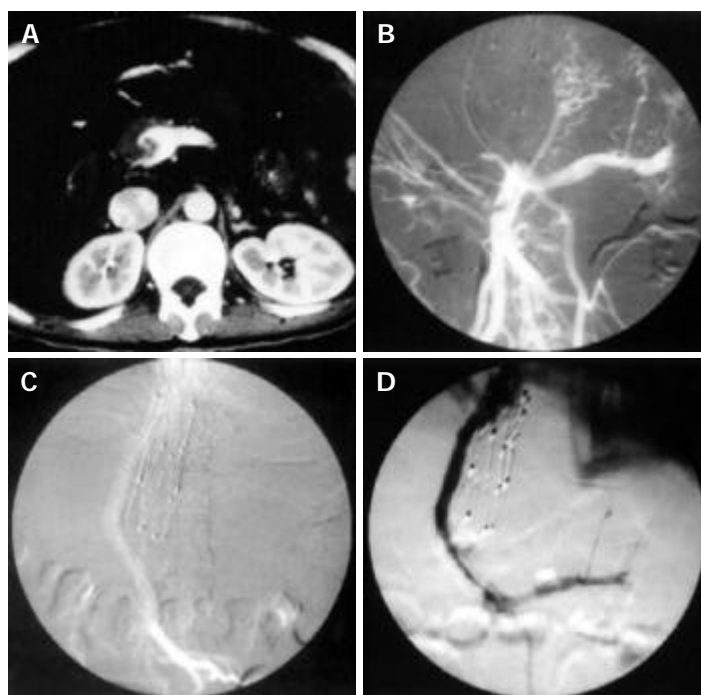
and improved after one week of treatment.

**Table 1** Clinical characteristics of 14 patients assigned to treatment with transjugular intrahepatic portosystemic stent-shunt procedure

Characteristic	Value
Age (yr)	
Range	28-75
mean±SD	53.6±12.7
Sex (M/F)	13/1
Occlusion of portal vein	
Portal vein trunk (complete/ incomplete)	10/4
Right branch (complete/ incomplete)	10/1
Left branch (complete/ incomplete)	2/2
Tumor type (nodular/massive/diffuse)	2/6/6
With cavernous transformation of PV	5
Times of TACE (mean±SD)	3.7±1.8

**Table 2** Portal pressure, ascites and clinical symptoms before and after TIPS procedure in 10 patients receiving stents (mean±SD)

	Before procedure	After procedure	(t/ $\chi^2$ value)	P Value
Portal vein pressure (mmHg)	37.5±4.8	18.2±1.8	t:13.032	0.000
Circumference of abdomen (cm)	85.3±4.7	79.2±5.2	t:3.823	0.002
Ascites				
Mild	3	8		
Moderate	1	4		
Severe	10	2		
Diarrhoea (times/d)	3.8±4.4	0±0	t:3.202	0.007
Hepatic encephalopathy				
0	9	9		
I	3	5		
II	2	0		
Variceal bleeding (times)	1.9±1.5	0±0	T:4.759	0.000



**Figure 1** TIPS procedure in patient with incomplete occlusion of portal vein trunk. A: Main portal vein dilation with eccentric tumor thrombi shown on enhanced Ctgram. B: Superior mesenteric vein dilation with eccentric filling defect and main portal vein occlusion shown on superior mesenteric vein angiogram. C: Open shunt shown on superior mesenteric vein angiogram after stent implantation. D: Recurrence of symptoms of ascites and diarrhoea 30 d after TIPS and shunt stenosis as well as segmental filling defects shown on follow-up angiogram.

## DISCUSSION

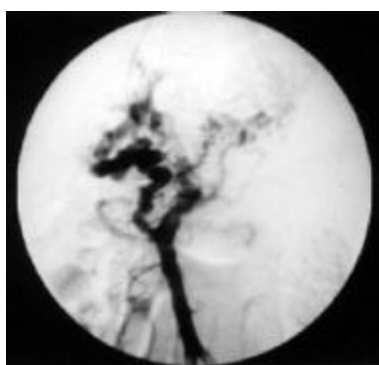
The incidence of PVTT in end-staged HCC was very high, about 20-30% in small hepatoma (2-3 cm in diameter) and 50-75% in those above 5 cm in diameter, and 86% of HCC patients with variceal bleeding had PVTT<sup>[18]</sup>. The tumor emboli resulting in portal hypertension and high resistance made the patients tend to have variceal bleeding and ascites. Tumor thrombosis in main portal vein was more prone to variceal bleeding and more difficult to be treated than that in branches and hepatic vein. Therefore some conservative measures were taken to relieve the patients' ailments, such as endoscopic sclerotherapy and ligation. But these measures were less effective. Because of low efficacy and huge cost, many patients abandoned treatment.

### Current status and application of TIPS in PVTT

TIPS procedure is an effective and safe treatment for patients with variceal hemorrhage and intractable ascites, but its use is limited due to its complications of encephalopathy and poor long-term efficacy<sup>[19-25]</sup>. It was reported that the rate of stenosis of shunt was 33-66% within 1 year and that of encephalopathy was 10-30%<sup>[1-2,19,22]</sup>. In recent years some scholars applied TIPS to portal hypertension secondary to portal thrombosis to ensure the patients to have time for further treatments including liver transplantation<sup>[26-29]</sup>. But the thrombus must be newly happened because old emboli possibly led to cavernous transformation and made the TIPS and liver transplantation difficult. Some authorities applied TIPS to HCC patients with esophagogastric variceal bleeding, but they thought that patients must be with hepatic function class A or B (Child-Pugh classification), under-controlled or small nodular type hepatoma and without PVTT<sup>[18,30-34]</sup>.

### Key skill points in TIPS procedure for PVTT

Of the 14 cases, 10 cases were technically successful and the ratio of success was consistent with that reported<sup>[1-2]</sup>. It was very difficult to puncture the right main portal branch directly because of portal occlusion, stenosis and cavernous transformation. Even a small branch of portal vein was punctured with good blood regurgitation, and hydrophilic coating wire guide could be introduced into the superior mesenteric vein or splenic vein through the loose thrombus (Figure 2). The stent should cover all the thrombus to prevent tumor from growing into the shunt. The slower the blood flow passing the stent, the more easily the shunt is thrombosed. Esophagogastric vein should be embolized after TIPS procedure because low blood flow tended to form thrombosis in the shunt<sup>[8,25]</sup>. The embolism of esophagogastric vein could also prevent variceal bleeding, keep high flow and reduce thrombosis in the stent. But esophagogastric vein was not displayed very well because of PVTT in most cases.

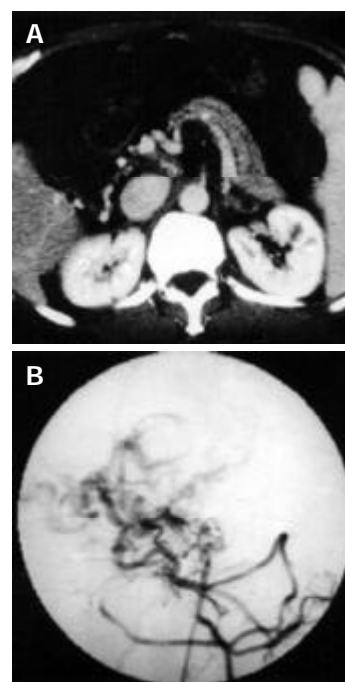


**Figure 2** Occlusive portal vein, dilated superior mesenteric vein, portal vein cavernous transformation, and esophagogastric varices shown on portal vein angiogram after introducing a catheter into superior mesenteric vein.

### Experiences and clinical effect

TIPS procedure is very effective for diarrhoea secondary to PVTT. A male patient with PVTT had mechanical diarrhoea 12-15 times a day and it lasted for a month with no abnormality in stool examination. Following the decrease of portal pressure after TIPS, ascites and diarrhoea decreased. The causes of diarrhoea were similar to those of ascites. Too high portal vein pressure could make fluid leak out of vessels not only into peritoneal cavity but also into intestinal tract as watery stool.

All patients who failed to TIPS procedure had cavernous transformation. Two patients with tumor thrombus in portal vein had no dilation in superior mesenteric vein and the pressure was not high as well (Figure 3). Considering that the effect was probably not very well in patients with little pressure gradient, we did not continue further procedure. In these portal hypertension patients there were areas with both a portal and a systemic venous drainage including esophagus, anal canal, retroperitoneum and umbilical region. Partial spleen artery embolization or gastric coronary vein embolization was not effective and variceal rebleeding was inevitable in the following months. In this study only one patient had a successful procedure in five patients with cavernous transformation, so it should be careful to carry out TIPS procedure in such cases.



**Figure 3** Main portal vein occlusion, hepatic arteric portal shunt and portal cavernous transformation in a 64-year-old patient with refractory ascites and hematemesis. A: Thin splenic and superior mesenteric vein shown on enhanced CT gram. B: Thin superior mesenteric vein and disordered drainage vein shown on angiogram.

A suitable size of stent is important to improve shunt flow, prevent esophagogastric variceal bleeding and decrease ascites<sup>[23-34]</sup>. Too large a stent could lead to encephalopathy and we used stents of 10 mm in diameter. The shunt stenosed in one patient with a stent of 8 mm in diameter 15 days after TIPS and died of rebleeding after 20 d. Another patient was placed 4 stents because the shunt was too long. Stenosis of the shunt happened 30 d after the stents were placed and the angiogram displayed shunt rugged and segmental filling defects (Figure 1D). Treatment of the shunt stenosis was similar to that of standard TIPS. The rate of shunt stenosis was relatively low in these patients, partly because of short-term follow-up and abnormal coagulation. By actively preventing encephalopathy and closely

monitoring condition change, patients in this study did not have encephalopathy of stage II and only 5 patients had transitory encephalopathy of stage I. Although patients died of dyscrasia or liver failure, their quality of life was improved.

## REFERENCES

- Papatheodoridis GV**, Goulis J, Leandro G, Patch D, Burroughs AK. Transjugular intrahepatic portosystemic shunt compared with endoscopic treatment for prevention of variceal rebleeding: a meta-analysis. *Hepatology* 1999; **30**: 612-622
- Schepke M**, Sauerbruch T. Transjugular portosystemic stent shunt in treatment of liver diseases. *World J Gastroenterol* 2001; **7**: 170-174
- Xu K**, Zhang HG, He XF, Zhao ZC, Ren K, Jin CY, Han MJ, Wang CL. Preliminary report on portal hypertension in liver cirrhosis treated by transjugular intrahepatic portosystemic stent-shunt: analysis of 8 cases. *Zhonghua Fangshexue Zazhi* 1993; **27**: 294-297
- Zhang JS**, Wang MQ, Yang L. Transjugular intrahepatic portosystemic stent shunts. *Zhonghua Yixue Zazhi* 1994; **74**: 150-152
- Wang MQ**, Zhang JS, Gao YA. Transjugular intrahepatic portosystemic stent-shunt: an experimental study. *Zhonghua Fangshexue Zazhi* 1993; **28**: 324-327
- Trotter JF**, Suhocki PV, Rockey DC. Transjugular intrahepatic portosystemic shunt (TIPS) in patients with refractory ascites: effect on body weight and Child-Pugh score. *Am J Gastroenterol* 1998; **93**: 1891-1894
- Han SW**, Joo YE, Kim HS, Choi SK, Rew JS, Kim JK, Kim SJ. Clinical results of the transjugular intrahepatic portosystemic shunt (TIPS) for the treatment of variceal bleeding. *Korean J Intern Med* 2000; **15**: 179-186
- Walser EM**, McNees SW, DeLa Pena O, Crow WN, Morgan RA, Soloway R, Broughan T. Portal venous thrombosis percutaneous therapy and outcome. *J Vasc Interv Radiol* 1998; **9**(1 Pt 1): 119-127
- Cwikiel W**, Keussen I, Larsson L, Solvig J, Kullendorff CM. Interventional treatment of children with portal hypertension secondary to portal vein occlusion. *Eur J Pediatr Surg* 2003; **13**: 312-318
- Opitz T**, Buchwald AB, Lorf T, Awuah D, Ramadori G, Nolte W. The transjugular intrahepatic portosystemic stent-shunt (TIPS) as rescue therapy for complete Budd-Chiari syndrome and portal vein thrombosis. *Z Gastroenterol* 2003; **41**: 413-418
- Ganger DR**, Klapman JB, McDonald V, Matalon TA, Kaur S, Rosenblatt H, Kane R, Saker M, Jensen DM. Transjugular intrahepatic portosystemic shunt (TIPS) for Budd-Chiari syndrome or portal vein thrombosis: review of indications and problems. *Am J Gastroenterol* 1999; **94**: 603-608
- Sehgal M**, Haskal ZJ. Use of transjugular intrahepatic portosystemic shunts during lytic therapy of extensive portal splenic and mesenteric venous thrombosis: long-term follow-up. *J Vasc Interv Radiol* 2000; **11**: 61-65
- Yamagami T**, Nakamura T, Tanaka O, Akada W, Takayama T, Maeda T. Transjugular intrahepatic portosystemic shunts after complete obstruction of portal vein. *J Vasc Interv Radiol* 1999; **10**: 575-578
- Shibata D**, Brophy DP, Gordon FD, Anastopoulos HT, Sentovich SM, Bleday R. Transjugular intrahepatic portosystemic shunt for treatment of bleeding ectopic varices with portal hypertension. *Dis Colon Rectum* 1999; **42**: 1581-1585
- Azoulay D**, Castaing D, Lemoine A, Samuel D, Majno P, Reynes M, Charpentier B, Bismuth H. Successful treatment of severe azathioprine-induced hepatic veno-occlusive disease in a kidney-transplanted patient with transjugular intrahepatic portosystemic shunt. *Clin Nephrol* 1998; **50**: 118-122
- Nolte W**, Canelo R, Figulla HR, Kersten J, Sattler B, Munke H, Hartmann H, Ringe B, Ramadori G. Transjugular intrahepatic portosystemic stent-shunt after orthotopic liver transplantation in a patient with early recurrence of portal hypertension of unknown origin. *Z Gastroenterol* 1998; **36**: 159-164
- Benador N**, Grimm P, Lavine J, Rosenthal P, Reznik V, Lemire J. Transjugular intrahepatic portosystemic shunt prior to renal transplantation in a child with autosomal-recessive polycystic kidney disease and portal hypertension: A case report. *Pediatr Transplant* 2001; **5**: 210-214
- Zhang XT**, Xu K, Zhang HG, Zhang LC, Zhao ZC, Han MJ. Primary hepatocellular carcinoma with portal hypertension treated with TIPSS. *Linchuang Fangshexue Zazhi* 1995; **14**: 236-238
- Hausegger KA**, Sternthal HM, Klein GE, Karaic R, Stauber R, Zenker G. Transjugular intrahepatic portosystemic shunt: angiographic follow-up and secondary interventions. *Radiology* 1994; **191**: 177-181
- Willkomm P**, Schomburg A, Brensing KA, Reichmann K, Bangard M, Overbeck B, Sauerbruch T, Biersack HJ. Liver perfusion scintigraphy prior to and after transjugular intrahepatic portosystemic shunts (TIPS) in patients with portal hypertension. *Nuklearmedizin* 2000; **39**: 139-141
- Zuckerman DA**, Darcy MD, Bocchini TP, Hildebolt CF. Encephalopathy after transjugular intrahepatic portosystemic shunting: analysis of incidence and potential risk factors. *Am J Roentgenol* 1997; **169**: 1727-1731
- Sterling RK**, Sanyal AJ. Are TIPS tops in the treatment of portal hypertension? A review on the use and misuse of transjugular intrahepatic portosystemic shunts. *Can J Gastroenterol* 2000; **14**(Suppl D): 122D-128D
- Sanyal AJ**. The use and misuse of transjugular intrahepatic portosystemic shunts. *Papatheodoridis G Curr Gastroenterol Rep* 2000; **2**: 61-71
- Younossi ZM**, McHutchison JG, Broussard C, Cloutier D, Sedghi-Vaziri A. Portal decompression by transjugular intrahepatic portosystemic shunt and changes in serum-ascites albumin gradient. *J Clin Gastroenterol* 1998; **27**: 149-151
- Latimer J**, Bawa SM, Rees CJ, Hudson M, Rose JD. Patency and reintervention rates during routine TIPSS surveillance. *Cardiovasc Intervent Radiol* 1998; **21**: 234-239
- Khan TT**, Reddy KS, Johnston TD, Lo FK, Shedlofsky S, Grubb S, Ranjan D. Transjugular intrahepatic portosystemic shunt migration in patients undergoing liver transplantation. *Int Surg* 2002; **87**: 279-281
- Hidajat N**, Vogl T, Stobbe H, Schmidt J, Wex C, Lenzen R, Berg T, Neuhaus P, Felix R. Transjugular intrahepatic portosystemic shunt. Experiences at a liver transplantation center. *Acta Radiol* 2000; **41**: 474-478
- Liatsos C**, Vlachogiannakos J, Patch D, Tibballs J, Watkinson A, Davidson B, Rolles K, Burroughs AK. Successful recanalization of portal vein thrombosis before liver transplantation using transjugular intrahepatic portosystemic shunt. *Liver Transpl* 2001; **7**: 453-460
- Menegaux F**, Keefe EB, Baker E, Egawa H, Concepcion W, Russell TR, Esquivel CO. Comparison of transjugular and surgical portosystemic shunts on the outcome of liver transplantation. *Arch Surg* 1994; **129**: 1018-1023
- Nicolini A**, Saccheri S, Lovaria A, Maggi A, Cazzaniga M, Panzeri A, Salerno F. Prevention of variceal rebleeding and treatment of liver carcinoma by consecutive transjugular intrahepatic portosystemic shunt and hepatic artery chemoembolization. *Ital J Gastroenterol* 1996; **28**: 269-271
- Burger JA**, Ochs A, Wirth K, Berger DP, Mertelsmann R, Engelhardt R, Roessle M, Haag K. The transjugular stent implantation for the treatment of malignant portal and hepatic vein obstruction in cancer patients. *Ann Oncol* 1997; **8**: 200-202
- Serafini FM**, Zwiebel B, Black TJ, Carey LC, Rosemurgy AS 2nd. Transjugular intrahepatic portosystemic stent shunt in the treatment of variceal bleeding in hepatocellular cancer. *Dig Dis Sci* 1997; **42**: 59-65
- Tazawa J**, Sakai Y, Yamane M, Kakinuma S, Maeda M, Suzuki K, Miyasaka Y, Nagayama K, Kusano F, Sato C. Long-term observation after transjugular intrahepatic portosystemic stent-shunt in two patients with hepatocellular carcinoma. *J Clin Gastroenterol* 2000; **31**: 262-267
- Sakaguchi H**, Uchida H, Maeda M, Matsuo N, Kichikawa K, Ohishi H, Nishida H, Ueno K, Nishimine K, Rosch J. Combined transjugular intrahepatic portosystemic shunt and segmental Lipiodol hepatic artery embolization for the treatment of esophagogastric varices and hepatocellular carcinoma in patients with cirrhosis: Preliminary report. *Cardiovasc Intervent Radiol* 1995; **18**: 9-15