

World Journal of *Clinical Cases*

World J Clin Cases 2021 November 26; 9(33): 10052-10391



Contents

Thrice Monthly Volume 9 Number 33 November 26, 2021

REVIEW

- 10052** Effects of alcohol consumption on viral hepatitis B and C
Xu HQ, Wang CG, Zhou Q, Gao YH

MINIREVIEWS

- 10064** Effects of anti-diabetic drugs on sarcopenia: Best treatment options for elderly patients with type 2 diabetes mellitus and sarcopenia
Ma XY, Chen FQ

ORIGINAL ARTICLE

Retrospective Cohort Study

- 10075** Utility of cooling patches to prevent hand-foot syndrome caused by pegylated liposomal doxorubicin in breast cancer patients
Zheng YF, Fu X, Wang XX, Sun XJ, He XD

Retrospective Study

- 10088** Clinicopathological features of small T1 colorectal cancers
Takashina Y, Kudo SE, Ichimasa K, Kouyama Y, Mochizuki K, Akimoto Y, Maeda Y, Mori Y, Misawa M, Ogata N, Kudo T, Hisayuki T, Hayashi T, Wakamura K, Sawada N, Baba T, Ishida F, Yokoyama K, Daita M, Nemoto T, Miyachi H
- 10098** Comparison of dental pulp periodontal therapy and conventional simple periodontal therapy as treatment modalities for severe periodontitis
Li L, Chen HJ, Lian Y, Wang T
- 10106** Tripartite intensive intervention for prevention of rebleeding in elderly patients with hypertensive cerebral hemorrhage
Li CX, Li L, Zhang JF, Zhang QH, Jin XH, Cai GJ
- 10116** Clinical and electroencephalogram characteristics and treatment outcomes in children with benign epilepsy and centrotemporal spikes
Chen RH, Li BF, Wen JH, Zhong CL, Ji MM
- 10126** Endoscopic ultrasonography diagnosis of gastric glomus tumors
Bai B, Mao CS, Li Z, Kuang SL
- 10134** Learning curves of robot-assisted pedicle screw fixations based on the cumulative sum test
Yu J, Zhang Q, Fan MX, Han XG, Liu B, Tian W
- 10143** Value of GRACE and SYNTAX scores for predicting the prognosis of patients with non-ST elevation acute coronary syndrome
Wang XF, Zhao M, Liu F, Sun GR

- 10151** Effectiveness of enhanced recovery after surgery in the perioperative management of patients with bone surgery in China

Zhao LY, Liu XT, Zhao ZL, Gu R, Ni XM, Deng R, Li XY, Gao MJ, Zhu WN

Clinical Trials Study

- 10161** Association between plasma dipeptidyl peptidase-4 levels and cognitive function in perinatal pregnant women with gestational diabetes mellitus

Sana SRGL, Li EY, Deng XJ, Guo L

- 10172** Paricalcitol in hemodialysis patients with secondary hyperparathyroidism and its potential benefits

Chen X, Zhao F, Pan WJ, Di JM, Xie WN, Yuan L, Liu Z

Observational Study

- 10180** Did the severe acute respiratory syndrome-coronavirus 2 pandemic cause an endemic *Clostridium difficile* infection?

Cojocariu C, Girleanu I, Trifan A, Olteanu A, Muzica CM, Huiban L, Chiriac S, Singeap AM, Cuciureanu T, Sfarti C, Stanciu C

- 10189** Effect of nursing intervention based on Maslow's hierarchy of needs in patients with coronary heart disease interventional surgery

Xu JX, Wu LX, Jiang W, Fan GH

- 10198** Impacts of statin and metformin on neuropathy in patients with type 2 diabetes mellitus: Korean Health Insurance data

Min HK, Kim SH, Choi JH, Choi K, Kim HR, Lee SH

META-ANALYSIS

- 10208** Is endoscopic retrograde appendicitis therapy a better modality for acute uncomplicated appendicitis? A systematic review and meta-analysis

Wang Y, Sun CY, Liu J, Chen Y, Bhan C, Tuason JPW, Misra S, Huang YT, Ma SD, Cheng XY, Zhou Q, Gu WC, Wu DD, Chen X

- 10222** Prognostic value of ground glass opacity on computed tomography in pathological stage I pulmonary adenocarcinoma: A meta-analysis

Pan XL, Liao ZL, Yao H, Yan WJ, Wen DY, Wang Y, Li ZL

CASE REPORT

- 10233** Atrial fibrillation and concomitant left subclavian, axillary and brachial artery embolism after fiberoptic bronchoscopy: A case report

Yang CL, Zhou R, Jin ZX, Chen M, Zi BL, Li P, Zhou KH

- 10238** Streptococcal toxic shock syndrome after hemorrhoidectomy: A case report

Lee CY, Lee YJ, Chen CC, Kuo LJ

- 10244** Subsequent placenta accreta after previous mifepristone-induced abortion: A case report

Zhao P, Zhao Y, He J, Bai XX, Chen J

- 10249** Autosomal dominant tubulointerstitial kidney disease with a novel heterozygous missense mutation in the uromodulin gene: A case report
Zhang LL, Lin JR, Zhu TT, Liu Q, Zhang DM, Gan LW, Li Y, Ou ST
- 10257** Novel KDM6A mutation in a Chinese infant with Kabuki syndrome: A case report
Guo HX, Li BW, Hu M, Si SY, Feng K
- 10265** Pancreatic cancer with synchronous liver and colon metastases: A case report
Dong YM, Sun HN, Sun DC, Deng MH, Peng YG, Zhu YY
- 10273** Veno-venous-extracorporeal membrane oxygenation treatment for severe capillary leakage syndrome: A case report
Nong WX, Lv QJ, Lu YS
- 10279** Anticoagulant treatment for pulmonary embolism in patient with cerebral hemorrhage secondary to mechanical thrombectomy: A case report
Chen XT, Zhang Q, Zhou CQ, Han YF, Cao QQ
- 10286** Complete restoration of congenital conductive hearing loss by staged surgery: A case report
Yoo JS, Lee CM, Yang YN, Lee EJ
- 10293** Blastic plasmacytoid dendritic cell neoplasm with skin and bone marrow involvement: Report of three cases
Guo JH, Zhang HW, Wang L, Bai W, Wang JF
- 10300** Extracranial multiorgan metastasis from primary glioblastoma: A case report
Luan XZ, Wang HR, Xiang W, Li SJ, He H, Chen LG, Wang JM, Zhou J
- 10308** Transverse myelitis after infection with varicella zoster virus in patient with normal immunity: A case report
Yun D, Cho SY, Ju W, Seo EH
- 10315** Duodenal ulcer caused by coil wiggle after digital subtraction angiography-guided embolization: A case report
Xu S, Yang SX, Xue ZX, Xu CL, Cai ZZ, Xu CZ
- 10323** Crab lice infestation in unilateral eyelashes and adjacent eyelids: A case report
Tang W, Li QQ
- 10328** Local random flaps for cervical circumferential defect or tracheoesophageal fistula reconstruction after failed gastric pull-up: Two case reports
Zhang Y, Liu Y, Sun Y, Xu M, Wang XL
- 10337** Incurable and refractory spinal cystic echinococcosis: A case report
Zhang T, Ma LH, Liu H, Li SK
- 10345** Individualized treatment of breast cancer with chronic renal failure: A case report and review of literature
Cai JH, Zheng JH, Lin XQ, Lin WX, Zou J, Chen YK, Li ZY, Chen YX

- 10355** Persistent fibrinogen deficiency after snake bite: A case report
Xu MH, Li J, Han L, Chen C
- 10362** Successful prolonged cardiopulmonary resuscitation after intraoperative cardiac arrest due to povidone-iodine allergy: A case report
Xiang BB, Yao YT, Jiao SL
- 10369** Clinical algorithm for preventing missed diagnoses of occult cervical spine instability after acute trauma: A case report
Zhu C, Yang HL, Im GH, Liu LM, Zhou CG, Song YM
- 10374** Carbon ion radiotherapy for synchronous choroidal melanoma and lung cancer: A case report
Zhang YS, Hu TC, Ye YC, Han JH, Li XJ, Zhang YH, Chen WZ, Chai HY, Pan X, Wang X, Yang YL
- 10382** Heart failure as an adverse effect of infliximab for Crohn's disease: A case report and review of the literature
Grillo TG, Almeida LR, Beraldo RF, Marcondes MB, Queiróz DAR, da Silva DL, Quera R, Baima JP, Saad-Hossne R, Sasaki LY

ABOUT COVER

Editorial Board Member of *World Journal of Clinical Cases*, Jian-Wu Zhao, PhD, Chief Physician, Professor, Department of Orthopedics, Jilin University Second Hospital, Changchun 130000, Jilin Province, China. jianwu@jlu.edu.cn

AIMS AND SCOPE

The primary aim of *World Journal of Clinical Cases* (WJCC, *World J Clin Cases*) is to provide scholars and readers from various fields of clinical medicine with a platform to publish high-quality clinical research articles and communicate their research findings online.

WJCC mainly publishes articles reporting research results and findings obtained in the field of clinical medicine and covering a wide range of topics, including case control studies, retrospective cohort studies, retrospective studies, clinical trials studies, observational studies, prospective studies, randomized controlled trials, randomized clinical trials, systematic reviews, meta-analysis, and case reports.

INDEXING/ABSTRACTING

The WJCC is now indexed in Science Citation Index Expanded (also known as SciSearch®), Journal Citation Reports/Science Edition, Scopus, PubMed, and PubMed Central. The 2021 Edition of Journal Citation Reports® cites the 2020 impact factor (IF) for WJCC as 1.337; IF without journal self cites: 1.301; 5-year IF: 1.742; Journal Citation Indicator: 0.33; Ranking: 119 among 169 journals in medicine, general and internal; and Quartile category: Q3. The WJCC's CiteScore for 2020 is 0.8 and Scopus CiteScore rank 2020: General Medicine is 493/793.

RESPONSIBLE EDITORS FOR THIS ISSUE

Production Editor: Ji-Hong Lin; Production Department Director: Xiang Li; Editorial Office Director: Jin-Lai Wang.

NAME OF JOURNAL

World Journal of Clinical Cases

ISSN

ISSN 2307-8960 (online)

LAUNCH DATE

April 16, 2013

FREQUENCY

Thrice Monthly

EDITORS-IN-CHIEF

Dennis A Bloomfield, Sandro Vento, Bao-Gan Peng

EDITORIAL BOARD MEMBERS

<https://www.wjnet.com/2307-8960/editorialboard.htm>

PUBLICATION DATE

November 26, 2021

COPYRIGHT

© 2021 Baishideng Publishing Group Inc

INSTRUCTIONS TO AUTHORS

<https://www.wjnet.com/bpg/gerinfo/204>

GUIDELINES FOR ETHICS DOCUMENTS

<https://www.wjnet.com/bpg/GerInfo/287>

GUIDELINES FOR NON-NATIVE SPEAKERS OF ENGLISH

<https://www.wjnet.com/bpg/gerinfo/240>

PUBLICATION ETHICS

<https://www.wjnet.com/bpg/GerInfo/288>

PUBLICATION MISCONDUCT

<https://www.wjnet.com/bpg/gerinfo/208>

ARTICLE PROCESSING CHARGE

<https://www.wjnet.com/bpg/gerinfo/242>

STEPS FOR SUBMITTING MANUSCRIPTS

<https://www.wjnet.com/bpg/GerInfo/239>

ONLINE SUBMISSION

<https://www.f6publishing.com>

Atrial fibrillation and concomitant left subclavian, axillary and brachial artery embolism after fiberoptic bronchoscopy: A case report

Cui-Lin Yang, Ran Zhou, Zhi-Xian Jin, Min Chen, Bao-Li Zi, Ping Li, Kai-Hua Zhou

ORCID number: Cui-Lin Yang 0000-0002-4761-4144; Ran Zhou 0000-0002-4738-4596; Zhi-Xian Jin 0000-0003-2497-4718; Min Chen 0000-0002-2334-8726; Bao-Li Zi 0000-0002-4875-435X; Ping Li 0000-0003-2821-6754; Kai-Hua Zhou 0000-0002-9256-3171.

Author contributions: Chen M and Jin ZX were the attending physicians for the patient, reviewed the literature, and contributed to writing the manuscript; Zi BL and Li P reviewed the literature and contributed to writing the manuscript; Zhou KH performed the bronchoscopy procedure and contributed to manuscript writing; Zhou R was responsible for revising the manuscript for important intellectual content; all authors approved the final submitted version of the manuscript.

Informed consent statement: Written informed consent was obtained from the patient for publication of this report and any accompanying images.

Conflict-of-interest statement: The authors declare that they have no conflicts of interest.

CARE Checklist (2016) statement:

Cui-Lin Yang, Zhi-Xian Jin, Min Chen, Bao-Li Zi, Ping Li, Kai-Hua Zhou, Department of Respiratory, Kunming Municipal First People's Hospital, Kunming 650000, Yunnan Province, China

Ran Zhou, Department of Respiratory, The First People's Hospital of Yunnan Province, Kunming 650000, Yunnan Province, China

Corresponding author: Kai-Hua Zhou, MM, Chief Physician, Department of Respiratory, Kunming Municipal First People's Hospital, No. 1288 Beijing Road, Kunming 650000, Yunnan Province, China. zkh51033528@sina.com

Abstract

BACKGROUND

Fiberoptic bronchoscopy has been widely used in the diagnosis and treatment of respiratory diseases. Numerous major and minor complications have been reported following this procedure. The incidence of major postoperative complications is approximately 0.5% and includes respiratory depression, pneumothorax, pulmonary edema, pneumonia, airway obstruction and cardiorespiratory arrest. Minor complications include vasovagal reactions, cardiac arrhythmias, hemorrhage, pneumothorax, aphonia, nausea, vomiting and fever. However, to our knowledge, a case of atrial fibrillation (AF) concomitant with fatal arterial embolism in the upper extremities following diagnostic bronchoscopy has never been reported.

CASE SUMMARY

A 70-year-old female patient presented with a history of rheumatic heart disease beginning at 10 years of age and an approximately 10-year history of hypertension. The patient was transferred from the cardiology department to the respiratory department due to recurrent coughing, pneumonia, and fever. She underwent fiberoptic bronchoscopy in the respiratory department. Approximately 2 h after completion of bronchoscopy, she complained of left arm numbness and weakness. Physical examination detected cyanosis of the left upper extremity, grade III weakened limb muscle strength, and undetectable left brachial artery pulsation. Auscultation indicated AF. B-mode ultrasound examination of the blood vessels showed hyperechoic material in the left subclavian, axillary and brachial arteries, and parallel veins. As our hospital has

The authors have read the CARE checklist (2016), and the manuscript was prepared and revised according to the CARE Checklist (2016).

Country/Territory of origin: China

Specialty type: Medicine, research and experimental

Provenance and peer review: Unsolicited article; Externally peer reviewed.

Peer-review report's scientific quality classification

Grade A (Excellent): 0
Grade B (Very good): B
Grade C (Good): 0
Grade D (Fair): 0
Grade E (Poor): 0

Open-Access: This article is an open-access article that was selected by an in-house editor and fully peer-reviewed by external reviewers. It is distributed in accordance with the Creative Commons Attribution NonCommercial (CC BY-NC 4.0) license, which permits others to distribute, remix, adapt, build upon this work non-commercially, and license their derivative works on different terms, provided the original work is properly cited and the use is non-commercial. See: <http://creativecommons.org/licenses/by-nc/4.0/>

Received: November 13, 2020

Peer-review started: November 13, 2020

First decision: July 8, 2021

Revised: August 4, 2021

Accepted: September 13, 2021

Article in press: September 13, 2021

Published online: November 26, 2021

P-Reviewer: Patel VJ

S-Editor: Gao CC

L-Editor: Kerr C

P-Editor: Ma YJ



no vascular surgery capability, the patient was transferred to a specialized hospital for emergency thrombectomy that day. A tracking investigation found that the patient's conditions improved after successful thrombectomy.

CONCLUSION

Thromboembolism following bronchoscopy is rare, and only a few cases of cerebral air embolism after bronchoscopy have been reported.

Key Words: Fiberoptic bronchoscopy; Complications; Atrial fibrillation; Thromboembolism; Anticoagulant therapy; Case report

©The Author(s) 2021. Published by Baishideng Publishing Group Inc. All rights reserved.

Core Tip: This case highlights the fact that although fiberoptic bronchoscopy is generally a well-known and safe procedure, serious complications, such as arterial thrombosis may occur. The risk of developing arterial thrombosis following bronchoscopy is higher in patients with atrial fibrillation with mitral stenosis, highlighting the need for a rigorous risk assessment in these patients.

Citation: Yang CL, Zhou R, Jin ZX, Chen M, Zi BL, Li P, Zhou KH. Atrial fibrillation and concomitant left subclavian, axillary and brachial artery embolism after fiberoptic bronchoscopy: A case report. *World J Clin Cases* 2021; 9(33): 10233-10237

URL: <https://www.wjgnet.com/2307-8960/full/v9/i33/10233.htm>

DOI: <https://dx.doi.org/10.12998/wjcc.v9.i33.10233>

INTRODUCTION

Fiberoptic bronchoscopy is a well-tolerated, minimally invasive surgical procedure, which has been widely used in the diagnosis and treatment of respiratory diseases[1]. For diagnostic purposes, bronchoscopy permits a visual inspection of the tracheo-bronchial tree and removal of tissue samples for biopsy. Therapeutically, bronchoscopy is used to remove secretions and to aspirate foreign bodies from the interior of the bronchi[2]. Although fiberoptic bronchoscopy is an established and commonly used procedure, there are several postoperative complications that may arise, including hemoptysis, bleeding, pneumothorax and bronchospasm[3]. Anecdotal evidence has been reported describing the occurrence of arterial cerebral air embolism following diagnostic flexible fiberoptic bronchoscopy[4-6]. However, to our knowledge, atrial fibrillation (AF) with concomitant embolism of the left subclavian artery, axillary artery, and brachial artery as a postoperative complication following fiberoptic bronchoscopy has not been reported.

CASE PRESENTATION

Chief complaints

A 70-year-old female patient was admitted to the Department of Cardiology due to complaints of repeated dizziness over a 10-year period and shortness of breath and cough for 1 year. These symptoms progressed over a 1-mo period.

History of present illness

The patient was transferred from the Cardiology Department to the Respiratory Department due to recurrent cough, fever, and multiple lesions identified on computed tomography (CT) in both lungs. Physicians recommended fiberoptic bronchoscopy for further diagnosis. Two hours after completion of the operation, the patient complained of exacerbation of left arm numbness and weakness. The skin of the left upper extremity was found to be cyanotic, muscle strength decreased to grade 3, and the left brachial artery pulsation was not detectable. B-mode ultrasound examination of the blood vessels revealed hyperechoic material in the left subclavian

artery, axillary artery, brachial artery, and parallel veins (Figure 1A, B). Based on the patient's symptoms, history of rheumatic heart disease, and ultrasound images, we diagnosed embolism in the left upper extremity. As our hospital has no vascular surgery capability, the patient was transferred on the same day to a specialized hospital for an emergency thrombectomy. A tracking investigation found that the patient's conditions improved after successful thrombectomy. The numbness in the left upper limb disappeared, and muscle strength and skin color returned to normal.

History of past illness

The patient had a history of rheumatic heart disease at age 10 years with hypertension as high as 160/110 mmHg, which was well controlled through oral amlodipine tablets.

Personal and family history

The patient had no pertinent family history.

Physical examination

Vital signs of the patient appeared stable during bronchoscopy, except for minor coughing. Blood pressure was 128/80 mmHg, heart rate was 80–105 beats/min with signs of AF, peripheral capillary oxygen saturation (SpO₂) was 95%–98%, respiratory rate was 20 breaths/min, and temperature was 36.5°C, 2 h after the examination. The patient complained of numbness in the left arm and difficulty stretching the fingers of her left hand. Her skin in the left upper extremity was cyanotic; muscle strength decreased to grade 3; and the left brachial artery pulsation was not detectable.

Laboratory examinations

Five coagulation tests on the first day of admission revealed a prothrombin time (PT) of 13.6 s, an activated partial thromboplastin time (APTT) of 23.4 s, a thrombin time (TT) of 16.6 s, an international normalized ratio (INR) of 1.19, and fibrinogen (FIB) levels of 5.12 g/L. Emergency coagulation tests after bronchoscopy showed a PT of 12.3 s, an APTT of 22.7 s, a TT of 17.2 s, and an INR of 0.89. The FIB concentration was 6 g/L (reference range 2–4 g/L), D-dimer was 8.13 mg/L (reference range 0–0.55 g/L), the potassium level was 3.36 mmol/L (reference range 3.5–5.3 mmol/L), lactate dehydrogenase was 439 U/L (reference range 90–250 U/L), and troponin I was 0.216 g/L (reference range 0.006–0.06 g/L).

Imaging examinations

Color doppler ultrasound indicated the presence of rheumatic heart disease, moderate mitral valve stenosis, and moderate insufficiency, left atrium enlargement, decreased left ventricular diastolic and systolic function, moderate tricuspid valve regurgitation, severe pulmonary hypertension, and minor pericardial effusion. Chest CT detected multiple nodules and exudative lesions in both lungs, as well as local swelling of the left upper lung lobe. The bronchoscopy examination detected branch stenosis in the anterior segment of the right upper lobe, chronic inflammation in the right upper lobe, and inflammatory infiltration in the upper apicoposterior segment.

FINAL DIAGNOSIS

Based on the patients' symptoms, history of rheumatic heart disease, and ultrasound images, the patient was finally diagnosed with AF with concomitant left subclavian artery, axillary artery, and brachial artery embolism after fiberoptic bronchoscopy.

TREATMENT

Since our hospital is not equipped for vascular surgery, the patient was transferred on the same day to a specialized hospital for emergency thrombectomy.

OUTCOME AND FOLLOW-UP

A tracking investigation found that the patient's conditions improved after successful thrombectomy. Left upper limb numbness disappeared, while muscle strength and

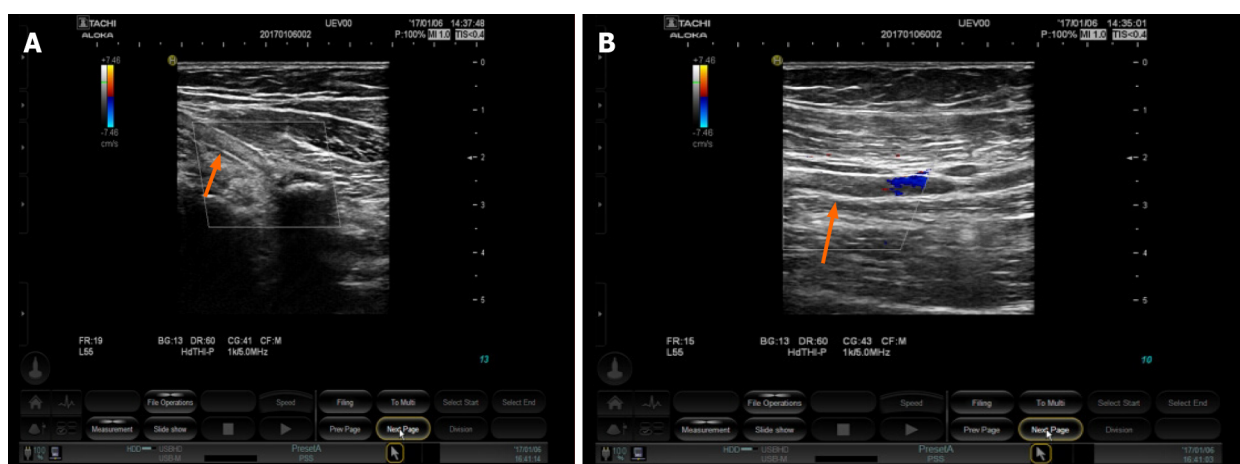


Figure 1 B-mode ultrasound examination of blood vessels showed hyperechoic material. A: Brachial artery; B: Axillary artery.

skin color returned to normal.

DISCUSSION

The most likely cause behind the formation of an upper extremity embolism in the case presented was the detachment of an atrial embolus induced by AF combined with an accelerated heartbeat throughout the bronchoscopy procedure. Physical examination showed an AF rhythm after bronchoscopy. The patient had a long history of rheumatic heart disease, and echocardiography indicated moderate mitral stenosis with mild mitral regurgitation. Studies have shown that ~20% of patients with mitral stenosis had thromboembolism, and ~80% of patients with thrombosis had AF[7]. Thus, AF, mitral stenosis, and thromboembolism are closely related.

AF is one of the most common arrhythmias and is the main complication in thromboembolism. The 2019 AHA/ACC/HRS updated guidelines for the management of patients with AF recognize the damage caused by thromboembolism due to AF and provide new recommendations for the prevention and treatment of thromboembolism[8]. Valvular AF is defined in the guidelines as AF that occurs in the setting of moderate-to-severe mitral stenosis (potentially requiring surgical intervention) or in the presence of an artificial (mechanical) heart valve. Valvular AF also may be considered as an indication for long-term anticoagulation therapy with warfarin. Our patient had AF and moderate mitral stenosis (mitral valve area 1.1 cm²), which is defined as valvular AF requiring long-time warfarin anticoagulation therapy. However, since the patient did not receive anticoagulant therapy, the surgical procedure may have induced detachment of the embolus, leading to the formation of an embolism in the upper limb.

AF is not an absolute contraindication for fiberoptic bronchoscopy. According to the 2019 American AF guidelines, if a patient with AF or a mechanical heart valve requires temporary interruption of warfarin treatment during an elective invasive procedure or surgery, bridging therapy that includes unfractionated heparin or low molecular weight heparin is recommended. The decision on bridging therapy should balance the risks of stroke and bleeding.

CONCLUSION

This case highlights the importance of anticoagulation prior to fiberoptic bronchoscopy in patients with AF. Numerous guidelines recommend an oral anticoagulant, especially warfarin, as the first choice for patients with AF[9]. To achieve optimum results and to reduce the risks of bleeding and thromboembolism, the recommended INR for warfarin treatment is between 2.0 and 3.0. At this dose, the relative risk of stroke is reduced by 64%, and all-cause mortality may be significantly reduced by 26%. However, the utilization rate of oral anticoagulants in China is lower than in western countries[10]. The current utilization rate of warfarin-based antithrombotic therapy in Chinese patients with non-valvular AF is below 10%. Various

reasons have been attributed to the low utilization rate of anticoagulation therapy in Chinese patients with AF, including the narrow safety window of warfarin, which results in poor compliance and extra coagulation monitoring and dose adjustments required due to the constant INR variations. GARFIELD global research has shown that the lack of effective long-term management and safety concerns of anticoagulant therapy results in approximately half of all eligible patients not receiving anticoagulant therapy[11]. Therefore, physicians have an important role in improving the acceptance and usage of anticoagulation therapy in patients with AF.

ACKNOWLEDGMENTS

We thank the Ultrasound team of Kunming Municipal First People's Hospital for providing the images for this manuscript.

REFERENCES

- 1 **Costa ADS Jr**, Scordamaglio PR, Suzuki I, Palomino ALM, Jacomelli M. Indications, clinical outcomes and complications of 1,949 flexible bronchoscopies. *Einstein (Sao Paulo)* 2018; **16**: eAO4380 [PMID: 30427487 DOI: 10.31744/einstein_journal/2018AO4380]
- 2 **Huang PM**, Kao MW. Endobronchial foreign body removed by flexible bronchoscopy using the Trendelenburg position. *Thorac Cardiovasc Surg* 2012; **60**: 545-547 [PMID: 22207366 DOI: 10.1055/s-0031-1293598]
- 3 **Leiten EO**, Martinsen EM, Bakke PS, Eagan TM, Grønseth R. Complications and discomfort of bronchoscopy: a systematic review. *Eur Clin Respir J* 2016; **3**: 33324 [PMID: 27839531 DOI: 10.3402/ecrj.v3.33324]
- 4 **Maemura K**, Kage H, Isago H, Takeshima H, Makita K, Amano Y, Takai D, Ohishi N, Nagase T. Cerebral Arterial Air Embolism after Diagnostic Flexible Fiberoptic Bronchoscopy: A Case Report and Review of the Literature. *Case Rep Pulmonol* 2018; **2018**: 7108215 [PMID: 29854532 DOI: 10.1155/2018/7108215]
- 5 **Azzola A**, von Garnier C, Chhajed PN, Schirp U, Tamm M. Fatal cerebral air embolism following uneventful flexible bronchoscopy. *Respiration* 2010; **80**: 569-572 [PMID: 21079412 DOI: 10.1159/000321849]
- 6 **Toyota H**, Kobayashi K, Matsukura S, Kawamura Y, Kanda T, Arai H, Nagase H, Yamaguchi M. A Case of Cerebral Air Embolism During Diagnostic Flexible Bronchoscopy. *J Bronchology Interv Pulmonol* 2019; **26**: e58-e60 [PMID: 31569105 DOI: 10.1097/LBR.0000000000000608]
- 7 **Giugliano RP**, O'Gara PT. DOACs in Patients With Mitral Stenosis and Atrial Fibrillation: Time for a Randomized Clinical Trial. *J Am Coll Cardiol* 2019; **73**: 1132-1134 [PMID: 30871696 DOI: 10.1016/j.jacc.2018.12.048]
- 8 **January CT**, Wann LS, Calkins H, Chen LY, Cigarroa JE, Cleveland JC Jr, Ellinor PT, Ezekowitz MD, Field ME, Furie KL, Heidenreich PA, Murray KT, Shea JB, Tracy CM, Yancy CW. 2019 AHA/ACC/HRS Focused Update of the 2014 AHA/ACC/HRS Guideline for the Management of Patients With Atrial Fibrillation: A Report of the American College of Cardiology/American Heart Association Task Force on Clinical Practice Guidelines and the Heart Rhythm Society in Collaboration With the Society of Thoracic Surgeons. *Circulation* 2019; **140**: e125-e151 [PMID: 30686041 DOI: 10.1161/CIR.0000000000000665]
- 9 **Katz DF**, Maddox TM, Turakhia M, Gehi A, O'Brien EC, Lubitz SA, Turchin A, Doros G, Lei L, Varosy P, Marzec L, Hsu JC. Contemporary Trends in Oral Anticoagulant Prescription in Atrial Fibrillation Patients at Low to Moderate Risk of Stroke After Guideline-Recommended Change in Use of the CHADS₂ to the CHA₂DS₂-VASc Score for Thromboembolic Risk Assessment: Analysis From the National Cardiovascular Data Registry's Outpatient Practice Innovation and Clinical Excellence Atrial Fibrillation Registry. *Circ Cardiovasc Qual Outcomes* 2017; **10** [PMID: 28506981 DOI: 10.1161/CIRCOUTCOMES.116.003476]
- 10 **Sun Y**, Hu D; Chinese Investigators of GARFIELD; Chinese Investigators of GARFIELD. [Chinese subgroup analysis of the global anticoagulant registry in the FIELD (GARFIELD) registry in the patients with non-valvular atrial fibrillation]. *Zhonghua Xin Xue Guan Bing Za Zhi* 2014; **42**: 846-850 [PMID: 25549561]
- 11 **Weitz JI**, Haas S, Ageno W, Angchaisuksiri P, Bounameaux H, Nielsen JD, Goldhaber SZ, Goto S, Kayani G, Mantovani L, Prandoni P, Schellong S, Turpie AG, Kakkar AK. Global Anticoagulant Registry in the Field - Venous Thromboembolism (GARFIELD-VTE). Rationale and design. *Thromb Haemost* 2016; **116**: 1172-1179 [PMID: 27656711 DOI: 10.1160/TH16-04-0335]



Published by **Baishideng Publishing Group Inc**
7041 Koll Center Parkway, Suite 160, Pleasanton, CA 94566, USA

Telephone: +1-925-3991568

E-mail: bpgoffice@wjgnet.com

Help Desk: <https://www.f6publishing.com/helpdesk>

<https://www.wjgnet.com>

