

国内版国际版

Microsoft Bing

Human Hepatitis Viruses-associated Cutaneous and Systemic Vasc

Image icon

Voice icon

Search icon

Chat with Bing

Sign in

Menu icon

ALLIMAGESVIDEOS

546,000 ResultsAny time

Small vessel vasculitis caused by hepatitis B virus immune ...

<https://pubmed.ncbi.nlm.nih.gov/701656>

In a comprehensive study of 80 patients with vasculitis, 4 had concurrent hepatitis B virus (HBV) infection. Polyarteritis nodosa was present in 2 and in the other 2, cutaneous vasculitis, presenting clinically as palpable or Henoch-Schönlein purpura. In one of these patients skin biopsies demonstra ...

Cited by: 134Author: Richard G. Gower, Richard G. Gower, Willia...Publish Year: 1978

Vasculitic syndromes in hepatitis C virus: A review ...

<https://www.sciencedirect.com/science/article/pii/S2090123216301023>

Mar 01, 2017 · In the literature, few studies discussed systemic vasculitis induced by HCV without evidence of cryoglobulinemia, most prescribed is HCV related PAN. HCV related PAN PAN is a medium sized necrotizing vasculitis classically related to HBV, but ...

Cited by: 16Author: Gaafar Ragab, Mohamed A. HusseinPublish Year: 2017

Search Tools

Turn off Hover Translation (关闭取词)

Images of Human Hepatitis Viruses-associated Cutaneous and Sy...

<bing.com/images>

国内版 国际版

Bing

Human hepatitis viruses-associated cutaneous and systemic vasculit



ALL

IMAGES

VIDEOS

541,000 Results

Any time ▾

[Hepatotropic viral infection associated systemic ...](#)

<https://pubmed.ncbi.nlm.nih.gov/25755502>

Hepatotropic viral infection associated **systemic** vasculitides-**hepatitis** B virus associated polyarteritis nodosa and **hepatitis** C virus associated cryoglobulinemic **vasculitis** J Clin Exp Hepatol . 2013 Sep;3(3):204-12. doi: 10.1016/j.jceh.2013.06.001.

Cited by: 12

Author: Aman Sharma, Kusum Sharma

Publish Year: 2013

[Vasculitic syndromes in hepatitis C virus: A review ...](#)

<https://www.sciencedirect.com/science/article/pii/S2090123216301023>

Mar 01, 2017 · In the literature, few studies discussed systemic vasculitis induced by **HCV** without evidence of cryoglobulinemia, most prescribed is **HCV** related PAN. **HCV** related PAN PAN is a medium sized necrotizing vasculitis classically related to **HBV**, but to a lesser extent can be found in **HCV** ...

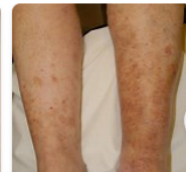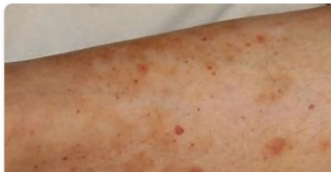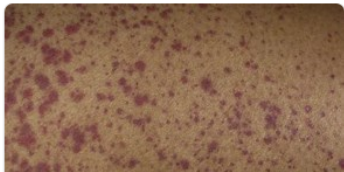
Cited by: 16

Author: Gaafar Ragab, Mohamed A. Hussein

Publish Year: 2017

[Images of Human Hepatitis Viruses-associated Cutaneous an...](#)

<bing.com/images>



Name of Journal: *World Journal of Gastroenterology*

Manuscript NO: 60654

Manuscript Type: REVIEW

Human hepatitis viruses-associated cutaneous and systemic vasculitis

Chrong-Reen Wang, Hung-Wen Tsai

Abstract

Human hepatitis viruses (HHVs) include hepatitis A virus, hepatitis B virus (HBV), hepatitis C virus (HCV), hepatitis delta virus, and hepatitis E virus and can cause liver inflammation in their common human host. Usually, HHV is rapidly cleared by the immune system, following acute HHV invasion. The morbidities associated with hepatitis A virus and hepatitis E virus infection occur shortly after their intrusion, in the acute stage. Nevertheless, the viral infectious process can persist for a long period of time, especially in HBV and

Match Overview

1	Internet 33 words crawled on 07-Jun-2020 www.tandfonline.com	1%
2	Internet 25 words crawled on 14-Jul-2020 shopplayer.net	<1%
3	Crossref 20 words Filipa Silva, Claudemira Pinto, Arsénio Barbosa, Tiago Bo... es, Carlos Dias, Jorge Almeida. "New insights in cryoglobuli	<1%
4	Crossref 19 words Patrice Calcoub, Benjamin Terrier. "Hepatitis B-Related Ai... Immune Manifestations", Rheumatic Disease Clinics of Nor	<1%
5	Internet 15 words crawled on 27-Nov-2020 test.dovepress.com	<1%
6	Crossref 15 words "Rook's Textbook of Dermatology", Wiley, 2010	<1%
7	Crossref 14 words Watts, R.A. "Vasculitis", Best Practice & Resea... Rheumatology, 199508	56% +0.2% +18.9%
8	Internet 14 words crawled on 06-Oct-2020	激活 Windows <1%

国内版 国际版

Human hepatitis viruses-associated cutaneous and systemic vasc



ALL IMAGES VIDEOS

536,000 Results Any time ▾

Small vessel vasculitis caused by hepatitis B virus immune ...

<https://pubmed.ncbi.nlm.nih.gov/701656>

In a comprehensive study of 80 patients with **vasculitis**, 4 had concurrent **hepatitis B virus (HBV)** infection. Polyarteritis nodosa was present in 2 and in the other 2, **cutaneous vasculitis**, presenting clinically as palpable or Henoch-Schönlein purpura. In one of these patients **skin** ...

Cited by: 133

Author: Richard G. Gower, Richard G. Gower, Wi...

Publish Year: 1978

Hepatotropic viral infection associated systemic ...

<https://pubmed.ncbi.nlm.nih.gov/25755502>

Hepatotropic viral infection associated **systemic vasculitides-hepatitis B virus associated** polyarteritis nodosa and **hepatitis C virus associated cryoglobulinemic vasculitis** J Clin Exp Hepatol . 2013 Sep;3(3):204-12. doi: 10.1016/j.jceh.2013.06.001.

Cited by: 12

Author: Aman Sharma, Kusum Sharma

Publish Year: 2013

Images of Human Hepatitis Viruses-associated Cutaneous and Syst...

<bing.com/images>

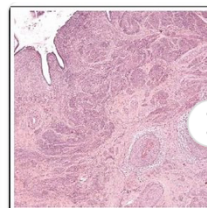
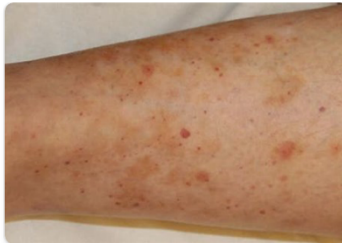
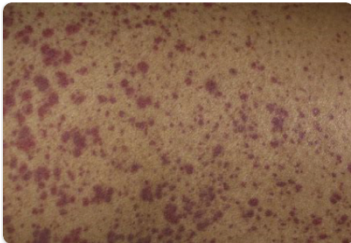


Figure 1. Histology of the uterine cervix showing an i
trate affecting the arteries. Hematoxylin-eosin stain. 5