

World Journal of *Gastrointestinal Surgery*

World J Gastrointest Surg 2019 August 27; 11(8): 334-357





SYSTEMATIC REVIEWS

- 334** Systematic review of anorectal leiomyosarcoma: Current challenges and recent advances
Nassif MO, Habib RA, Almarzouki LZ, Trabulsi NH

CASE REPORT

- 342** Acute epiploic appendagitis at the tip of the appendix mimicking acute appendicitis: A rare case report with literature review
Huang K, Waheed A, Juan W, Misra S, Alpendre C, Jones S
- 348** Doege-Potter syndrome by malignant solitary fibrous tumor of the liver: A case report and review of literature
Antonella D, Loren D, Maria C, Felicia F, Stefano L, Umberto R, Antonella C, Bianca P, Anna C, Leonardo R, Riccardo M

Contents

World Journal of Gastrointestinal Surgery
Volume 11 Number 8 August 27, 2019

ABOUT COVER

Associate Editor of *World Journal of Gastrointestinal Surgery*, Chiara Mussi, MD, Research Fellow, Unita Operativa di Chirurgia Generale ed Oncologica, IRCCS, Istituto Clinico Humanitas, Rozzano 20089, Italy

AIMS AND SCOPE

World Journal of Gastrointestinal Surgery (*World J Gastrointest Surg*, *WJGS*, online ISSN 1948-9366, DOI: 10.4240) is a peer-reviewed open access academic journal that aims to guide clinical practice and improve diagnostic and therapeutic skills of clinicians.

The *WJGS* covers topics concerning micro-invasive surgery; laparoscopy; hepatic, biliary, pancreatic and splenic surgery; surgical nutrition; portal hypertension, as well as associated subjects. The current columns of *WJGS* include editorial, frontier, diagnostic advances, therapeutics advances, field of vision, mini-reviews, review, original articles, case report, etc.

We encourage authors to submit their manuscripts to *WJGS*. We will give priority to manuscripts that are supported by major national and international foundations and those that are of great basic and clinical significance.

INDEXING/ABSTRACTING

The *WJGS* is now abstracted and indexed in PubMed, PubMed Central, Emerging Sources Citation Index (Web of Science), China National Knowledge Infrastructure (CNKI), China Science and Technology Journal Database (CSTJ), and Superstar Journals Database.

RESPONSIBLE EDITORS FOR THIS ISSUE

Responsible Electronic Editor: *Bao-Xia Zhou*

Proofing Production Department Director: *Yun-Xiao Jian Wu*

NAME OF JOURNAL

World Journal of Gastrointestinal Surgery

ISSN

ISSN 1948-9366 (online)

LAUNCH DATE

November 30, 2009

FREQUENCY

Monthly

EDITORS-IN-CHIEF

Varut Lohsiriwat, Shu-You Peng

EDITORIAL BOARD MEMBERS

<https://www.wjgnet.com/1948-9366/editorialboard.htm>

EDITORIAL OFFICE

Jin-Lei Wang, Director

PUBLICATION DATE

August 27, 2019

COPYRIGHT

© 2019 Baishideng Publishing Group Inc

INSTRUCTIONS TO AUTHORS

<https://www.wjgnet.com/bpg/gerinfo/204>

GUIDELINES FOR ETHICS DOCUMENTS

<https://www.wjgnet.com/bpg/GerInfo/287>

GUIDELINES FOR NON-NATIVE SPEAKERS OF ENGLISH

<https://www.wjgnet.com/bpg/gerinfo/240>

PUBLICATION MISCONDUCT

<https://www.wjgnet.com/bpg/gerinfo/208>

ARTICLE PROCESSING CHARGE

<https://www.wjgnet.com/bpg/gerinfo/242>

STEPS FOR SUBMITTING MANUSCRIPTS

<https://www.wjgnet.com/bpg/GerInfo/239>

ONLINE SUBMISSION

<https://www.f6publishing.com>

© 2019 Baishideng Publishing Group Inc. All rights reserved. 7041 Koll Center Parkway, Suite 160, Pleasanton, CA 94566, USA

E-mail: bpgoffice@wjgnet.com <https://www.wjgnet.com>



Acute epiploic appendagitis at the tip of the appendix mimicking acute appendicitis: A rare case report with literature review

Kai Huang, Abdul Waheed, William Juan, Subhasis Misra, Cristiano Alpendre, Stephen Jones

ORCID number: Kai Huang (0000-0003-0704-6063); Abdul Waheed (0000-0001-7461-9410); Juan William (0000-0002-6493-5572); Subhasis Misra (0000-0002-7538-0824); Cristiano Alpendre (0000-0002-2196-8710); Stephen Jones (0000-0002-7534-8450).

Author contributions: Huang K, Alpendre C and Jones S designed the case report, Juan W performed the literature search and informed consent; Huang K wrote the manuscript, Waheed A and Misra S revised the manuscript.

Informed consent statement: Informed consent for the publication of this work has been obtained.

Conflict-of-interest statement: None of the authors report a conflict of interest regarding this case report.

CARE Checklist (2016) statement: The guidelines of the "CARE Checklist - 2016: Information for writing a case report has been adopted.

Open-Access: This article is an open-access article which was selected by an in-house editor and fully peer-reviewed by external reviewers. It is distributed in accordance with the Creative Commons Attribution Non Commercial (CC BY-NC 4.0) license, which permits others to distribute, remix, adapt, build upon this work non-commercially, and license their derivative works on different terms, provided the

Kai Huang, Abdul Waheed, William Juan, Subhasis Misra, Cristiano Alpendre, Stephen Jones, Brandon Regional Hospital, HCA West Florida Division/USF Consortium, Brandon, FL 33511, United States

Corresponding author: Kai Huang, MD, Department of General Surgery, Brandon Regional Hospital, 119 Oakfield Dr, Brandon, FL 33511, United States. kai.huang@hcahealthcare.com

Telephone: +1-813-5413043

Fax: +1-813-6626200

Abstract

BACKGROUND

Acute epiploic appendagitis of the appendix (AEAA) is a rare self-limiting inflammatory disorder of the epiploic appendages (EA) close to the vermiform appendix, which often times mimicking the presentation of acute appendicitis (AA). To date, very few cases of AEAA have been reported. We report a case of a 52-year old man with the clinical suspicion of AA, but post-operative specimen examination confirmed AEAA as the final diagnosis.

CASE SUMMARY

A 52-year-old morbidly obese man presented to the emergency department with a 1-d history of the right lower quadrant (RLQ) abdominal pain. Physical examination revealed localized RLQ tenderness mimicking AA. The computed tomography abdomen was inconclusive, and a decision was made to perform laparoscopic appendectomy (LA). During the LA, an infarcted epiploic appendage at the tip of appendix and adherent to the abdominal wall was found, which was entirely excised. Final pathology showed congested and hemorrhagic epiploic appendage without any accompanied acute inflammatory changes in the wall of the appendix. Postoperative course was uneventful and he was doing well at seven months follow-up.

CONCLUSION

The possibility of AEAA should be considered in patients clinically suspected of having AA. Surgery is considered for those refractory to conservative management, with inconclusive diagnosis or develop complications at presentation.

Key words: Acute epiploic appendagitis of the appendix; Acute epiploic appendagitis; Acute appendicitis; Case report

original work is properly cited and the use is non-commercial. See: <http://creativecommons.org/licenses/by-nc/4.0/>

Manuscript source: Unsolicited manuscript

Received: March 8, 2019

Peer-review started: March 11, 2019

First decision: April 18, 2019

Revised: June 4, 2019

Accepted: July 27, 2019

Article in press: July 27, 2019

Published online: August 27, 2019

P-Reviewer: Bandyopadhyay SK, Kakaei F

S-Editor: Wang JL

L-Editor: A

E-Editor: Zhou BX



©The Author(s) 2019. Published by Baishideng Publishing Group Inc. All rights reserved.

Core tip: Acute appendiceal epiploic appendagitis is very rare condition challenging to differentiate from acute appendicitis clinically. Computed tomography abdomen plays a crucial role in diagnosis, while pain control with anti-inflammatory drugs is the treatment of choice. Surgery is only considered for those refractory to conservative management or develop complications at presentation.

Citation: Huang K, Waheed A, Juan W, Misra S, Alpendre C, Jones S. Acute epiploic appendagitis at the tip of the appendix mimicking acute appendicitis: A rare case report with literature review. *World J Gastrointest Surg* 2019; 11(8): 342-347

URL: <https://www.wjgnet.com/1948-9366/full/v11/i8/342.htm>

DOI: <https://dx.doi.org/10.4240/wjgs.v11.i8.342>

INTRODUCTION

Acute epiploic appendagitis of the appendix (AEAA) is a benign, mostly non-surgical inflammatory disorder of the epiploic appendages (EA), which are usually located adjacent to the tenia coli^[1]. Although the actual incidence of AEAA is not well known, however, it has been reported in 0.3%-1% of patients initially suspected of having acute appendicitis (AA)^[2]. The most common mechanism resulting in AEAA is the acute torsion of abnormally elongated and large appendages, which leads to ischemia and necrosis of appendages^[3]. Also, the primary thrombosis of the epiploic appendage central draining vein has also been related to the development of AEAA^[4]. It most commonly presents as acute, constant, and non-radiating right lower quadrant (RLQ) abdominal pain^[5].

Moreover, computed tomography (CT) scan of the abdomen is considered as the diagnostic modality of choice for AEAA, while ultrasound abdomen is reserved for patients with equivocal finding on CT abdomen^[2,6,7]. Additionally, conservative management with oral anti-inflammatory medications is the most appropriate management for AEAA patients, while those who fail the conservative management, those with new or worsening symptoms and those with complications are best treated with the surgical interventions^[6,8-10]. Current knowledge regarding AEAA is limited and only rare case reports exist. In order to better understand and add our contribution to the available literature on this rare condition, we report a unique case of a 52-year-old male patient initially suspected of having AA, but post-operative specimen evaluation was significant for AEAA.

CASE PRESENTATION

Chief complaints

A 52-year-old man with a basal metabolic index: 43.4 kg/m², presented to the emergency department complaining of acute RLQ abdominal pain of 18 hours duration.

History of present illness

His pain was severe, constant, non-radiating, and aggravated with movement, without any history of associated symptoms including nausea, vomiting, diarrhea, anorexia, fever, and chills. He denies any recent history of trauma.

History of past illness

His past medical history was significant for hypertension, laparoscopic cholecystectomy and open umbilical hernia repair.

Personal and family history

Personal and family history was unremarkable.

Physical examination upon admission

On admission, his vitals were: temperature (T) = 36.5 °C, pulse (P) = 71, beats per minute, respiratory rate = 18/min, and blood pressure = 174/74 mmHg. Physical exam revealed severe tenderness in the abdominal RLQ, no peritoneal sign, although

Rovsing sign and Psoas signs were negative.

Laboratory examinations

Routine pre-operative laboratory testing indicated mild leukocytosis white blood count = 11200/m³ with no left shift, and procalcitonin < 0.05 ng/mL. Basic metabolic panel was unremarkable.

Imaging examinations

Patient had an abdominal CT without contrast in the emergency room (ER), which showed a 1.0 cm × 1.8 cm focus of oval inflammatory changes surrounding central fat density adjacent to the tip of the appendix and inferior aspect of the cecum. This is likely due to epiploic appendagitis. Possibility of very early acute distal tip appendicitis cannot be entirely excluded but felt to be less likely.

FINAL DIAGNOSIS

Although these radiological findings are highly suspicious for AEAA, the possibility of very early acute distal tip appendicitis could not be entirely excluded at that moment (Figure 1). Despite the aggressive management with IV fluids and antibiotics, his abdominal pain persisted.

TREATMENT

Based on the suspicious of early appendicitis, and the fact that the patient decided to choose surgery after our length discussion, a decision was made to perform an emergent laparoscopic appendectomy. During the laparoscopic appendectomy, mild hyperemic changes were noted in the vermiform appendix which was intensely adhered to the RLQ abdominal pain. Also noted was an infarcted epiploic appendage which was also attached to the tip of the appendix (Figure 2). At this moment, a complete laparoscopic appendectomy was performed, and the specimen was retrieved. Pathology report showed a tubular appendix measuring 42 mm in length and 6 mm in diameter on macroscopic examination. The congested and hemorrhagic appendage measured 6.3 cm × 1.6 cm × 1 cm. On microscopic examination, the tip of appendix had partial fibrous obliteration with perpendicular fibrin, and no acute inflammation identified in the appendiceal wall confirming the AEAA as the final diagnosis (Figure 3).

OUTCOME AND FOLLOW-UP

The postoperative course was uneventful, and the patient was discharged on the following day. Patient was doing well at seven months follow-up.

DISCUSSION

Acute epiploic appendagitis (AEA), first described by Lynn *et al* in 1956, is one of the rare causes of acute abdomen secondary to the inflammation of the EA, which are 0.5-5 cm long and 1-2 cm thick serosa-covered fat pad pouches of the colonic wall^[11,12]. Although the EA are distributed along the entire colon (50-100 in total), they are mostly populated in the rectosigmoid junction (57%), ileocecal region (26%), ascending colon (9%), transverse colon (6%) and descending colon (2%)^[12].

AEA may be primary or secondary. Primary acute epiploic appendagitis (PAEA) is caused by torsion or spontaneous venous thrombosis of the involved epiploic appendage, while secondary epiploic appendagitis (SEA) is associated with inflammation of adjacent organs, such as diverticulitis, appendicitis or cholecystitis^[13]. Moreover, the PAEA presents mostly in 2-5 decades of life without any sexual predominance, while SEA affects mostly middle-aged obese male population^[3,11-13]. Also, the most common parts of the colon affected by AEA in decreasing order of frequency are the sigmoid colon, descending colon, cecum and the ascending colon^[13].

AEAA is an even extremely rare form of AEA accounting for only 3% of all AEA cases. Shiryajev *et al*^[14] described a case of AEAA secondary to underlying appendicitis, while Hambury *et al*^[15] described an actual case of torse EA of the vermiform appendix, which mimicked AA. Surprisingly, the luminal diameter of the EA near the vermiform appendix is usually smaller compared to those around the

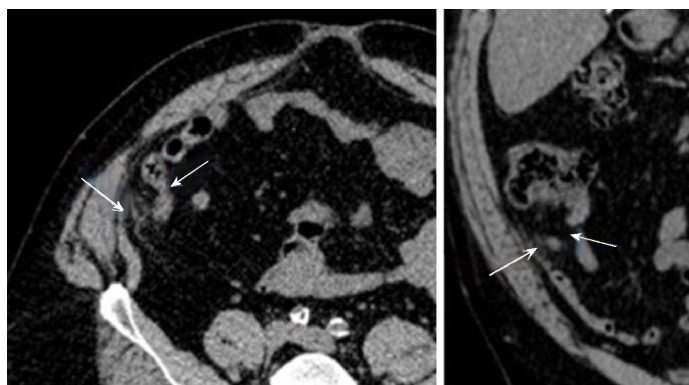


Figure 1 Abdominal computed tomography scan. A 1.0 cm × 1.8 cm focus of oval inflammatory changes surrounding central fat density visualized adjacent to the tip of the appendix and inferior aspect of the cecum noted. This is likely due to epiploic appendagitis. Possibility of very early acute distal tip appendicitis cannot be entirely excluded but felt to be less likely (Short arrow: Appendix; Long arrow: Epiploic appendagitis).

colon, making them susceptible to the early infarction after the torsion. Additionally, AEAA typically presents in the middle-aged male population with acute onset of right lower quadrant pain usually without associated symptoms such as fever, anorexia, nausea, vomiting, diarrhea, or constipation.

Given the non-specific clinical presentation of AEAA, the use of imaging technology plays a critical role in the diagnosis of this rare entity. Advances in imaging techniques made it possible to radiologically describe the first report of EA using CT scan abdomen in 1986^[6]. The hallmark CT abdomen findings for AEAA include; fat attenuating oval lesion usually less than 2 cm with the hyper-attenuated rim located near the tip of the appendix^[17]. Other less specific findings include localized edema, described as streaky fluid attenuation or fat stranding around the appendage^[18]. Additionally, the appendix is usually normal in caliber without any enhancement or thickness of appendiceal wall^[18].

Furthermore, AEAA is a self-limiting disease, and most of the patients recover within 1-14 d after the analgesic medication^[12]. Conservative management using non-steroidal anti-inflammatory drugs (NSAID) is currently considered the standard management for radiologically confirmed AEAA^[3,19]. Antibiotics and surgery are reserved for those with worsening symptoms, or those who do not respond to conservative management, or those who develop complications such as the abscess or intestinal obstruction, new or worsening symptoms^[12].

To comment further on the complex nature of the AEAA, we performed a literature search which yielded only seven case reports specifically for AEAA (Table 1). Based on the results of our literature search, we can conclude that most of the AEAA cases reported so far were an accidental finding in patients who underwent emergent appendectomy with a clinical diagnosis of AA in the absence of radiologic confirmation. Also, our literature search yielded AEAA effects mostly middle-aged population (32-63 years; mean = 42.7 years), mostly male (4/7, 62.5%), presents with RLQ pain, with normal or mild elevated white count (normal-13.3/mm³). Also, the maximum diameter of lesions was 1.3 to 1.8cm. It was found near the tip of the appendix (3/7), proximal appendix (1/7) and middle and distal one third (2/7).

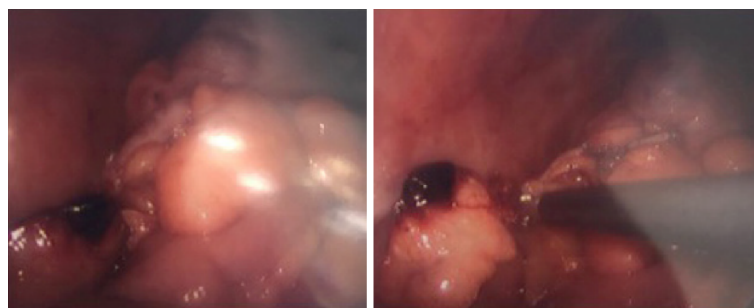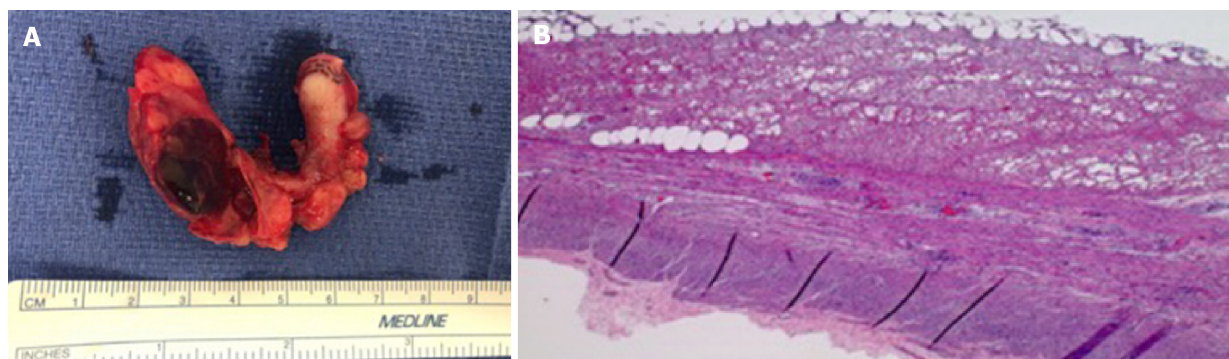
CONCLUSION

AEAA is a rare cause of abdominal RLQ pain that can easily mimic the clinical presentation of AA. The advances in the diagnostic modalities have permitted the better radiological delineation of this rare entity, and have also reduced the burden of un-necessary surgeries on the United States economy. In the clinical settings of the non-specific clinical presentation of AA, CT abdomen should be ordered in order to rule out AEAA as the possible cause of acute abdominal pain. Additionally, in the absence of other complication, conservative management with NSAID should be considered as the initial management for AEAA before making decision for the invasive approaches.

Table 1 Acute appendiceal epiploic appendagitis and literature review

Author	Age (yr)	Sex	Symptom	Lab results	Size of the lesion	Location of the lesion	CT appearance	Outcomes
Hambury <i>et al</i> ^[4]	34	F	RLQ pain	Not mentioned	1.3 cm	Junction of the middle and distal one-third of the appendix	N/A	Surgically confirmed
Sand <i>et al</i> ^[5]	50	M	RLQ pain	Leukocytosis (WBC 12/nL) Elevated CRP (1 mg/dL)	Not mentioned	Not mentioned	N/A	Surgically confirmed
Aslam <i>et al</i> ^[3]	57	M	RLQ pain	Leukocytosis	Not mentioned	Near the tip of appendix	N/A	Surgically confirmed
Magnuson <i>et al</i> ^[6]	36	F	RLQ pain	Within normal range	Not mentioned	Proximal appendix	N/A	Surgically confirmed
Purysko <i>et al</i> ^[2]	38	M	RLQ pain	Not mentioned	Not mentioned	Near the tip of appendix	Periappendiceal fatty oval lesion with hyperattenuating rim	Surgically confirmed
Jung <i>et al</i> ^[8]	32	M	RLQ pain	Leukocytosis (WBC 10950/mm ³) Elevated ESR (14 mm/h)	1.5 cm	Near the tip of appendix	Periappendiceal fatty oval lesion with hyperattenuating rim and central linear hyperattenuation	Surgically confirmed
Sahin <i>et al</i> ^[7]	63	F	RLQ pain	Leukocytosis (WBC 13300/mm ³)	Not mentioned	Near the middle of appendix	N/A	Surgically confirmed

WBC: White blood cell; RLQ: Right lower quadrant; CT: Computed tomography.

**Figure 2** Infarcted appendiceal epiploic appendage at the tip of the appendix (Intraoperative).**Figure 3** The Congested and hemorrhagic appendage. A: The congested and hemorrhagic appendage measures 6.3 cm × 1.6 cm × 1 cm; B: Serosal surface with fibrin and few acute inflammatory cells. Muscular layer with no inflammatory cells. High power.

ACKNOWLEDGEMENTS

We are thankful to Soraya Rodriguez, MD from the Department of Pathology at Brandon Regional Hospital, Florida for providing her valuable feedback in the interpretation of histology slides for this unique case report.

REFERENCES

- 1 **Patel H**, Abdelbaki A, Steenbergen P, Chanana C, Li S. Know the name: acute epiploic appendagitis-CT findings and review of literature. *AME Case Rep* 2018; **2**: 8 [PMID: [30264004](#) DOI: [10.21037/acr.2018.02.02](#)]
- 2 **Thomson GT**, Johnston JL, Baragar FD, Toole JW. Psoriatic arthritis and myopathy. *J Rheumatol* 1990; **17**: 395-398 [PMID: [2110253](#) DOI: [10.1038/nrgastro.2010.189](#)]
- 3 **Aslam MB**, Hasan N. Torsion of an appendix epiploica present at the vermiform appendix: a rare cause of acute abdomen. *Ulus Travma Acil Cerrahi Derg* 2009; **15**: 509-510 [PMID: [19779995](#)]
- 4 **Tabbara TA**, Alassaf OY, Kaouas MC. Acute epiploic appendicitis: Diagnostic and laparoscopic approach. *Int J Surg Case Rep* 2018; **44**: 157-160 [PMID: [29505992](#) DOI: [10.1016/j.ijscr.2018.02.003](#)]
- 5 **Sandrasegaran K**, Maglinte DD, Rajesh A, Akisik FM. Primary epiploic appendagitis: CT diagnosis. *Emerg Radiol* 2004; **11**: 9-14 [PMID: [15278705](#) DOI: [10.1007/s10140-004-0369-9](#)]
- 6 **Rioux M**, Langis P. Primary epiploic appendagitis: clinical, US, and CT findings in 14 cases. *Radiology* 1994; **191**: 523-526 [PMID: [8153333](#) DOI: [10.1148/radiology.191.2.8153333](#)]
- 7 **Singh AK**, Gervais DA, Hahn PF, Rhea J, Mueller PR. CT appearance of acute appendicitis. *AJR Am J Roentgenol* 2004; **183**: 1303-1307 [PMID: [15505294](#) DOI: [10.2214/ajr.183.5.1831303](#)]
- 8 **Desai HP**, Tripodi J, Gold BM, Burakoff R. Infarction of an epiploic appendage. Review of the literature. *J Clin Gastroenterol* 1993; **16**: 323-325 [PMID: [8331268](#) DOI: [10.1097/00004836-199306000-00012](#)]
- 9 **Legome EL**, Belton AL, Murray RE, Rao PM, Novelline RA. Epiploic appendagitis: the emergency department presentation. *J Emerg Med* 2002; **22**: 9-13 [PMID: [11809550](#) DOI: [10.1016/S0736-4679\(01\)00430-9](#)]
- 10 **Vinson DR**. Epiploic appendagitis: a new diagnosis for the emergency physician. Two case reports and a review. *J Emerg Med* 1999; **17**: 827-832 [PMID: [10499697](#) DOI: [10.1016/S0736-4679\(99\)00090-6](#)]
- 11 **Almuhanna AF**, Alghamdi ZM, Alshammari E. Acute epiploic appendagitis: A rare cause of acute abdomen and a diagnostic dilemma. *J Family Community Med* 2016; **23**: 48-50 [PMID: [26929730](#) DOI: [10.4103/2230-8229.172234](#)]
- 12 **Sand M**, Gelos M, Bechara FG, Sand D, Wiese TH, Steinstraesser L, Mann B. Epiploic appendagitis--clinical characteristics of an uncommon surgical diagnosis. *BMC Surg* 2007; **7**: 11 [PMID: [17603914](#) DOI: [10.1186/1471-2482-7-11](#)]
- 13 **Subramaniam R**. Acute appendagitis: emergency presentation and computed tomographic appearances. *Emerg Med J* 2006; **23**: e53 [PMID: [16988291](#) DOI: [10.1136/emj.2005.033704](#)]
- 14 **Shiryajev YN**, Glebova AV. Torsion of an epiploic appendage of the vermiform appendix. *Ulus Travma Acil Cerrahi Derg* 2013; **19**: 593 [DOI: [10.5505/tjtes.2013.82574](#)]
- 15 **Hambury HJ**. Torsion of an appendix epiploica of the vermiform appendix. *Br J Surg* 1952; **40**: 176-177 [PMID: [12987654](#) DOI: [10.1002/bjs.18004016019](#)]
- 16 **Danielson K**, Chernin MM, Amberg JR, Goff S, Durham JR. Epiploic appendicitis: CT characteristics. *J Comput Assist Tomogr* 1986; **10**: 142-143 [PMID: [3944300](#) DOI: [10.1097/00004728-198601000-00032](#)]
- 17 **Almeida AT**, Melão L, Viamonte B, Cunha R, Pereira JM. Epiploic appendagitis: an entity frequently unknown to clinicians--diagnostic imaging, pitfalls, and look-alikes. *AJR Am J Roentgenol* 2009; **193**: 1243-1251 [PMID: [19843737](#) DOI: [10.2214/AJR.08.2071](#)]
- 18 **Eberhardt SC**, Strickland CD, Epstein KN. Radiology of epiploic appendages: acute appendagitis, post-infarcted appendages, and imaging natural history. *Abdom Radiol (NY)* 2016; **41**: 1653-1665 [PMID: [27142382](#) DOI: [10.1007/s00261-016-0757-0](#)]
- 19 **Ozdemir S**, Gulpinar K, Leventoglu S, Uslu HY, Turkoz E, Ozcay N, Korkmaz A. Torsion of the primary epiploic appendagitis: a case series and review of the literature. *Am J Surg* 2010; **199**: 453-458 [PMID: [19520357](#) DOI: [10.1016/j.amjsurg.2009.02.004](#)]



Published By Baishideng Publishing Group Inc
7041 Koll Center Parkway, Suite 160, Pleasanton, CA 94566, USA
Telephone: +1-925-2238242
Fax: +1-925-2238243
E-mail: bpgoffice@wjgnet.com
Help Desk: <https://www.f6publishing.com/helpdesk>
<https://www.wjgnet.com>

