

# World Journal of *Clinical Cases*

*World J Clin Cases* 2021 January 16; 9(2): 291-520



## Contents

Thrice Monthly Volume 9 Number 2 January 16, 2021

### OPINION REVIEW

- 291 Continuity of cancer care in the era of COVID-19 pandemic: Role of social media in low- and middle-income countries  
*Yadav SK, Yadav N*

### REVIEW

- 296 Effect of a fever in viral infections — the ‘Goldilocks’ phenomenon?  
*Belon L, Skidmore P, Mehra R, Walter E*
- 308 Overview of bile acid signaling in the cardiovascular system  
*Zhang R, Ma WQ, Fu MJ, Li J, Hu CH, Chen Y, Zhou MM, Gao ZJ, He YL*

### MINIREVIEWS

- 321 Gut microbiota and inflammatory bowel disease: The current status and perspectives  
*Zheng L, Wen XL*

### ORIGINAL ARTICLE

#### Retrospective Cohort Study

- 334 Effective immune-inflammation index for ulcerative colitis and activity assessments  
*Zhang MH, Wang H, Wang HG, Wen X, Yang XZ*

#### Retrospective Study

- 344 Risk factors associated with acute respiratory distress syndrome in COVID-19 patients outside Wuhan: A double-center retrospective cohort study of 197 cases in Hunan, China  
*Hu XS, Hu CH, Zhong P, Wen YJ, Chen XY*

### META-ANALYSIS

- 357 Limb length discrepancy after total knee arthroplasty: A systematic review and meta-analysis  
*Tripathy SK, Pradhan SS, Varghese P, Purudappa PP, Velagada S, Goyal T, Panda BB, Vanyambadi J*

### CASE REPORT

- 372 Lateral position intubation followed by endoscopic ultrasound-guided angiotherapy in acute esophageal variceal rupture: A case report  
*Wen TT, Liu ZL, Zeng M, Zhang Y, Cheng BL, Fang XM*
- 379 Perioperative mortality of metastatic spinal disease with unknown primary: A case report and review of literature  
*Li XM, Jin LB*

- 389** Massive gastric bleeding - perforation of pancreatic pseudocyst into the stomach: A case report and review of literature  
*Jin Z, Xiang YW, Liao QS, Yang XX, Wu HC, Tuo BG, Xie R*
- 396** Natural history of inferior mesenteric arteriovenous malformation that led to ischemic colitis: A case report  
*Kimura Y, Hara T, Nagao R, Nakanishi T, Kawaguchi J, Tagami A, Ikeda T, Araki H, Tsurumi H*
- 403** Coil embolization of arterioportal fistula complicated by gastrointestinal bleeding after Caesarian section: A case report  
*Stepanyan SA, Poghosyan T, Manukyan K, Hakobyan G, Hovhannisyan H, Safaryan H, Baghdasaryan E, Gemilyan M*
- 410** Cholecystoduodenal fistula presenting with upper gastrointestinal bleeding: A case report  
*Park JM, Kang CD, Kim JH, Lee SH, Nam SJ, Park SC, Lee SJ, Lee S*
- 416** Rare case of fecal impaction caused by a fecalith originating in a large colonic diverticulum: A case report  
*Tanabe H, Tanaka K, Goto M, Sato T, Sato K, Fujiya M, Okumura T*
- 422** Intravitreal dexamethasone implant — a new treatment for idiopathic posterior scleritis: A case report  
*Zhao YJ, Zou YL, Lu Y, Tu MJ, You ZP*
- 429** Inflammatory myofibroblastic tumor successfully treated with metformin: A case report and review of literature  
*Liang Y, Gao HX, Tian RC, Wang J, Shan YH, Zhang L, Xie CJ, Li JJ, Xu M, Gu S*
- 436** Neonatal isovaleric acidemia in China: A case report and review of literature  
*Wu F, Fan SJ, Zhou XH*
- 445** Malignant solitary fibrous tumor of the greater omentum: A case report and review of literature  
*Guo YC, Yao LY, Tian ZS, Shi B, Liu Y, Wang YY*
- 457** Paratesticular liposarcoma: Two case reports  
*Zheng QG, Sun ZH, Chen JJ, Li JC, Huang XJ*
- 463** Sinistral portal hypertension associated with pancreatic pseudocysts - ultrasonography findings: A case report  
*Chen BB, Mu PY, Lu JT, Wang G, Zhang R, Huang DD, Shen DH, Jiang TT*
- 469** Epstein-Barr virus-associated monomorphic post-transplant lymphoproliferative disorder after pediatric kidney transplantation: A case report  
*Wang Z, Xu Y, Zhao J, Fu YX*
- 476** Postoperative complications of concomitant fat embolism syndrome, pulmonary embolism and tympanic membrane perforation after tibiofibular fracture: A case report  
*Shao J, Kong DC, Zheng XH, Chen TN, Yang TY*
- 482** Double-hit lymphoma (rearrangements of MYC, BCL-2) during pregnancy: A case report  
*Xie F, Zhang LH, Yue YQ, Gu LL, Wu F*

- 489** Is sinusoidal obstructive syndrome a recurrent disease after liver transplantation? A case report  
*Liu Y, Sun LY, Zhu ZJ, Wei L, Qu W, Zeng ZG*
- 496** Portal hypertension exacerbates intrahepatic portosystemic venous shunt and further induces refractory hepatic encephalopathy: A case report  
*Chang YH, Zhou XL, Jing D, Ni Z, Tang SH*
- 502** Repair of a severe palm injury with anterolateral thigh and ilioinguinal flaps: A case report  
*Gong HY, Sun XG, Lu LJ, Liu PC, Yu X*
- 509** Indirect inguinal hernia containing portosystemic shunt vessel: A case report  
*Yura M, Yo K, Hara A, Hayashi K, Tajima Y, Kaneko Y, Fujisaki H, Hirata A, Takano K, Hongo K, Yoneyama K, Nakagawa M*
- 516** Recurrent inverted papilloma coexisted with skull base lymphoma: A case report  
*Hsu HJ, Huang CC, Chuang MT, Tien CH, Lee JS, Lee PH*

**ABOUT COVER**

Editorial Board Member of *World Journal of Clinical Cases*, Dr. Mukul Vij is Senior Consultant Pathologist and Lab Director at Dr Rela Institute and Medical Center in Chennai, India (since 2018). Having received his MBBS degree from King George Medical College in 2004, Dr. Vij undertook postgraduate training at Sanjay Gandhi Postgraduate Institute of Medical Sciences, receiving his Master's degree in Pathology in 2008 and his PDCC certificate in Renal Pathology in 2009. After 2 years as senior resident, he became Assistant Professor in the Department of Pathology at Christian Medical College, Vellore (2011), moving on to Global Health City as Consultant Pathologist and then Head of the Pathology Department (2013). (L-Editor: Filipodia)

**AIMS AND SCOPE**

The primary aim of *World Journal of Clinical Cases* (*WJCC*, *World J Clin Cases*) is to provide scholars and readers from various fields of clinical medicine with a platform to publish high-quality clinical research articles and communicate their research findings online.

*WJCC* mainly publishes articles reporting research results and findings obtained in the field of clinical medicine and covering a wide range of topics, including case control studies, retrospective cohort studies, retrospective studies, clinical trials studies, observational studies, prospective studies, randomized controlled trials, randomized clinical trials, systematic reviews, meta-analysis, and case reports.

**INDEXING/ABSTRACTING**

The *WJCC* is now indexed in Science Citation Index Expanded (also known as SciSearch®), Journal Citation Reports/Science Edition, PubMed, and PubMed Central. The 2020 Edition of Journal Citation Reports® cites the 2019 impact factor (IF) for *WJCC* as 1.013; IF without journal self cites: 0.991; Ranking: 120 among 165 journals in medicine, general and internal; and Quartile category: Q3.

**RESPONSIBLE EDITORS FOR THIS ISSUE**

Production Editor: Jia-Hui Li; Production Department Director: Yu-Jie Ma; Editorial Office Director: Jin-Lai Wang.

**NAME OF JOURNAL**

*World Journal of Clinical Cases*

**ISSN**

ISSN 2307-8960 (online)

**LAUNCH DATE**

April 16, 2013

**FREQUENCY**

Thrice Monthly

**EDITORS-IN-CHIEF**

Dennis A Bloomfield, Sandro Vento, Bao-gan Peng

**EDITORIAL BOARD MEMBERS**

<https://www.wjgnet.com/2307-8960/editorialboard.htm>

**PUBLICATION DATE**

January 16, 2021

**COPYRIGHT**

© 2021 Baishideng Publishing Group Inc

**INSTRUCTIONS TO AUTHORS**

<https://www.wjgnet.com/bpg/gerinfo/204>

**GUIDELINES FOR ETHICS DOCUMENTS**

<https://www.wjgnet.com/bpg/GerInfo/287>

**GUIDELINES FOR NON-NATIVE SPEAKERS OF ENGLISH**

<https://www.wjgnet.com/bpg/gerinfo/240>

**PUBLICATION ETHICS**

<https://www.wjgnet.com/bpg/GerInfo/288>

**PUBLICATION MISCONDUCT**

<https://www.wjgnet.com/bpg/gerinfo/208>

**ARTICLE PROCESSING CHARGE**

<https://www.wjgnet.com/bpg/gerinfo/242>

**STEPS FOR SUBMITTING MANUSCRIPTS**

<https://www.wjgnet.com/bpg/GerInfo/239>

**ONLINE SUBMISSION**

<https://www.f6publishing.com>



## Intravitreal dexamethasone implant — a new treatment for idiopathic posterior scleritis: A case report

Yong-Ji Zhao, Yu-Ling Zou, Ying Lu, Meng-Jun Tu, Zhi-Peng You

**ORCID number:** Yong-Ji Zhao 0000-0002-3530-082; Yu-Ling Zou 0000-0002-2202-4367; Ying Lu 0000-0002-1310-0583; Meng-Jun Tu 0000-0003-4821-8095; Zhi-Peng You 0000-0003-3557-5560.

**Author contributions:** Zou YL, Lu Y, and Tu MJ treated the patient; Zhao YJ and You ZP drafted the paper; all authors read and approved the final version to be published.

**Supported by** National Natural Science Foundation of China, No. 81460088 and No. 81860177.

**Informed consent statement:** The patient provided informed written for the publication of this case report.

**Conflict-of-interest statement:** The authors declare that there is no conflict of interest in this study.

**CARE Checklist (2016) statement:** The authors have read the CARE Checklist (2016), and the manuscript was prepared and revised according to the CARE Checklist (2016).

**Open-Access:** This article is an open-access article that was selected by an in-house editor and fully peer-reviewed by external reviewers. It is distributed in accordance with the Creative

**Yong-Ji Zhao, Yu-Ling Zou, Ying Lu, Zhi-Peng You,** Department of Ophthalmology, The Second Affiliated Hospital of Nanchang University, Nanchang 330006, Jiangxi Province, China

**Meng-Jun Tu,** Department of Ophthalmology, The Eye Hospital, Wenzhou Medical University, Wenzhou 330006, Zhejiang Province, China

**Corresponding author:** Zhi-Peng You, PhD, Doctor, Department of Ophthalmology, The Second Affiliated Hospital of Nanchang University, No. 1 Minde Street, Nanchang 330006, Jiangxi Province, China. [yzp\\_oph74@163.com](mailto:yzp_oph74@163.com)

### Abstract

#### BACKGROUND

Posterior scleritis is one of the most easily missed and misdiagnosed diseases in ophthalmology. In this case we treated a patient with intravitreal dexamethasone implant that has not been extensively studied before.

#### CASE SUMMARY

A 40-year-old female patient who had anxiety, palpitation, and insomnia presented with eye pain and decreased vision in the left eye. An eye examination indicated that her visual acuity (VA) was 40/100. Her left eye presented conjunctival edema, mild exophthalmos, clear cornea, KP(-), and clear aqueous humor. In the fundus, there was a cinerous retinal protuberance. Ultrasonography showed “T-sign” and no systemic association was detected in laboratory examination. One month after injection of dexamethasone implant, the patient exhibited VA of 20/20, fundus serous retinal detachment disappeared, and intraocular pressure of both eyes was at the normal level.

#### CONCLUSION

Intravitreal injection of dexamethasone implant may be a safe and effective treatment for patients with idiopathic posterior scleritis.

**Key Words:** Intravitreal dexamethasone implant; Posterior scleritis; Treatment; Case report; Ophthalmology

©The Author(s) 2021. Published by Baishideng Publishing Group Inc. All rights reserved.

Commons Attribution NonCommercial (CC BY-NC 4.0) license, which permits others to distribute, remix, adapt, build upon this work non-commercially, and license their derivative works on different terms, provided the original work is properly cited and the use is non-commercial. See: <http://creativecommons.org/licenses/by-nc/4.0/>

**Manuscript source:** Unsolicited manuscript

**Specialty type:** Medicine, research and experimental

**Country/Territory of origin:** China

**Peer-review report's scientific quality classification**

Grade A (Excellent): 0  
Grade B (Very good): 0  
Grade C (Good): 0  
Grade D (Fair): 0  
Grade E (Poor): 0

**Received:** August 4, 2020

**Peer-review started:** August 4, 2020

**First decision:** November 14, 2020

**Revised:** November 18, 2020

**Accepted:** November 29, 2020

**Article in press:** November 29, 2020

**Published online:** January 16, 2021

**P-Reviewer:** Demonacos C

**S-Editor:** Gao CC

**L-Editor:** Wang TQ

**P-Editor:** Liu JH



**Core Tip:** We describe a case of using intravitreal dexamethasone implant to treat a patient with idiopathic posterior scleritis.

**Citation:** Zhao YJ, Zou YL, Lu Y, Tu MJ, You ZP. Intravitreal dexamethasone implant — a new treatment for idiopathic posterior scleritis: A case report. *World J Clin Cases* 2021; 9(2): 422-428

**URL:** <https://www.wjgnet.com/2307-8960/full/v9/i2/422.htm>

**DOI:** <https://dx.doi.org/10.12998/wjcc.v9.i2.422>

## INTRODUCTION

Posterior scleritis refers to inflammation of the sclera at the posterior to equator or around the optic nerve. It is one of the most easily misdiagnosed and most difficult to treat diseases in ophthalmology<sup>[1]</sup>. Due to the variety of clinical manifestations, posterior scleritis often leads to misdiagnosis. When the disease is not accompanied by anterior scleritis and no obvious sign performed in the outer eye, missed diagnosis is most likely to happen in the end. After examining some removed eyeballs, it is not uncommon to find eyeballs with primary posterior scleritis or retrogressive anterior scleritis, which indicates the clinical concealment of posterior scleritis<sup>[2]</sup>. Statistical data show that the incidence of posterior scleritis in females accounts for 71.1% of all cases. The average age is  $45.9 \pm 16.8$  years old. In around 40% of the cases, it is associated with other systemic diseases<sup>[3]</sup>. In addition to the anterior scleritis, most of the signs are fundus changes, such as circumscribed fundus mass<sup>[4]</sup>, edema of the optic disc, cystoid macular edema, exudative retinal detachment<sup>[5]</sup>, optic neuritis, or retrobulbar optic neuritis<sup>[6]</sup>. In the past, patients take systemic glucocorticoid for a long time, which usually causes many side effects, such as centripetal obesity, hypertension, hyperglycemia, peptic ulcer, osteoporosis, infection, mental disorders, and so on<sup>[7]</sup>.

This case report aims to evaluate the safety and efficacy of intravitreal slow delivery of 0.7 mg dexamethasone implant (Ozurdex; Allergan Inc., Irvine, CA, United States) for idiopathic posterior scleritis.

## CASE PRESENTATION

### Chief complaints

A 40-year-old female patient sought treatment at our department because of eye pain and decreased vision in the left eye.

### History of present illness

The patient reported pain and decreased vision of the left eye with no obvious cause 1 wk ago, with pain of the ipsilateral head and double eyelid swelling. Therefore, she visited our hospital. Since the onset of the disease, her spirit, appetite, sleep, and urine were normal.

### History of past illness

The patient's medical history was not remarkable, and there were no symptoms to indicate connective tissue disorder.

### Personal and family history

The patient had no family history of ocular diseases.

### Physical examination

The examination showed that her visual acuity was 40/100 in the left eye and 100/100 in the right eye. Slit-lamp examination of the anterior chamber revealed clear cornea, KP(-), and clear aqueous humor. The pupillary reflex and the eye movements were normal in both eyes. No systematic deficits were noted on physical examination.

### Laboratory examinations

The patient's leukocyte count was  $6.06 \times 10^9/L$  [normal range,  $(3.5-9.5) \times 10^9/L$ ], lymphocyte count was  $1.16 \times 10^9/L$  [normal range,  $(1.5-4) \times 10^9/L$ ], serum complement C3 was 0.779 g/L [normal (0.9-1.8) g/L], and the immune function test showed that her immunoglobulins were within the normal level.

### Imaging examinations

Ocular fundus images of the left eye showed that there was a cinerous protuberance of the retina in close proximity to the optic disc and the macula (Figure 1A). In her right eye, the fundus examination did not reveal any pathological findings (Figure 1B). Optical coherence tomography (OCT) of her left eye showed retinal edema and choroidal folds, and at the periphery of the macular, there was serous retinal detachment (Figure 1C and D). Then, we carried out fundus fluorescein angiography. The fluorescein angiography of the left eye (red light free image) showed that there was a dark area in macula, which indicated periretinal edema (Figure 1E). In the latter stages of the angiography, there was an increased dark area at the peripheral of the macula with no leakage in choroid or retina (Figure 1F). Ultrasonography showed 'T-sign' with an eyeball thickness of 3.68 mm (Figure 1G). MRI examination showed left eyelid swelling and thickening of eye ring.

## FINAL DIAGNOSIS

The final diagnosis of the presented case was idiopathic posterior scleritis.

## TREATMENT

Intravitreal injection of dexamethasone implant was conducted in the left eye after relevant examinations were performed (Figure 2).

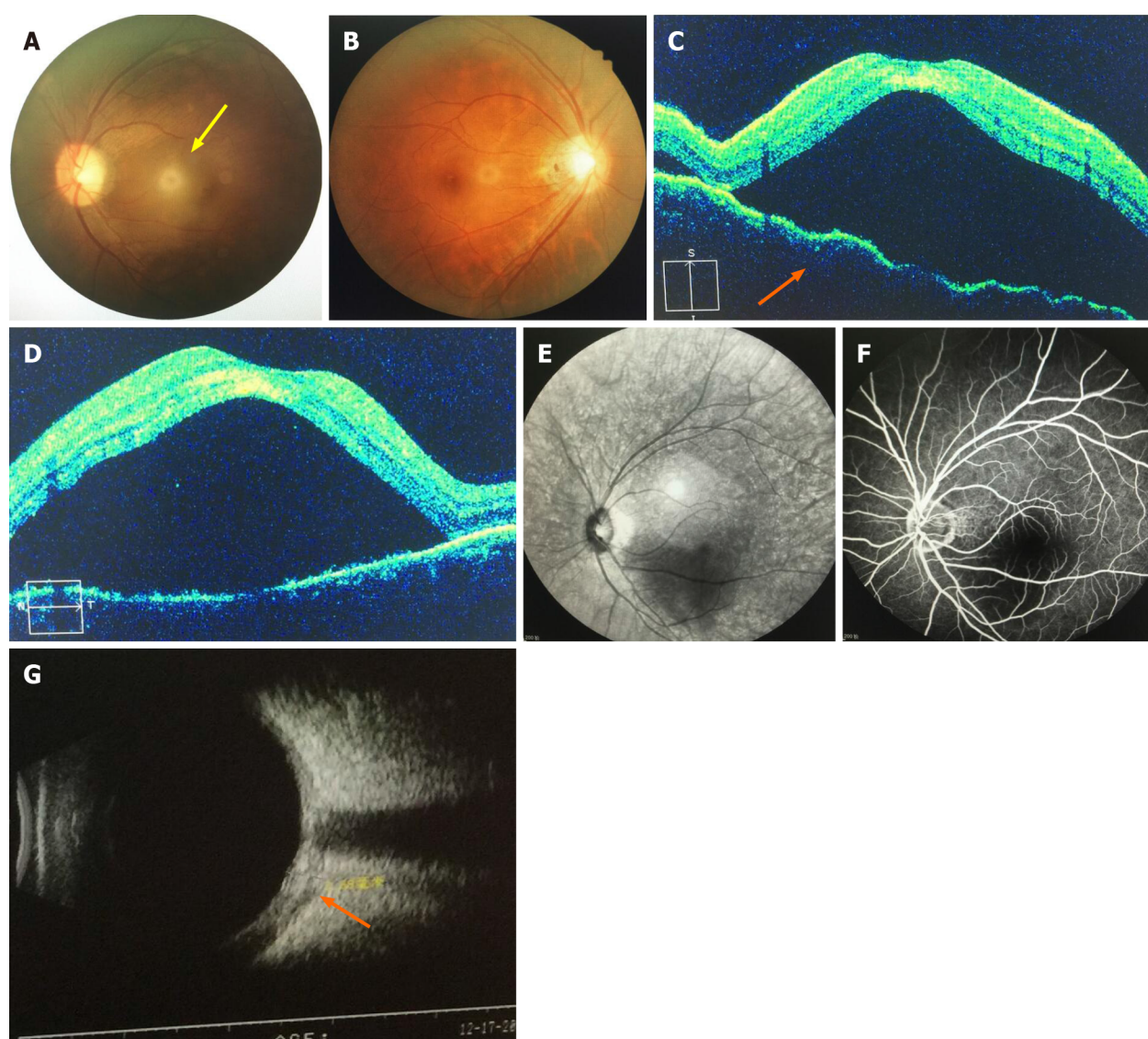
## OUTCOME AND FOLLOW-UP

Four days after the surgery, the left eye had VA of 60/100, the fundus serous retinal detachment was relieved than before, and the thickness of fluid under the retinal became lower. Two week later, macular serous retinal detachment disappeared and retinal thickness returned to the normal level. One month later, OCT showed a normal choroidal and retina structure, but the retinal pigment epithelium and inner segment/outer segment layer in the nasal side of macula were broken off (Figure 3A and B). Three month later, the 'T-sign' disappeared and the thickness of the eyeball return to normal (Figure 3C). The visual acuity returned to 100/100. The intraocular pressure (IOP) of both eyes were within the normal level.

## DISCUSSION

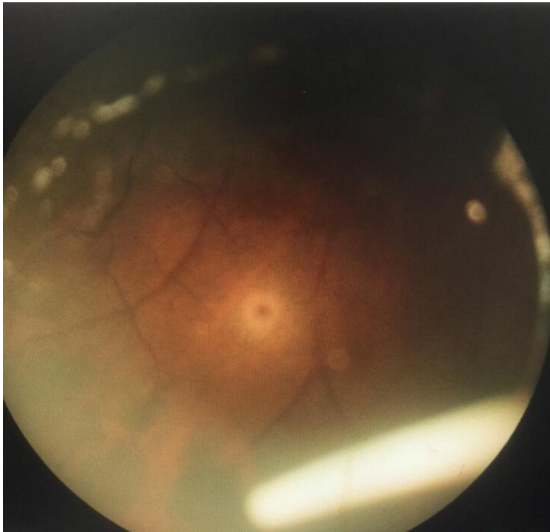The etiology of posterior scleritis is little known, which includes exogenous and endogenous infection, autoimmune diseases, and so on. Despite extensive investigation and multidisciplinary approach which included consultation from a rheumatologist and physician, the cause of scleral inflammation in this case remained unknown. Diagnosis and treatment for posterior scleritis are a challenge in ophthalmology<sup>[8]</sup>. In the previous literature, systemic administration of corticosteroids and/or non-steroidal anti-inflammatory drugs (NSAIDs) is the mainstay treatment for non-infectious scleritis<sup>[9]</sup>, although compliance and side effects such as fluid retention, centripetal obesity, hypertension, hypertension, digestive tract ulcers, greater susceptibility to infections, osteoporosis, mental abnormalities (excitement, insomnia, and mood changes)<sup>[10]</sup> preclude effective treatment. Systemic immunosuppressive therapy as a corticosteroid-sparing therapy is effective for ocular inflammatory diseases. However, immunosuppressive agents may have significant side effects for those who are pregnant, such as mutagenic and teratogenic effects, which can cause fetal death or congenital malformation. Also it can increase the risk of malignancies.

Nowadays, intravitreal dexamethasone implant has already been used for macular



**Figure 1 Imaging examinations.** A: Left eye fundus examination highlighting retinal edema and local retinal detachment; B: Right eye fundus examination without any remarkable findings; C: Left eye optical coherence tomography (OCT) showing choroidal folds and serous retinal detachment from the inferior to superior; D: Left eye OCT showing choroidal folds and serous retinal detachment from temporal to nasal; E: Red light free image of fluorescein angiography (FA) showing a dark area in the macula of the left eye; F: Final phases of FA showing no leakage in the choroid or retina of the left eye; G: Ultrasound showing "T-sign" (indicated by the orange arrow) in the left eye.

edema due to non-infectious uveitis and retinal vein occlusions<sup>[11]</sup>. But it has rarely been used for posterior scleritis. In this case, as the patient had anxiety, palpitation, and insomnia, which could be caused by systemic administration of glucocorticoids, we considered to use intravitreal dexamethasone implant. Our results suggest that dexamethasone implant therapy is effective for idiopathic posterior scleritis. This might indicate that intravitreal dexamethasone implant is a good choice for those who have underlying diseases that might be caused by systemic glucocorticoids. In addition, we found that after 2 wk of dexamethasone implant injection, almost all fundus pathological changes, choroidal folds, and serous retinal detachment disappeared and visual acuity had great improvement. However, traditional systemic administration of corticosteroids needs more time to achieve the same effect. In contrast to systemic glucocorticoids, intravitreal dexamethasone implant has a shorter treating period, although pharmacodynamics of the implant has not been tested in the intravitreal space. In addition, intravitreal injection of dexamethasone implant was an effective approach to control refractory non-necrotizing scleritis for about 6 mo. Furthermore, as systemic glucocorticoids take a long time and might have poor therapeutic effect if the patient's compliance is not good, intravitreal dexamethasone implant might be a better choice for this problem. In the past, as corticosteroids are the mainstay treatment for non-infectious scleritis, the intravitreal injection of dexamethasone may be a good choice for this autoimmune disease associated scleritis



**Figure 2** Ozurdex in the inferior of the vitreous cavity.

and idiopathic scleritis.

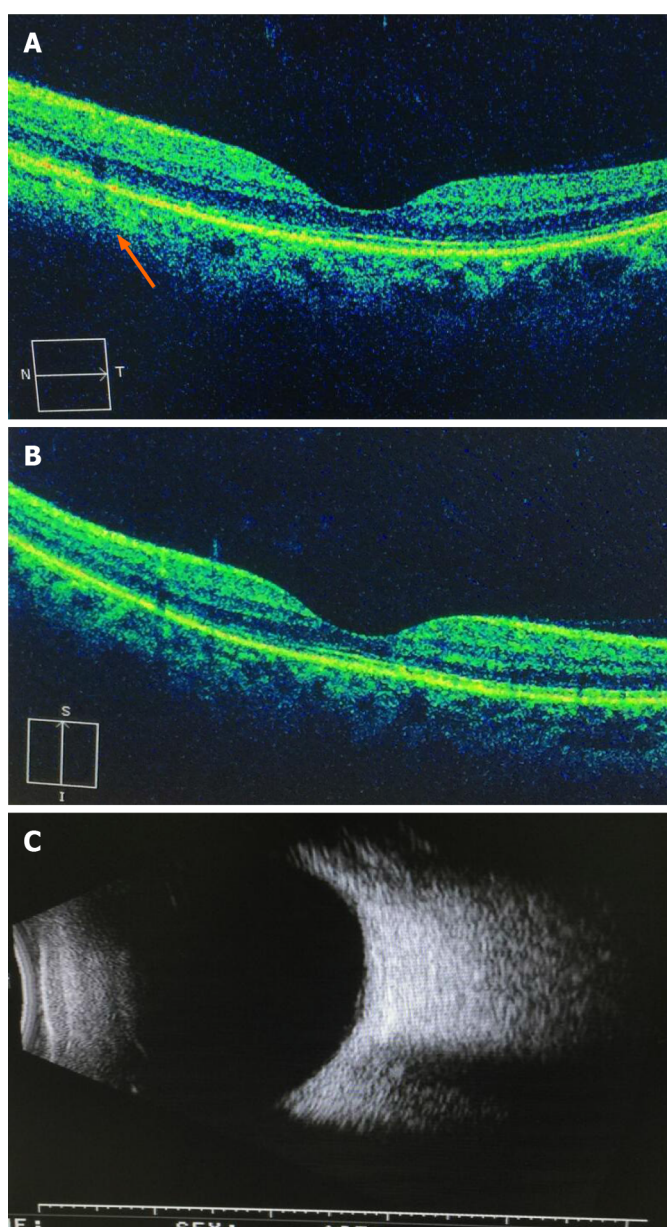
There is also a general concern about the increase of IOP and cataracts, which were not found in our patient. But this patient developed subconjunctival hemorrhage after injection and the hemorrhage was absorbed 1 wk later. As there was a short period of follow-up in this case, more studies with a longer period of follow-up need to be performed to better elucidate the efficacy and safety of the treatment. We should weigh the advantages and disadvantages and choose the treatment carefully. Further studies on intravitreal dexamethasone implant injections should be performed to better evaluate those issues.

---

## CONCLUSION

---

Intravitreal injection of dexamethasone implant is a safe and effective local treatment for idiopathic posterior scleritis. Potential advantages could include no exposure of the patients to the risks of systemic steroids. Also, it could avoid compliance issues of systemic administration of corticosteroids that may preclude effective treatment.



**Figure 3 Optical coherence tomography and ultrasonography.** A: Retinal pigment epithelium and inner segment/outer segment layer in the nasal side of the macula were broken off (orange arrow); B: Total regression of the serous macular detachment of the left eye; C: Ultrasonography showed normal findings.

## REFERENCES

- 1 **Chapelle AC**, Blaise P, Rakic JM. [Posterior scleritis]. *Rev Med Liege* 2016; **71**: 324-327 [PMID: [28383839](#)]
- 2 **Yang P**, Ye Z, Tang J, Du L, Zhou Q, Qi J, Liang L, Wu L, Wang C, Xu M, Tian Y, Kijlstra A. Clinical Features and Complications of Scleritis in Chinese Patients. *Ocul Immunol Inflamm* 2018; **26**: 387-396 [PMID: [27849414](#) DOI: [10.1080/09273948.2016.1241282](#)]
- 3 **Lavric A**, Gonzalez-Lopez JJ, Majumder PD, Bansal N, Biswas J, Pavesio C, Agrawal R. Posterior Scleritis: Analysis of Epidemiology, Clinical Factors, and Risk of Recurrence in a Cohort of 114 Patients. *Ocul Immunol Inflamm* 2016; **24**: 6-15 [PMID: [26134101](#) DOI: [10.3109/09273948.2015.1005240](#)]
- 4 **Ozkaya A**, Alagoz C, Koc A, Ozkaya HM, Yazıcı AT. A case of nodular posterior scleritis mimicking choroidal mass. *Saudi J Ophthalmol* 2015; **29**: 165-168 [PMID: [25892938](#) DOI: [10.1016/j.sjopt.2014.06.012](#)]
- 5 **Kellar JZ**, Taylor BT. Posterior Scleritis with Inflammatory Retinal Detachment. *West J Emerg Med* 2015; **16**: 1175-1176 [PMID: [26759674](#) DOI: [10.5811/westjem.2015.8.28349](#)]
- 6 **Gonzalez-Gonzalez LA**, Molina-Prat N, Doctor P, Tauber J, Sainz de la Maza M, Foster CS. Clinical features and presentation of posterior scleritis: a report of 31 cases. *Ocul Immunol Inflamm* 2014; **22**: 203-207 [PMID: [24131324](#) DOI: [10.3109/09273948.2013.840385](#)]
- 7 **Oray M**, Abu Samra K, Ebrahimiadib N, Meese H, Foster CS. Long-term side effects of

- glucocorticoids. *Expert Opin Drug Saf* 2016; **15**: 457-465 [PMID: [26789102](#) DOI: [10.1517/14740338.2016.1140743](#)]
- 8 **Bielefeld P**, Saadoun D, Héron E, Abad S, Devilliers H, Deschasse C, Trad S, Sène D, Kaplanski G, Sève P. [Scleritis and systemic diseases: What should know the internist? *Rev Med Interne* 2018; **39**: 711-720 [PMID: [29496270](#) DOI: [10.1016/j.revmed.2018.02.001](#)]
- 9 **Stem MS**, Todorich B, Faia LJ. Ocular Pharmacology for Scleritis: Review of Treatment and a Practical Perspective. *J Ocul Pharmacol Ther* 2017; **33**: 240-246 [PMID: [28355124](#) DOI: [10.1089/jop.2016.0127](#)]
- 10 **Tappeiner C**, Walscheid K, Heiligenhaus A. [Diagnosis and treatment of episcleritis and scleritis]. *Ophthalmologe* 2016; **113**: 797-810 [PMID: [27550224](#) DOI: [10.1007/s00347-016-0344-3](#)]
- 11 **He Y**, Ren XJ, Hu BJ, Lam WC, Li XR. A meta-analysis of the effect of a dexamethasone intravitreal implant versus intravitreal anti-vascular endothelial growth factor treatment for diabetic macular edema. *BMC Ophthalmol* 2018; **18**: 121 [PMID: [29784048](#) DOI: [10.1186/s12886-018-0779-1](#)]



Published by **Baishideng Publishing Group Inc**  
7041 Koll Center Parkway, Suite 160, Pleasanton, CA 94566, USA

**Telephone:** +1-925-3991568

**E-mail:** [bpgoffice@wjgnet.com](mailto:bpgoffice@wjgnet.com)

**Help Desk:** <https://www.f6publishing.com/helpdesk>

<https://www.wjgnet.com>

