

Perfusion computed tomography in renal cell carcinoma

Chandan J Das, Usha Thingujam, Ananya Panda, Sanjay Sharma, Arun Kumar Gupta

Chandan J Das, Usha Thingujam, Ananya Panda, Sanjay Sharma, Arun Kumar Gupta, Department of Radiology, All India Institute of Medical Sciences, Ansari Nagar, New Delhi 110029, India

Author contributions: Das CJ, Thingujam U and Panda A contributed equally to conception, article design, literature search, article drafting, critical revision and image preparation; Das CJ and Sharma S helped with the article concept and revision; Das CJ and Gupta AK helped in article preparation and final approval of version of article to be published.

Conflict-of-interest statement: None.

Open-Access: This article is an open-access article which was selected by an in-house editor and fully peer-reviewed by external reviewers. It is distributed in accordance with the Creative Commons Attribution Non Commercial (CC BY-NC 4.0) license, which permits others to distribute, remix, adapt, build upon this work non-commercially, and license their derivative works on different terms, provided the original work is properly cited and the use is non-commercial. See: <http://creativecommons.org/licenses/by-nc/4.0/>

Correspondence to: Dr. Chandan J Das, MD, DNB, MNAMS, Assistant Professor, Department of Radiology, All India Institute of Medical Sciences, Room No. 63, Ansari Nagar, New Delhi 110029, India. docchandan17@gmail.com
 Telephone: +91-11-26594889
 Fax: +91-11-26588663

Received: December 1, 2014
 Peer-review started: December 2, 2014
 First decision: February 7, 2015
 Revised: March 30, 2015
 Accepted: June 4, 2015
 Article in press: June 8, 2015
 Published online: July 28, 2015

Abstract

Various imaging modalities are available for the diagnosis, staging and response evaluation of patients with renal cell carcinoma (RCC). While contrast enhanced computed tomography (CT) is used as the standard of

imaging for size, morphological evaluation and response assessment in RCC, a new functional imaging technique like perfusion CT (pCT), goes down to the molecular level and provides new perspectives in imaging of RCC. pCT depicts regional tumor perfusion and vascular permeability which are indirect parameters of tumor angiogenesis and thereby provides vital information regarding tumor microenvironment. Also response evaluation using pCT may predate the size criteria used in Response Evaluation Criteria in Solid Tumors, as changes in the perfusion occurs earlier following tissue kinase inhibitors before any actual change in size. This may potentially help in predicting prognosis, better selection of therapy and more accurate and better response evaluation in patients with RCC. This article describes the techniques and role of pCT in staging and response assessment in patients with RCCs.

Key words: Angiogenesis; Anti-angiogenic therapy; Perfusion computed tomography; Renal cell carcinoma

© **The Author(s) 2015.** Published by Baishideng Publishing Group Inc. All rights reserved.

Core tip: Perfusion computed tomography is a functional imaging technique. It can be used to predict the histologic grade and early as well as more accurate response evaluation in renal cell carcinoma (RCC). This has the potential to help in better selection of therapy and improve prognosis in RCC.

Das CJ, Thingujam U, Panda A, Sharma S, Gupta AK. Perfusion computed tomography in renal cell carcinoma. *World J Radiol* 2015; 7(7): 170-179 Available from: URL: <http://www.wjgnet.com/1949-8470/full/v7/i7/170.htm> DOI: <http://dx.doi.org/10.4329/wjr.v7.i7.170>

INTRODUCTION

Renal cell carcinoma (RCC) is the most common primary tumor of the kidney. Hypervascularity is

an important feature of primary RCC as well as its metastases. Angiogenesis plays an important role in the growth of the primary tumor and the spread of distant metastases.

Depending on the histologic type and the stage of tumors, the treatment options vary from surgery to chemotherapy. With the advent of new anti-angiogenic agents acting at a molecular level, the treatment of RCC has undergone a paradigm shift. These drugs include sorafenib, sunitinib, pazopanib, and axitinib that target key growth factors like the vascular endothelial growth factor and tyrosine kinase, monoclonal antibody (*e.g.*, bevacizumab), and mammalian target of rapamycin inhibitors (*e.g.*, temsirolimus and everolimus).

The evaluation of the treatment response in patients on these drugs is a challenge. Because of their cytostatic nature, most of these agents produce no significant change in the size of tumor as compared to earlier agents which were cytotoxic. Thus traditional response evaluation based only on size will not be accurate in predicting actual response.

Hence there is a need for tumor evaluation with new functional imaging techniques like perfusion computed tomography (pCT) and dynamic contrast enhanced magnetic resonance imaging. These make feasible grading of the tumor, prognosticating and targeted therapy. These are predicted based on certain perfusion parameters, namely blood flow (BF), blood volume (BV), mean transit time (MTT) and permeability (PMB) which shall be dealt in detail in the subsequent paragraphs. Also different histologic types of tumors have been shown to have different perfusion parameters which will have an impact on the prognosis^[1].

PCT: PRINCIPLE

pCT is based on the temporal changes in tissue attenuation after intravenous administration of iodinated contrast media. Tissue iodine concentration determines enhancement and is an indirect reflection of tissue vascularity and vascular physiology^[2,3]. Two phases are seen in tissue enhancement based on the contrast dynamics and contrast distribution in the intravascular and extravascular compartment^[2]. Initial phase contrast enhancement is due to intravascular space distribution and lasts for approximately 40 to 60 s^[2-4]. Contrast extravasation from the intravascular to the extravascular compartment across the capillary basement membrane marks the onset of the second phase.

BF and BV determine the first phase, whereas vascular PMB to the contrast media is the main determining factor during the second phase^[2]. In pCT, images are taken in quick succession in the region of interest during these two phases. A tissue attenuation curve is plotted after recording the temporal changes in tissue attenuation. Quantification of tissue perfusion is done by applying proper mathematical modeling^[2].

Table 1 Protocol for dynamic perfusion computed tomography acquisition

No. of scans	Cycle time (s)	Accumulated time since start of scan (s)
3	3	9
9	1.5	22.5
5	3	37.5
5	6	68.0
22 (in total)		Examination time: 68

PCT: TECHNIQUE

pCT protocol consists of a baseline image acquisition without contrast enhancement. Dynamic acquisition performed sequentially after intravenous injection of contrast media follows subsequently^[2].

Unenhanced CT acquisition

An unenhanced CT scan of the upper abdomen covering the kidneys is initially performed to locate the renal lesion. It also acts as a localizer to further select the region of interest in the contrast-enhanced dynamic imaging phase. Larger coverage (8-16 cm) is currently obtained with the use of newer scanners having increased rows of detectors^[2].

Dynamic CT acquisition

Images are acquired every 3 to 5 s (Table 1) in the initial cine phase for a total of approximately 40 to 60 s during the first-pass study^[2-4]. For obtaining PMB measurements, a second phase lasting from 2 to 10 min is supplemented after the first-pass study^[2,3]. The second phase images are acquired every 10 to 20 s^[2].

In the pCT study, a predefined scan volume (80 mm for shuttle axial technique and 40 mm for cine technique) in the Z-axis is selected to cover the lesion^[5]. For lesions smaller than 20 mm, cine technique is useful. One hundred milliliters of non-ionic iodinated contrast is administered intravenously for the pCT study maintaining a flow rate of 5 mL/s followed by 40 mL of normal saline flush at the same flow rate^[5].

In cine mode acquisition, 8 contiguous sections, collimated to 5 mm, with temporal resolution of 1 s by are obtained without table movement using the following parameters: 100 Kv, 80 mAs, rotation time 0.5 s, and scan field of view of 50 cm^[5]. Whereas in shuttle-mode acquisition, 8 contiguous sections, collimated to 5 mm, with temporal resolution of 2.8 s are obtained with table movement (21 passes) and using following parameters: 100 Kv, 80 mAs, rotation time 0.4 s, and scan field of view of 50 cm^[5]. In order to include both first-pass enhancement and delayed phase, the total duration of scan is approximately 60 s. After pCT scans, a conventional contrast enhanced CT of the abdomen and thorax is performed immediately. Excretory phase CT urography may be obtained after 5 to 10 min after the contrast media injection whenever required^[5].

Table 2 Computed tomography perfusion parameters^[2-4]

Perfusion parameters	Definition	Unit	Biomarker
Regional blood flow	Blood flow per unit volume or mass of tissue	mL/100 mL per minute	Tumour vascularization
Regional tumour blood volume	Ratio of blood volume to tumour volume	mL/100 mL	Tumour vascularization
Permeability/blood flow extraction (PMB/PS/k-trans)	Rate of transfer of contrast agent from the intravascular to the extravascular compartment	mL/100 gm per minute	Vascular immaturity
Mean transit time	Average time taken to travel from artery to vein	s	Perfusion pressure
Time to peak	Time from arrival of the contrast in major arterial vessels to the peak enhancement	s	Perfusion pressure
Maximum peak intensity	Maximum increase in tissue density after contrast injection	HU	Tissue blood volume

Table 3 Perfusion computed tomography parameter values for kidney (renal cell carcinoma *vs* normal renal cortex)^[7]

	Normal renal cortex (mean \pm SD)	Renal cell carcinoma (mean \pm SD)	<i>t</i> value	<i>P</i> value
Blood flow (mL/min per 100 g)	454.32 \pm 110.90	261.96 \pm 175.86	-7.620	0.000
Blood volume (mL/100 g)	23.53 \pm 5.71	17.17 \pm 8.34	-5.193	0.000
Mean transit time (s)	3.62 \pm 1.38	7.08 \pm 3.42	7.670	0.000
Permeability (mL/min per 100 g)	63.95 \pm 18.85	25.07 \pm 13.20	-14.193	0.000

PCT: IMAGE INTERPRETATION

Post processing is done to correct for the motion artifacts and the data are analyzed at a work station. The slice showing the maximal transverse tumor diameter is chosen for further analysis. An arterial input is defined by putting a circular region-of-interest (ROI) over the abdominal aorta at the level of the renal vessels. Similarly, ROIs are also placed manually (covering 1 cm²) over the renal tumor and the normal renal cortex of the affected kidney or the contralateral kidney. Tumor ROI is placed in solid enhancing area avoiding necrosis, calcification, hemorrhage and cysts.

A tissue time attenuation curve is generated using in-built software. Perfusion parameters (BV, BF, MTT, PMB, MIP) are also calculated. The perfusion parameters are obtained and their definitions have been enumerated in Table 2.

Histogram analysis in pCT

Differentiation between the different tumor types on the basis of qualitative interpretation of contrast enhancement patterns may be possible but quantitative methods of measuring enhancement provides a higher degree of accuracy^[6]. Quantitative method is associated with less subjective variability. ROI-based method of assessing enhancement has demonstrated high accuracy in differentiating clear cell RCC (ccRCC) from papillary RCC (pRCC)^[6]. Limitations of ROI-based methods include invariability in ROI placement amongst different observers, difficulty in selecting the exact location of ROI and technical problems such as misregistration between pre- and post-contrast acquisitions^[6].

Therefore, to overcome the limitations of ROI placement, a tool that can perform automatic registration, lesion segmentation, and whole-lesion (WL) enhancement analysis is needed. Furthermore, histogram distribution has been used to discriminate ccRCC from pRCC using analysis of the WL enhancement pattern^[6].

Whole lesion parameter of third quartile enhancement has been found to have the highest accuracy (area under curve 0.98), with sensitivity of 96% and specificity of 90%^[6]. Special software is used to obtain a histogram of the voxel-based enhancement values and computation of the mean, median, and third quartile enhancement of the sorted values done. Histogram distribution parameters like kurtosis and skewness off-line are subsequently obtained from the values computed^[6].

pCT parameters in normal kidneys

Chen *et al*^[7] have reported CT perfusion values for normal renal cortex; the average BF was reported to be 454.32 mL/100 mL per minute (Figure 1). Difference between BF, BV, MTT, and PMB of normal renal cortex and RCC are shown in Table 3. Perfusion parameters in two representative cases are shown in Table 4.

pCT in renal tumours

Predicting the histologic grade: Pre-operative tumor histotyping using perfusion parameters can be used to prognosticate patients and is important in patients with small renal tumors. Chen *et al*^[7] found that mean values of BF, BV were significantly higher and mean MTT was significantly lower in ccRCC than in pRCC ($P < 0.05$ (Figures 1 and 2).

Similarly Gigli *et al*^[1] have shown a correlation between tumor histological subtype and perfusion index. Significant differences in perfusion values were found in ccRCC of different Fuhrman grades. High perfusion index corresponded with high microvessel density (MVD) while those with lower MVD showed lower perfusion indices.

Previous studies have shown that there was a significant difference in PS and MTT values of malignant lesions (ccRCCs, pRCCs, and chromophobe RCCs) and the normal renal cortex ($P < 0.001$ and $P = 0.029$, respectively) but BF and BV values did not differ

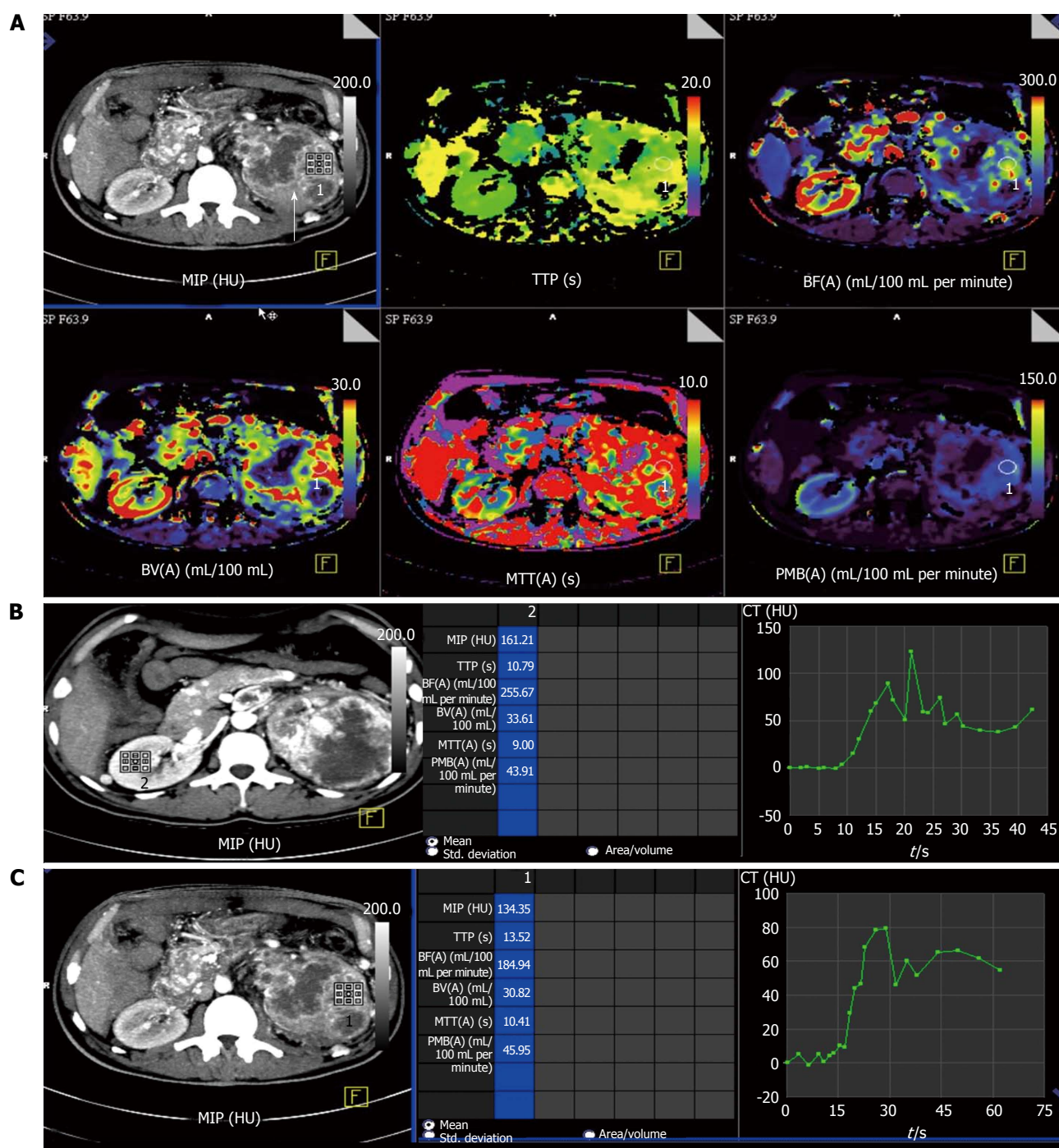


Figure 1 Perfusion computed tomography in normal renal parenchyma vs renal cell carcinoma in a 50-year-old man with left renal cell carcinoma (clear cell type). A: Contrast computed tomography (CT) images showed a large, hyperenhancing mass in left kidney with central necrosis (arrow). Colour-coded perfusion maps show various perfusion parameters in normal right kidney and diseased left kidney. Red being the region with highest perfusion parameter with purple being the least; B: Time attenuation curve and the perfusion parameters in normal right kidney. Normal renal parenchyma is seen to have high perfusion in the range of 255 mL/100 mL per minute; C: Time attenuation curve and perfusion parameters in the left renal cell carcinoma. There is delayed wash-out of contrast in the region of the tumour as depicted in the graph. MIP: Maximum peak intensity; TTP: Time to peak; BF: Blood flow; BV: Blood volume; MTT: Mean transit time; PMB: Permeability.

significantly^[8,9]. Also the permeability surface area product, MTT, and BF values were reported to be significantly lower in malignant lesions as compared with oncocytomas^[8].

BF and BV are two perfusion parameters which have been found to have significant histological correlation ($P < 0.01$) with MVD as a prognostic marker for RCCs

and the neoangiogenesis associated with RCCs^[8]. The difference in normal cortex and tumoral PS values has been found to best predict RCCs with a cutoff greater than 2.5 mL/100 g per minute having sensitivity, specificity, and accuracy of 100%, 66.67%, and 95.92%^[5]. Hence, evaluation of the different perfusion parameters can depict histologic grade of RCCs.

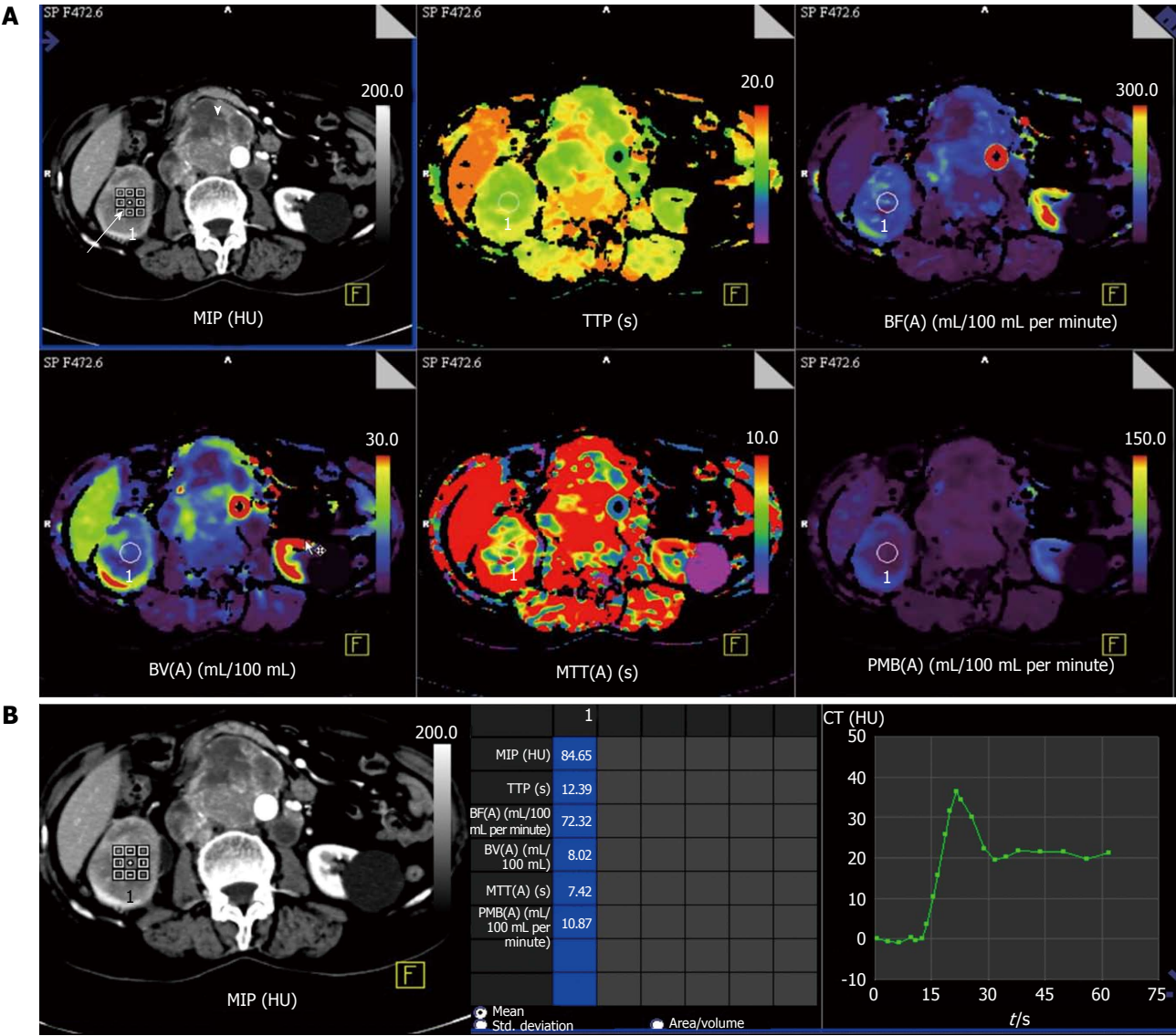


Figure 2 Perfusion computed tomography in a 63-year-old lady with right renal cell carcinoma (chromophobe type). A: Contrast computed tomography (CT) images show tumor in right kidney (white arrow) with retroperitoneal nodal metastases (arrowhead). Colour-coded perfusion maps show the perfusion parameters; B: Time attenuation curve and perfusion parameters with region-of-interest in the right renal cell carcinoma depict delayed wash-out of contrast. MIP: Maximum peak intensity; TTP: Time to peak; BF: Blood flow; BV: Blood volume; MTT: Mean transit time; PMB: Permeability.

Table 4 Response evaluation using changes in computed tomography perfusion parameters in two representative cases								
Date of study			MIP (HU)	TTP (s)	BF (mL/100 mL per minute)	BV (mL/100 mL)	MTT (s)	PMB (mL/100 mL per minute)
Case 1	2013-4-2	Normal cortex	120	11.1	202.9	31.6	8.7	47.1
		Renal tumour	134	13.5	184.9	30.8	10.4	45.95
	2013-9-11	Normal cortex	121	13.2	209	30.2	9.2	50.2
		Renal tumour	79	11.5	174	13.2	5	18.1
	2013-11-20	Normal cortex	130	10.8	229	32	9.6	45.3
		Renal tumour	42	12.3	5.7	1.2	12.4	8.2
Case 2	2013-10-23	Normal cortex	157	11.9	236	27.8	8.9	43.7
		Renal tumour	88	12.3	64.4	9.3	8.9	18.7
	2013-12-26	Normal cortex	140	15.2	170.9	29.5	10.5	42.1
		Renal tumour	82.7	14.8	60.9	7.9	8.4	13.8
	2013-8-3	Normal cortex	216	12.5	315	38	72	55.2
		Renal tumour	84.6	12.3	72.3	8	7.4	10.8

BF: Blood flow; BV: Blood volume; MTT: Mean transit time; PMB: Permeability; MIP: Maximum peak intensity; TTP: Time to peak.

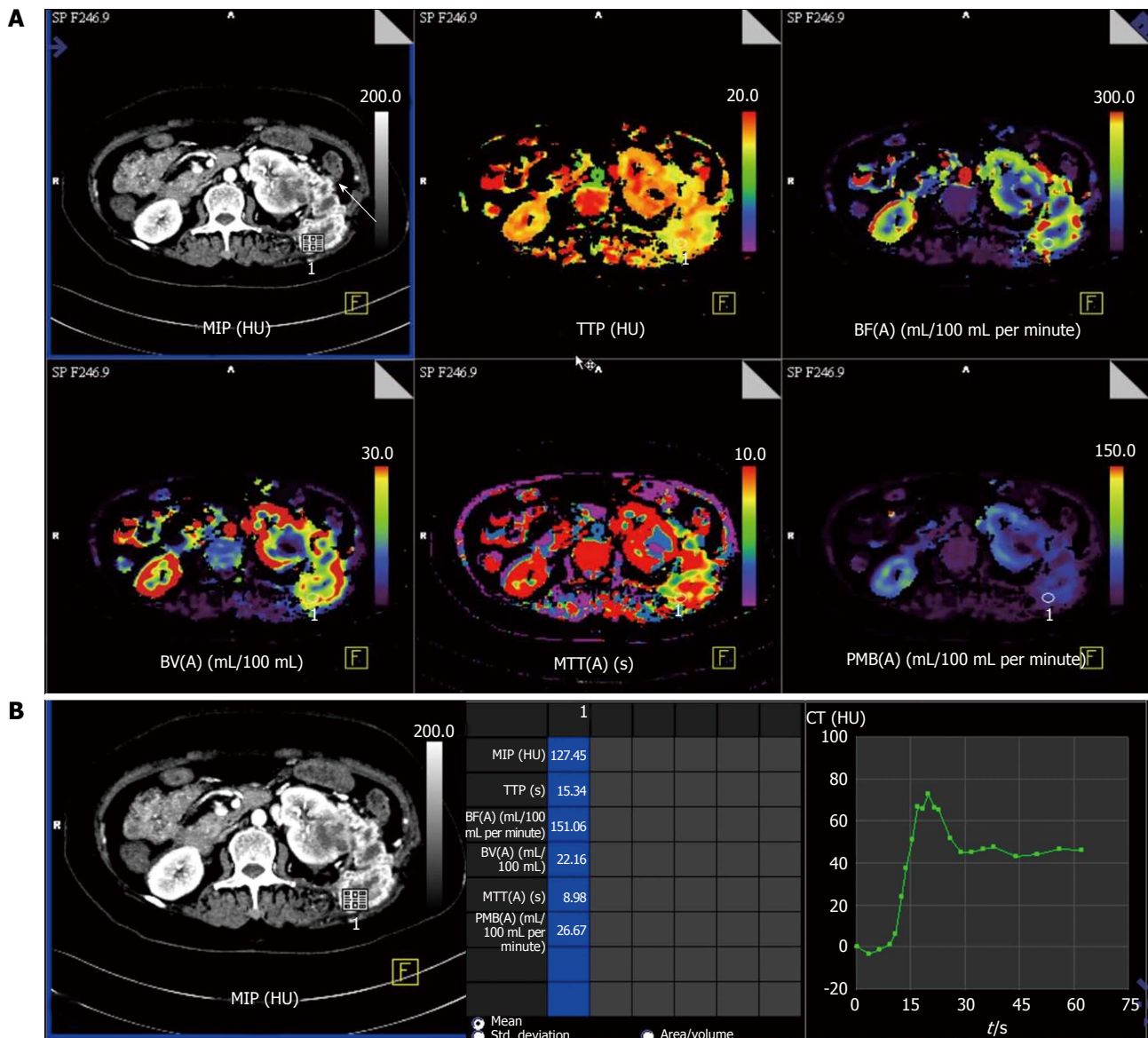


Figure 3 Perfusion computed tomography in a 55-year-old lady with metastatic left renal cell carcinoma. A: Contrast computed tomography (CT) images show heterogeneous necrotic mass in left kidney with abdominal wall metastatic deposit in left lumbar region (arrow) and colour-coded perfusion maps show the perfusion parameters; B: Time attenuation curve and perfusion parameters with region-of-interest placed in the metastatic left lumbar lesion depict delayed wash-out of contrast from the tumour deposit. MIP: Maximum peak intensity; TTP: Time to peak; BF: Blood flow; BV: Blood volume; MTT: Mean transit time; PMB: Permeability.

Response evaluation with anti-angiogenic therapy:

Predicting response assessment with anti-angiogenic therapy can be done with pCT (e.g., colorectal)^[10]. It is known that growth of primary tumor as well as seeding of distant metastasis in patients with renal tumors requires angiogenesis. By inhibiting angiogenesis, it is possible to target both the primary tumor as well as metastases.

The role of several antiangiogenic therapies in RCC are currently being evaluated in clinical trials^[11-14]. However, these anti-angiogenic therapies are predominantly cytostatic in action rather than cytotoxic and induce disease stabilization rather than tumor regression (Figures 3-5). Thereby, traditional response assessment based on size criteria by using the Response Evaluation Criteria in Solid Tumors (RECIST) is rendered

inadequate for follow-up and prognostication of patients on anti-angiogenic therapy. In such instances, functional evaluation with pCT can play a major role. There are few studies highlighting the role of pCT for assessing effect of antiangiogenesis^[15-17].

Significant differences in pCT parameters have been described between treated tumors and control tumors in a rat model by Kan *et al.*^[16]. There was significant difference in these parameters after interventional therapy as compared with the pre-therapy in an investigation in a rabbit model^[17].

Maksimovic *et al.*^[18] in their study using tyrosine kinase inhibitor sorafenib found that perfusion parameters changes appear much earlier before changes in size during therapy. Also early disease progression identification seen as new areas of tumour perfusion

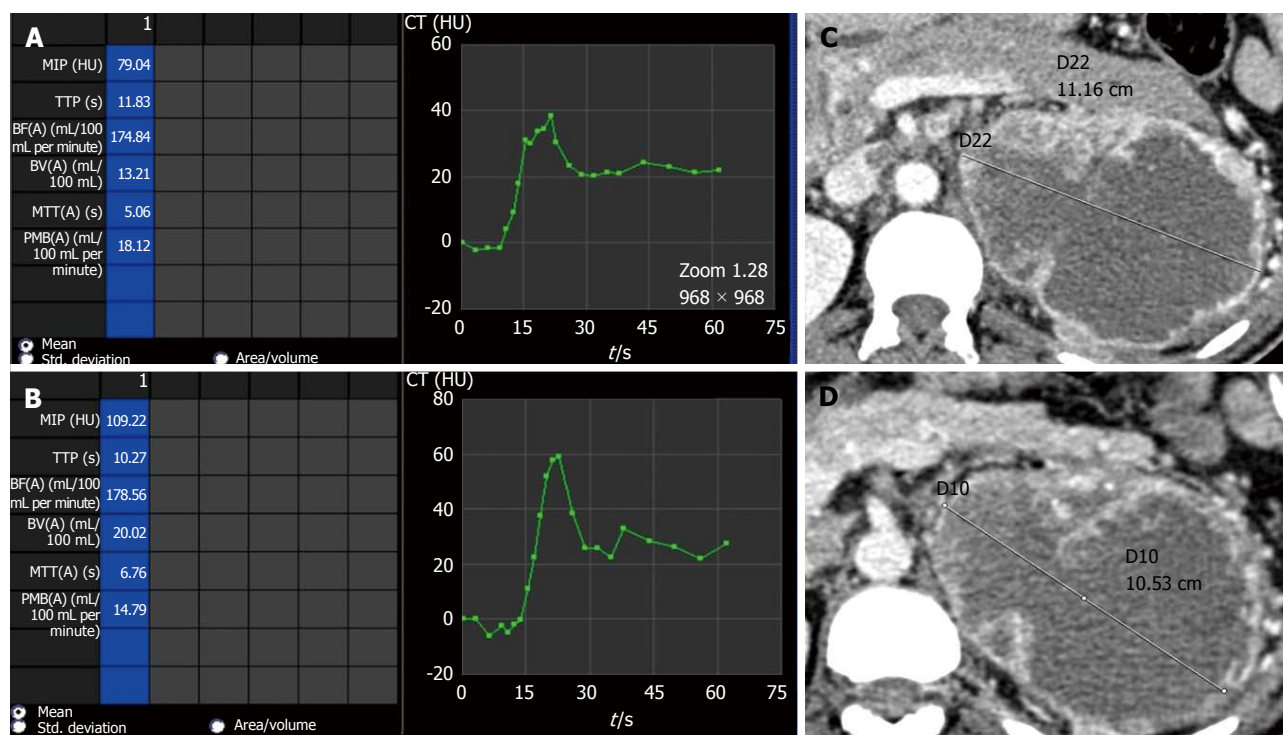


Figure 4 Perfusion parameters vs size evaluation in depicting partial response. Comparison of perfusion parameters in a case of left side clear cell renal cell carcinoma after start of anti-angiogenic therapy. Follow-up scan at 6 mo interval (B) showed at 6 mo interval shows decrease in permeability as compared to baseline scan (A) suggestive of partial response. However, no change in size of lesion noted between baseline (C) and follow-up (D) scans which would have been labelled as stable disease. MIP: Maximum peak intensity; TTP: Time to peak; BF: Blood flow; BV: Blood volume; MTT: Mean transit time; PMB: Permeability; CT: Computed tomography.

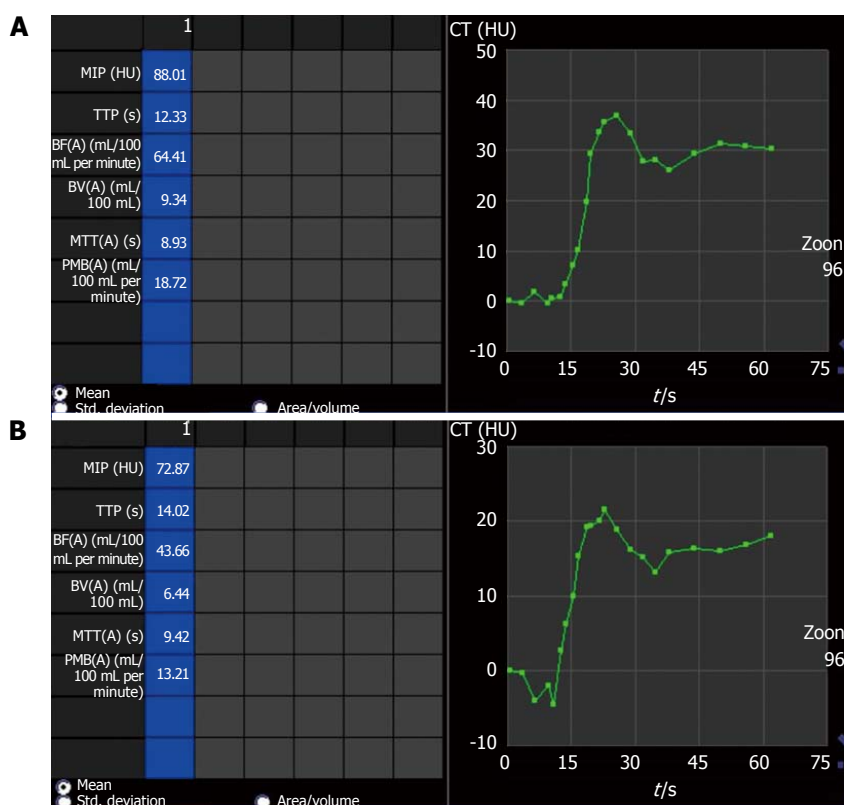


Figure 5 Perfusion parameters showing partial response with anti-angiogenic therapy. Comparison of perfusion parameters in right side chromophobe renal cell carcinoma (same patient as shown in Figure 2) after start of anti-angiogenic therapy shows partial response as permeability (PMB) in follow-up scan (B) at 6 mo interval decreased compared to baseline scan (A). The PMB measured 18.72 mL/100 mL per minute at baseline (A) while in follow-up scan (B), PMB was 13.2 mL/100 mL per minute. There was no interval change in lesion size and would have been labeled as stable disease in absence of perfusion parameters. MIP: Maximum peak intensity; TTP: Time to peak; BF: Blood flow; BV: Blood volume; MTT: Mean transit time; CT: Computed tomography.

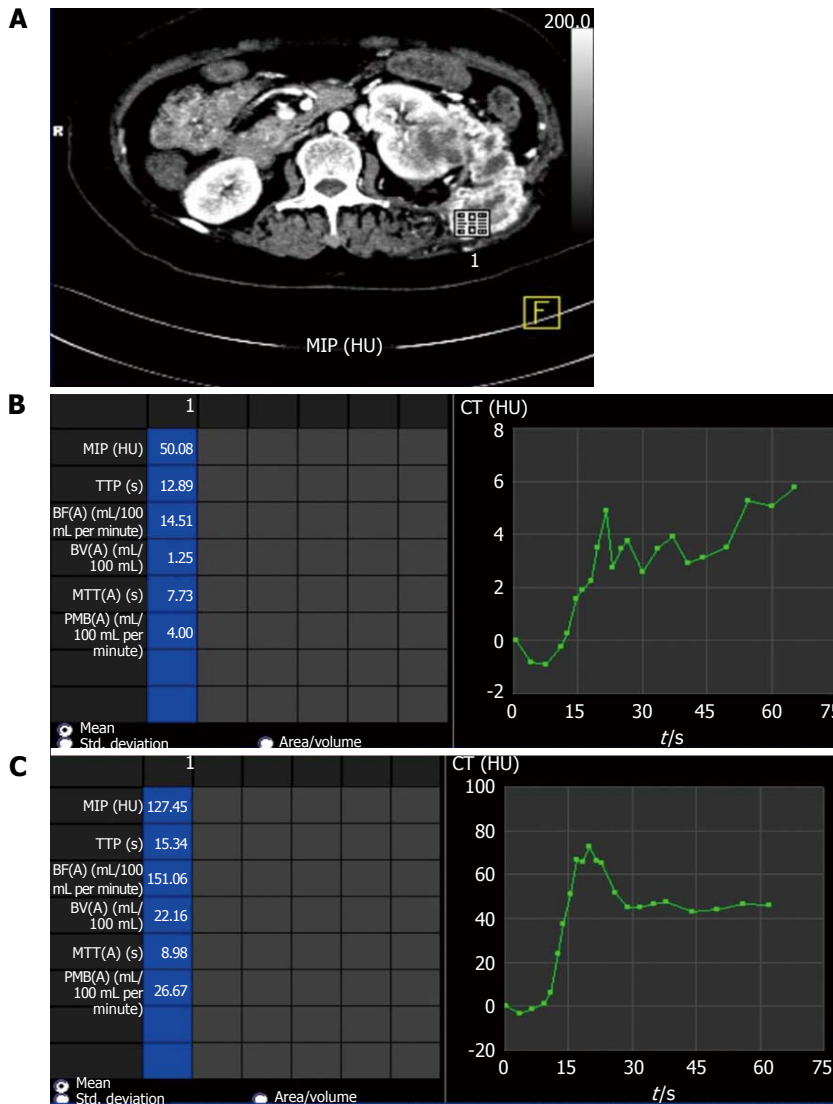


Figure 6 Perfusion parameters showing progressive disease with anti-angiogenic therapy. Comparison of perfusion parameters in left metastatic renal cell carcinoma (A) after start of anti-angiogenic therapy at 6 mo interval shows progressive disease as permeability (PMB) at baseline scan (B) was 4.00 mL/100 mL per minute which increased to 26.67 mL/100 mL per minute in follow-up scan (C). There was also increase in size and extent of lesions during this interval (not shown). MIP: Maximum peak intensity; TTP: Time to peak; BF: Blood flow; BV: Blood volume; MTT: Mean transit time; CT: Computed tomography.

would enable clinicians to change therapy. A targeted biopsy and therapy by identification of the specific area at an early stage can be performed^[19].

Perfusion parameters can also be utilized to prognosticate response to therapy. Patients responding to antiangiogenic therapy had higher baseline values of BF and BV than in those patients whose perfusion parameters remained stable throughout follow-up^[20].

Significant decrease in BF, BV and PMB can be seen in those patients responding to antiangiogenic therapy (case 1 in Table 4) (Figures 3 and 4) while those showing progression showed increase in these perfusion parameters over serial follow-up (case 2 in Table 4) (Figure 5).

Evaluation of metastases: Metastases are commonly seen in RCCs. Most are hematogenous and are highly vascular. Amongst the different histologic subtypes,

ccRCCs have the highest risk of developing metastatic disease and is seen in more than 90% of cases^[21]. Since maximum anatomic coverage during pCT is limited, hence evaluation of distant metastasis is challenging considering the increasing radiation burden with increase in the region covered. However, evaluation of RCC metastases is made possible in most cases because of the characteristic distribution of these metastases in lung bases, liver, adrenal glands, pancreas, retroperitoneal lymph nodes (Figure 2) and lumbar fossa (Figure 6)^[22]. The renal metastases show similar contrast enhancement as the parent tumor and may be evaluated for treatment response by using pCT.

Pitfalls of pCT

As true for any imaging technique, pCT also has certain technical limitations. These include high radiation burden as shown in Table 5 because of the repetitive scans

Table 5 Comparison of the acquisition parameters and dose in dynamic acquisition of perfusion computed tomography and normal contrast enhanced computed tomography chest and abdomen in our institute

	Dynamic acquisition	Chest and abdomen scan (routine)
Exposure time (s)	33	14.24
Scan length (mm)	155	655
Collimation (mm)	1.2	0.6
KVp	100	100
Ma	523	211
CTDI vol (mGy)	180.1	7.2
DLP (mGycm)	2789.69	458.68

CTDI vol: Computed tomography dose index volumetric; DLP: Dose length product.

acquired over a period of time and limited anatomic coverage. As the scan has to be repeated within a short span of time, the actual anatomic length that can be covered is limited (maximum up to about 20 cm). This imposes a limitation on the evaluation of distant metastases which may be present in such patients.

CONCLUSION

pCT is an evolving imaging modality which provides deeper insights into the molecular behavior of tumor angiogenesis and thereby facilitating targeted therapy. It has revolutionized oncologic imaging by prognosticating and evaluating therapy response at an earlier stage. Other potential benefits include identifying tumor histological subtype and predicting potentially aggressive tumors which can help clinicians to better plan the therapy of patients. As an emerging technique, pCT is currently used in evaluation of malignancies of different body parts such as kidneys, brain, lung, liver, pancreas and colon. In the future, pCT is likely to become the *in vivo* biomarker for tumor behavior and response evaluation in malignant lesions of different body parts.

REFERENCES

- Gigli F, Zattoni F, Zamboni G, Valotto C, Bernardin L, Mucelli RP, Zattoni F. [Correlation between pathologic features and perfusion CT of renal cancer: a feasibility study]. *Urologia* 2010; **77**: 223-231 [PMID: 21234864]
- Miles KA. Tumour angiogenesis and its relation to contrast enhancement on computed tomography: a review. *Eur J Radiol* 1999; **30**: 198-205 [PMID: 10452718 DOI: 10.1016/S0720-048X(99)00012-1]
- Miles KA, Griffiths MR. Perfusion CT: a worthwhile enhancement? *Br J Radiol* 2003; **76**: 220-231 [PMID: 12711641 DOI: 10.1259/bjr/13564625]
- Miles KA. Functional CT imaging in oncology. *Eur Radiol* 2003; **13** Suppl 5: M134-M138 [PMID: 14989624 DOI: 10.1016/S0959-8049(02)00386-6]
- Mazzei FG, Mazzei MA, Cioffi Squitieri N, Pozzessere C, Righi L, Cirigliano A, Guerrini S, D'Elia D, Ambrosio MR, Barone A, del Vecchio MT, Volterrani L. CT perfusion in the characterisation of renal lesions: an added value to multiphasic CT. *Biomed Res Int* 2014; **2014**: 135013 [PMID: 25184133 DOI: 10.1155/2014/135013]
- Chandarana H, Rosenkrantz AB, Mussi TC, Kim S, Ahmad AA, Raj SD, McMenamy J, Melamed J, Babb JS, Kiefer B, Kiraly AP. Histogram analysis of whole-lesion enhancement in differentiating clear cell from papillary subtype of renal cell cancer. *Radiology* 2012; **265**: 790-798 [PMID: 23175544 DOI: 10.1148/radiol.12111281]
- Chen Y, Zhang J, Dai J, Feng X, Lu H, Zhou C. Angiogenesis of renal cell carcinoma: perfusion CT findings. *Abdom Imaging* 2010; **35**: 622-628 [PMID: 19763683 DOI: 10.1007/s00261-009-9565-0]
- Chen C, Liu Q, Hao Q, Xu B, Ma C, Zhang H, Shen Q, Lu J. Study of 320-slice dynamic volume CT perfusion in different pathologic types of kidney tumor: preliminary results. *PLoS One* 2014; **9**: e85522 [PMID: 24465588 DOI: 10.1371/journal.pone.0085522]
- Reiner CS, Roessle M, Thiesler T, Eberli D, Klotz E, Frauenfelder T, Sulser T, Moch H, Alkadhi H. Computed tomography perfusion imaging of renal cell carcinoma: systematic comparison with histopathological angiogenic and prognostic markers. *Invest Radiol* 2013; **48**: 183-191 [PMID: 23328912 DOI: 10.1097/RLI.0b013e31827c63a3]
- Sahani DV, Kalva SP, Hamberg LM, Hahn PF, Willett CG, Saini S, Mueller PR, Lee TY. Assessing tumor perfusion and treatment response in rectal cancer with multisection CT: initial observations. *Radiology* 2005; **234**: 785-792 [PMID: 15734934 DOI: 10.1148/radiol.2343040286]
- Dhanabal M, Ramchandran R, Volk R, Stillman IE, Lombardo M, Iruela-Arispe ML, Simons M, Sukhatme VP. Endostatin: yeast production, mutants, and antitumor effect in renal cell carcinoma. *Cancer Res* 1999; **59**: 189-197 [PMID: 9892206]
- Morita T, Shinohara N, Tokue A. Antitumour effect of a synthetic analogue of fumagillin on murine renal carcinoma. *Br J Urol* 1994; **74**: 416-421 [PMID: 7529632 DOI: 10.1111/j.1464-410X.1994.tb00415.x]
- Fujioka T, Hasegawa M, Ogiu K, Matsushita Y, Sato M, Kubo T. Antitumor effects of angiogenesis inhibitor 0-(chloroacetyl-carbamoyl) fumagillol (TNP-470) against murine renal cell carcinoma. *J Urol* 1996; **155**: 1775-1778 [PMID: 8627882 DOI: 10.1016/S0022-5347(01)66196-2]
- Stadler WM, Kuzel T, Shapiro C, Sosman J, Clark J, Vogelzang NJ. Multi-institutional study of the angiogenesis inhibitor TNP-470 in metastatic renal carcinoma. *J Clin Oncol* 1999; **17**: 2541-2545 [PMID: 10561320]
- Koukourakis MI, Mavanis I, Kouklakis G, Pitiakoudis M, Minopoulos G, Manolas C, Simopoulos C. Early antivascular effects of bevacizumab anti-VEGF monoclonal antibody on colorectal carcinomas assessed with functional CT imaging. *Am J Clin Oncol* 2007; **30**: 315-318 [PMID: 17551312 DOI: 10.1097/01.coc.0000258119.90805.ca]
- Kan Z, Phongkitkarun S, Kobayashi S, Tang Y, Ellis LM, Lee TY, Charnsangavej C. Functional CT for quantifying tumor perfusion in antiangiogenic therapy in a rat model. *Radiology* 2005; **237**: 151-158 [PMID: 16183931 DOI: 10.1148/radiol.2363041293]
- Zhang J, Wang R, Lou H, Zou Y, Zhang M. Functional computed tomographic quantification of angiogenesis in rabbit VX2 soft-tissue tumor before and after interventional therapy. *J Comput Assist Tomogr* 2008; **32**: 697-705 [PMID: 18830097 DOI: 10.1097/RCT.0b013e31815b7dcf]
- Maksimovic O, Schraml C, Hartmann JT, Bitzer M, Claussen CD, Pintoff J, Horger M. Evaluation of response in malignant tumors treated with the multitargeted tyrosine kinase inhibitor sorafenib: a multitechnique imaging assessment. *AJR Am J Roentgenol* 2010; **194**: 5-14 [PMID: 20028898 DOI: 10.2214/AJR.09.2744]
- Sabir A, Schor-Bardach R, Wilcox CJ, Rahmanuddin S, Atkins MB, Kruskal JB, Signoretti S, Raptopoulos VD, Goldberg SN. Perfusion MDCT enables early detection of therapeutic response to antiangiogenic therapy. *AJR Am J Roentgenol* 2008; **191**: 133-139 [PMID: 18562736 DOI: 10.2214/AJR.07.2848]
- Fournier LS, Oudard S, Thiam R, Trinquart L, Banu E, Medioni J, Balvay D, Chatellier G, Fria G, Cuenod CA. Metastatic renal

- carcinoma: evaluation of antiangiogenic therapy with dynamic contrast-enhanced CT. *Radiology* 2010; **256**: 511-518 [PMID: 20551183 DOI: 10.1148/radiol.10091362]
- 21 **Motzer RJ**, Bacik J, Mariani T, Russo P, Mazumdar M, Reuter V. Treatment outcome and survival associated with metastatic renal cell carcinoma of non-clear-cell histology. *J Clin Oncol* 2002; **20**: 2376-2381 [PMID: 11981011 DOI: 10.1200/JCO.2002.11.123]
- 22 **Bianchi M**, Sun M, Jeldres C, Shariat SF, Trinh QD, Briganti A, Tian Z, Schmitges J, Graefen M, Perrotte P, Menon M, Montorsi F, Karakiewicz PI. Distribution of metastatic sites in renal cell carcinoma: a population-based analysis. *Ann Oncol* 2012; **23**: 973-980 [PMID: 21890909 DOI: 10.1093/annonc/mdr362]

P- Reviewer: Cerwenka HR, Chen F, Nouh MR

S- Editor: Tian YL **L- Editor:** A **E- Editor:** Liu SQ





Published by **Baishideng Publishing Group Inc**

8226 Regency Drive, Pleasanton, CA 94588, USA

Telephone: +1-925-223-8242

Fax: +1-925-223-8243

E-mail: bpgoffice@wjgnet.com

Help Desk: <http://www.wjgnet.com/esps/helpdesk.aspx>

<http://www.wjgnet.com>

