



Multiparametric ultrasound as a new concept of assessment of liver tissue damage

Angela Peltec, Ioan Sporea

Specialty type: Gastroenterology and hepatology

Provenance and peer review: Invited article; Externally peer reviewed.

Peer-review model: Single blind

Peer-review report's scientific quality classification

Grade A (Excellent): 0
Grade B (Very good): 0
Grade C (Good): 0
Grade D (Fair): 0
Grade E (Poor): 0

P-Reviewer: Kumar R, India

Received: December 27, 2023

Peer-review started: December 27, 2023

First decision: January 19, 2024

Revised: February 5, 2024

Accepted: March 12, 2024

Article in press: March 12, 2024

Published online: March 28, 2024



Angela Peltec, Department of Internal Medicine, Discipline of Gastroenterology, State University of Medicine and Pharmacy "Nicolae Testemitanu", Chishinev 2019, Moldova

Ioan Sporea, Department of Gastroenterology and Hepatology, "Victor Babes" University of Medicine and Pharmacy, Timisoara 300736, Romania

Corresponding author: Angela Peltec, MD, PhD, Associate Professor, Department of Internal Medicine, Discipline of Gastroenterology, State University of Medicine and Pharmacy "Nicolae Testemitanu", Testemitanu 29, Chishinev 2019, Moldova. apeltec@yahoo.com

Abstract

Liver disease accounts for approximately 2 million deaths per year worldwide. All chronic liver diseases (CLDs), whether of toxic, genetic, autoimmune, or infectious origin, undergo typical histological changes in the structure of the tissue. These changes may include the accumulation of extracellular matrix material, fats, triglycerides, or tissue scarring. Noninvasive methods for diagnosing CLD, such as conventional B-mode ultrasound (US), play a significant role in diagnosis. Doppler US, when coupled with B-mode US, can be helpful in evaluating the hemodynamics of hepatic vessels and detecting US findings associated with hepatic decompensation. US elastography can assess liver stiffness, serving as a surrogate marker for liver fibrosis. It is important to note that interpreting these values should not rely solely on a histological classification. Contrast-enhanced US (CEUS) provides valuable information on tissue perfusion and enables excellent differentiation between benign and malignant focal liver lesions. Clinical evaluation, the etiology of liver disease, and the patient current comorbidities all influence the interpretation of liver stiffness measurements. These measurements are most clinically relevant when interpreted as a probability of compensated advanced CLD. B-mode US offers a subjective estimation of fatty infiltration and has limited sensitivity for mild steatosis. The controlled attenuation parameter requires a dedicated device, and cutoff values are not clearly defined. Quantitative US parameters for liver fat estimation include the attenuation coefficient, backscatter coefficient, and speed of sound. These parameters offer the advantage of providing fat quantification alongside B-mode evaluation and other US parameters. Multiparametric US (MPUS) of the liver introduces a new concept for complete noninvasive diagnosis. It encourages examiners to utilize the latest features of an US machine, including conventional B-mode, liver stiffness evaluation, fat quantification, dispersion imaging, Doppler US, and CEUS for focal liver lesion characterization. This comprehensive approach allows for

diagnosis in a single examination, providing clinicians worldwide with a broader perspective and becoming a cornerstone in their diagnostic arsenal. MPUS, in the hands of skilled clinicians, becomes an invaluable predictive tool for diagnosing, staging, and monitoring CLD.

Key Words: Multiparametric ultrasound; Ultrasound-based elastography; Liver stiffness; Noninvasive diagnostic test for chronic liver disease; Liver steatosis assessment; Portal hypertension evaluation

©The Author(s) 2024. Published by Baishideng Publishing Group Inc. All rights reserved.

Core Tip: Multiparametric ultrasound (MPUS) of the liver introduces a new concept for complete liver evaluation. It encourages examiners to utilize the latest features of an ultrasound (US) machine, including conventional B-mode, liver stiffness evaluation, fat quantification, dispersion imaging, Doppler US, and contrast-enhanced US for focal liver lesion characterization. MPUS, in the hands of skilled clinicians, becomes an invaluable predictive tool for diagnosing, staging, and monitoring chronic liver disease.

Citation: Peltec A, Sporea I. Multiparametric ultrasound as a new concept of assessment of liver tissue damage. *World J Gastroenterol* 2024; 30(12): 1663-1669

URL: <https://www.wjgnet.com/1007-9327/full/v30/i12/1663.htm>

DOI: <https://dx.doi.org/10.3748/wjg.v30.i12.1663>

INTRODUCTION

Chronic liver disease (CLD) poses a global health challenge, contributing to approximately two million deaths annually worldwide[1]. The nature of these diseases, arising from diverse etiologies, present a complex array of structural and functional abnormalities. The assessment of liver tissue damage is a critical aspect of managing various liver diseases. Historically, liver tissue damage assessment relied heavily on invasive methods such as liver biopsy. Histological changes in liver tissue are characteristic of CLDs, encompassing toxic (alcoholic), genetic, autoimmune, and infectious etiologies [2]. Accumulation of extracellular matrix material, fats, triglycerides, or tissue scarring are common manifestations. The gold standard for evaluating CLDs is a liver biopsy. This is because examining the histologic specimen not only helps with fibrosis staging but also provides additional information about necroinflammation and other pathological changes. Offering direct insights into histopathological changes, it is an invasive procedure carrying potential complications and limitations such as sampling errors and interobserver variability. This underscores the necessity for noninvasive alternatives[3-5].

Traditional B-mode ultrasound (US) has been a cornerstone in diagnosing liver diseases, providing valuable insights into structural abnormalities[6]. Recent developments have expanded the diagnostic capabilities of US. Doppler US, when combined with B-mode imaging, offers a nuanced evaluation of hepatic vessel hemodynamics and identifies findings associated with hepatic decompensation. Contrast-enhanced US (CEUS) enhances tissue perfusion assessment, facilitating the differentiation between benign and malignant liver lesions[7]. US-based elastography, measuring liver stiffness, emerges as a pivotal tool for assessing liver fibrosis. However, its interpretation must consider clinical evaluation, the etiology of the liver disease, and the patient's comorbidities. These measurements prove most clinically relevant when viewed as a probability of compensated advanced CLD (cACLD)[8]. Accurate diagnosis of liver disease is essential for effective management and timely intervention. Multiparametric US (MPUS) addresses this challenge by combining multiple imaging parameters to offer a detailed and nuanced assessment of liver health. The advent of MPUS marks a paradigm shift in liver disease diagnosis. By integrating various US features such as B-mode, liver stiffness, fat quantification, dispersion imaging, Doppler US, and CEUS, clinicians gain a comprehensive diagnostic perspective in a single examination. MPUS, when wielded by skilled clinicians, becomes an invaluable predictive tool for diagnosing, staging, and monitoring CLDs. The ability to provide a broader perspective enhances diagnostic accuracy, empowering clinicians worldwide with efficient diagnostic tools. The evolution of noninvasive methods, particularly MPUS, has revolutionized the landscape of liver disease diagnosis.

COMPONENTS OF MPUS

Traditional B-mode US remains a fundamental component, providing a structural overview of liver tissue. However, its limitations in detecting mild steatosis emphasize the need for a more comprehensive approach. When coupled with B-mode imaging, Doppler US enhances the evaluation of hepatic vessel hemodynamics. This addition aids in identifying early signs of hepatic decompensation, contributing to a more thorough diagnostic picture. Vascular thrombosis can be diagnosed very simply with standard US and with Doppler evaluation. CEUS provides valuable information on tissue perfusion, enabling accurate differentiation between benign and malignant focal liver lesions. The enhanced imaging

capabilities contribute significantly to the diagnostic accuracy of MPUS. US-based elastography serves as a surrogate marker for liver fibrosis. However, the interpretation of these measurements requires a holistic consideration of clinical evaluation, the underlying etiology, confounding factors, and the patient comorbidities. The limitations of B-mode US in estimating fatty infiltration underscore the need for comprehensive approaches. The controlled attenuation parameter, though requiring a dedicated device, contributes valuable insights. Quantitative US parameters like attenuation coefficient, backscatter coefficient, and speed of sound offer a holistic evaluation of liver fat, complementing B-mode assessments. Interpreting results from noninvasive methods requires a nuanced understanding of the underlying liver disease, patient comorbidities, and the specific modality used. A comprehensive clinical evaluation is essential for accurate diagnosis. The availability of advanced diagnostic technologies varies globally, impacting the accessibility of these noninvasive methods. Efforts to enhance accessibility and reduce disparities are crucial for widespread adoption. Standardizing the interpretation of results and establishing cutoff values for different modalities remain ongoing challenges. Consistent guidelines are necessary to ensure uniformity in assessments across healthcare settings. Standardization efforts are essential to enhance reliability and comparability. The field of liver tissue damage assessment is rapidly evolving. Future advancements may involve the integration of artificial intelligence for enhanced diagnostic accuracy, the development of novel serum biomarkers, and the refinement of existing technologies to address current limitations. Introduction of these new modules of evaluation (stiffness, fatty quantification) to a middle-class US machine is essential for the future accessibility of these new developments of the method.

BEYOND FIBROSIS: THE COMPREHENSIVE ROLE OF ELASTOGRAPHY IN ASSESSING LIVER TISSUE HEALTH

Liver fibrosis, a key feature of CLDs caused by various factors, can progress to liver cirrhosis along with its associated complications[3]. Evaluating the presence and extent of liver fibrosis is crucial in managing CLD patients as it can anticipate the prognosis and potentially impact treatment decision. Initially developed to estimate liver fibrosis by measuring tissue stiffness, elastography has transcended its original purpose. Elastography, once primarily associated with fibrosis assessment, has evolved into a versatile method offering insights into various aspects of liver tissue health (Figure 1).

Now, many experts explore the expanding role of elastography beyond fibrosis evaluation, highlighting its diverse applications in assessing the dynamic nature of liver tissues[8]. A model centered on applications of elastography beyond fibrosis offers several options including: (1) Liver steatosis assessment. Elastography has shown promise in quantifying liver steatosis, providing a noninvasive means to evaluate fat content. Identifying and quantifying fat infiltration contributes to a more comprehensive understanding of liver health; (2) inflammation detection. The dynamic nature of elastography allows for the detection of inflammatory changes within liver tissues. By assessing tissue stiffness alterations, elastography aids in identifying inflammation, a crucial factor in the progression of various liver diseases; (3) portal hypertension evaluation. Elastography provides valuable insights into portal hypertension by assessing liver stiffness. Monitoring changes in stiffness aids in understanding the impact of portal hypertension on liver tissues and guides appropriate interventions; and (4) monitoring treatment response. Elastography serves as a tool for monitoring responses to therapeutic interventions. Whether assessing the effectiveness of anti-inflammatory treatments or tracking changes in liver stiffness post-treatment, elastography offers real-time feedback on treatment outcomes (Figure 1).

However, there are some confounding factors that can increase the liver stiffness. These confounding factors can contribute to a false increase in liver stiffness. Cholestasis refers to the impaired flow of bile, leading to the accumulation of bile acids and other substances within the liver. The accumulation of bile acids and other components in liver tissue may lead to inflammation and fibrosis. Elastography measurements in cholestatic conditions may indicate increased liver stiffness, reflecting the fibrotic changes associated with chronic cholestasis.

Hepatic congestion, often seen in conditions such as congestive heart failure, can impact liver stiffness as well. Congestion in the liver causes increased pressure within the hepatic vasculature. This elevated pressure can affect the mechanical properties of liver tissue, leading to changes in stiffness. Elastography may detect increased liver stiffness in cases of hepatic congestion, indicating the mechanical alterations caused by elevated intrahepatic pressure (Figure 1). Assessing the severity of cholestasis, the degree of congestion, and other contributing factors is essential for accurate diagnosis and appropriate clinical management. However, the interpretation should be conducted in the broader clinical context, considering the underlying causes and potential coexisting factors influencing liver health.

Various techniques, such as shear wave elastography (SWE) and strain elastography, have demonstrated their efficacy in assessment of the mechanical properties of liver tissues. Various SWE techniques evaluate the speed of shear waves produced through mechanically induced stress. US SWE methods encompass vibration-controlled transient elastography (VCTE) and techniques based on acoustic radiation force impulse (ARFI). In VCTE, shear waves result from vibration controlled at the body surface, while in ARFI-based techniques, the waves stem from the push-pulse of a focused US beam. ARFI-based techniques comprise point SWE (pSWE), assessing stiffness in a specific and constant region, and two-dimensional SWE (2D-SWE), measuring stiffness across a broader area, accompanied by a color-coded parametric map of stiffness. The results of US SWE techniques are typically presented in meters per second (m/s), representing shear wave velocity. Alternatively, they can be converted to Young's modulus in kilopascals (kPa), although this conversion relies on assumptions that may not always be accurate[9].

Regular monitoring of liver stiffness can aid in assessing disease progression and the effectiveness of interventions in managing these conditions. It is crucial to interpret liver stiffness values in the context of the patient's clinical history, including the underlying cause of cholestasis or congestion. The ongoing evolution of elastography suggests a promising

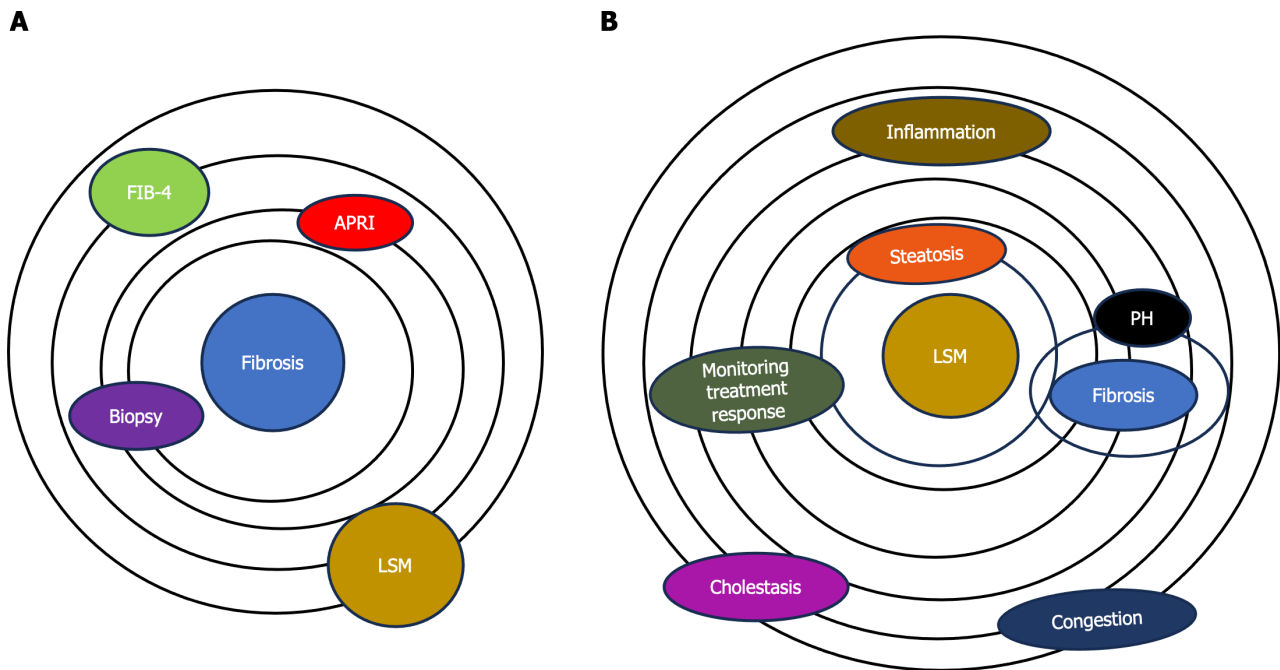


Figure 1 Role of elastography in assessing liver tissue health. A: Model of assessment of fibrosis. Elastography, once primarily associated with fibrosis assessment (biopsy, different noninvasive scores like fibrosis index based on 4 factors, aspartate aminotransferase-to-platelet index, *etc*); B: Model of assessment of liver stiffness. Now, elastography has evolved into a versatile method offering assessment of the mechanical properties and dynamic nature of liver tissues such as the quantification of liver steatosis by providing a noninvasive means for evaluation of fat content and the detection of inflammatory changes within liver tissues. Elastography may provide valuable insights into portal hypertension and monitor responses to therapeutic interventions. There are some confounding factors (cholestasis and heart congestion) that can contribute to increasing the liver stiffness. LSM: Liver stiffness measurement; FIB-4: Fibrosis index based on 4 factors; APRI: Aminotransferase-to-platelet index; PH: Portal hypertension.

future in liver tissue assessment. Advances in technology and research may lead to further refinements, increased standardization, and expanded applications, solidifying elastography as a cornerstone in liver health diagnostics. Elastography has transcended its initial role in fibrosis assessment, emerging as a powerful tool for comprehensive liver tissue evaluation. From steatosis to inflammation and portal hypertension, the diverse applications of elastography offer a nuanced understanding of liver health. As technology and standardization efforts progress, elastography is poised to play an increasingly central role in noninvasive liver assessments, shaping the future of liver disease diagnosis and management.

LIVER STIFFNESS MEASUREMENT IS USED TO STRATIFY THE SEVERITY OF LIVER DISEASE

The acronym advanced CLD (ACLD) is employed for individuals in the advanced stages of CLD and serves as an alternative to the term "cirrhosis," which is based on histology[10,11]. This designation is intended to encompass a wide range of patients, including those with significant liver fibrosis (bridging fibrosis) as observed in histology and those with compensated cirrhosis[12].

Many studies and meta-analyses proposed different cutoff values for liver stiffness evaluation with VCTE and in connection with different etiologies. In the Baveno VI and Baveno VII consensus[13] "rule of 5" was accepted. This is a very simple modality of stiffness value classification where < 5 kPa means normal liver, less than 10 kPa excludes cACLD, more than 15 kPa assumes cACLD, and more than 25 kPa assumes clinically significant portal hypertension (CSPH). This rule in daily practice can be used for a lot of purposes, like assessment of fibrosis and determining cACLD or CSPH (if liver stiffness is more than 25 kPa, the upper endoscopy can be avoided). Using the VCTE system in a patient and starting with the controlled attenuation parameter, we can stratify severity of steatosis and significant fibrosis can be determined in a very short time. It is important to note that while VCTE provides valuable information about liver stiffness, the interpretation should always be performed in conjunction with other clinical assessments, including medical history, laboratory tests, and potentially additional imaging studies and excluding confounding factors (including fasting, elevated aminotransferases, obstructive cholestasis, or right heart failure). As a prognostic tool, adopting the rule of 5 with cutoff values of liver stiffness measurement (LSM) using VCTE (10-15-20-25 kPa) is suggested. This approach enables a rapid estimation of the risk of decompensation and liver-related deaths, irrespective of the etiology of ACLD (Figure 2).

ARFI methods (pSWE and 2D-SWE) are implemented in a US system and can be used for standard US evaluation, Doppler examination, fatty quantification, stiffness measurement, and lesion discovery (focal liver lesion). Immediately, a CEUS examination can be performed. Then finally, this evaluation a MPUS method.

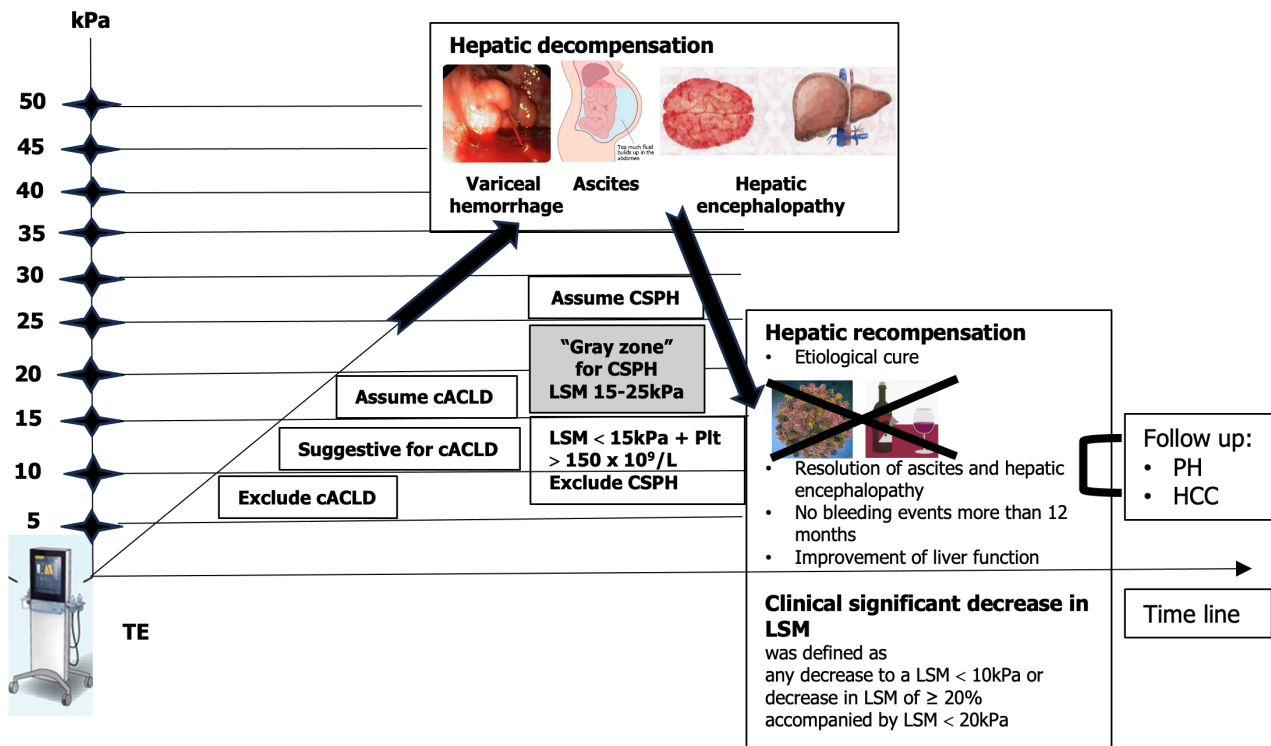


Figure 2 Use of noninvasive tests according to the rule of 5 to determine compensated advanced chronic liver disease and clinically significant portal hypertension. Dynamic use of noninvasive tests for assessment of hepatic decompensation or recompensation. Patients having a liver stiffness measurement (LSM) < 10 kPa rules out compensated advanced chronic liver disease (cACLD) in the absence of other clinical/imaging signs. LSM values between 10 kPa and 15 kPa are suggestive of cACLD, and LSM ≤ 15 kPa plus platelets ≥ 150 × 10⁹/L rule out clinically significant portal hypertension (CSPH) in the majority of etiologies. LSM measured by transient elastography (TE) > 15 kPa are considered as a high likelihood of cACLD in all etiologies. Patients with intermediate values of LSM between 15 kPa and 25 kPa are in a "gray zone" of CSPH. The best cutoff to determine the presence of CSPH was an LSM ≥ 25 kPa (specificity and positive predictive value > 90%) in alcoholic liver disease, chronic hepatitis B, chronic hepatitis C, and non-obese patients with nonalcoholic steatohepatitis. Hepatic recompensation includes all of the following criteria: Suppression or removal of the underlying etiology of cirrhosis; Resolution of ascites and hepatic encephalopathy after discontinuation of diuretics and prophylactic therapies; Absence of variceal bleeding for 12 months; Sustained improvement of biochemical liver function, assessed by serum albumin, bilirubin, and international normalized ratio[13]. LSM: Liver stiffness measurement; HCC: Hepatocellular carcinoma; PH: Portal hypertension; TE: Transient elastography.

For many years, every company proposed their own cutoff values. Then in practice it was quite difficult to use these values. In 2020 a proposed algorithm, the "Rule of 4" for interpretation of liver stiffness (5-9-13-17 kPa), was presented [14]. In this system, it is quite easy to use the cutoffs for ARFI methods. If the values are < 5 kPa, the liver is normal, and below 9 kPa rules out cACLD. Values between 9-13 kPa are suggestive for cACLD and more than 13 kPa suggests the presence of cACLD. Values > 17 kPa are suggestive for CSPH (Figure 3). Concerning the practical value of SWE methods for liver stiffness evaluation, many published papers show the good results of these methods. There are meta-analyses and prospective studies (with most using liver biopsy as the gold standard). All these studies show that the area under the receiver operating characteristic curve of the methods increases with the severity of fibrosis, with more than 90% for liver cirrhosis[15-18].

Conventionally, cirrhosis progression was seen as a one-way street, transitioning inevitably from a compensated to a decompensated stage[19]. Yet, a growing body of evidence suggests that effective treatment or the elimination of the underlying liver disease etiology not only decelerates disease advancement but can even result in disease regression. The outlook is more optimistic than we once thought! The evolution in how we perceive things led to the development of the idea of hepatic recompensation[13]. This involves a significant improvement in hepatic function, along with a reduction in functional and structural factors like hepatic inflammation, fibrosis, and portal hypertension, all stemming from the successful treatment of the underlying cause. It emphasizes the encouraging potential for positive changes in liver health.

Numerous studies have investigated the significance of LSM in predicting liver-related events in individuals with liver diseases. However, a majority of these studies rely on one-time assessments. Precision in determining the long-term risk of liver complications based on a single LSM remains challenging. This is due to the fact that patients may encounter various situations over time, such as alterations in alcohol consumption, the emergence of metabolic disturbances, resolution of the underlying etiologic factor, or the introduction of new contributing factors, all of which can impact their prognosis. Repeated LSM offer an enhanced understanding of the liver disease's natural progression, potentially enabling personalized treatment decisions when integrated into clinical decision-making. However, certain aspects still require further exploration. Determining the optimal frequency of LSMs and the intervals between them must be established and proven to be cost-effective. Changes in LSM over time can be regarded as a dynamic prognostic biomarker. Repeated LSM holds the potential to refine predictions and individualize treatment strategies in clinical practice.

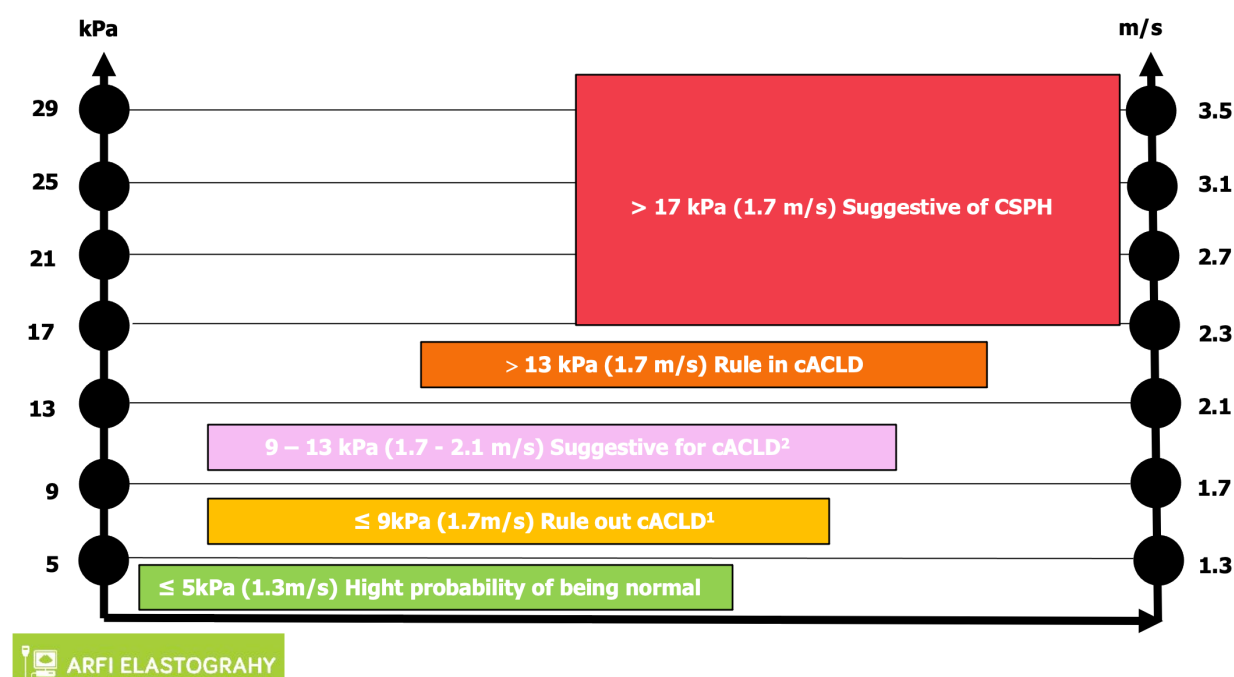


Figure 3 Interpretation of liver stiffness value with acoustic radiation force impulse techniques. Based on some published studies, the consensus panel Baveno VII proposed a vendor-neutral “rule of 4” (5, 9, 13, and 17 kPa) for the acoustic radiation force impulse techniques for viral etiologies and nonalcoholic fatty liver disease, liver stiffness of 5 kPa (1.3 m/sec) or less has a high probability of being normal. Values greater than 13 kPa (2.1 m/sec) are highly suggestive of compensated advanced chronic liver disease (cACLD). There is a probability of clinically significant portal hypertension with liver stiffness values greater than 17 kPa (2.4 m/sec), but additional patient testing may be required. In some patients with nonalcoholic fatty liver disease, the cutoff values for cACLD may be lower and follow-up or additional testing in those with values between 7 kPa and 9 kPa is recommended[10]. For other causes such as alcoholic hepatitis, primary biliary cirrhosis, Wilson’s disease, autoimmune hepatitis, sclerosing cholangitis, and drug-induced liver disease, there is insufficient data to make a conclusion. ¹Liver stiffness less than 9 kPa (1.7 m/sec), in the absence of other known clinical signs, rules out compensated advanced chronic liver disease (cACLD). ²Values between 9 kPa (1.7 m/sec) and 13 kPa (2.1 m/sec) are suggestive of compensated advanced chronic liver disease but may need further testing for confirmation. cACLD: Compensated advanced chronic liver disease; CSPH: Clinically significant portal hypertension.

NONINVASIVE TESTS TO GUIDE CLINICAL DECISION MAKING

Prognostic biomarkers quantify the likelihood of clinical events, disease recurrence, or disease progression. As transitioning from a compensated to decompensated state is the single most important factor affecting survival in patients with cirrhosis, prediction of decompensation is a major prognostic target[20]. An LSM by transient elastography (TE) is the best validated prognostic marker for determining liver-related morbidity and mortality in patients with compensated liver disease. A study of 3028 patients with mixed etiologies found a cumulative incidence of decompensation of 3.7% after 5 years for patients with TE values < 15 kPa, increasing to 19% for patients with baseline TE values ≥ 25 kPa[21]. Other elastography techniques such as pSWE, 2D-SWE, and magnetic resonance elastography also exhibit comparable accuracy as prognostic markers of decompensation and mortality, but variation in published cutoffs and heterogeneity attributable to equipment from different manufacturers limit their generalizability. It is important to switch off assessment of fibrosis to evaluation of clinically important ACLD.

CONCLUSION

The assessment of liver tissue damage has witnessed a transformative shift from invasive to noninvasive methods, providing safer alternatives for patients. The continuous refinement of noninvasive diagnostic methods, particularly the MPUS approach, signifies a crucial stride in managing CLDs. As this technology becomes more accessible and its applications expand, it promises to reshape clinical practices, offering a holistic and efficient means of diagnosing, staging, and monitoring liver diseases on a global scale. Addressing current challenges and embracing emerging technologies will pave the way for more effective management and personalized treatment strategies for patients with liver diseases.

FOOTNOTES

Author contributions: Peltec A and Sporea I provided significant intellectual contributions to this paper, including to the writing and editing of the manuscript, illustrations for the figures, and review of the literature; Peltec A designed the overall concept and outline of the manuscript; Sporea I contributed to the discussion and design of the manuscript.

Conflict-of-interest statement: All authors have nothing to disclose related to this paper.

Open-Access: This article is an open-access article that was selected by an in-house editor and fully peer-reviewed by external reviewers. It is distributed in accordance with the Creative Commons Attribution NonCommercial (CC BY-NC 4.0) license, which permits others to distribute, remix, adapt, build upon this work non-commercially, and license their derivative works on different terms, provided the original work is properly cited and the use is non-commercial. See: <https://creativecommons.org/licenses/by-nc/4.0/>

Country/Territory of origin: Moldova

ORCID number: Angela Peltec 0000-0002-2616-5634; Ioan Sporea 0000-0002-1510-9223.

S-Editor: Qu XL

L-Editor: A

P-Editor: Chen YX

REFERENCES

- Devarbhavi H, Asrani SK, Arab JP, Nartey YA, Pose E, Kamath PS. Global burden of liver disease: 2023 update. *J Hepatol* 2023; **79**: 516-537 [PMID: 36990226 DOI: 10.1016/j.jhep.2023.03.017]
- Mitten EK, Rutherford A. How Hepatologists Use Liver Biopsy in the Evaluation of Liver Disease? *Surg Pathol Clin* 2023; **16**: 443-456 [PMID: 37536881 DOI: 10.1016/j.path.2023.04.001]
- Parola M, Pinzani M. Liver fibrosis: Pathophysiology, pathogenetic targets and clinical issues. *Mol Aspects Med* 2019; **65**: 37-55 [PMID: 30213667 DOI: 10.1016/j.mam.2018.09.002]
- Davison BA, Harrison SA, Cotter G, Alkhouri N, Sanyal A, Edwards C, Colca JR, Iwashita J, Koch GG, Dittrich HC. Suboptimal reliability of liver biopsy evaluation has implications for randomized clinical trials. *J Hepatol* 2020; **73**: 1322-1332 [PMID: 32610115 DOI: 10.1016/j.jhep.2020.06.025]
- Bedossa P, Carrat F. Liver biopsy: the best, not the gold standard. *J Hepatol* 2009; **50**: 1-3 [PMID: 19017551 DOI: 10.1016/j.jhep.2008.10.014]
- Sporea I, Badea R, Martie A, Dumitru E, Ioanîtescu S, Şirli R, Socaciu M, Popescu A, Dănilă M, Voiculescu M. Contrast Enhanced Ultrasound for the evaluation of focal liver lesions in daily practice. A multicentre study. *Med Ultrason* 2012; **14**: 95-100 [PMID: 22675708]
- Sporea I, Lupuşoru R, Şirli R. Ultrasound Based Elastography Techniques for the Evaluation of Nonalcoholic Liver Disease. *IntechOpen* 2022 [DOI: 10.5772/intechopen.102363]
- Sporea I, Gilja OH, Bota S, Şirli R, Popescu A. Liver elastography - an update. *Med Ultrason* 2013; **15**: 304-314 [PMID: 24286095 DOI: 10.11152/nu.2013.2066.154.isp23]
- Dietrich CF, Bamber J, Berzigotti A, Bota S, Cantisani V, Castera L, Cosgrove D, Ferraioli G, Friedrich-Rust M, Gilja OH, Goertz RS, Karlas T, de Knecht R, de Ledinghen V, Piscaglia F, Procopet B, Saftoiu A, Sidhu PS, Sporea I, Thiele M. EFSUMB Guidelines and Recommendations on the Clinical Use of Liver Ultrasound Elastography, Update 2017 (Long Version). *Ultraschall Med* 2017; **38**: e16-e47 [PMID: 28407655 DOI: 10.1055/s-0043-103952]
- Berzigotti A. Advances and challenges in cirrhosis and portal hypertension. *BMC Med* 2017; **15**: 200 [PMID: 29121925 DOI: 10.1186/s12916-017-0966-6]
- Tsochatzis EA, Bosch J, Burroughs AK. Liver cirrhosis. *Lancet* 2014; **383**: 1749-1761 [PMID: 24480518 DOI: 10.1016/S0140-6736(14)60121-5]
- de Franchis R; Baveno VI Faculty. Expanding consensus in portal hypertension: Report of the Baveno VI Consensus Workshop: Stratifying risk and individualizing care for portal hypertension. *J Hepatol* 2015; **63**: 743-752 [PMID: 26047908 DOI: 10.1016/j.jhep.2015.05.022]
- de Franchis R, Bosch J, Garcia-Tsao G, Reiberger T, Ripoll C; Baveno VII Faculty. Baveno VII - Renewing consensus in portal hypertension. *J Hepatol* 2022; **76**: 959-974 [PMID: 35120736 DOI: 10.1016/j.jhep.2021.12.022]
- Barr RG, Wilson SR, Rubens D, Garcia-Tsao G, Ferraioli G. Update to the Society of Radiologists in Ultrasound Liver Elastography Consensus Statement. *Radiology* 2020; **296**: 263-274 [PMID: 32515681 DOI: 10.1148/radiol.2020192437]
- Talwalkar JA, Kurtz DM, Schoenleber SJ, West CP, Montori VM. Ultrasound-based transient elastography for the detection of hepatic fibrosis: systematic review and meta-analysis. *Clin Gastroenterol Hepatol* 2007; **5**: 1214-1220 [PMID: 17916549 DOI: 10.1016/j.cgh.2007.07.020]
- Friedrich-Rust M, Ong MF, Martens S, Sarrazin C, Bojunga J, Zeuzem S, Herrmann E. Performance of transient elastography for the staging of liver fibrosis: a meta-analysis. *Gastroenterology* 2008; **134**: 960-974 [PMID: 18395077 DOI: 10.1053/j.gastro.2008.01.034]
- Tsochatzis EA, Gurusamy KS, Ntaoula S, Cholongitas E, Davidson BR, Burroughs AK. Elastography for the diagnosis of severity of fibrosis in chronic liver disease: a meta-analysis of diagnostic accuracy. *J Hepatol* 2011; **54**: 650-659 [PMID: 21146892 DOI: 10.1016/j.jhep.2010.07.033]
- Bota S, Herkner H, Sporea I, Salzl P, Şirli R, Neghina AM, Peck-Radosavljevic M. Meta-analysis: ARFI elastography versus transient elastography for the evaluation of liver fibrosis. *Liver Int* 2013; **33**: 1138-1147 [PMID: 23859217 DOI: 10.1111/liv.12240]
- D'Amico G, Morabito A, D'Amico M, Pasta L, Malizia G, Rebora P, Valsecchi MG. Clinical states of cirrhosis and competing risks. *J Hepatol* 2018; **68**: 563-576 [PMID: 29111320 DOI: 10.1016/j.jhep.2017.10.020]
- D'Amico G, Garcia-Tsao G, Pagliaro L. Natural history and prognostic indicators of survival in cirrhosis: a systematic review of 118 studies. *J Hepatol* 2006; **44**: 217-231 [PMID: 16298014 DOI: 10.1016/j.jhep.2005.10.013]
- Shearer JE, Jones R, Parker R, Ferguson J, Rowe IA. The Natural History of Advanced Chronic Liver Disease Defined by Transient Elastography. *Clin Gastroenterol Hepatol* 2023; **21**: 694-703.e8 [PMID: 35337981 DOI: 10.1016/j.cgh.2022.03.015]



Published by **Baishideng Publishing Group Inc**
7041 Koll Center Parkway, Suite 160, Pleasanton, CA 94566, USA

Telephone: +1-925-3991568

E-mail: office@baishideng.com

Help Desk: <https://www.f6publishing.com/helpdesk>

<https://www.wjgnet.com>

