

Growth, invasion, metastasis, differentiation, angiogenesis and apoptosis of gastric cancer regulated by expression of PTEN encoding products

Hua-Chuan Zheng, Yi-Ling Li, Jin-Min Sun, Xue-Fei Yang, Xiao-Han Li, Wei-Guo Jiang, Yin-Chang Zhang, Yan Xin

Hua-Chuan Zheng, Jin-Min Sun, Xue-Fei Yang, Yin-Chang Zhang, Yan Xin, Lab. 4, Cancer Institute, The First Affiliated Hospital of China Medical University, Shenyang 110001, Liaoning Province, China

Yi-Ling Li, Department of Digestive Diseases, The First Affiliated Hospital of China Medical University, Shenyang 110001, Liaoning Province, China

Xiao-Han Li, Wei-Guo Jiang, Department of Pathology, The Second Affiliated Hospital of China Medical University, Shenyang 110004, Liaoning Province, China

Correspondence to: Hua-Chuan Zheng, Lab. 4, Cancer Institute, The First Affiliated Hospital of China Medical University, Shenyang 110001, Liaoning Province, China. zheng_huachuan@hotmail.com
Telephone: +86-24-23256666 Ext 6351 **Fax:** +86-24-23253443

Received: 2003-03-05 **Accepted:** 2003-03-29

Abstract

AIM: To investigate expression of PTEN in gastric cancer and to explore its roles in tumorigenesis and progression of gastric cancer.

METHODS: Formalin-fixed and paraffin-embedded tissues of adjacent non-tumor mucosa and primary foci from 113 cases of gastric cancers were studied for the expression of PTEN and Caspase-3 and microvessel density (MVD) by streptavidin-peroxidase (S-P) immunohistochemistry with antibodies against PTEN, Caspase-3, and CD34. The relationship between PTEN and Caspase 3 expression and clinicopathological parameters of tumors was compared.

RESULTS: Primary gastric cancer cells expressed PTEN less frequently than adjacent epithelial cells of primary foci (54.9 % vs 89.4 %; $P=0.000$, $\chi^2=33.474$). PTEN expression was significantly associated with invasive depth ($P=0.003$, $rs=0.274$), metastasis ($P=0.036$, $rs=0.197$), growth pattern ($P=0.008$, $rs=0.282$), Lauren's classification ($P=0.000$, $rs=0.345$), and histological classification ($P=0.005$, $rs=0.262$) of tumors, but not with tumor size ($P=0.639$, $rs=0.045$), Borrmann's classification ($P=0.544$, $rs=0.070$) or TNM staging ($P=0.172$, $rs=0.129$). PTEN expression was negatively correlated with MDV in primary gastric cancer ($P=0.020$, $F=5.558$). Primary gastric cancer cells showed less frequent immunoreactivity to Caspase-3 than adjacent epithelial cells of primary foci (32.7 % vs 50.4 %; $P=0.007$, $\chi^2=7.286$). Caspase-3 expression was dependent of PTEN expression in primary gastric cancer cells ($P=0.000$, $\chi^2=15.266$).

CONCLUSION: Down-regulated expression of PTEN plays an important role in tumorigenesis, progression, growth, differentiation and angiogenesis of gastric cancer. Low expression of PTEN can decrease expression of Caspase-3 to disorder apoptosis of tumor cells, which might explain the molecular mechanisms of PTEN contributions to tumorigenesis and progression of gastric cancer.

Zheng HC, Li YL, Sun JM, Yang XF, Li XH, Jiang WG, Zhang YC, Xin Y. Growth, invasion, metastasis, differentiation, angiogenesis and apoptosis of gastric cancer regulated by expression of PTEN encoding products. *World J Gastroenterol* 2003; 9(8): 1662-1666

<http://www.wjgnet.com/1007-9327/9/1662.asp>

INTRODUCTION

Human suppressor gene, PTEN/MMAC1/TEP1 (phosphatase and tensin homology deleted from chromosome ten/mutated in multiple advanced cancer 1/TGF- β -regulated and epithelial cell enriched phosphatase 1), located on chromosome 10q23.3 encodes a dual specific protein- phospholipid phosphatase that is involved in regulation of a variety of signal transduction pathways^[1]. PTEN inhibits shc's (src-homology collagen) phosphorylation following epidermal growth factor (EGF) stimulation and therefore blocks the activation of the Ras/MAP-kinase (MAPK) pathway^[2]. Another mechanism that involves the protein phosphatase activity of PTEN is dephosphorylation and inactivation of focal adhesion kinase (FAK), thus playing a crucial role of PTEN in the interaction between extracellular matrix and cytoskeleton^[3,4]. Besides its function as the protein phosphatase, PTEN acts as a phospholipid phosphatase with phosphatidylinositol 3,4,5-triphosphate (PIP₃) as a substrate^[5-7]. Recently, many studies have shown that there are several putative mechanisms relating to tumor suppression as follows: inhibiting cell invasion and metastasis by dephosphorylating FAK, inhibiting cell apoptosis and increasing cell growth by dephosphorylating PIP₃, restraining cell differentiation by inhibiting MAPK signal pathway^[5,8,9]. Mutation or abnormal expression of PTEN protein occurs commonly in multiple tumors and significantly correlates with tumorigenesis and progression of different malignancies^[10-20]. It was reportedly suggested that deletion or mutation of PTEN could enhance the expression of vascular epithelial growth factor (VEGF) and matrix metalloproteinases (MMPs), which in turn closely correlated with tumor angiogenesis and metastasis^[10-14]. Jones *et al.*^[15] found that activation of PTEN signal pathway could reduce expression of Caspase-3, resulting in inhibition of cellular apoptosis.

Gastric cancer is one of the commonest malignancies in China, and even in the world. In patients with gastric cancer, the natural disease process consists of carcinogenesis, metastasis and eventual death. However, the molecular aspects of carcinogenesis and progression of gastric cancer remain elusive^[16-18]. In the current study, we evaluated the expression of PTEN in adjacent epithelial cells, primary gastric cancer cells and intended to find if there was any correlation between its expression and clinicopathological features and microvessel density (MVD) of gastric cancer, as well as between PTEN and Caspase-3 expression in primary foci in order to clarify its role in tumorigenesis and progression of gastric cancer.

MATERIALS AND METHODS

Patients

One hundred and thirteen cases of surgically resected specimens of gastric cancer were collected from the Second Affiliated Hospital of China Medical University from Sept, 1997 to Feb, 2001, including 83 men and 30 women. Their age ranged from 26 to 83 years, with the mean age of 57.1 years. Among them, 38 tumors were accompanied by lymph node or organ metastasis. None of the patients had received radiotherapy or chemotherapy before operation.

Preparation of tissue samples

Adjacent mucosa and primary lesions of each case were fixed in 4 % formaldehyde solution, embedded in paraffin, incised into 4 μ m sections and mounted on poly-lysine-coated slides. These sections were stained by hematoxylin-and-eosin method to confirm their histological diagnosis and other microscopic characteristics.

Evaluation of clinicopathological parameters

Clinical staging for each gastric carcinoma was evaluated according to the TNM system. Gross appearance of the tumors was described according to the Borrmann's classification. Histomorphological architecture of the tumor samples was expressed on the basis of Lauren's and Nakamura's classifications. Growth patterns of gastric cancer were classified in the light of Zhang's classification. Tumor diameter, invasive depth and metastasis were determined as well.

Immunohistochemistry

Representative and consecutive sections were studied with streptavidin-peroxidase immunohistochemistry (S-P kit from Zhongshan Biotech., China). Anti-PTEN, anti-CD34 and anti-Caspase-3 antibodies were purchased from Antibody Dignostica (USA), Zhongshan (China), and DAKO (Japan), respectively. All procedures were implemented according to the product recommendation. For negative controls, sections were processed as above but treated with PBS (0.01 mol/L, pH7.4) instead of primary antibodies.

Evaluation of PTEN and Caspase-3 immunostaining

The immunoreactivity to PTEN and Caspase-3 was localized in the cytoplasm. From 5 randomly selected representative fields of each section, two independent observers counted one hundred cells. According to the proportion of positive ones in counted cells, the degree of immunostaining was graded as follows: negative(-), ≤ 5 %; weakly positive (+), 5-25 %; moderately positive (++), 25-50 %; and strongly positive (+++), ≥ 50 %.

Microvessel density counting

Modified Weidner's method was used to calculate MVD by anti-CD34 immunohistochemistry, which was described as follows. Microvessels in sclerotic areas within tumor, where microvessels were sparse and immediately adjacent areas of unaffected gastric tissue were considered as hot points in vessel counts. Observers selected five such areas and counted individual microvessels in a 400 \times field (i.e. 40 \times objective lens and 10 \times ocular lens, 0.1885 mm² per field). Any brown staining endothelial cell or endothelial cell cluster that was clearly separated from adjacent microvessel, tumor cells, and other connective tissue elements was considered as a single, countable microvessel. They must agree on what constituted a single microvessel.

Statistical analysis

Statistical evaluation was performed using chi-square test to

compare the rates between different groups, using Spearman test to analyze the rank data, and using the one-way ANOVA to differentiate the means of different groups. $P < 0.05$ was considered as statistically significant. SPSS 10.0 software was employed to analyze all data.

RESULTS

PTEN expression in adjacent epithelial cells and cancer cells of primary gastric cancer

Figures 1-3 show that PTEN was positively expressed in the nuclei of adjacent epithelial cells, lymphocytes and cancer cells of primary foci of gastric cancer. In this study, epithelial cells and cancer cells were immunostained for PTEN protein in 89.4 % and 54.9 % of the tumors, respectively. There was a significant difference between them ($P < 0.05$) (Table 1).

Table 1 PTEN expression in adjacent epithelial cells and cancer cells of primary gastric cancer

Groups	n	PTEN expression				PR(%)
		-	+	++	+++	
Adjacent epithelial cells	113	12	10	23	68	89.4
Primary cancer cells	113	51	13	11	38	54.9 ^a

Notes: PR: positive rate, ^a $P=0.000$ ($\chi^2=33.474$, Pearson' R=0.385).

Table 2 Relationship between expression of PTEN in primary foci and clinicopathological features of gastric cancer

Clinicopathological features	n	PTEN expression				rs	P value
		-	+	++	+++		
Tumor size						0.045	0.639
<4 cm	47	20	6	4	17	57.4	
≥ 4 cm	66	31	7	7	21	53.0	
Borrmann's Classification						0.070	0.544
I/II	28	12	3	3	10	57.1	
III/IV	59	30	5	6	18	49.2	
Invasive depth						0.274	0.003
Above submucosa	26	7	4	2	13	73.1	
Muscularis propria	34	14	2	4	14	58.8	
Below subserosa	53	30	7	5	11	56.6	
Metastasis						0.197	0.036
Negative	76	28	10	8	29	62.7	
Positive	38	23	3	3	9	39.5	
TNM staging						0.129	0.172
O	18	7	4	1	6	61.1	
I	28	11	2	2	13	60.7	
II	40	19	3	5	13	52.5	
III	17	7	3	3	4	58.8	
IV	10	7	1	0	2	30.0	
Growth pattern						0.282	0.008
Mass	23	8	2	2	11	65.2	
Nest	30	12	3	4	11	60.0	
Diffuse	34	22	3	3	6	35.3	
Lauren's Classification						0.345	0.000
Intestinal type	36	8	2	6	20	77.8	
Diffuse type	57	32	10	3	12	43.9	
Mixed type	20	11	1	2	6	45.0	
Histological classification						0.262	0.005
Differentiated	53	18	3	8	24	66.0	
Undifferentiated	60	33	10	3	14	45.0	

Notes: PR: positive rate.

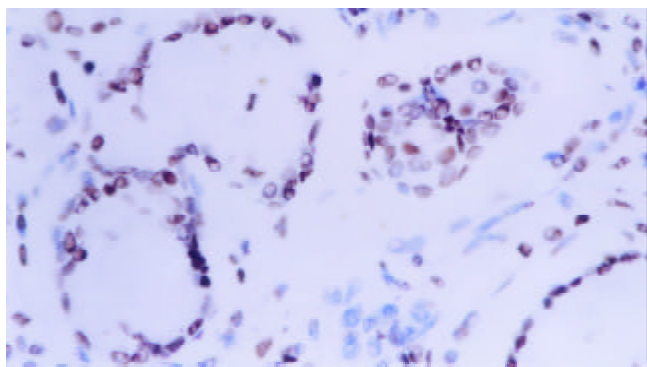


Figure 1 PTEN was immunostained in cell nuclear. It was strongly expressed in gastric epithelial cells (+++) (S-P, $\times 400$).

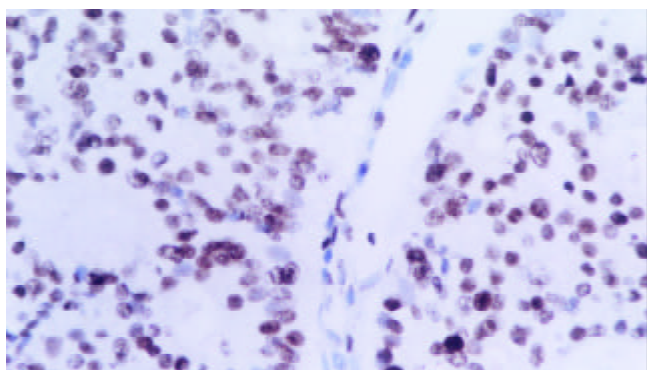


Figure 2 PTEN was strongly expressed in gastric well-differentiated adenocarcinoma (+++) (S-P, $\times 400$).

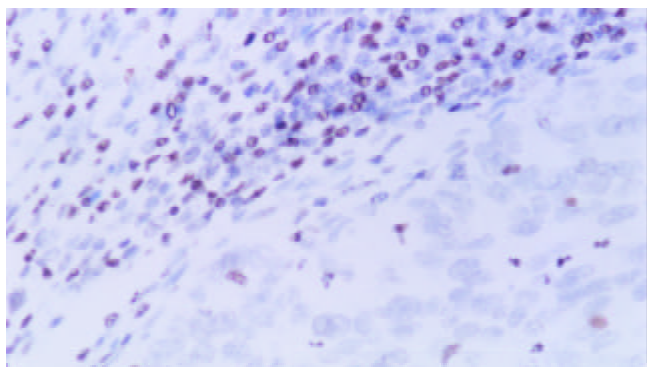


Figure 3 PTEN was negatively expressed in poorly-differentiated adenocarcinoma cells (-) and tumor infiltrated lymphocytes showed strong expression of PTEN (+++) (S-P, $\times 400$).

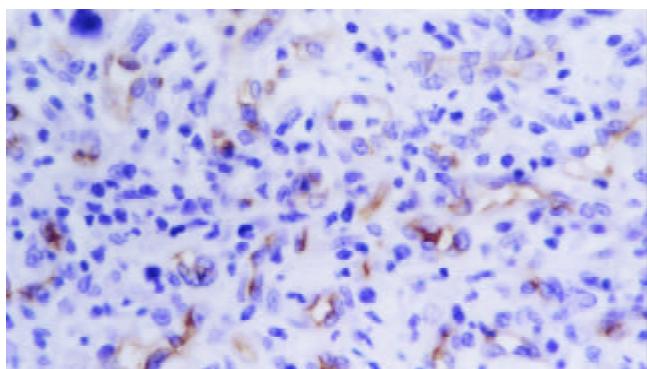


Figure 4 CD34 was located in cytoplasm and cellular membrane of vascular endothelial cells (S-P, $\times 400$).

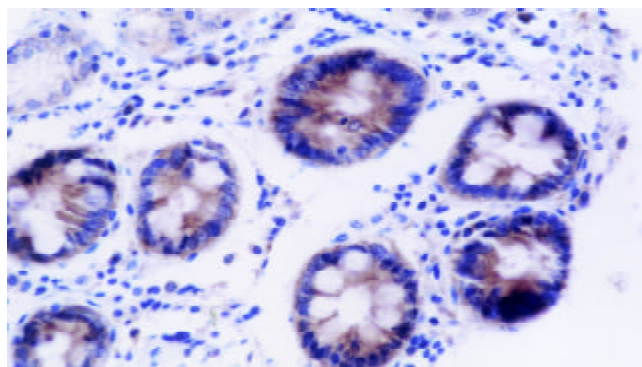


Figure 5 Caspase-3 was distributed in cytoplasm. Caspase-3 was strongly expressed in gastric epithelial cells (+++) (S-P, $\times 400$).

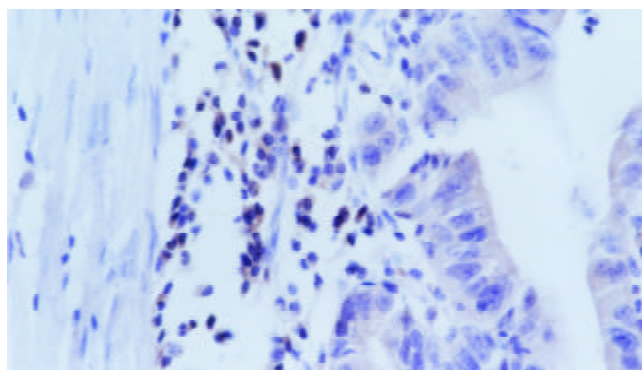


Figure 6 Caspase-3 was positively expressed in well-differentiated adenocarcinoma of stomach (++) and strongly in tumor infiltrated lymphocytes (+++) (S-P, $\times 400$).

Correlation between PTEN expression in primary cancer cells and clinicopathological features of gastric cancer

PTEN expression in primary cancer cells was significantly associated with invasive depth, metastasis, growth pattern, Lauren's Classification, and histological classification of gastric cancer ($P < 0.05$). There was no close correlation between PTEN expression and tumor size, Borrmann's Classification or TNM staging ($P > 0.05$). One ANOVA analysis showed PTEN expression was negatively correlated with MDV in primary gastric cancer ($P < 0.05$) (Tables 2-3, Figure 4).

Table 3 Relationship between expression of PTEN expression and MVD in primary gastric cancer

PTEN expression	<i>n</i>	MVD (mean \pm standard error)	<i>F</i> value	<i>P</i> value
-	51	52.53 \pm 25.47	5.558	0.020
+~+++	62	41.84 \pm 22.69		
Total	113	46.67 \pm 24.47		

Table 4 Relationship between expression of PTEN and Caspase-3 in primary gastric cancer cells

PTEN expression	<i>n</i>	Caspase-3 expression		
		-	+~+++	PR(%)
-	51	44	7	13.7 ^a
+~+++	62	32	30	48.4
Total	113	76	37	32.7

Notes: PR: positive rate. ^a $P = 0.000$ ($\chi^2 = 15.266$, Pearson's $R = 0.368$).

Relationship between PTEN and Caspase-3 expression in primary gastric cancer cells

Figures 5-6 showed positive immunostaining of Caspase-3 in

the cytoplasm of adjacent epithelial cells, infiltrating lymphocytes, and cancer cells of primary gastric cancer. Cancer cells showed less frequent immunoreactivity to Caspase-3 than adjacent epithelial cells (32.7 % vs 50.4 %; $P < 0.05$). Moreover, Caspase-3 expression was dependent of PTEN expression in primary gastric cancer cells ($P < 0.05$) (Table 4).

DISCUSSION

Deletion or down-regulation of tumor suppressing genes plays an important role in the multiple steps of tumorigenesis and progression of gastric cancer. PTEN, a tumor-suppressing gene, makes a great contribution to cellular differentiation, reproduction and apoptosis, as well as cellular adhesion and mobility^[8,9]. Some studies showed down-regulation of PTEN protein expression was due to genetic changes such as mutation, loss of heterozygosity, hypermethylation in gastric cancer, prostate cancer and breast cancer^[19-21]. Our results showed that expression of PTEN decreased in primary gastric cancer cells, compared with that in adjacent epithelial cells. This revealed that genetic changes of PTEN gene could play an important role in malignant transition of gastric epithelial cells.

Low expression of PTEN gene product was involved in clinicopathological stage and metastasis of various malignancies. We found that the positive rate of PTEN was lower in gastric cancer with metastasis than that without metastasis. Additionally, the positive rate of PTEN expression tended to decrease with increase of invasive depth. These results were similar to other kinds of tumors^[22-29]. Mass-type gastric cancer showed more expression of PTEN than nest-type one, the latter more than diffuse-type one, demonstrating that PTEN expression was implicated in the growth pattern of gastric cancer. These results suggest that deletion or reduced expression of PTEN protein probably facilitates the invasive and metastatic ability of gastric cancer cells. Several studies revealed that PTEN could enhance mobility and metastasis of tumor cells by regulating MMPs and VEGF^[10-14]. There was another report that PTEN dephosphorylated FAK so as to be involved in cellular adhesion^[30]. Deletion or reduced expression of PTEN could result in decreased cellular adhesion, increased synthesis of MMPs and VEGF, which subsequently contributed to invasion and angiogenesis of tumor tissues. These biological effects possibly underlay the prelude of invasion and metastasis of tumor. Our results revealed that reduced expression of PTEN was implicated in progression of gastric cancer probably by decreased cellular adhesion, increased cellular mobility and angiogenesis, and could act as an objective and effective marker to reflect the pathobiological behaviors of gastric cancer.

In addition, undifferentiated carcinomas showed the lower expression of PTEN than differentiated ones, suggesting that down-regulated expression of PTEN was closely associated with differentiation of gastric cancer. Diffuse-type gastric cancer showed fewer expression of PTEN than intestinal-type one. It supported that there were different tumorigenic pathways between diffuse- and intestinal-type gastric cancer. Diffuse-type gastric cancer, the main part of which was undifferentiated, showed diffusely invasive growth pattern. It was possible that down-regulation of PTEN expression could influence the function of cellular skeleton, mobility and adhesion of cancer cells.

Angiogenesis was necessary for tumor growth, invasion and metastasis, and tumor-host interaction induced several sorts of tumor angiogenic factors such as VEGF and MMPs to stimulate the intratumoral and peritumoral neovascularization^[31,32]. In this study, we found that mean MVD was negatively related to PTEN expression in primary gastric cancer. Huang *et al.*^[12] found that inhibition of endogenous endothelial PTEN by adenovirus-mediated over-expression of a dominant negative

PTEN mutant in cultured endothelial cells potentially enhanced a variety of VEGF-mediated cellular responses by PIP₃-kinase signaling, including cell survival, mitogenesis, and migration. In contrast, these effects of VEGF were significantly inhibited by over-expression of wild-type PTEN. Moreover, overexpression of wild-type PTEN modulated endothelial tube formation *in vitro* and vascular sprouting in an *ex vivo* model of angiogenesis. On the other hand, decreased and loss of expression of wild-type PTEN would facilitate MMPs expression which played an important role in angiogenic processes, including proliferation of endothelial cells, breakdown of the extracellular matrix and endothelial cell migration^[33]. These *in vivo* and *in vitro* observations suggested that down-regulated expression of PTEN in gastric cancer increased angiogenesis by up-regulating VEGF and MMPs.

Some investigators found that PTEN could promote cell apoptosis, which in turn inhibited tumor growth^[34]. Additionally Caspase-3 played an important role in apoptosis as an effector. Krajewska *et al.*^[35] delineated for the first time some of the *in vivo* patterns of Caspase-3 expression in human tissues. Their observation that Caspase-3 was detectable in almost all types of cell implied its role in the regulation of cell life and death in a variety of types of cells as a proteinase. Our finding showed that Caspase-3 was less frequently expressed in gastric cancer cells than in adjacent epithelial cells. In addition, our study showed that expression of PTEN was positively correlated with expression of Caspase-3 in primary gastric cancer cells. Schwartzbauer *et al.*^[36] found increased PTEN expression by recombinant adenovirus in cultured neonatal rat primary cardiomyocytes caused cardiomyocyte apoptosis as evidenced by increased caspase-3 activity and cleaved poly (A) DP-ribose polymerase. Furthermore, several studies suggested PTEN could enhance Fas/FasL-mediated or cytochrome-c-mediated apoptosis, whose apoptotic pathway evoked Caspase-3^[34,37]. Consequently, we could infer that low expression of PTEN could decrease expression of Caspase-3 to make tumor cells apoptosis dysfunction, which underlay the theoretic basis of contribution of PTEN to tumorigenesis and progression of gastric cancer.

In conclusion, expression of PTEN and Caspase-3 is down-regulated in tumorigenesis of gastric cancer. Decreased expression of PTEN is implicated in progression of gastric cancer by decreased cell adhesion and increased angiogenesis and cell mobility. Moreover, low expression of PTEN can reduce expression of Caspase-3 to make tumor cells apoptosis disorder, which forms molecular mechanisms of PTEN contribution to tumorigenesis and progression of gastric cancer. However, a further study is necessary to directly clarify regulatory roles of PTEN and MMP-7 expression in angiogenesis of gastric cancer.

REFERENCES

- 1 **Steck PA**, Pershouse MA, Jasser SA, Yung WK, Lin H, Ligon AH, Langford LA, Baumgard ML, Hattier T, Davis T, Frye C, Hu R, Swedlund B, Teng DH, Tavtigian SV. Identification of a candidate tumour suppressor gene, MMAC1, at chromosome 10q23.3 that is mutated in multiple advanced cancers. *Nat Genet* 1997; **15**: 356-362
- 2 **Gu J**, Tamura M, Yamada KM. Tumor suppressor PTEN inhibits integrin- and growth factor-mediated mitogen-activated protein (MAP) kinase signaling pathways. *J Cell Biol* 1998; **143**: 1375-1383
- 3 **Tamura M**, Gu J, Takino T, Yamada KM. Tumor suppressor PTEN inhibition of cell invasion, migration, and growth: differential involvement of focal adhesion kinase and p130Cas. *Cancer Res* 1999; **59**: 442-449
- 4 **Tamura M**, Gu J, Tran H, Yamada KM. PTEN gene and integrin signaling in cancer. *J Natl Cancer Inst* 1999; **91**: 1820-1828
- 5 **Maehama T**, Dixon JE. The tumor suppressor, PTEN/MMAC1,

- dephosphorylates the lipid second messenger, phosphatidylinositol 3, 4, 5-trisphosphate. *J Biol Chem* 1998; **273**: 13375-13378
- 6 **Hopkin K**. A surprising function for the PTEN tumor suppressor. *Science* 1998; **282**: 1027-1030
- 7 **Cantley LC**, Neel BG. New insight into tumor suppression: PTEN suppresses tumor formation by restraining the phosphoinositide 3-kinase/AKT pathway. *Proc Natl Acad Sci USA* 1999; **96**: 4240-4245
- 8 **Besson A**, Robbins SM, Yong VW. PTEN/MMAC1/TEP1 in signal transduction and tumorigenesis. *Eur J Biochem* 1999; **263**: 605-611
- 9 **Waite KA**, Eng C. Protean PTEN: form and function. *Am J Hum Genet* 2002; **70**: 829-844
- 10 **Koul D**, Parthasarathy R, Shen R, Davies MA, Jasser SA, Chintala SK, Rao JS, Sun Y, Benveniste EN, Liu TJ, Yung WK. Suppression of matrix metalloproteinase-2 gene expression and invasion in human glioma cells by MMAC/PTEN. *Oncogene* 2001; **20**: 6669-6678
- 11 **Tsugawa K**, Jones MK, Sugimachi K, Sarfeh II, Tarnawski AS. Biological role of phosphatase pten in cancer and tissue injury healing. *Front Biosci* 2002; **7**: E245-251
- 12 **Huang J**, Kontos CD. PTEN modulates vascular endothelial growth factor-mediated signaling and angiogenic effects. *J Biol Chem* 2002; **277**: 10760-10766
- 13 **Byzova TV**, Goldman CK, Pampori N, Thomas KA, Bett A, Shattil SJ, Plow EF. A mechanism for modulation of cellular responses to VEGF: activation of the integrins. *Mol Cell* 2000; **6**: 851-860
- 14 **Jiang BH**, Zheng JZ, Aoki M, Vogt PK. Phosphatidylinositol 3-kinase signaling mediates angiogenesis and expression of vascular endothelial growth factor in endothelial cells. *Proc Natl Acad Sci USA* 2000; **97**: 1749-1753
- 15 **Jones RG**, Elford AR, Parsons MJ, Wu L, Krawczyk CM, Yeh WC, Hakem R, Rottapel R, Woodgett JR, Ohashi PS. CD28-dependent activation of protein kinase B/Akt blocks Fas-mediated apoptosis by preventing death-inducing signaling complex assembly. *J Exp Med* 2002; **196**: 335-348
- 16 **Parkin DM**. Global cancer statistics in the year 2000. *Lancet Oncol* 2001; **2**: 533-543
- 17 **Chen XY**, van Der Hulst RW, Shi Y, Xiao SD, Tytgat GN, Ten Kate FJ. Comparison of precancerous conditions: atrophy and intestinal metaplasia in *Helicobacter pylori* gastritis among Chinese and dutch patients. *J Clin Pathol* 2001; **54**: 367-370
- 18 **Xin Y**, Li XL, Wang YP, Zhang SM, Zheng HC, Wu DY, Zhang YC. Relationship between phenotypes of cell-function differentiation and pathobiological behavior of gastric carcinomas. *World J Gastroenterol* 2001; **7**: 53-59
- 19 **Kondo K**, Yao M, Kobayashi K, Ota S, Yoshida M, Kaneko S, Baba M, Sakai N, Kishida T, Kawakami S, Uemura H, Nagashima Y, Nakatani Y, Hosaka M. PTEN/MMAC1/TEP1 mutations in human primary renal-cell carcinomas and renal carcinoma cell lines. *Int J Cancer* 2001; **91**: 219-224
- 20 **Wang DS**, Rieger-Christ K, Latini JM, Moizadeh A, Stoffel J, Pezza JA, Saini K, Libertino JA, Summerhayes IC. Molecular analysis of PTEN and MXI1 in primary bladder carcinoma. *Int J Cancer* 2000; **88**: 620-625
- 21 **Salvesen HB**, MacDonald N, Ryan A, Jacobs IJ, Lynch ED, Akslen LA, Das S. PTEN methylation is associated with advanced stage and microsatellite instability in endometrial carcinoma. *Int J Cancer* 2001; **91**: 22-26
- 22 **Lee JJ**, Soria JC, Hassan KA, El-Naggar AK, Tang X, Liu DD, Hong WK, Mao L. Loss of PTEN expression as a prognostic marker for tongue cancer. *Arch Otolaryngol Head Neck Surg* 2001; **127**: 1441-1445
- 23 **Verma RS**, Manikal M, Conte RA, Godec CJ. Chromosomal basis of adenocarcinoma of the prostate. *Cancer Invest* 1999; **17**: 441-447
- 24 **McMenamin ME**, Soung P, Perera S, Kaplan I, Loda M, Sellers WR. Loss of PTEN expression in paraffin-embedded primary prostate cancer correlates with high gleason score and advanced stage. *Cancer Res* 1999; **59**: 4291-4296
- 25 **Rustia A**, Wierzicki V, Marrocco L, Tossini A, Zamponi C, Lista F. Is exon 5 of the PTEN/MMAC1 gene a prognostic marker in anaplastic glioma? *Neurosurg Rev* 2001; **24**: 97-102
- 26 **Nozaki M**, Tada M, Kobayashi H, Zhang CL, Sawamura Y, Abe H, Ishii N, Van Meir EG. Roles of the functional loss of p53 and other genes in astrocytoma tumorigenesis and progression. *Neurooncol* 1999; **1**: 124-137
- 27 **Minaguchi T**, Yoshikawa H, Oda K, Ishino T, Yasugi T, Onda T, Nakagawa S, Matsumoto K, Kawana K, Taketani Y. PTEN mutation located only outside exons 5, 6, and 7 is an independent predictor of favorable survival in endometrial carcinomas. *Clin Cancer Res* 2001; **7**: 2636-2642
- 28 **Tada K**, Shiraishi S, Kamiryo T, Nakamura H, Hirano H, Kuratsu J, Kochi M, Saya H, Ushio Y. Analysis of loss of heterozygosity on chromosome 10 in patients with malignant astrocytic tumors: correlation with patient age and survival. *J Neurosurg* 2001; **95**: 651-659
- 29 **Mills GB**, Lu Y, Kohn EC. Linking molecular therapeutics to molecular diagnostics: inhibition of the FRAP/RAFT/TOR component of the PI3K pathway preferentially blocks PTEN mutant cells *in vitro* and *in vivo*. *Proc Natl Acad Sci USA* 2001; **98**: 10031-10033
- 30 **Maehama T**, Taylor GS, Dixon JE. PTEN and myotubularin: novel phosphoinositide phosphatases. *Annu Rev Biochem* 2001; **70**: 247-279
- 31 **Kim TS**, Kim YB. Correlation between expression of matrix metalloproteinase-2 (MMP-2), and matrix metalloproteinase-9 (MMP-9) and angiogenesis in colorectal adenocarcinoma. *J Korean Med Sci* 1999; **14**: 263-270
- 32 **Giatromanolaki A**, Koukourakis MI, Stathopoulos GP, Kapsoritakis A, Paspatis G, Kakolyris S, Sivridis E, Georgoulis V, Harris AL, Gatter KC. Angiogenic interactions of vascular endothelial growth factor of thymidine phosphorylase, and of p53 protein expression in locally advanced gastric cancer. *Oncol Res* 2000; **12**: 33-41
- 33 **Cox G**, O'Byrne KJ. Matrix metalloproteinases and cancer. *Anti-cancer Res* 2001; **21**: 4207-4219
- 34 **Carson JP**, Kulik G, Weber MJ. Antiapoptotic signaling in LNCaP prostate cancer cells: a survival signaling pathway independent of phosphatidylinositol 3'-kinase and Akt/protein kinase B. *Cancer Res* 1999; **59**: 1449-1453
- 35 **Krajewska M**, Wang HG, Krajewski S, Zapata JM, Shabalik A, Gascoyne R, Reed JC. Immunohistochemical analysis of *in vivo* patterns of expression of CPP32 (Caspase-3), a cell death protease. *Cancer Res* 1997; **57**: 1605-1613
- 36 **Schwartzbauer G**, Robbins J. The tumor suppressor gene PTEN can regulate cardiac hypertrophy and survival. *J Biol Chem* 2001; **276**: 35786-357893
- 37 **Wick W**, Furnari FB, Naumann U, Caveness WK, Weller M. PTEN gene transfer in human malignant glioma: sensitization to irradiation and CD95L-induced apoptosis. *Oncogene* 1999; **18**: 3936-3943

Edited by Xu XQ