

Dear Professor Bloomfield,

Thank you so much for giving us this great valuable chance to further enhance our manuscript entitled “Imaging characteristics of A Rare Case of Monostotic Fibrous Dysplasia at Sacrum” (Manuscript NO.:59177). Following the specific suggestions and review comments in email, we have carefully revised our manuscript accordingly. Following is a detailed point-by-point response to address the review comments.

Response to Editor’s Comments

We are pleased to inform you that, after preview by the Editorial Office and peer review, as well as CrossCheck and Google plagiarism detection, we believe that the academic quality, language quality, and ethics of your manuscript (Manuscript NO.: 59177, Case Report) basically meet the publishing requirements of the World Journal of Clinical Cases. As such, we have made the preliminary decision that it is acceptable for publication after your appropriate revision. Upon our receipt of your revised manuscript, we will send it for re-review. We will then make a final decision on whether to accept the manuscript or not, based on the reviewers’ comments, the quality of the revised manuscript, and the relevant documents. Please follow the steps outlined below to revise your manuscript to meet the requirements for final acceptance and publication.

Re to ED: We appreciate very much your warm help in reviewing and revising our paper and giving us valuable comments for us to improve our work. Following your specific comments, a point-to point response has been carefully provided as follows.

Response to Reviewers’ Comments

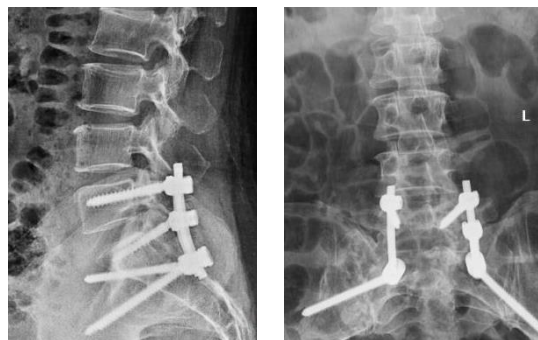
Reviewer #1:

Authors reported a rare case of a case of spinal monostotic fibrous dysplasia (MFD) in the sacral spine. In the manuscript, authors correctly described computed tomography (CT) and magnetic resonance imaging (MRI) findings and a pathologic confirmation was obtained. Also, an overview of differential diagnoses was performed. STATUS: ACCETTABLE FOR PUBBLICATION PENDING MINOR REVISIONS General considerations: This is a CASE REPORT article. The work is interesting, the paper is very well-written and there are only a few articles in literature about this topic. However, the only objection I make is the following: -Why does the title of the article refer only to the single case? -Wouldn't it be better to talk about literature review too? Abstract: the abstract appropriately summarize the manuscript without discrepancies between the abstract and the remainder of the manuscript. Keywords: adequate. Reference: adequate. Paper The paper is very well-written. Figures: good. Do you have plain X-rays of the patient? If yes, please enter them.

Re to R1: Thanks so much for your greatly helpful comments and suggestions.

(1) FD is rare in the spinal extremely rare at sacrum.[1] Kinnunen[2] reviewed the literatures, collected 136 cases of fibrous dysplasia, including all parts of the body, in which the incidence of vertebral body accounted for 24/136 (18%). The percentage of vertebral body FD in cervical was 17%, thoracic was 29%, lumbar was 29%, and sacral was only 8% (2/24). In the spinal, it is either in the monostotic or polyostotic form, but rare in the monostotic FD.[3] Until now, this is the seventh case reported in sacrum. They are all monostotic FD. Therefore in our article we only talk about the imaging characteristics of a single case in sacrum. We have increased these details in the text.

(2) Before the operation, the patient had no X-ray examination. Imaging studies obtained computed tomographic (CT), and magnetic resonance imaging (MRI). After three days of the operation, the patient had a X-ray examination. I have increased two figures in the text.



Science editor:

1 Scientific quality: The manuscript describes a case report of the imaging characteristics of a rare case of monostotic fibrous dysplasia of the sacrum. The topic is within the scope of the WJCC. (1) Classification: Grade C; (2) Summary of the Peer-Review Report: The work is interesting and the paper is very well-written. Authors correctly described computed tomography and magnetic resonance imaging findings and a pathologic confirmation was obtained. the abstract appropriately summarize the manuscript without discrepancies between the abstract and the remainder of the manuscript. The only objection I make is the following: the title of the article refers only to the single case, if you have plain X-rays of the patient, please enter them; and (3) Format: There is 1 table and 4 figures. A total of 25 references are cited, including 1 reference published in the last 3 years. There are no self-citations. 2 Language evaluation: Classification: Grade A. A language editing certificate issued by AJE was provided. 3 Academic norms and rules: The authors provided the Signed Informed Consent. The authors need to provide the signed Conflict-of-Interest Disclosure Form and Copyright License Agreement and the CARE Checklist – 2016. No academic misconduct was found in the CrossCheck detection and Bing search. 4

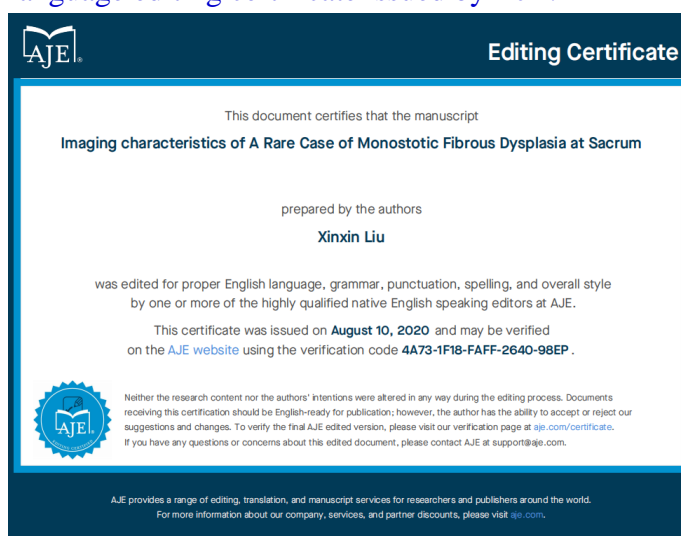
Supplementary comments: This is an unsolicited manuscript. The topic has not previously been published in the WJCC. The corresponding author has not published article in the BPG. 5 Issues raised: (1) I found no “Author contribution” section. Please provide the author contributions; (2) I found the authors did not provide the original figures. Please provide the original figure documents. Please prepare and arrange the figures using PowerPoint to ensure that all graphs or arrows or text portions can be reprocessed by the editor; (3) I found the authors did not add the PMID and DOI in the reference list. Please provide the PubMed numbers and DOI citation numbers to the reference list and list all authors of the references. Please revise throughout; (4) I found the “Case Presentation” did not meet our requirements. Please re-write the “Case Presentation” section, and add “FINAL DIAGNOSIS”, “TREATMENT”, and “OUTCOME AND FOLLOW-UP” section to the main text, according to the Guidelines and Requirements for Manuscript Revision; (5) the author should number the references in Arabic numerals according to the citation order in the text. The reference numbers will be superscripted in square brackets at the end of the sentence with the citation content or after the cited author’s name, with no spaces. 6 Re-Review: Required. 7 Recommendation: Conditionally accepted.

Re to Science editor: We are so appreciated for your helpful comments and suggestions.

(1) It is extremely rare FD in sacrum. In spine it is either monostotic or polyostotic, but rare in monostotic form. This is the seventh case reported in sacrum. Including our case, there are only seven cases of FD in sacrum. They are all single case.

(2) Before the operation, the patient didn’t take X-ray examination. She had computed tomographic (CT), and magnetic resonance imaging (MRI). But after three days of the operation, the patient had a X-ray examination. I have increased two figures in the text.

(3) This is the language editing certificate issued by AJE.



(4) We have provided the signed Conflict-of-Interest Disclosure Form and Copyright License Agreement and the CARE Checklist – 2016

(5) We have increased the author contributions in the text, and provided the original figure documents using PowerPoint.

(6) We had added the PMID and DOI in the reference list and list all authors of the references.

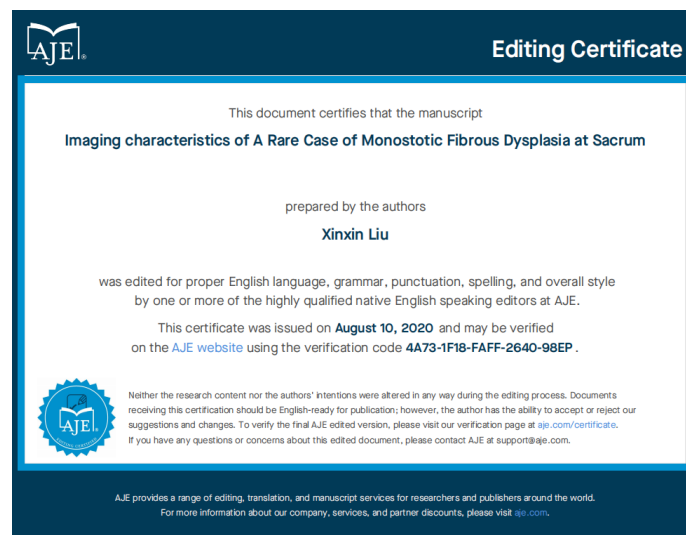(7) We have re-written the “Case Presentation” section, and added “FINAL DIAGNOSIS”, “TREATMENT”, and “OUTCOME AND FOLLOW-UP” section to the main text, according to the Guidelines and Requirements for Manuscript Revision.

(8) We have numbered the references in Arabic numerals according to the citation order in the text. The reference numbers have been superscripted in square brackets at the end of the sentence with the citation content or after the cited author’s name, with no spaces.

Editorial office director:

I have checked the comments written by the science editor. The authors need to provide the right language certificate, not the email.

Re to Editorial office director: This is the language editing certificate issued by AJE.

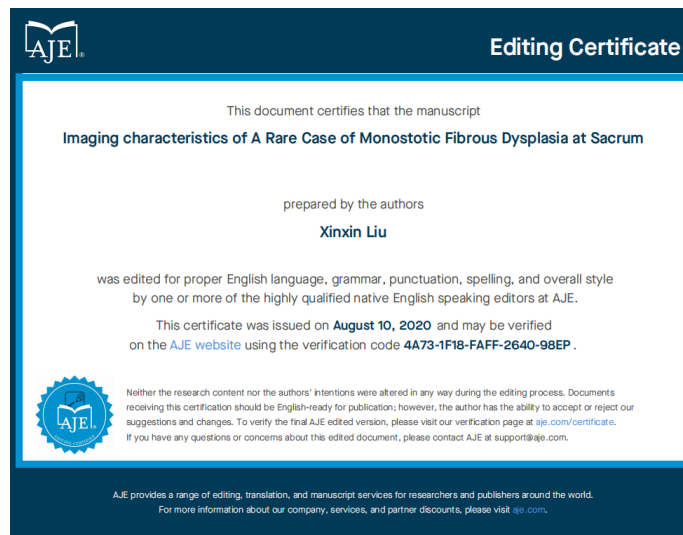


Company editor-in-chief:

I have reviewed the Peer-Review Report, the full text of the manuscript, and the relevant ethics documents, all of which have met the basic publishing requirements of the World Journal of Clinical Cases, and the manuscript is conditionally accepted. I have sent the manuscript to the author(s) for its revision according to the Peer-Review

Report, Editorial Office's comments and the Criteria for Manuscript Revision by Authors. However, the quality of the English language of the manuscript does not meet the requirements of the journal. Before final acceptance, the author(s) must provide the English Language Certificate issued by a professional English language editing company.

Re to Company editor-in-chief: We have the language editing certificate issued by AJE.



- [1] Ropper AE, Cahill KS, Hanna JW, McCarthy EF, Gokaslan ZL, Chi JH. Primary vertebral tumors: a review of epidemiologic, histological, and imaging findings, part I. *Neurosurgery*. 2011;69:1171-80. PMID:21725252 DOI:10.1227/NEU.0b013e31822b8107.
- [2] Ehara S, Kattapuram SV, Rosenberg AE. Fibrous dysplasia of the spine. *Spine*. 1992; 17: 977-9. PMID: 1523499 DOI: 10.1097/00007632-199208000-00020.
- [3] Anna-Reetta Kinnunen, Reijo Sironen, Petri Sipola. Magnetic resonance imaging characteristics in patients with histopathologically proven fibrous dysplasia-a systematic review. *Skeletal Radiol*. 2020;49:837-845. PMID:32040603 DOI: 10.1007/s00256-020-03388-x.