

Endotipsitis: A case report with a literature review on an emerging prosthetic related infection

Annalan MD Navaratnam, Matthew Grant, David B Banach

Annalan MD Navaratnam, Department of Infectious Disease Epidemiology, Imperial College London, W2 1PG London, United Kingdom

Matthew Grant, David B Banach, Department of Infectious Diseases, Yale School of Medicine, New Haven, CT 06510, United States

Author contributions: Navaratnam AMD and Grant M conceived the idea and drafted the manuscript; Navaratnam AMD carried out the literature review and data collection; Navaratnam AMD, Grant M and Banach DB analyzed the data; all authors revised, read and approved the final manuscript.

Conflict-of-interest: The authors declare that they have no conflict of interests.

Data sharing: No additional data are available.

Open-Access: This article is an open-access article which was selected by an in-house editor and fully peer-reviewed by external reviewers. It is distributed in accordance with the Creative Commons Attribution Non Commercial (CC BY-NC 4.0) license, which permits others to distribute, remix, adapt, build upon this work non-commercially, and license their derivative works on different terms, provided the original work is properly cited and the use is non-commercial. See: <http://creativecommons.org/licenses/by-nc/4.0/>

Correspondence to: Dr. Annalan MD Navaratnam, Department of Infectious Disease Epidemiology, Imperial College London, St Mary's Campus, Norfolk Place, W2 1PG London, United Kingdom. amnavaratnam@gmail.com

Telephone: +44-20-759443287

Received: August 1, 2014

Peer-review started: August 2, 2014

First decision: November 14, 2014

Revised: December 15, 2014

Accepted: January 30, 2015

Article in press: February 2, 2015

Published online: April 8, 2015

out, reviewing all papers with specific words in the title or abstract, and excluding appropriately. Of 283 papers that were reviewed, 22 papers reporting 53 cases in total were included in the analyses.

RESULTS: No predominant etiology for endotipsitis was identified, but gram-positive organisms were more common among early-onset infections ($P < 0.01$). A higher mortality rate was associated with *Staphylococcus aureus* and *Candida* spp infections ($P < 0.01$). There was no trend in choice of antibiotic based on the microorganisms isolated and treatment varied from the guidelines of other vegetative prosthetic infections. In endotipsitis "high risk" organisms have been identified, emphasizing the importance of ensuring optimal antimicrobial therapy and adjunctive management strategies.

CONCLUSION: Higher mortality rate was associated with *Staphylococcus aureus* and *Candida* spp infections. A prospective multicenter trial is needed before specific treatment can be recommended.

Key words: Transjugular intrahepatic portosystemic shunts; Transjugular intrahepatic portosystemic shunt infection; Persistent bacteremia; Tipsitis; Antimicrobial therapy

© The Author(s) 2015. Published by Baishideng Publishing Group Inc. All rights reserved.

Core tip: We present a case of a rare disease entity called endotipsitis, vegetative infection of a transjugular intrahepatic portosystemic shunt (TIPS). This case has the longest latency, from insertion to infection, reported in the literature. The literature review supplementing this case report demonstrates an association between onset of infection from TIPS insertion and the etiological agent causing the disease. Furthermore, we demonstrate significantly poorer outcomes in specific infections.

Abstract

AIM: To investigate the etiology and management of a poorly understood complication of transjugular intrahepatic portosystemic shunt; "endotipsitis".

METHODS: A MEDLINE database search was carried

Navaratnam AMD, Grant M, Banach DB. Endotipsitis: A case report with a literature review on an emerging prosthetic related infection. *World J Hepatol* 2015; 7(4): 710-716 Available from: URL: <http://www.wjgnet.com/1948-5182/full/v7/i4/710.htm> DOI: <http://dx.doi.org/10.4254/wjh.v7.i4.710>

INTRODUCTION

Transjugular intrahepatic portosystemic shunt (TIPS) insertion is a minimally invasive procedure that is used for the decompression of elevated portal pressure. Technical complications to this procedure include capsular perforation affecting up to 33% of cases, with 1%-2% leading to significant intraperitoneal haemorrhage as well as stent misplacement in 20% of cases^[1]. Although initially employed to treat refractory variceal bleeding and ascites, its list of indications has broadened^[2]. Increasing experience with this procedure has led to the recognition of multiple complications including hepatic failure, encephalopathy, sepsis and death. Sustained or relapsing bacteraemia secondary to endovascular vegetative infection of the prosthesis is a rare but serious complication^[3].

In 1998, Sanyal *et al.*^[3] proposed the term "endotipsitis" to describe this disease entity, along with a proposal for diagnostic criteria^[4]. They defined a "definite" infection as continuous clinically significant bacteraemia with vegetative/thrombi inside TIPS and "probable" infection sustained bacteraemia with no other source of infection in a patient with TIPS^[3]. Since this proposal, there have been several suggestions to improve the diagnostic accuracy and sensitivity of the disease.

Incidence and risk factors of endotipsitis are poorly understood due to difficulty in diagnosis and lack of a uniform disease definition^[2]. There are no extensive studies on this topic, the most recent and thorough being a single centre, retrospective study in 2010, which found the incidence of endotipsitis in patients with TIPS to be approximately 1%^[3]. Furthermore, no unified agreement on the best management strategy for these cases to prevent relapses or mortality has been reached. The authors report a case of endotipsitis supplemented with an analysis on a literature review of this disease process and antimicrobial therapy.

Case report

In July 2013 a 30-year-old male with a history of intravenous drug use, chronic liver disease secondary to congenital hepatic fibrosis and alcohol dependence presented with a one month history of fevers, weakness, confusion and rigors. He described a four day history of intermittent stabbing right-sided abdominal pain, non-productive cough, headache and constant fever - all of which had been gradually worsening. He also reported a three-week history of worsening peripheral edema treated with furosemide and spironolactone. Two days

before his admission his family noted confusion and impaired cognitive function.

His past medical history also included resection of a right hepatic lobe mesenchymal hemangioma at age 6, non-bleeding esophageal varices, TIPS insertion 38 mo prior to admission and splenic artery embolization to ameliorate hypersplenism. TIPS insertion was carried out in an elective setting to prevent esophageal variceal bleeds.

On examination, there was evidence of tender hepatomegaly and right flank tenderness. Although his abdomen was distended, there was no evidence of shifting dullness. He had track marks secondary to injections on both arms, symmetrical peripheral edema and tattoos on his back and arms. No abnormalities were found on neurological examination, other than impaired cognition.

Laboratory tests revealed a white blood cell count of $10.7 \times 10^9/L$ with 86% neutrophils, hemoglobin of 93 g/L, platelet count of $63 \times 10^9/L$, aspartate transaminase 819 U/L, alanine aminotransferase 148 U/L, alkaline phosphatase of 2210 U/L, total bilirubin of 23.4 mg/dL (19.8 direct) and a markedly elevated erythrocyte sedimentation rate of 111 mm/h. Blood cultures drawn at admission grew both *Klebsiella oxytoca*, only resistant to ampicillin, and *Escherichia coli* (*E. coli*) (resistant to ampicillin and sulfamethoxazole/trimethoprim).

He was initially treated with piperacillin-tazobactam and gentamicin. Diagnostic workup included doppler ultrasound of the liver showing a patent TIPS with markedly decreased velocity at the portal aspect (17 cm/s, decreased from 104 cm/s two years prior), and computed tomography imaging revealed a non-occlusive filling defect in the superior segment of the TIPS. A transthoracic echocardiogram showed mild mitral and tricuspid regurgitation but no vegetations were seen.

The patient slowly improved despite blood cultures remaining persistently positive for six days and fever continuing for nine days despite appropriate treatment. He subsequently completed a six-week course of combination intravenous antibiotic therapy, at which point antibiotics were changed to oral ciprofloxacin 500 mg daily. In light of the high risk and complication of relapsing bacteraemia and inability to remove the suspected infected TIPS, the relatively inexpensive and well tolerated use of suppressive oral ciprofloxacin was decided until transplant. He was followed for the next 14 mo without infection relapse. Unfortunately the patient was lost to follow up, so was not possible to conduct repeat imaging.

MATERIALS AND METHODS

We performed a MEDLINE database search, January 1956 to November 2013, using terms "infection", "vegetation", "bacteraemia", "sepsis", "tipsitis" and "endotipsitis" combined with the term transjugular intrahepatic portosystemic shunt, TIPSS or TIPS. The

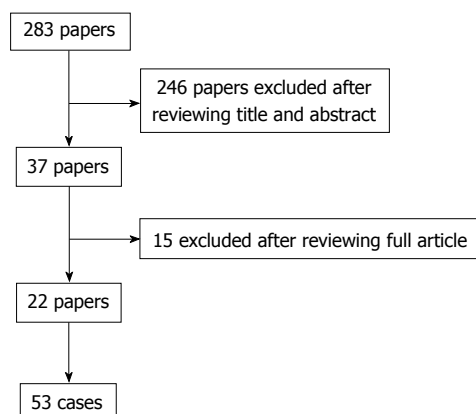


Figure 1 Number of papers excluded and include from the results of the literature review.

titles and abstracts of all papers that appeared on this search were reviewed and excluded accordingly. All data was entered in Microsoft Excel spreadsheet software. Univariate analysis was performed using a χ^2 or Fisher's exact test, as appropriate. Data was analyzed in SPSS, version 16.0^[4]. *P*-values less than 0.05 were considered statistically significant.

RESULTS

Our literature search produced 283 papers, 246 of which were excluded on the basis of their title and abstract. Of the 37 remaining articles, another 15 were excluded after reviewing the contents of the full article. There were 22 papers that reported a sum of 53 cases of "endotipsitis"; 15 case reports and 7 case series (Figure 1). Based on the demographics of the cases, including, age, gender, co-morbidities and aetiological agent, it was possible to exclude any duplications. Analysis includes the case reported by the authors.

Patient characteristics

The mean age was 54.3 years (range 30-69 years; 14 cases unrecorded), with a predominance of males (70.4% vs 17%). The most common underlying disease process was alcoholic liver disease ($n = 32$), 6 of which were also positive for hepatitis B (HBV) ($n = 1$), hepatitis C virus (HCV) ($n = 4$) or both ($n = 1$). HCV cirrhosis ($n = 10$) was the second most common etiology of chronic liver disease, followed by cryptogenic cirrhosis ($n = 9$), HBV ($n = 1$), primary sclerosing cholangitis ($n = 1$) and one case was not recorded. There was no record of whether viral hepatitis positive cases were undergoing treatment at the time of diagnosis of endotipsitis.

Microbiology

Of the 54 cases (including our case report); there were 30 monomicrobial gram-positive infections [of which 14 were *Enterococcal* spp and 7 were *Staphylococcus aureus* (*S. aureus*)], 11 monomicrobial gram-negative

infections (of which 6 were *E. coli*), 5 polymicrobial and 6 *Candida* spp infections (4 *Candida glabrata* and 2 *Candida albicans*). The mean onset of endotipsitis from insertion of TIPS was 277 d, with bacterial being 304 d, and the longest overall being our case report 1158 d (range 6-158 d; 3 unrecorded). Among monomicrobial bacterial infections gram-positive organisms were significantly more common in early-onset infections (less than 120 d following TIPS insertion) than late-onset infections [18/19, (94.7%) vs 9/18 (50%) $P < 0.01$]. The average duration of bacteraemia was 43 d (range 3-20 d; 14 unrecorded).

Treatment

Of the 54 cases reported, 30 (56%) were treated successfully with antimicrobials, 4 (7%) underwent transplantation and 17 (31%) died (Table 1). The average duration of treatment for fungemia and bacteremia was 28 (range 6-51 wk, 3 unrecorded) and 13.5 (range 1-101 wk; 10 unrecorded) wk respectively. Of those with bacteremia, 25 cases were treated with a single antibiotic (19 cases resolved; 2 outcome not recorded), where as 14 were managed with combination antibiotic therapy (1 case patient received 6 different antibiotics; 8 cases resolved). Comparing gram-positive and gram-negative infections, there was no significant difference in mortality [9/30 (30%) vs 4/12 (33%), $P = 0.57$]. Of the 39 antibiotic therapies recorded for bacterial endotipsitis, 7 cases used an aminoglycoside (gentamicin) and 2 used rifampin. None of the staphylococcal cases were treated with gentamicin.

The organisms associated with the highest mortality rates were *S. aureus* (63% mortality) and *Candida* spp (67% mortality). Patients with infections caused by *S. aureus* and *Candida* spp had significantly higher mortality than those infections caused by all other organisms [9/14 (64.3%) vs 8/36 (22.2%) $P < 0.01$]. There was no difference in mortality rate between early and late-onset infections [8/22 (36.4%) vs 7/23 (30.4%) $P = 0.67$].

DISCUSSION

The authors have reported a case of *Klebsiella oxytoca* and *E. coli* polymicrobial endotipsitis with the longest latency of time between TIPS insertion and TIPS infection ever reported. A case of endotipsitis with similar bacteriology was reported previously but was managed quite differently (ceftriaxone monotherapy for 4 wk). Our literature review reviews the largest number of reported endotipsitis cases to date and provides a window into a rare disease, heterogeneous in both its microbiologic etiology and management approaches.

Endotipsitis is suspected in the setting of unexplained bacteremia in a patient with TIPS, supported by abnormalities in TIPS flow or the presence of vegetation

Table 1 Demographics for each case identified in the literature review as well as microorganisms isolated and duration and type of antimicrobials

Etiological agent	Outcome	Duration of bacteremia (d)	Treatment	Duration of treatment (wk)	Cirrhosis etiology	Onset (d)	Ref.
Gram positive, monomicrobial infections							
<i>Staphylococcus aureus</i>	R	6	Vancomycin	6	EtOH	110	[3]
	Tx	-	Rifampin	-	HCV	38	[17]
	D	15	Ciprofloxacin	9	HCV	8	[6]
			Penicillin				
			Vancomycin				
			Teicoplanin				
			Rifampin				
	D	-	Flucloxacillin	2	EtOH	663	[2]
	D	5	Vancomycin	1	EtOH, HBV, HCV	100	[18]
	D	-	-	-	HCV	38	[17]
<i>Staphylococcus aureus</i> (MRSA)	R	46	Vancomycin	6	Cryptogenic	300	[5]
			Linezolid				
<i>Staphylococcus epidermidis</i>	R	25	Daptomycin	6	EtOH	7	[19]
	R	30	Vancomycin	6	EtOH	120	[5]
<i>Enterococcus spp. (unspecified)</i>	R	14	Vancomycin	6	Cryptogenic	47	[5]
	R	10	Vancomycin	28	EtOH, HCV	10	[20]
			Gentamicin				
	R	3	Vancomycin	2	EtOH	60	[18]
			Gentamicin				
	R	21	Vancomycin	7	HCV	-	[20]
	D	-	Vancomycin	-	EtOH	60	[20]
	Tx	-	-	-	HCV	38	[20]
	D	-	-	-	HCV	38	[20]
	D	-	-	-	HCV	38	[20]
<i>Enterococcus faecalis</i>	R	90	Gentamicin	6	EtOH	420	[21]
			Amphotericin				
	R	100	Quinupristin	14	Cryptogenic	-	[22]
	R	10	Vancomycin	8	Cryptogenic	60	[23]
	Tx	10	Vancomycin	4	Cryptogenic	90	[16]
<i>Enterococcus faecium</i>	R	10	Vancomycin	28	EtOH	10	[20]
	-	-	Vancomycin	1	EtOH	375	[2]
<i>Streptococcus sanguis</i>	R	6	Penicillin	4	EtOH	416	[3]
<i>Gemella morbillorum</i>	R	5	Vancomycin	2	PSC	6	[18]
	R	60	Ampicillin	44	EtOH	56	[24]
<i>Streptococcus bovis</i>	R	6	Vancomycin	6	Cryptogenic	416	[3]
<i>Lactobacillus rhamnosus</i>	R	-	Netilmicin,	12	EtOH	730	[2]
			Clarithromycin				
<i>Lactobacillus acidophilus</i>	D	4	Ampicillin	4	EtOH	732	[18]
	D	3	Ampicillin	6	EtOH	146	[18]
			Gentamicin				
Gram negative, monomicrobial infections							
<i>Escherichia coli</i>	R	6	Ceftriaxone	4	EtOH	183	[3]
	R	6	Ceftriaxone	4	EtOH	532	[3]
	R	31	Ciprofloxacin	16	EtOH	1065	[6]
	D	-	Ceftriaxone	12	EtOH	282	[2]
			Gentamicin				
	D	-	Ceftriaxone	12	EtOH	1092	[2]
			Vancomycin				
			Piperacillin-				
			Tazobactam				
			Amoxicillin				
	D	-	Meropenem	3	EtOH	765	[2]
			Amikacin				
<i>Klebsiella pneumoniae</i>	R	6	Ceftriaxone	4	EtOH, HCV	329	[3]
<i>Klebsiella (unspecified) MDR</i>	R	9	Tigecycline	-	EtOH	1095	[25]
<i>Serratia marcescens</i>	R	49	Imipenem	98	EtOH	21	[26]
<i>Enterobacter cloacae</i>	R	-	Ceftriaxone	12	EtOH	1065	[2]
			Gentamicin				
			Vancomycin				
			Piperacillin-				
			Tazobactam				
			Meropenem				
			Ciprofloxacin				

<i>Salmonella typhi</i>	-	-	-	-	-	-	[27]
Fungal infections							
<i>Candida glabrata</i>	R	1700	Amphotericin	51	HCV	180	[28]
	D	27	Amphotericin	27	Cryptogenic	27	[29]
	D	-	Fluconazole	-	EtOH	150	[30]
	D	60	Posaconazole	6	EtOH	-	[31]
<i>Candida albicans</i>	R	-	-	-	HBV	38	[18]
	D	-	-	-	HCV	38	[18]
Polymicrobial infections							
<i>Staphylococcus aureus</i> / <i>Pseudomonas aeruginosa</i>	D	14	Ticarcillin-clavulanic acid	-	EtOH, HBV	35	[6]
			Gentamicin				
			Amikacin				
			Ciprofloxacin				
<i>Escherichia coli</i> / <i>Klebsiella oxytoca</i>	R	6	Ceftriaxone	4	EtOH	235	[3]
<i>Escherichia coli</i> / <i>Acinetobacter</i>	R	6	Ceftriaxone	6	EtOH	285	[3]
<i>Escherichia coli</i> / <i>Klebsiella oxytoca</i>	R	6	Piperacillin- Tazobactam	6	Cryptogenic, EtOH	1158	-
			Gentamicin				
"Polymicrobial"	R	720	-	101	HCV	100	[32]
"Polymicrobial"	Tx	90	-	-	HCV	180	[15]
Unknown	-	-	-	-	-	-	[2]

D: Death; Tx: Transplant; R: Resolved; EtOH: Alcoholic liver disease; HBV: Hepatitis B virus; HCV: Hepatitis C virus.

and remains a diagnosis of exclusion, but there have been propositions to improve the diagnostic accuracy. Bouza *et al*^[5] suggested using quantitative bacteriology, where by comparison of colony counts of peripheral venous blood and portal blood will show a substantial increase in bacteria of the latter sample. The gold standard would be to take a biopsy from the pseudo-epithelium of the TIPS, which can only be done at autopsy or after transplantation and is therefore not a viable option in clinical practice^[6].

It is evident from our review that no single micro-organism is the predominant etiological agent, but most infections were caused by gram-positive organisms^[5,6]. This trend has also been reported in studies investigating spontaneous bacterial peritonitis and nosocomial infections in cirrhotic patients and may be attributed to widespread use of fluoroquinolone prophylaxis in this population^[7,8]. Bouza *et al*^[5] suggested however that etiology of the infection could be influenced by the onset of infection post TIPS insertion, which can be categorised as early-onset (within 120 d) or late-onset (over 120 d post insertion). In their review of 36 cases, they found that all *Enterococcus* spp exclusively occurred in early infections, which was not confirmed in our review, with no significant difference between the groups in number of *Enterococcus* spp cases isolated ($P = 0.23$; 95%CI: 0.08-1.77). There was also no significant difference in mortality between early and late infections ($P = 0.76$; 95%CI: 0.35-0.44). Our data also reflect an association between early-onset infections and gram-positive organisms.

Due to the wide variety of causative pathogens and overall rarity of this disease, it is highly unlikely that prospective data will guide management decisions of this clinical entity. As there is a variation in antibiotic choice and duration of treatment on review of the literature, the evidence base is too limited to support specific antibiotic

recommendations. It may be reasonable that patients diagnosed with endotipsitis should be treated based on the principles of prosthetic valve endocarditis (PVE) management, as in many ways the two disease entities are analogous. Both are endovascular infections involving difficult to remove prosthetic material that confer a high rate of treatment failure and relapse. We found antimicrobial management strategies that were overall quite divergent from the pathogen specific treatment guidelines for PVE. For example, staphylococcal PVE is generally treated with a cell wall active agent (*e.g.*, oxacillin or vancomycin) plus rifampin and gentamicin^[9]. Of the 9 cases of staphylococcal endotipsitis reported here, 7 treatment courses were previously published with none including gentamicin and only 2 including rifampin. It is impossible to know whether addition of these agents would have improved the poor response rate we saw in this subgroup (44%). Acknowledging the reluctance of using drugs with potential hepatotoxicity and nephrotoxicity, in the face of treatment response rates below 50%, the potential benefits may outweigh the risks, when administering in a monitored setting.

S. aureus and *Candida* spp are both known to be able to resist the antimicrobial effects of antibiotics through the formation of biofilms^[10]. This propensity underlies the rationale to remove medical devices such as central venous catheters when infected with these organisms, thus reducing the attributable mortality^[11]. When comparing the treatment of monomicrobial infections in endotipsitis cases, there was a significantly lower response rate to antimicrobials alone in those with *S. aureus* or candidal infection compared to other pathogens. Therefore, when managing these patients, transplantation should be considered as a means of cure, as there is a significantly lower chance that they will respond with antibiotics and retention of the TIPS.

Of the 6 cases of fungal endotipsitis (all *Candida*

spp), only 2 responded to antifungal treatment. Similarly, *Candida* spp are the most common cause of fungal infective endocarditis (IE), with these patients more likely to have prosthetic intravascular devices^[12]. Baddley *et al*^[12] found persistently positive blood cultures were associated with this group as well as a significantly higher rate of mortality when compared to non-fungal cases of IE^[13]. With the accumulating evidence of dismal outcomes in patients with candidal endotipsitis, strong consideration for urgent transplantation needs to be contemplated in appropriate patients^[14,15].

In patients who are ineligible for transplantation aggressive medical therapy and potentially chronic suppressive antibiotics should be considered acknowledging the prognosis is poor. In general, the role and timing of liver transplantation in the setting of endotipsitis is poorly understood. In our review we identified four patients who underwent transplantation. Mizrahi *et al*^[1] did report clearance of blood cultures prior to transplant in their 2 cases^[16,17]. Jawaid *et al*^[15] described a case with repeat episodes of bacteraemia, 1 mo after TIPS insertion, with 9 different microorganisms isolated from blood cultures over the period of 11 mo. Willner *et al*^[16] reported persistent polymicrobial bacteraemia 4 d after a TIPS revision, which resulted in a transplant 3 mo later (after 3 episodes of bacteraemia). It unclear whether the patients had negative blood cultures leading up to their transplant. In both cases, a biliary-venous fistula was not identified until after the assessment of the explant. Among patients with suspected endotipsitis and persistent or relapsing bacteremia, biliary-venous fistula should be considered and in this setting transplantation would be warranted to achieve cure.

Optimal treatment of endotipsitis remains elusive given the difficulty of studying a rare disease without a broadly accepted definition and caused by a variety of microbes. Our data suggests that infections caused by *S. aureus* and *Candida* spp is associated with particularly poor outcomes. Based on the treatment of PVE, addition of gentamicin and rifampin to cell wall active antimicrobials may improve outcomes of *S. aureus* endotipsitis cases. Transplantation should be strongly considered in the setting of relapsing disease and infections caused by difficult to eradicate pathogens. More data on the epidemiology and management outcomes of endotipsitis will be needed to determine the most appropriate prevention and treatment strategies.

COMMENTS

Background

"Endotipsitis" is a poorly understood complication of transjugular intrahepatic portosystemic shunt (TIPS) procedures. Sustained or relapsing bacteraemia secondary to endovascular vegetative infection of the prosthesis, "endotipsitis", is a rare but serious complication. The authors report a case with the longest latency from insertion to infection in the literature, supplemented by a review of the literature, in particular the management of this insidious and variable disease process.

Research frontiers

Incidence and risk factors of endotipsitis are poorly understood due to difficulty

in diagnosis and lack of a uniform disease definition. Furthermore, no unified agreement on the best management strategy for these cases to prevent relapses or mortality has been reached.

Innovations and breakthroughs

The authors' data reflects an association between early-onset infections and gram-positive organisms. It also suggests that infections caused by *Staphylococcus aureus* (*S. aureus*) and *Candida* spp are associated with particularly poor outcomes. The evidence base is too limited to support specific antibiotic recommendations, but it may be reasonable to treat based on the principles of prosthetic valve endocarditis (PVE) management.

Applications

Transplantation should be strongly considered in those with infections associated with particularly poor outcomes, such as *Candida* spp. Based on the treatment of PVE, addition of gentamicin and rifampin to cell wall active antimicrobials may improve outcomes of *S. aureus* endotipsitis cases.

Terminology

TIPS insertion is a minimally invasive procedure that is used for the decompression of elevated portal pressure. Although there is no universally accepted definition of "endotipsitis", it is generally agreed that it can be defined as "definite" infection (continuous clinically significant bacteraemia with vegetative/thrombi inside TIPS) and "probable" infection (sustained bacteraemia with no other source of infection in a patient with TIPS).

Peer-review

The manuscript presents an interesting case of "endotipsitis" and reviews the literature on a rare disease. In this paper Navaratnam *et al* present a case of "endotipsitis" and performed a review of the existing literature on this field. They identified 22 papers reporting 54 patients with endotipsitis. The great majority had monomicrobial infections (gram positive agents were the majority). Infections with *S. aureus* and *Candida* spp were associated higher mortality. No homogeneous management was applied for the treatment of this condition and guidelines on antibiotics use are usually derivate from the treatment of endocarditis.

REFERENCES

- 1 Mizrahi M, Adar T, Shouval D, Bloom AI, Shibolet O. Endotipsitis-persistent infection of transjugular intrahepatic portosystemic shunt: pathogenesis, clinical features and management. *Liver Int* 2010; **30**: 175-183 [PMID: 19929905 DOI: 10.1111/j.1478-3231] 2
- 2 Kochar N, Tripathi D, Arestis NJ, Ireland H, Redhead DN, Hayes PC. Tipsitis: incidence and outcome-a single centre experience. *Eur J Gastroenterol Hepatol* 2010; **22**: 729-735 [PMID: 20440117 DOI: 10.1097/MEG.0b013e3282fd6917]
- 3 Sanyal AJ, Reddy KR. Vegetative infection of transjugular intrahepatic portosystemic shunts. *Gastroenterology* 1998; **115**: 110-115 [PMID: 9649465 DOI: 10.1016/S0016-5085(98)70371-3]
- 4 Fisher RA. On the interpretation of Chi-square from contingency tables and the calculation of P. *J R Stat Soc* 1922; **85**: 87-94 [DOI: 10.2307/2340521]
- 5 Bouza E, Muñoz P, Rodríguez C, Grill F, Rodríguez-Créixems M, Bañares R, Fernández J, García-Pagán JC. Endotipsitis: an emerging prosthetic-related infection in patients with portal hypertension. *Diagn Microbiol Infect Dis* 2004; **49**: 77-82 [PMID: 15183855 DOI: 10.1016/j.diagmicrobio.2004.03.006]
- 6 Armstrong PK, MacLeod C. Infection of transjugular intrahepatic portosystemic shunt devices: three cases and a review of the literature. *Clin Infect Dis* 2003; **36**: 407-412 [PMID: 12567297 DOI: 10.1086/346156]
- 7 Fernández J, Navasa M, Gómez J, Colmenero J, Vila J, Arroyo V, Rodés J. Bacterial infections in cirrhosis: epidemiological changes with invasive procedures and norfloxacin prophylaxis. *Hepatology* 2002; **35**: 140-148 [PMID: 11786970 DOI: 10.1053/jhep.2002.30082]
- 8 Gould FK, Denning DW, Elliott TS, Foweraker J, Perry JD, Prendergast BD, Sandoe JA, Spry MJ, Watkin RW. Guidelines for the diagnosis and antibiotic treatment of endocarditis in adults: a report of the Working Party of the British Society for Antimicrobial Chemotherapy. *J Antimicrob Chemother* 2012; **67**: 269-289 [PMID: 22086858 DOI: 10.1093/jac/dkr450]
- 9 Harriott MM, Noverr MC. *Candida albicans* and *Staphylococcus*

- aureus form polymicrobial biofilms: effects on antimicrobial resistance. *Antimicrob Agents Chemother* 2009; **53**: 3914-3922 [PMID: 19564370 DOI: 10.1128/AAC.00657-09]
- 10 **Steinbach WJ**, Perfect JR, Cabell CH, Fowler VG, Corey GR, Li JS, Zaas AK, Benjamin DK. A meta-analysis of medical versus surgical therapy for *Candida* endocarditis. *J Infect* 2005; **51**: 230-247 [PMID: 16230221 DOI: 10.1016/j.jinf.2004.10.016]
 - 11 **Falcone M**, Barzaghi N, Carosi G, Grossi P, Minoli L, Ravasio V, Rizzi M, Suter F, Utili R, Viscoli C, Venditti M; Italian Study on Endocarditis. *Candida* infective endocarditis: report of 15 cases from a prospective multicenter study. *Medicine* (Baltimore) 2009; **88**: 160-168 [PMID: 19440119 DOI: 10.1097/MD.0b013e3181a693f8]
 - 12 **Baddley JW**, Benjamin DK, Patel M, Miró J, Athan E, Barsic B, Bouza E, Clara L, Elliott T, Kanafani Z, Klein J, Lerakis S, Levine D, Spelman D, Rubinstein E, Tornos P, Morris AJ, Pappas P, Fowler VG, Chu VH, Cabell C; International Collaboration on Endocarditis-Prospective Cohort Study Group (ICE-PCS). *Candida* infective endocarditis. *Eur J Clin Microbiol Infect Dis* 2008; **27**: 519-529 [PMID: 18283504 DOI: 10.1007/s10096-008-0466-x]
 - 13 **Mora-Duarte J**, Betts R, Rotstein C, Colombo AL, Thompson-Moya L, Smietana J, Lupinacci R, Sable C, Kartsonis N, Perfect J. Comparison of caspofungin and amphotericin B for invasive candidiasis. *N Engl J Med* 2002; **347**: 2020-2029 [PMID: 12490683 DOI: 10.1056/NEJMoa021585]
 - 14 **Kullberg BJ**, Sobel JD, Ruhnke M, Pappas PG, Viscoli C, Rex JH, Cleary JD, Rubinstein E, Church LW, Brown JM, Schlamm HT, Oborska IT, Hilton F, Hodges MR. Voriconazole versus a regimen of amphotericin B followed by fluconazole for candidaemia in non-neutropenic patients: a randomised non-inferiority trial. *Lancet* 2005; **366**: 1435-1442 [PMID: 16243088 DOI: 10.1016/S0140-6736(05)67490-9]
 - 15 **Jawaid Q**, Saeed ZA, Di Bisceglie AM, Brunt EM, Ramrakhiani S, Varma CR, Solomon H. Biliary-venous fistula complicating transjugular intrahepatic portosystemic shunt presenting with recurrent bacteremia, jaundice, anemia and fever. *Am J Transplant* 2003; **3**: 1604-1607 [PMID: 14629294 DOI: 10.1046/j.1600-6135.2003.00267.x]
 - 16 **Willner IR**, El-Sakr R, Werkman RF, Taylor WZ, Riely CA. A fistula from the portal vein to the bile duct: an unusual complication of transjugular intrahepatic portosystemic shunt. *Am J Gastroenterol* 1998; **93**: 1952-1955 [PMID: 9772063 DOI: 10.1111/j.1572-0241.1998.00553.x]
 - 17 **Mizrahi M**, Roemi L, Shouval D, Adar T, Korem M, Moses A, Bloom A, Shibolet O. Bacteremia and "Endotipsitis" following transjugular intrahepatic portosystemic shunting. *World J Hepatol* 2011; **3**: 130-136 [PMID: 21731907 DOI: 10.4254/wjh.v3.i5.130]
 - 18 **DeSimone JA**, Beavis KG, Eschelman DJ, Henning KJ. Sustained bacteremia associated with transjugular intrahepatic portosystemic shunt (TIPS). *Clin Infect Dis* 2000; **30**: 384-386 [PMID: 10671346 DOI: 10.1086/313653]
 - 19 **Colston JM**, Scarborough M, Collier J, Bowler IC. High-dose daptomycin monotherapy cures *Staphylococcus epidermidis* 'endotipsitis' after failure of conventional therapy. *BMJ Case Rep* 2013; **2013**: pii: bcr2013009529 [PMID: 23595199 DOI: 10.1136/bcr-2013-009529]
 - 20 **Brown RS**, Brumage L, Yee HF, Lake JR, Roberts JP, Somberg KA. Enterococcal bacteremia after transjugular intrahepatic portosystemic shunts (TIPS). *Am J Gastroenterol* 1998; **93**: 636-639 [PMID: 9576462 DOI: 10.1111/j.1572-0241.1998.180_b.x]
 - 21 **Passeron A**, Mihaïla-Amrouche L, Perreira Rocha E, Wyplosz B, Capron L. [Recurrent enterococcal bacteremia associated with a transjugular intrahepatic portosystemic shunt]. *Gastroenterol Clin Biol* 2004; **28**: 1284-1286 [PMID: 15671940 DOI: 10.1016/S0399-8320(04)95222-0]
 - 22 **Zaman MM**, Recco R, Tejwani U, Scuto TJ, Ahmed S, Hypolite A, Jayaraman G. Case of vancomycin-resistant *Enterococcus faecium* infection associated with a transjugular intrahepatic portosystemic shunt that was treated with quinupristin/dalfopristin after bacteremia persisted with alatrofloxacin therapy. *Clin Infect Dis* 1999; **29**: 954-955 [PMID: 10589932 DOI: 10.1086/520480]
 - 23 **Eversman D**, Chalasani N. A case of infective endotipsitis. *Gastroenterology* 1999; **117**: 514 [PMID: 10465639 DOI: 10.1053/gast.1999.0029900514a]
 - 24 **Medina-Gens L**, López J, Manzanedo B, Pintado V. [Endotipsitis due to *Gemella morbillorum*]. *Enferm Infecc Microbiol Clin* 2007; **25**: 419-420 [PMID: 17583662 DOI: 10.1157/13106974]
 - 25 **Aggarwal S**, Park J. Endotipsitis: a diagnostic challenge. *J Postgrad Med* 2011; **57**: 134 [PMID: 21654138 DOI: 10.4103/0022-3859.81875]
 - 26 **Marques N**, Sá R, Coelho F, da Cunha S, Meliço-Silvestre A. Spondylodiscitis associated with recurrent *Serratia* bacteremia due to a transjugular intrahepatic portosystemic shunt (TIPS): a case report. *Braz J Infect Dis* 2007; **11**: 525-527 [PMID: 17962882 DOI: 10.1590/S1413-86702007000500016]
 - 27 **Barrio J**, Castiella A, Von Wichman MA, Cosme A, López P, Arenas JL. [Spontaneous bacteremia due to *Salmonella* hadar in liver cirrhosis with transjugular intrahepatic portosystemic shunt]. *Gastroenterol Hepatol* 1999; **22**: 79-81 [PMID: 10193091]
 - 28 **Brickey TW**, Trotter JF, Johnson SP. *Torulopsis glabrata* fungemia from infected transjugular intrahepatic portosystemic shunt stent. *J Vasc Interv Radiol* 2005; **16**: 751-752 [PMID: 15872333 DOI: 10.1097/01.RVI.0000153587.52276.06]
 - 29 **Darwin P**, Mergner W, Thuluvath P. *Torulopsis glabrata* fungemia as a complication of a clotted transjugular intrahepatic portosystemic shunt. *Liver Transpl Surg* 1998; **4**: 89-90 [PMID: 9457972 DOI: 10.1002/lt.500040112]
 - 30 **Schiano TD**, Atillasoy E, Fiel MI, Wolf DC, Jaffe D, Cooper JM, Jonas ME, Bodenheimer HC, Min AD. Fatal fungemia resulting from an infected transjugular intrahepatic portosystemic shunt stent. *Am J Gastroenterol* 1997; **92**: 709-710 [PMID: 9128335]
 - 31 **Anstead GM**, Martinez M, Graybill JR. Control of a *Candida glabrata* prosthetic endovascular infection with posaconazole. *Med Mycol* 2006; **44**: 273-277 [PMID: 16702108 DOI: 10.1080/13693780500049152]
 - 32 **Suhocki PV**, Smith AD, Tendler DA, Sexton DJ. Treatment of TIPS/biliary fistula-related endotipsitis with a covered stent. *J Vasc Interv Radiol* 2008; **19**: 937-939 [PMID: 18503911 DOI: 10.1016/j.jvir.2008.01.026]

P-Reviewer: De Ponti F, Narciso-Schiavon JL, Procopet B
S-Editor: Tian YL **L-Editor:** A **E-Editor:** Liu SQ





Published by **Baishideng Publishing Group Inc**

8226 Regency Drive, Pleasanton, CA 94588, USA

Telephone: +1-925-223-8242

Fax: +1-925-223-8243

E-mail: bpgoffice@wjgnet.com

Help Desk: <http://www.wjgnet.com/esps/helpdesk.aspx>

<http://www.wjgnet.com>

