

# World Journal of *Clinical Cases*

*World J Clin Cases* 2023 September 16; 11(26): 6031-6317



## Contents

Thrice Monthly Volume 11 Number 26 September 16, 2023

## MINIREVIEWS

- 6031 Diabetes among Muslims during Ramadan: A narrative review

*Ochani RK, Shaikh A, Batra S, Pikale G, Surani S*

## ORIGINAL ARTICLE

## Retrospective Cohort Study

- 6040 Clinical evaluation of ventilation mode on acute exacerbation of chronic obstructive pulmonary disease with respiratory failure

*Wang JJ, Zhou Z, Zhang LY*

## Retrospective Study

- 6051 Predictive value of preoperative albumin-bilirubin score and other risk factors for short-term outcomes after open pancreatoduodenectomy

*Zavrtanik H, Cosola D, Badovinac D, Hadžialjević B, Horvat G, Plevel D, Bogoni S, Tarchi P, de Manzini N, Tomažič A*

- 6066 Lyophilized recombinant human brain natriuretic peptide for chronic heart failure: Effects on cardiac function and inflammation

*Li F, Li H, Luo R, Pei JB, Yu XY*

- 6073 Continuous renal replacement therapy with oXiris® in patients with hematologically malignant septic shock: A retrospective study

*Wang J, Wei SR, Ding T, Zhang LP, Weng ZH, Cheng M, Zhou Y, Zhang M, Liu FJ, Yan BB, Wang DF, Sun MW, Cheng WX*

- 6083 Serum basic fibroblast growth factor and interleukin-1 $\beta$  predict the effect of first-line chemotherapy in patients with advanced gastric cancer

*Zheng L, Gan LH, Yao L, Li B, Huang YQ, Zhang FB, Kuang MQ, Fang N*

- 6091 Multinucleated giant cells of bladder mucosa are modified telocytes: Diagnostic and immunohistochemistry algorithm and relation to PD-L1 expression score

*Gulinac M, Velikova T, Dikov D*

## Clinical Trials Study

- 6105 Comparing the efficacy of regen-cov, remdesivir, and favipiravir in reducing invasive mechanical ventilation need in hospitalized COVID-19 patients

*Hegazy SK, Tharwat S, Hassan AH*

## META-ANALYSIS

- 6122 Risk factors for stroke recurrence in young patients with first-ever ischemic stroke: A meta-analysis

*Xia Y, Liu H, Zhu R*

## SCIENTOMETRICS

- 6132** Unveiling the hidden world of gut health: Exploring cutting-edge research through visualizing randomized controlled trials on the gut microbiota

*Zyoud SH, Shakhshir M, Abushanab AS, Koni A, Shahwan M, Jairoun AA, Abu Taha A, Al-Jabi SW*

## CASE REPORT

- 6147** Rivaroxaban for the treatment of heparin-induced thrombocytopenia with thrombosis in a patient undergoing artificial hip arthroplasty: A case report

*Ly FF, Li MY, Qu W, Jiang ZS*

- 6154** Mepolizumab induced palmoplantar psoriasis: A case report

*Artosi F, Diluvio L, Vultaggio M, Campione E, Bianchi L*

- 6159** Early diagnosis of renal pelvis villous adenoma: A case report

*Li LL, Song PX, Xing DF, Liu K*

- 6165** Identification of the dominant loop of a dual-loop macro-reentry left atrial flutter without prior intervention using high-density mapping technology: A case report

*Yu SD, Chu YP*

- 6170** Surgery for fibrous dysplasia associated with aneurysmal-bone-cyst-like changes in right proximal femur: A case report

*Xie LL, Yuan X, Zhu HX, Pu D*

- 6176** Efficacy of abatacept treatment in a patient with enteropathy carrying a variant of unsignificance in *CTLA4* gene: A case report

*Musabak U, Erdoğan T, Ceylaner S, Özbek E, Suna N, Özdemir BH*

- 6183** Postpartum hemophagocytic lymphohistiocytosis: A case report

*An JH, Ahn JH*

- 6189** Non-arteritic anterior ischemic optic neuropathy combined with branch retinal vein obstruction: A case report

*Gong HX, Xie SY*

- 6194** Large colonic lipoma with a laterally spreading tumor treated by endoscopic submucosal dissection: A case report

*Bae JY, Kim HK, Kim YJ, Kim SW, Lee Y, Ryu CB, Lee MS*

- 6200** T/myeloid mixed-phenotype acute leukemia treated with venetoclax and decitabine: A case report

*Park S, Jeong EJ, Kang JH, Lee GW, Go SI, Lee DH, Koh EH*

- 6206** Severe inflammatory disorder in trisomy 8 without myelodysplastic syndrome and response to methylprednisolone: A case report

*Pan FY, Fan HZ, Zhuang SH, Pan LF, Ye XH, Tong HJ*

- 6213** Aggressive variant prostate cancer: A case report and literature review  
*Weng XT, Lin WL, Pan QM, Chen TF, Li SY, Gu CM*
- 6223** Typical Zollinger-Ellison syndrome-atypical location of gastrinoma and absence of hypergastrinemia: A case report and review of literature  
*Zhang JM, Zheng CW, Li XW, Fang ZY, Yu MX, Shen HY, Ji X*
- 6231** Left epigastric isolated tumor fed by the inferior phrenic artery diagnosed as ectopic hepatocellular carcinoma: A case report  
*Liu HB, Zhao LH, Zhang YJ, Li ZF, Li L, Huang QP*
- 6240** Squamous cell carcinoma associated with endometriosis in the uterus and ovaries: A case report  
*Cai Z, Yang GL, Li Q, Zeng L, Li LX, Song YP, Liu FR*
- 6246** Intestinal obstruction due to giant liver cyst: A case report  
*Küçük A, Mohamed SS, Abdi AM, Ali AY*
- 6252** Difficulties in diagnosing angiomatoid fibrous histiocytoma of the head and neck region: A case report  
*Michcik A, Bieñ M, Wojciechowska B, Polcyn A, Garbacewicz Ł, Kowalski J, Drogozewska B*
- 6262** Efficacy of tolvaptan in an infant with syndrome of inappropriate antidiuretic hormone secretion associated with holoprosencephaly: A case report  
*Mori M, Takeshita S, Nakamura N, Mizuno Y, Tomita A, Aoyama M, Kakita H, Yamada Y*
- 6268** Recurrent hemoptysis in pediatric bronchial Dieulafoy's disease with inferior phrenic artery supply: A case report  
*Wang F, Tang J, Peng M, Huang PJ, Zhao LJ, Zhang YY, Wang T*
- 6274** Variant of Guillain-Barré syndrome with anti-sulfatide antibody positivity and spinal cord involvement: A case report  
*Liu H, Lv HG, Zhang R*
- 6280** Secondary pulmonary infection by *Fusarium solani* and *Aspergillus niger* during systemic steroid treatment for COVID-19: A case report  
*Usuda D, Kato M, Sugawara Y, Shimizu R, Inami T, Tsuge S, Sakurai R, Kawai K, Matsubara S, Tanaka R, Suzuki M, Shimozawa S, Hotchi Y, Osugi I, Katou R, Ito S, Mishima K, Kondo A, Mizuno K, Takami H, Komatsu T, Oba J, Nomura T, Sugita M*
- 6289** Collision tumor of primary malignant lymphoma and adenocarcinoma in the colon diagnosed by molecular pathology: A case report and literature review  
*Jiang M, Yuan XP*
- 6298** Successful resolution of gastric perforation caused by a severe complication of pancreatic walled-off necrosis: A case report  
*Noh BG, Yoon M, Park YM, Seo HI, Kim S, Hong SB, Park JK, Lee MW*
- 6304** Bilateral dislocation of the long head of biceps tendon with intact rotator cuff tendon: A case report  
*Sohn HJ, Cho CH, Kim DH*

- 6311** Delayed diagnosis of abdominal Henoch-Schonlein purpura in children: A case report

*Guo H, Wang ZL, Tao Z*



**ABOUT COVER**

Editorial Board Member of *World Journal of Clinical Cases*, Vikram K Mahajan, MD, Professor, Dermatology, Venereology and Leprosy, Dr. Radhakrishnan Government Medical College, Kangra 177001, Himachal Pradesh, India. vkm1@rediffmail.com

**AIMS AND SCOPE**

The primary aim of *World Journal of Clinical Cases* (WJCC, *World J Clin Cases*) is to provide scholars and readers from various fields of clinical medicine with a platform to publish high-quality clinical research articles and communicate their research findings online.

WJCC mainly publishes articles reporting research results and findings obtained in the field of clinical medicine and covering a wide range of topics, including case control studies, retrospective cohort studies, retrospective studies, clinical trials studies, observational studies, prospective studies, randomized controlled trials, randomized clinical trials, systematic reviews, meta-analysis, and case reports.

**INDEXING/ABSTRACTING**

The WJCC is now abstracted and indexed in Science Citation Index Expanded (SCIE, also known as SciSearch®), Journal Citation Reports/Science Edition, Current Contents®/Clinical Medicine, PubMed, PubMed Central, Reference Citation Analysis, China National Knowledge Infrastructure, China Science and Technology Journal Database, and Superstar Journals Database. The 2023 Edition of Journal Citation Reports® cites the 2022 impact factor (IF) for WJCC as 1.1; IF without journal self cites: 1.1; 5-year IF: 1.3; Journal Citation Indicator: 0.26; Ranking: 133 among 167 journals in medicine, general and internal; and Quartile category: Q4.

**RESPONSIBLE EDITORS FOR THIS ISSUE**

Production Editor: Hua-Ge Yin; Production Department Director: Xu Guo; Editorial Office Director: Jin-Lei Wang.

**NAME OF JOURNAL**

*World Journal of Clinical Cases*

**ISSN**

ISSN 2307-8960 (online)

**LAUNCH DATE**

April 16, 2013

**FREQUENCY**

Thrice Monthly

**EDITORS-IN-CHIEF**

Bao-Gan Peng, Jerzy Tadeusz Chudek, George Kontogeorgos, Maurizio Serati, Ja Hyeon Ku

**EDITORIAL BOARD MEMBERS**

<https://www.wjgnet.com/2307-8960/editorialboard.htm>

**PUBLICATION DATE**

September 16, 2023

**COPYRIGHT**

© 2023 Baishideng Publishing Group Inc

**INSTRUCTIONS TO AUTHORS**

<https://www.wjgnet.com/bpg/gerinfo/204>

**GUIDELINES FOR ETHICS DOCUMENTS**

<https://www.wjgnet.com/bpg/GerInfo/287>

**GUIDELINES FOR NON-NATIVE SPEAKERS OF ENGLISH**

<https://www.wjgnet.com/bpg/gerinfo/240>

**PUBLICATION ETHICS**

<https://www.wjgnet.com/bpg/GerInfo/288>

**PUBLICATION MISCONDUCT**

<https://www.wjgnet.com/bpg/gerinfo/208>

**ARTICLE PROCESSING CHARGE**

<https://www.wjgnet.com/bpg/gerinfo/242>

**STEPS FOR SUBMITTING MANUSCRIPTS**

<https://www.wjgnet.com/bpg/GerInfo/239>

**ONLINE SUBMISSION**

<https://www.f6publishing.com>



## Mepolizumab induced palmoplantar psoriasis: A case report

Fabio Artosi, Laura Diluvio, Martina Vultaggio, Elena Campione, Luca Bianchi

**Specialty type:** Dermatology

**Provenance and peer review:**

Unsolicited article; Externally peer reviewed.

**Peer-review model:** Single blind

**Peer-review report's scientific quality classification**

Grade A (Excellent): 0  
Grade B (Very good): B  
Grade C (Good): C, C  
Grade D (Fair): 0  
Grade E (Poor): E

**P-Reviewer:** Bai H, China; Lin L, China; Zhang Y, China

**Received:** March 14, 2023

**Peer-review started:** March 14, 2023

**First decision:** April 11, 2023

**Revised:** May 4, 2023

**Accepted:** May 24, 2023

**Article in press:** May 24, 2023

**Published online:** September 16, 2023



**Fabio Artosi, Martina Vultaggio, Elena Campione,** Department of Systems Medicine, University of Rome "Tor Vergata", Rome 00133, Italy

**Laura Diluvio,** Department of Dermatology, Dermatology Unit, Policlinico Tor Vergata, Rome 00133, Italy

**Luca Bianchi,** Department of Dermatology, University Roma Tor Vergata, Rome 00133, Italy

**Corresponding author:** Fabio Artosi, MD, Academic Fellow, Doctor, Department of Systems Medicine, University of Rome "Tor Vergata", 81 Viale Oxford, Rome 00133, Italy.  
[fabio.artosi994@gmail.com](mailto:fabio.artosi994@gmail.com)

### Abstract

#### BACKGROUND

Atopic dermatitis and asthma are two diseases whose pathogenesis is largely attributable to the activation, at least in the initial stages, of T helper (Th)-2 Lymphocytes, the related cytokine axis, and B lymphocytes with antibody production. Psoriasis is conversely a pathology resulting from a recruitment of Th-17 and Th-1 lymphocytes, after an initial role of innate immunity. Mepolizumab is a humanized monoclonal antibody directed against interleukin (IL)-5, a central cytokine in the Th-2 axis, therefore involved in the pathogenesis of asthma. Several authors have described the appearance of psoriatic lesions in patients with asthma or atopic dermatitis following the therapy with dupilumab, a monoclonal antibody that blocks the interleukin (IL)-4, another Th-2 cytokine.

#### CASE SUMMARY

We present the case of a 59-year-old patient who developed psoriasiform lesions on the palms after mepolizumab therapy for asthma, for the activation of the parallel cytokine cascade after the blockade of IL-5. We successfully treated the patient with a topical calcipotriol and betamethasone ointment.

#### CONCLUSION

We should investigate with further attention the possible impact on the human immunological ecosystem put in place by the inhibition of the activity of individual inflammatory mediators, so as to be able to recognize the initial adverse effects early.

**Key Words:** Psoriasis; Interleukin-5; Mepolizumab; Asthma; Immunology; Case report

©The Author(s) 2023. Published by Baishideng Publishing Group Inc. All rights reserved.

**Core Tip:** We report the case of a 59-year-old patient with severe asthma who developed palmar psoriasis after 6 mo from the initiation of treatment with a humanized monoclonal antibody directed against interleukin-5 (IL-5), mepolizumab. There are several case reports of psoriasis induced by dupilumab therapy in the literature, but this phenomenon has not yet been recognized with modulating IL-5R signalling. This article reports the pathogenetic hypotheses that may underlie this phenomenon.

**Citation:** Artosi F, Diluvio L, Vultaggio M, Campione E, Bianchi L. Mepolizumab induced palmoplantar psoriasis: A case report. *World J Clin Cases* 2023; 11(26): 6154-6158

**URL:** <https://www.wjgnet.com/2307-8960/full/v11/i26/6154.htm>

**DOI:** <https://dx.doi.org/10.12998/wjcc.v11.i26.6154>

## INTRODUCTION

Despite the lack of a precise overview of the cytokine ecosystem that governs human immune responses, numerous clues suggest that certain types of diseases are more associated with specific cytokine circuits[1]. Extrinsic asthma, atopic dermatitis, and chronic spontaneous urticaria are indeed based on the hyperactivation of the cytokine pathway associated with a predominantly T helper (Th)2-type or humoral response, as confirmed by the efficacy of drugs against inflammatory mediators, including interleukin (IL)-4, IL-5, IL-9, IL-13, IL-31, and thymic stromal lymphopoietin. Often, these conditions are associated with a large production of immunoglobulins E[2-5].

Psoriasis, on the other hand, is a chronic/relapsing inflammatory skin disease characterized, in an initial phase, by activation of innate immunity, followed by the subsequent involvement of the adaptive counterpart, without the involvement of humoral immunity[6]. Specifically, Th1, Th17, and Th22 lymphocytes are activated in response to the differentiation stimulus of the cytokines IL-12 and IL-23 secreted by the activated dermal dendritic cells. In this context, Th1 cells play an important role in producing interferon- $\gamma$  and tumor necrosis factor- $\alpha$ , amplifying the inflammatory cascade and supplying proliferative stimuli to the keratinocytes. Th17 cells create a positive feedback circuit to increase the production of IL-17 by themselves promoting epidermal hyperplasia and neutrophil recruitment from blood to the psoriasis-affected derma and epidermis[6,7]. Psoriasis affects 2%-5% of the population, and 2.8%-40.9% of individuals with psoriasis have palmoplantar psoriasis (PPP), which is a variant of psoriasis that affects the palms and/or soles and can start at any age[8].

In the literature, there have been several reported cases of patients with atopic dermatitis and/or asthma who, once subjected to treatment with dupilumab, a monoclonal antibody that inhibits IL-4/IL-13 signaling, developed a skin picture of psoriasis for an immunological shift from a Th2/humoral to a Th1/cell-mediated pattern[9-11].

Mepolizumab is a humanized monoclonal antibody directed against IL-5, a central cytokine in the Th-2 axis, therefore involved in the pathogenesis of asthma, is approved by the Food and Drug Administration in 2015. IL-5, secreted by Th2 lymphocytes, has numerous effects on eosinophils, promoting their maturation, activation, survival, and chemotaxis from the bloodstream to the airways[12]. IL-5 acts to increase the likelihood of differentiation of conventional B cells to antibody-secreting plasma cells (ASCs) and synergizes with IL-4[13].

We report the case of a 59-year-old patient with a family history of psoriasis that developed severe psoriasiform lesions on the palms after 6 mo of mepolizumab therapy for severe asthma. We speculate that the appearance of PPP could be explained by a switch of the immune response from the prevalent antibody-mediated immunopathogenesis to a cell-mediated pathology after IL-5 blockage by mepolizumab, in a similar manner to what has occurred in patients after the use of dupilumab.

## CASE PRESENTATION

### Chief complaints

A 59-year-old woman came to the Allergy Dermatology Unit at the Tor Vergata Polyclinic for itchy, scaly erythematous lesions on palmar and plantar skin for 6 mo (Figure 1). She denied any previous exposure to irritating substances.

### History of present illness

The patient had a past medical history of severe asthmatic disease, which was diagnosed at her age of 20 and treated with mepolizumab, a humanized monoclonal antibody directed against IL-5[12], for 12 mo with a good clinical response assessed by a pneumologist.

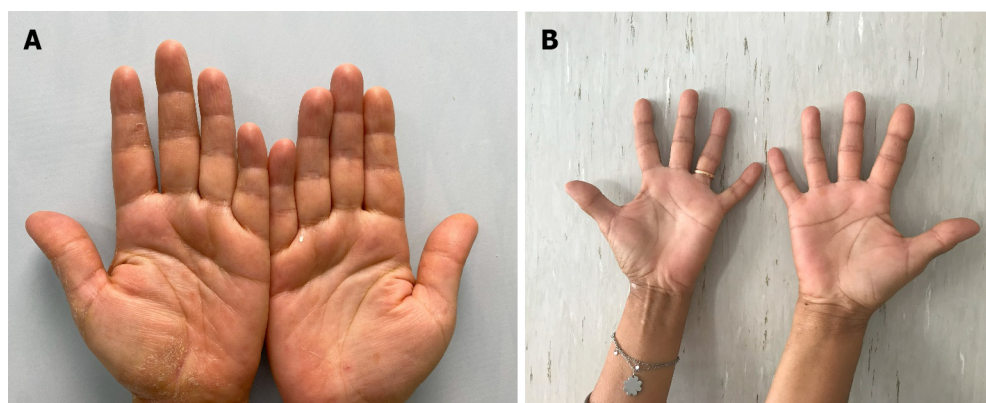
### History of past illness

The patient reported that she had no other pathologies.

### Personal and family history

The patient had a family history of psoriasis, as her father suffered from moderate-severe chronic plaque psoriasis. She





DOI: 10.12998/wjcc.v11.i26.6154 Copyright ©The Author(s) 2023.

**Figure 1** Clinical pictures of affected palms before and after treatment. A: Before treatment; B: After 12 wk.

had no family history for atopy.

### Physical examination

The patient presented itchy, scaly erythematous lesions on palmar and plantar skin for 6 mo; there were no associated lesions on the body, but the nail apparatus showed splinter haemorrhage and pitting. The patient complained of itching and burning, with an itch visual analogue scale (VAS) score of 6. The hand Physician's Global Assessment (PGA) score was estimated to be 3.

### Laboratory examinations

All other physical findings, as well as blood chemistry, urine analysis, and complete blood count, were found to be normal except for the C-reactive protein (CRP) value, slightly above the threshold limit (0.9 mg/dL; normal range: < 0.5 mg/dL).

### Imaging examinations

There was no need for imaging examinations for the dermatologic issue. On dermoscopy, characteristic features of psoriasis lesions were diffuse scaling, white scales, and dotted vessels along with a regular distribution of vessels as shown in Figure 2[14].

---

## FINAL DIAGNOSIS

By clinical evaluation, a diagnosis of PPP was made.

---

## TREATMENT

A topical calcipotriol and betamethasone ointment was prescribed to the affected areas once daily for 8 wk.

---

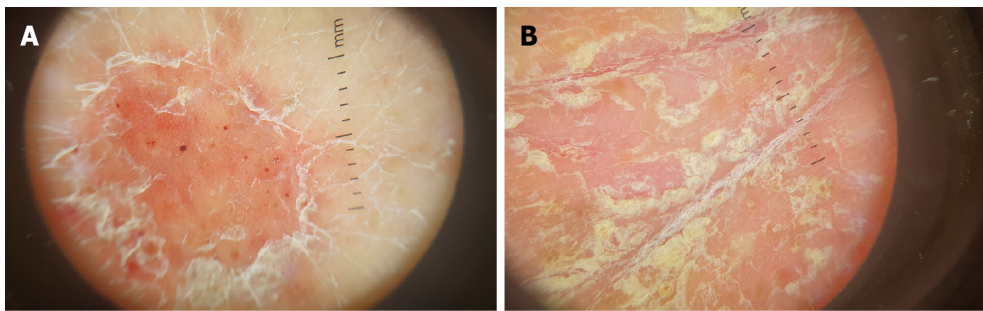
## OUTCOME AND FOLLOW-UP

We prescribed control blood tests and set a date for a new dermatological visit after 12 wk. During the control visit, the patient presented almost complete resolution of the skin features and the symptoms of itch and burning. Itch VAS was assessed and the result was 0. The hand PGA score estimated by the clinician was 0.5. The patient showed us the results of the blood analysis which roughly overlapped with the results shown in the first visit, with a slight increase in CRP (0.8 mg/dL) and a slightly increased cholesterol value (205.0 mg/dL). The patient has continued the treatment with mepolizumab. We prescribed a maintenance treatment with calcipotriol alone three times per week for 8 wk and a new date for a control visit after 12 wk.

---

## DISCUSSION

IL-4 is a cytokine secreted by Th2 lymphocytes and may serve as an excellent paradigm to shed light on the modulation of the balance that governs the immune response, being fundamental not only for the differentiation of naïve Th



DOI: 10.12998/wjcc.v11.i26.6154 Copyright ©The Author(s) 2023.

**Figure 2 Dermoscopic images.** A: Dermoscopic pattern of regularly distributed dotted vessels and white scales; B: Yellow white scales in a thickened hand skin area.

lymphocytes to Th2 lymphocytes, but also for stimulating the production of immunoglobulins by B lymphocytes[1,5,15].

IL-4 is also implicated in suppressing the effector functions of Th1 lymphocytes in the context of pathologies connected to a de-regulation of the latter, such as delayed hypersensitivity, certainly inducing a transient cessation of Th1-type pro-inflammatory activity[1]. In this regard, there is some evidence that psoriasis can improve in laboratory animals subjected to the administration of human IL-4 at a precise therapeutic range[16].

In atopic subjects, it is believed that there is an upregulation of the genes that control the release of IL-4 by Th2 Lymphocytes in response to environmental allergens and clinicians have been interfering for years in this altered Th1-Th2 balance through immunotherapy for atopy[17,18]. This therapeutic strategy, consisting in the injection of purified allergens in patients with atopy, can reduce the production of IL-4 by Th-2 Lymphocytes, reducing the reactivity of the memory Th-2 Lymphocytes to these allergens. By the reduction of IL-4 levels, it was possible to find an increase in the mRNA encoding IL-12, secreted by Th1 and antigen-presenting cells. IL-12, *in vivo*, has been shown to be able to prevent Th2-mediated immune responses and, sometimes, also to convert them into Th1 ones[1,18-20].

To date, the role that IL-5 can play in regulating the Th1/Th2 or humoral-cellular immunity balance is unknown; however, in the light of the different evidence observed with IL-4 inhibitory antibodies, it is possible to hypothesize that a similar link may also exist in the blockade of IL-5, although it must be recognized that different functions are attributable to IL-4 and IL-5 cytokines, both however involved in the first moments of activation of the Th2 axis[21].

Indeed, IL-5 is implicated in activating ASC differentiation and is a co-activator for B cell proliferation, enabling humoral immune responses mostly following the activation of Th2 cells[13], and there is evidence in rats and *in vitro* studies that IL-5 therapies can treat graft rejection phenomena by reversing autoimmune mechanisms based on Th1 and Th17 activation[22].

At the same time, we think that in our specific case, there was a similar conversion of the immune response from a predominantly antibody-based one, responsible for the patient's asthma, to one with a strong cell-mediated component, responsible for the patient's PPP.

## CONCLUSION

Nowadays, given the increasing use of IL inhibitory monoclonal antibodies in numerous pathologies, we should investigate with further attention the possible impact on the human immunological ecosystem put in place by the inhibition of the activity of individual inflammatory mediators, so as to be able to be increasingly aware of the manifestations of pathologies that could arise or be revealed by the treatment itself and therefore recognize the initial lesions early.

## FOOTNOTES

**Author contributions:** Artosi F and Diluvio L contributed to conceptualization; Campione E contributed to methodology; Artosi F and Diluvio L contributed to investigation; Artosi F, Diluvio L, and Vultaggio M contributed to data curation; Artosi F contributed to writing and original draft preparation; Diluvio L and Bianchi L contributed to writing review and editing.

**Informed consent statement:** Informed written consent was obtained from the patient for the publication of this report and any accompanying images.

**Conflict-of-interest statement:** The authors declare that they have no conflict of interest to disclose.

**CARE Checklist (2016) statement:** The authors have read the CARE Checklist (2016), and the manuscript was prepared and revised according to the CARE Checklist (2016).

**Open-Access:** This article is an open-access article that was selected by an in-house editor and fully peer-reviewed by external reviewers. It is distributed in accordance with the Creative Commons Attribution NonCommercial (CC BY-NC 4.0) license, which permits others to distribute, remix, adapt, build upon this work non-commercially, and license their derivative works on different terms, provided the original work is properly cited and the use is non-commercial. See: <https://creativecommons.org/licenses/by-nc/4.0/>

**Country/Territory of origin:** Italy

**ORCID number:** Fabio Artosi 0000-0002-7636-3532.

**S-Editor:** Chen YL

**L-Editor:** Wang TQ

**P-Editor:** Chen YL

## REFERENCES

- Biedermann T, Röcken M, Carballido JM. TH1 and TH2 lymphocyte development and regulation of TH cell-mediated immune responses of the skin. *J Invest Dermatol Symp Proc* 2004; **9**: 5-14 [PMID: 14870978 DOI: 10.1111/j.1087-0024.2004.00829.x]
- Dubin C, Del Duca E, Guttman-Yassky E. The IL-4, IL-13 and IL-31 pathways in atopic dermatitis. *Expert Rev Clin Immunol* 2021; **17**: 835-852 [PMID: 34106037 DOI: 10.1080/1744666X.2021.1940962]
- Peebles RS Jr, Aronica MA. Proinflammatory Pathways in the Pathogenesis of Asthma. *Clin Chest Med* 2019; **40**: 29-50 [PMID: 30691715 DOI: 10.1016/j.ccm.2018.10.014]
- Maurer M, Eyerich K, Eyerich S, Ferrer M, Guterthum J, Hartmann K, Jakob T, Kapp A, Kolkhir P, Larenas-Linnemann D, Park HS, Pejler G, Sánchez-Borges M, Schäkel K, Simon D, Simon HU, Weller K, Zuberbier T, Metz M. Urticaria: Collegium Internationale Allergologicum (CIA) Update 2020. *Int Arch Allergy Immunol* 2020; **181**: 321-333 [PMID: 32224621 DOI: 10.1159/000507218]
- Singh VK, Mehrotra S, Agarwal SS. The paradigm of Th1 and Th2 cytokines: its relevance to autoimmunity and allergy. *Immunol Res* 1999; **20**: 147-161 [PMID: 10580639 DOI: 10.1007/BF02786470]
- Zhou X, Chen Y, Cui L, Shi Y, Guo C. Advances in the pathogenesis of psoriasis: from keratinocyte perspective. *Cell Death Dis* 2022; **13**: 81 [PMID: 35075118 DOI: 10.1038/s41419-022-04523-3]
- Vecellio M, Hake VX, Davidson C, Carena MC, Wordsworth BP, Selmi C. The IL-17/IL-23 Axis and Its Genetic Contribution to Psoriatic Arthritis. *Front Immunol* 2020; **11**: 596086 [PMID: 33574815 DOI: 10.3389/fimmu.2020.596086]
- Timotijević ZS, Trajković G, Janković J, Relić M, Đorić D, Vukićević D, Relić G, Rašić D, Filipović M, Janković S. How frequently does palmoplantar psoriasis affect the palms and/or soles? A systematic review and meta-analysis. *Postepy Dermatol Alergol* 2019; **36**: 595-603 [PMID: 31839777 DOI: 10.5114/ada.2019.89508]
- Safa G, Paumier V. Psoriasis induced by dupilumab therapy. *Clin Exp Dermatol* 2019; **44**: e49-e50 [PMID: 30656722 DOI: 10.1111/ced.13901]
- Kim HS, Yeung J. Psoriasis appearing after dupilumab therapy in atopic dermatitis: A case report. *SAGE Open Med Case Rep* 2020; **8**: 2050313X20940458 [PMID: 32699634 DOI: 10.1177/2050313X20940458]
- Fowler E, Silverberg JI, Fox JD, Yosipovitch G. Psoriasiform Dermatitis After Initiation of Treatment with Dupilumab for Atopic Dermatitis. *Dermatitis* 2019; **30**: 234-236 [PMID: 31094943 DOI: 10.1097/DER.0000000000000481]
- Nagase H, Ueki S, Fujieda S. The roles of IL-5 and anti-IL-5 treatment in eosinophilic diseases: Asthma, eosinophilic granulomatosis with polyangiitis, and eosinophilic chronic rhinosinusitis. *Allergol Int* 2020; **69**: 178-186 [PMID: 32139163 DOI: 10.1016/j.alit.2020.02.002]
- Takatsu K, Nakajima H. IL-5 and eosinophilia. *Curr Opin Immunol* 2008; **20**: 288-294 [PMID: 18511250 DOI: 10.1016/j.coi.2008.04.001]
- Adabala SS, Doshi BR, Manjunathswamy BS. A Cross-Sectional Study to Assess the Role of Dermoscopy in Differentiating Palmar Psoriasis, Chronic Hand Eczema, and Eczema in Psoriatico. *Indian Dermatol Online J* 2022; **13**: 78-85 [PMID: 35198472 DOI: 10.4103/idoj.IDOJ\_782\_20]
- Röcken M, Racke M, Shevach EM. IL-4-induced immune deviation as antigen-specific therapy for inflammatory autoimmune disease. *Immunol Today* 1996; **17**: 225-231 [PMID: 8991384 DOI: 10.1016/0167-5699(96)80556-1]
- Ghoreschi K, Thomas P, Breit S, Dugas M, Mailhammer R, van Eden W, van der Zee R, Biedermann T, Prinz J, Mack M, Mrowietz U, Christophers E, Schlöndorff D, Plewig G, Sander CA, Röcken M. Interleukin-4 therapy of psoriasis induces Th2 responses and improves human autoimmune disease. *Nat Med* 2003; **9**: 40-46 [PMID: 12461524 DOI: 10.1038/nm804]
- Biedermann T, Röcken M. Th1/Th2 balance in atopy. *Springer Semin Immunopathol* 1999; **21**: 295-316 [PMID: 10666775 DOI: 10.1007/BF00812259]
- Bousquet J, Becker WM, Hejjiaoui A, Chanal I, Lebel B, Dhivert H, Michel FB. Differences in clinical and immunologic reactivity of patients allergic to grass pollens and to multiple-pollen species. II. Efficacy of a double-blind, placebo-controlled, specific immunotherapy with standardized extracts. *J Allergy Clin Immunol* 1991; **88**: 43-53 [PMID: 2071784 DOI: 10.1016/0091-6749(91)90299-4]
- Secrist H, Chelen CJ, Wen Y, Marshall JD, Umetsu DT. Allergen immunotherapy decreases interleukin 4 production in CD4+ T cells from allergic individuals. *J Exp Med* 1993; **178**: 2123-2130 [PMID: 7902409 DOI: 10.1084/jem.178.6.2123]
- Hamid QA, Schotman E, Jacobson MR, Walker SM, Durham SR. Increases in IL-12 messenger RNA+ cells accompany inhibition of allergen-induced late skin responses after successful grass pollen immunotherapy. *J Allergy Clin Immunol* 1997; **99**: 254-260 [PMID: 9042055 DOI: 10.1016/S0091-6749(97)70106-4]
- Larché M, Robinson DS, Kay AB. The role of T lymphocytes in the pathogenesis of asthma. *J Allergy Clin Immunol* 2003; **111**: 450-63; quiz 464 [PMID: 12642820 DOI: 10.1067/mai.2003.169]
- Hall BM, Hall RM, Tran GT, Robinson CM, Wilcox PL, Rakesh PK, Wang C, Sharland AF, Verma ND, Hodgkinson SJ. Interleukin-5 (IL-5) Therapy Prevents Allograft Rejection by Promoting CD4(+)CD25(+) Treg Regulatory Cells That Are Antigen-Specific and Express IL-5 Receptor. *Front Immunol* 2021; **12**: 714838 [PMID: 34912327 DOI: 10.3389/fimmu.2021.714838]



Published by **Baishideng Publishing Group Inc**  
7041 Koll Center Parkway, Suite 160, Pleasanton, CA 94566, USA

**Telephone:** +1-925-3991568

**E-mail:** [bpgoffice@wjgnet.com](mailto:bpgoffice@wjgnet.com)

**Help Desk:** <https://www.f6publishing.com/helpdesk>

<https://www.wjgnet.com>

