



Meatoplasty: A novel technique and minireview

Todd Kanzara, Jagdeep S Virk, Anthony O Owa

Todd Kanzara, Jagdeep S Virk, Anthony O Owa, ENT Department, Queen's Hospital, Barking, Havering and Redbridge University Hospitals NHS Trust, Romford, Essex RM7 0AZ, United Kingdom

Author contributions: Kanzara T performed the majority of the writing and literature search; Virk JS assisted with manuscript design, literature search and proof reading; Owa AO provided senior supervision.

Conflict-of-interest statement: Nothing to declare.

Open-Access: This article is an open-access article which was selected by an in-house editor and fully peer-reviewed by external reviewers. It is distributed in accordance with the Creative Commons Attribution Non Commercial (CC BY-NC 4.0) license, which permits others to distribute, remix, adapt, build upon this work non-commercially, and license their derivative works on different terms, provided the original work is properly cited and the use is non-commercial. See: <http://creativecommons.org/licenses/by-nc/4.0/>

Manuscript source: Invited manuscript

Correspondence to: Todd Kanzara, LLB (Hons) MRCS (ENT), ENT Department, Queen's Hospital, Barking, Havering and Redbridge University Hospitals NHS Trust, Rom Valley Way, Romford, Essex RM7 0AZ, United Kingdom. todd.kanzara@nhs.net
Telephone: +44-790-8960034
Fax: +44-208-8692964

Received: March 1, 2016
Peer-review started: March 1, 2016
First decision: April 15, 2016
Revised: May 12, 2016
Accepted: June 1, 2016
Article in press: June 3, 2016
Published online: August 28, 2016

Abstract

We describe a modified aural meatoplasty technique. The technique has been mainly used for mastoid surgery but it may also be used to address other causes of meatal

stenosis. It involves removing most of the cartilage in the conchal bowl and soft tissue in the external auditory meatus. Cartilage from the helical root may also be sacrificed as part of this procedure. Our technique produces an excellent cosmetic result and an adequate meatoplasty which is easy to monitor in the outpatient setting.

Key words: Meatoplasty; Cartilage; Reconstruction; Mastoid; Conchal bowl

© **The Author(s) 2016.** Published by Baishideng Publishing Group Inc. All rights reserved.

Core tip: A successful meatoplasty addresses the bony, soft tissue and cartilaginous portions of the external auditory meatus. At least one, if not all these factors, can contribute to external auditory canal stenosis. Cartilage from the helical root can be resected in order to create an adequate meatoplasty.

Kanzara T, Virk JS, Owa AO. Meatoplasty: A novel technique and minireview. *World J Otorhinolaryngol* 2016; 6(3): 50-53
Available from: URL: <http://www.wjgnet.com/2218-6247/full/v6/i3/50.htm> DOI: <http://dx.doi.org/10.5319/wjo.v6.i3.50>

INTRODUCTION

Creating an adequate meatoplasty is a critical step in allowing access and ventilation of the ear canal. Meatoplasty is often performed in conjunction with mastoid surgery. To create a successful meatoplasty, the surgeon considers the 3 main factors that contribute to meatal stenosis: (1) excess skin and soft tissue; (2) aberrations in the anatomy of the cartilage; or (3) the bony tympanic ring^[1]. A range of techniques and variations have been reported in the literature since the original descriptions in 1893 by Stacke and Schwartz^[2].

We present a technique developed at our centre by the senior author to ensure suitable meatoplasty size

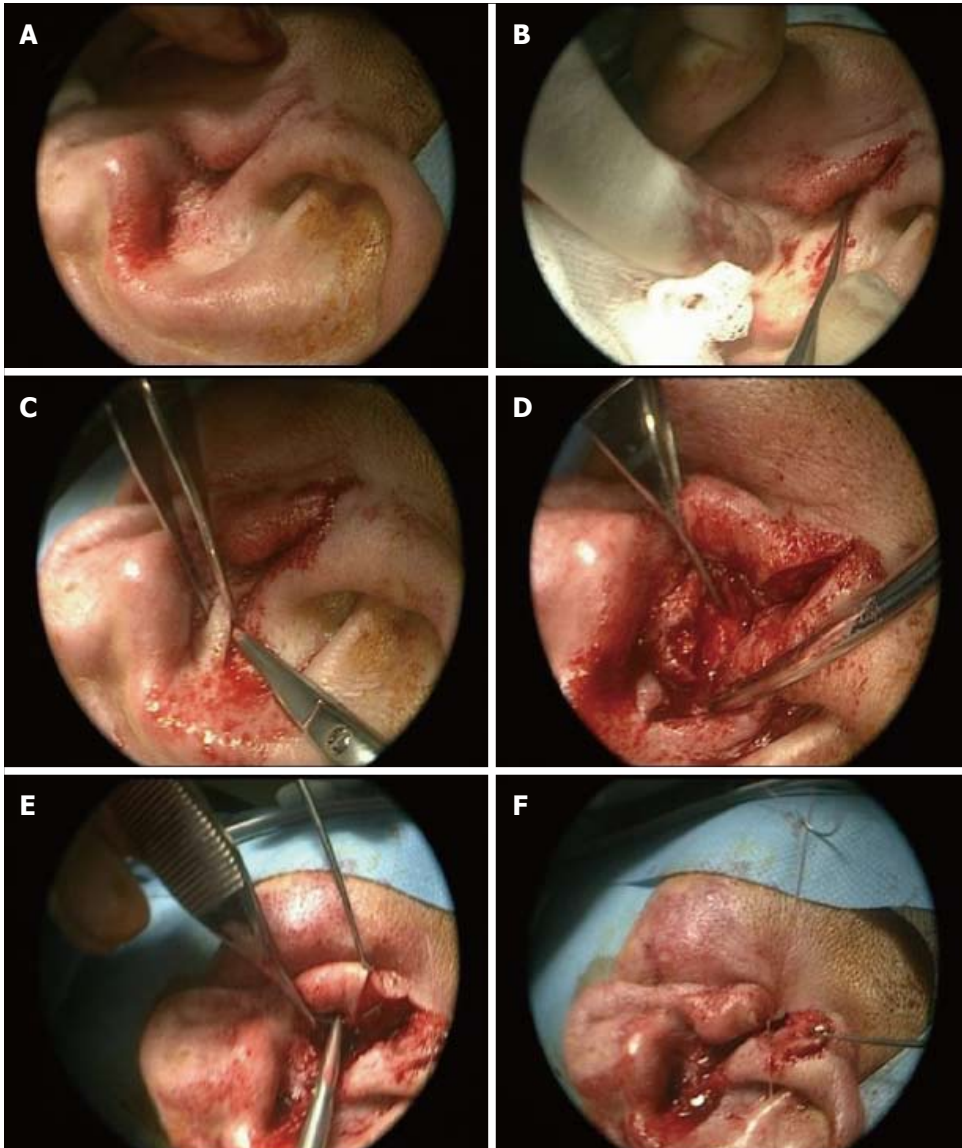


Figure 1 Meatoplasty technique. A: Endaural incision; B: Superiorly based conchal bowl incision; C: Conchal cartilage harvested; D: Excess skin and soft tissue resected; E: Closure of anterior endaural incision to prevent cartilage exposure; F: Closure of endaural incision, 154 mm × 183 mm (120 × 120 DPI).

whilst maintaining cosmesis, principally in conjunction with mastoid surgery.

OPERATIVE TECHNIQUE

The steps include performing an endaural incision to bone (Figure 1A), followed by a skin incision over the superior aspect of the conchal bowl/cartilage (Figure 1B). A large portion of conchal cartilage is then removed, which can be used as part of the reconstruction in tympanomastoid surgery (Figure 1C). To facilitate the meatoplasty redundant mucosa and soft tissue is excised medial to the skin incision. An important factor is removal of prominent cartilage, for example at the root of the helix. The resultant skin flap is rotated into the cavity such that the meatoplasty is widened. Following this, absorbable sutures are used to ensure the tragus remains anterosuperior, by suturing the anterior edge

of the endaural incision (Figure 1D). The free edge of conchal skin is opposed with absorbable suture (Figure 1E and F). An adequately sized meatoplasty should not require splinting by packing such as with bismuth iodoform paraffin paste (BIPP).

This technique for meatoplasty over the preceding two years has resulted in very good functional and cosmetic outcomes in all 54 patients (Figure 2). We have managed to achieve a dry, auto cleaning ear with very good cosmetic results in all cases. We have not had any cases of stenosis or troublesome granulation. Therefore, we propose our technique as a useful adaptation in performing meatoplasty.

DISCUSSION

There is an abundance of meatoplasty techniques in the literature reportedly producing very good results in

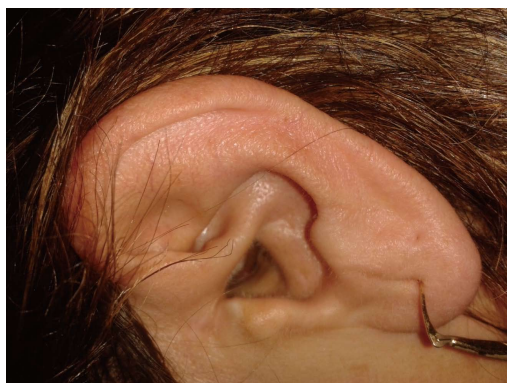

Figure 2 Post-operative result.

the respective author's hands. These techniques rely on creating a meatoplasty using a fibrocartilaginous posterior meatal flap in a post-auricular approach mastoidectomy, or partially resecting conchal bowl cartilage for the endaural approach^[3]. Traditional thinking with regards to meatoplasty surgery has tended to focus on creating a large meatoplasty thought to support optimal ventilation, reduce both bacterial and debris accumulation^[4-7]. However, the "big is better" approach is often associated with a few complications which include poor cosmesis and poor hearing aid fitting amongst other things^[8,9].

Two broad approaches have been reported with regards to widening the skin of the entrance of the external auditory meatus. The first approach, which in essence forms the basis of the Portman technique, uses radial incisions to create flaps arising from the outer ring of the external auditory meatus^[10]. Following the excision of underlying soft tissue, the flaps are then elevated onto the bony canal. The second approach, originally described by Korner and Siebenmann but reported by others, involves dividing the ring and rotating a skin flap to cover the defect^[1,11].

More recent techniques, similarly ours, have tended to favour the second approach involving rotational flaps. Osborne and Martin^[12] described rotating a superiorly placed pre-tragal flap into the endaural incision following removal of some conchal bowl cartilage. Hovis *et al.*^[13] described a "one cut meatoplasty" involving making a single horizontal incision from the posterosuperior meatus to the antihelix to create an inferiorly based triangular conchal flap. Martin-Hirsch and Smelt described a flap starting medial to the excess conchal mucosa and extending superiorly^[14]. Follow-up results of patients managed with this technique over a 9-year period have shown favourable results especially for the otitis externa group^[15]. Banerjee *et al.*^[16] reported using an inferiorly based transposition flap which potentially has poor cosmesis as its major demerit owing to the inferoposterior widening inherent in the technique^[1,14].

Other techniques which do not make use of skin flaps have been reported. Patil *et al.*^[1] describe a technique which involves the removal of a small triangle

of skin on the entrance of the external auditory canal in addition to conchal cartilage resection. Goodyear *et al.*^[17] described a helical advancement technique which involves resecting a cuff of skin anterior to the helix followed by releasing the helix anteriorly to cover the defect. The authors point out that whilst this approach produces inferior cosmesis it has the advantage of producing an auto-cleaning cavity which is easy to manage in the outpatient setting^[17].

In our experience of using this technique, we have not experienced any of the common complications associated with meatoplasty such as perichondritis, discharge or restenosis. Further, the patients operated on have not complained about poor cosmesis on follow-up.

CONCLUSION

We believe this previously undescribed methodology will provide an additional tool in the armamentarium of the otolaryngologist. Our modified approach demonstrated in this paper is reproducible and technically straightforward. It provides an adequate meatoplasty which promotes an auto cleaning ear that is easily accessible in clinic whilst producing an excellent cosmetic result.

REFERENCES

1. **Patil S**, Ahmed J, Patel N. Endaural meatoplasty: the Whipps Cross technique. *J Laryngol Otol* 2011; **125**: 78-81 [PMID: 20831850 DOI: 10.1017/S0022215110001842]
2. **Rouelleau P**. [Development of the surgery of chronic otitis]. *Rev Laryngol Otol Rhinol (Bord)* 1993; **114**: 87-91 [PMID: 8284561]
3. **Phillips WC**. The radical mastoid operation. In: Phillips WC, editor. *Diseases of the Ear, Nose and Throat Medical and Surgical*. Philadelphia: FA Davis, 1929: 311-343
4. **Jackson CG**, Glasscock ME, Nissen AJ, Schwaber MK, Bojrab DI. Open mastoid procedures: contemporary indications and surgical technique. *Laryngoscope* 1985; **95**: 1037-1043 [PMID: 4033324 DOI: 10.1288/00005537-198509000-00003]
5. **Nadol JB**. Revision mastoidectomy. *Otolaryngol Clin North Am* 2006; **39**: 723-740, vi-vii [PMID: 16895781 DOI: 10.1016/j.otc.2006.05.003]
6. **Sheehy JL**. Cholesteatoma surgery: canal wall down procedures. *Ann Otol Rhinol Laryngol* 1988; **97**: 30-35 [PMID: 3277524 DOI: 10.1177/000348948809700106]
7. **Pillsbury HC**, Carrasco VN. Revision mastoidectomy. *Arch Otolaryngol Head Neck Surg* 1990; **116**: 1019-1022 [PMID: 2200440 DOI: 10.1001/archotol.1990.01870090035002]
8. **Osborne JE**, Terry RM, Gandhi AG. Large meatoplasty technique for mastoid cavities. *Clin Otolaryngol Allied Sci* 1985; **10**: 357-360 [PMID: 3830482 DOI: 10.1111/j.1365-2273.1985.tb00269.x]
9. **Gluth MB**, Friedman AB, Atcherson SR, Dornhoffer JL. Hearing aid tolerance after revision and obliteration of canal wall down mastoidectomy cavities. *Otol Neurotol* 2013; **34**: 711-714 [PMID: 23640093 DOI: 10.1097/MAO.0b013e31828daeca]
10. **Portmann M**. "How I do it"--otology and neurotology. A specific issue and its solution. Meatoplasty and conchoplasty in cases of open technique. *Laryngoscope* 1983; **93**: 520-522 [PMID: 6834983]
11. **Wormald PJ**, van Hasselt CA. A technique of mastoidectomy and meatoplasty that minimizes factors associated with a discharging mastoid cavity. *Laryngoscope* 1999; **109**: 478-482 [PMID: 10089979 DOI: 10.1097/00005537-199903000-00025]
12. **Osborne JE**, Martin FW. Endaural meatoplasty for mastoid cavities. *Clin Otolaryngol Allied Sci* 1990; **15**: 453-455 [PMID: 2282710 DOI: 10.1017/S0022215110001842]

- 10.1111/j.1365-2273.1990.tb00500.x]
- 13 **Hovis KL**, Carlson ML, Sweeney AD, Haynes DS. The one-cut meatoplasty: novel surgical technique and outcomes. *Am J Otolaryngol* 2015; **36**: 130-135 [PMID: 25456511 DOI: 10.1016/j.amjoto.2014.10.002]
 - 14 **Martin-Hirsch DP**, Smelt GJ. Conchal flap meatoplasty. *J Laryngol Otol* 1993; **107**: 1029-1031 [PMID: 8288973 DOI: 10.1017/S0022215106003574]
 - 15 **Kumar PJ**, Smelt GJ. A long term follow up of conchal flap meatoplasty in chronic otitis externa. *J Laryngol Otol* 2007; **121**: 1-4 [PMID: 17059629]
 - 16 **Banerjee AR**, Moir AA, Jervis P, Narula AA. A canalplasty technique for the surgical treatment of chronic otitis externa. *Clin Otolaryngol Allied Sci* 1995; **20**: 150-152 [PMID: 7634522 DOI: 10.1111/j.1365-2273.1995.tb00033.x]
 - 17 **Goodyear PW**, Reddy CE, Lesser TH. Helix advancement meatoplasty. *J Laryngol Otol* 2012; **126**: 612-614 [PMID: 22643206 DOI: 10.1017/S0022215112000515]

P- Reviewer: Pan F, Vynios D **S- Editor:** Ji FF **L- Editor:** A
E- Editor: Lu YJ





Published by **Baishideng Publishing Group Inc**

8226 Regency Drive, Pleasanton, CA 94588, USA

Telephone: +1-925-223-8242

Fax: +1-925-223-8243

E-mail: bpgoffice@wjgnet.com

Help Desk: <http://www.wjgnet.com/esps/helpdesk.aspx>

<http://www.wjgnet.com>

