

World Journal of *Clinical Cases*

World J Clin Cases 2021 March 6; 9(7): 1499-1760



Contents

Thrice Monthly Volume 9 Number 7 March 6, 2021

REVIEW

- 1499 Review of the risk factors for SARS-CoV-2 transmission

Li X, Xia WY, Jiang F, Liu DY, Lei SQ, Xia ZY, Wu QP

MINIREVIEWS

- 1513 Regulation of the expression of proinflammatory cytokines induced by SARS-CoV-2

Zhang XN, Wu LJ, Kong X, Zheng BY, Zhang Z, He ZW

ORIGINAL ARTICLE

Case Control Study

- 1524 Efficacy and safety of short duration radiotherapy combined with chemotherapy for advanced rectal cancer

Gao SQ, Zhang YC, Zhang C, Wang SJ, Ren W, Yuan N, Wen JY

Retrospective Study

- 1532 Effects of transjugular intrahepatic portosystemic shunt using the Viatorr stent on hepatic reserve function in patients with cirrhosis

Yao X, Zhou H, Huang S, Tang SH, Qin JP

- 1543 Primary and secondary postoperative hemorrhage in pediatric tonsillectomy

Xu B, Jin HY, Wu K, Chen C, Li L, Zhang Y, Gu WZ, Chen C

- 1554 Dynamic monitoring of serum liver function indexes in patients with COVID-19

Lin H, Wu LJ, Guo SQ, Chen RL, Fan JR, Ke B, Pan ZQ

- 1563 Construction of a clinical survival prognostic model for middle-aged and elderly patients with stage III rectal adenocarcinoma

Liu H, Li Y, Qu YD, Zhao JJ, Zheng ZW, Jiao XL, Zhang J

- 1580 Short-term outcomes of radiofrequency ablation for hepatocellular carcinoma using cone-beam computed tomography for planning and image guidance

Yao XS, Yan D, Jiang XX, Li X, Zeng HY, Li H

- 1592 Intra-arterial thrombolysis for early hepatic artery thrombosis after liver transplantation

Li T, Sun XD, Yu Y, Lv GY

- 1600 Study on pathogenic genes of dwarfism disease by next-generation sequencing

Yang LL, Liang SS

- 1610** Effects of cooperative nursing and patient education on postoperative infection and self-efficacy in gastrointestinal tumors

Qiao L, Zeng SQ, Zhang N

Observational Study

- 1619** Elevated soluble 4-1BB is associated with serum markers of hepatitis B virus in patients with chronic hepatitis B

Zhan MR, Gao XZ, Wang C, Peng F, Wang XM, Xu HQ, Niu JQ

CASE REPORT

- 1631** Balloon-assisted endoscopic submucosal dissection for treating small intestinal lipomas: Report of two cases

Chen HY, Ning SB, Yin X, Li BR, Zhang J, Jin XW, Sun T, Xia ZB, Zhang XP

- 1639** Dysphagia in a patient with ankylosing spondylitis: A case report

Wang XW, Zhang WZ

- 1646** Autologous scalp skin grafting to treat toxic epidermal necrolysis in a patient with a large skin injury: A case report

Xue DD, Zhou L, Yang Y, Ma SY

- 1654** Epstein-Barr virus-positive diffuse large B-cell lymphoma with human immunodeficiency virus mimicking complicated frontal sinusitis: A case report

Yoon S, Ryu KH, Baek HJ, An HJ, Joo YH

- 1661** Multiple well-differentiated retroperitoneal liposarcomas with different patterns of appearance on computed tomography: A case report

Xie TH, Ren XX, Fu Y, Ha SN, Liu LT, Jin XS

- 1668** Sarcomatoid carcinoma of the prostate with bladder invasion shortly after androgen deprivation: Two case reports

Wei W, Li QG, Long X, Hu GH, He HJ, Huang YB, Yi XL

- 1676** Metastatic thymic-enteric adenocarcinoma responding to chemoradiation plus anti-angiogenic therapy: A case report

Li M, Pu XY, Dong LH, Chang PY

- 1682** Solid pseudopapillary neoplasm-diagnostic approach and post-surgical follow up: Three case reports and review of literature

Abudalou M, Vega EA, Dhingra R, Holzwanger E, Krishnan S, Kondratiev S, Niakosari A, Conrad C, Stallwood CG

- 1696** Vancomycin-induced thrombocytopenia in endocarditis: A case report and review of literature

Guleng SR, Wu RH, Guo XB

- 1705** Human menstrual blood-derived stem cells as immunoregulatory therapy in COVID-19: A case report and review of the literature

Lu J, Xie ZY, Zhu DH, Li LJ

- 1714** Pure transvaginal natural orifice transluminal endoscopic surgery right hemicolectomy for colon cancer: A case report
Song ZJ, Shi YQ, Jiang YM, Liu K, Li Y, Wang CG, Zhao R
- 1720** Hyperglycemic hemianopia: A case report
Xiang XH, Fang JJ, Yang M, Zhao GH
- 1728** Mucinous appendiceal neoplasm: A case report
Chirca A, Negreanu L, Iliesiu A, Costea R
- 1734** Reconstructing abdominal wall defects with a free composite tissue flap: A case report
Wang J
- 1741** Mononeuropathy multiplex associated with systemic vasculitis: A case report
Chae HJ, Kim JW, Lee YL, Park JH, Lee SY
- 1748** Congenital fiber-type disproportion presenting with type II respiratory failure after delivery: A case report
Yang HM, Guo JX, Yang YM
- 1755** Use of three dimensional-printing in the management of floating aortic thrombus due to occult aortic dissection: A case report
Wang TH, Zhao JC, Xiong F, Yang Y

ABOUT COVER

Chin-Hsiao Tseng, MD, PhD, Full Professor, Department of Internal Medicine, National Taiwan University College of Medicine, No. 1 Jen Ai Road Section 1, Taipei 100, Taiwan. cckts@ms6.hinet.net

AIMS AND SCOPE

The primary aim of *World Journal of Clinical Cases* (WJCC, *World J Clin Cases*) is to provide scholars and readers from various fields of clinical medicine with a platform to publish high-quality clinical research articles and communicate their research findings online.

WJCC mainly publishes articles reporting research results and findings obtained in the field of clinical medicine and covering a wide range of topics, including case control studies, retrospective cohort studies, retrospective studies, clinical trials studies, observational studies, prospective studies, randomized controlled trials, randomized clinical trials, systematic reviews, meta-analysis, and case reports.

INDEXING/ABSTRACTING

The WJCC is now indexed in Science Citation Index Expanded (also known as SciSearch®), Journal Citation Reports/Science Edition, Scopus, PubMed, and PubMed Central. The 2020 Edition of Journal Citation Reports® cites the 2019 impact factor (IF) for WJCC as 1.013; IF without journal self cites: 0.991; Ranking: 120 among 165 journals in medicine, general and internal; and Quartile category: Q3. The WJCC's CiteScore for 2019 is 0.3 and Scopus CiteScore rank 2019: General Medicine is 394/529.

RESPONSIBLE EDITORS FOR THIS ISSUE

Production Editor: Yan-Xia Xing; **Production Department Director:** Yun-Xiaoqian Wu; **Editorial Office Director:** Jin-Li Wang.

NAME OF JOURNAL

World Journal of Clinical Cases

ISSN

ISSN 2307-8960 (online)

LAUNCH DATE

April 16, 2013

FREQUENCY

Thrice Monthly

EDITORS-IN-CHIEF

Dennis A Bloomfield, Sandro Vento, Bao-Gan Peng

EDITORIAL BOARD MEMBERS

<https://www.wjgnet.com/2307-8960/editorialboard.htm>

PUBLICATION DATE

March 6, 2021

COPYRIGHT

© 2021 Baishideng Publishing Group Inc

INSTRUCTIONS TO AUTHORS

<https://www.wjgnet.com/bpg/gerinfo/204>

GUIDELINES FOR ETHICS DOCUMENTS

<https://www.wjgnet.com/bpg/GerInfo/287>

GUIDELINES FOR NON-NATIVE SPEAKERS OF ENGLISH

<https://www.wjgnet.com/bpg/gerinfo/240>

PUBLICATION ETHICS

<https://www.wjgnet.com/bpg/GerInfo/288>

PUBLICATION MISCONDUCT

<https://www.wjgnet.com/bpg/gerinfo/208>

ARTICLE PROCESSING CHARGE

<https://www.wjgnet.com/bpg/gerinfo/242>

STEPS FOR SUBMITTING MANUSCRIPTS

<https://www.wjgnet.com/bpg/GerInfo/239>

ONLINE SUBMISSION

<https://www.f6publishing.com>



Hyperglycemic hemianopia: A case report

Xiao-Hui Xiang, Jia-Jia Fang, Mi Yang, Guo-Hua Zhao

ORCID number: Xiao-Hui Xiang 0000-0003-4565-8722; Jia-Jia Fang 0000-0002-8549-8009; Mi Yang 0000-0003-3920-8979; Guo-Hua Zhao 0000-0001-7943-209X.

Author contributions: Xiang XH drafted the manuscript for intellectual content; Yang M collected the clinical data; Fang JJ and Zhao GH revised the manuscript for intellectual content; all authors read and approved the final manuscript.

Supported by The fund of Department of Education Zhejiang Province Scientific Research Project, No. Y201839721; Zhejiang Province Medical Science and Technology Project, No. 2017174708, No. 2020RC061, and No. 2018273034; the Zhejiang Provincial Natural Scientific Foundation of China, No. LGF20H090011 and No. LY18H090002; Zhejiang public welfare Technology Application Research Project, No. LGF20H090011; and the Medical and Health Science and Technology Program of Zhejiang Province, No. 2018273034.

Informed consent statement: Written informed consent was obtained from each participant for publication of this case report.

Conflict-of-interest statement: The authors declare that they have no competing interests.

Xiao-Hui Xiang, Jia-Jia Fang, Mi Yang, Guo-Hua Zhao, Department of Neurology, The Fourth Affiliated Hospital, Zhejiang University School of Medicine, Yiwu 322000, Zhejiang Province, China

Corresponding author: Guo-Hua Zhao, MD, Doctor, Department of Neurology, The Fourth Affiliated Hospital, Zhejiang University School of Medicine, No. N1 Shangcheng Avenue, Yiwu 322000, Zhejiang Province, China. gzhao@zju.edu.cn

Abstract

BACKGROUND

Nonketotic hyperglycemia (NKH) is characterized by hyperglycemia with little or no ketoacidosis. Diverse neurological symptoms have been described in NKH patients, including choreoathetosis, hemiballismus, seizures, and coma in severe cases. Homonymous hemianopia, with or without occipital seizures, caused by hyperglycemia is less readily recognized.

CASE SUMMARY

We describe a 54-year-old man with NKH, who reported seeing round, colored flickering lights with right homonymous hemianopia. Cranial magnetic resonance imaging demonstrated abnormalities in the left occipital lobe, with decreased T2 signal of the white matter, restricted diffusion, and corresponding low signal intensity in the apparent diffusion coefficient map. He responded to rehydration and a low-dose insulin regimen, with improvements of his visual field defect.

CONCLUSION

Patients with NKH may present focal neurologic signs. Hyperglycemia should be taken into consideration when making an etiologic diagnosis of homonymous hemianopia.

Key Words: Nonketotic hyperglycemia; Homonymous hemianopia; Occipital seizures; Imaging manifestations; Case report

©The Author(s) 2021. Published by Baishideng Publishing Group Inc. All rights reserved.

Core Tip: Nonketotic hyperglycemia is one of the most common endocrine emergencies. Patients with nonketotic hyperglycemia may present with various neurologic symptoms. We report a case of homonymous hemianopia with occipital seizures caused by hyperglycemia. Aggressive glycemic control and adequate

CARE Checklist (2016) statement:

The guidelines of the “CARE Checklist – 2016: Information for writing a case report” have been adopted.

Open-Access: This article is an open-access article that was selected by an in-house editor and fully peer-reviewed by external reviewers. It is distributed in accordance with the Creative Commons Attribution NonCommercial (CC BY-NC 4.0) license, which permits others to distribute, remix, adapt, build upon this work non-commercially, and license their derivative works on different terms, provided the original work is properly cited and the use is non-commercial. See: <http://creativecommons.org/licenses/by-nc/4.0/>

Manuscript source: Unsolicited manuscript

Specialty type: Medicine, research and experimental

Country/Territory of origin: China

Peer-review report's scientific quality classification

Grade A (Excellent): 0
Grade B (Very good): B
Grade C (Good): C
Grade D (Fair): 0
Grade E (Poor): 0

Received: November 14, 2020

Peer-review started: November 14, 2020

First decision: November 24, 2020

Revised: December 6, 2020

Accepted: December 16, 2020

Article in press: December 16, 2020

Published online: March 6, 2021

P-Reviewer: Ferreira GSA

S-Editor: Zhang L

L-Editor: Webster JR

P-Editor: Liu JH



hydration can reverse neurologic deficits. Subcortical T2 and fluid-attenuated inversion recovery hypointensity on resonance imaging were identified as characteristics.

Citation: Xiang XH, Fang JJ, Yang M, Zhao GH. Hyperglycemic hemianopia: A case report. *World J Clin Cases* 2021; 9(7): 1720-1727

URL: <https://www.wjgnet.com/2307-8960/full/v9/i7/1720.htm>

DOI: <https://dx.doi.org/10.12998/wjcc.v9.i7.1720>

INTRODUCTION

Nonketotic hyperglycemia (NKH) is a clinical syndrome consisting of hyperglycemia, hyperosmolality and intracellular dehydration with little or no ketoacidosis^[1]. In such cases, the level of insulin is sufficient to inhibit free fatty acid mobilization, but fails to support transmembrane transport of adequate glucose into cells. Diverse neurological symptoms have been described in NKH patients, including choreoathetosis, hemiballismus, seizures, somatosensory symptoms, headache, nausea and vomiting, and coma in severe cases^[2-5]. Seizures occur in 15%-40% of patients with NKH, and the majority are focal motor seizures and epilepsy partialis continua^[6,7]. Homonymous hemianopia, with or without occipital seizures, caused by hyperglycemia is less readily recognized. Here, we report a case of homonymous hemianopia and visual hallucination associated with NKH, in addition to a review of the related literature.

CASE PRESENTATION

Chief complaints

A 54-year-old man presented to the neurologic clinic of The Fourth Affiliated Hospital Zhejiang University School of Medicine, after episodes of seeing round, colored flickering lights, and reporting that he “can't see things in his right visual field” 7 d before admission.

History of present illness

One week prior to admission, the patient saw paroxysmal green and red flickering lights in his right visual field. He then experienced blurred vision in his right visual field. He visited a local ophthalmic clinic several days before coming to our hospital, and a visual field examination showed a right homonymous hemianopia (Figure 1). His visual field defect improved partially without treatment. The paroxysmal flickering lights lasted for about 3 d before remission, but there was no further improvement in his hemianopia.

History of past illness

The patient was otherwise healthy. He denied a history of hypertension, diabetes mellitus (DM), prior cerebrovascular disease or other neurological complications.

Personal and family history

The patient was a journalist with a height of 178 cm and weight of 76 kg. He had no history of drug use, drinking, smoking, or bad sexual life. One of his four siblings had DM, and there was no family history of stroke, epilepsy, or other neurological diseases.

Physical examination

His general examination was unremarkable. Neurologic examination revealed right homonymous hemianopia with normal pupillary reactivity. No other positive neurologic signs were found.

Laboratory examinations

His blood glucose was 645 mg/dL (35.83 mmol/L) without ketoacidosis, although his urine ketone test was weakly positive. Serum osmolality was 297.09 mOsmol/L (range: 280-310 mOsmol/L), with serum sodium 126.42 mmol/L (range: 137-142 mmol/L), and serum potassium 4.21 mmol/L (range: 3.50-5.30 mmol/L). HbA1c was

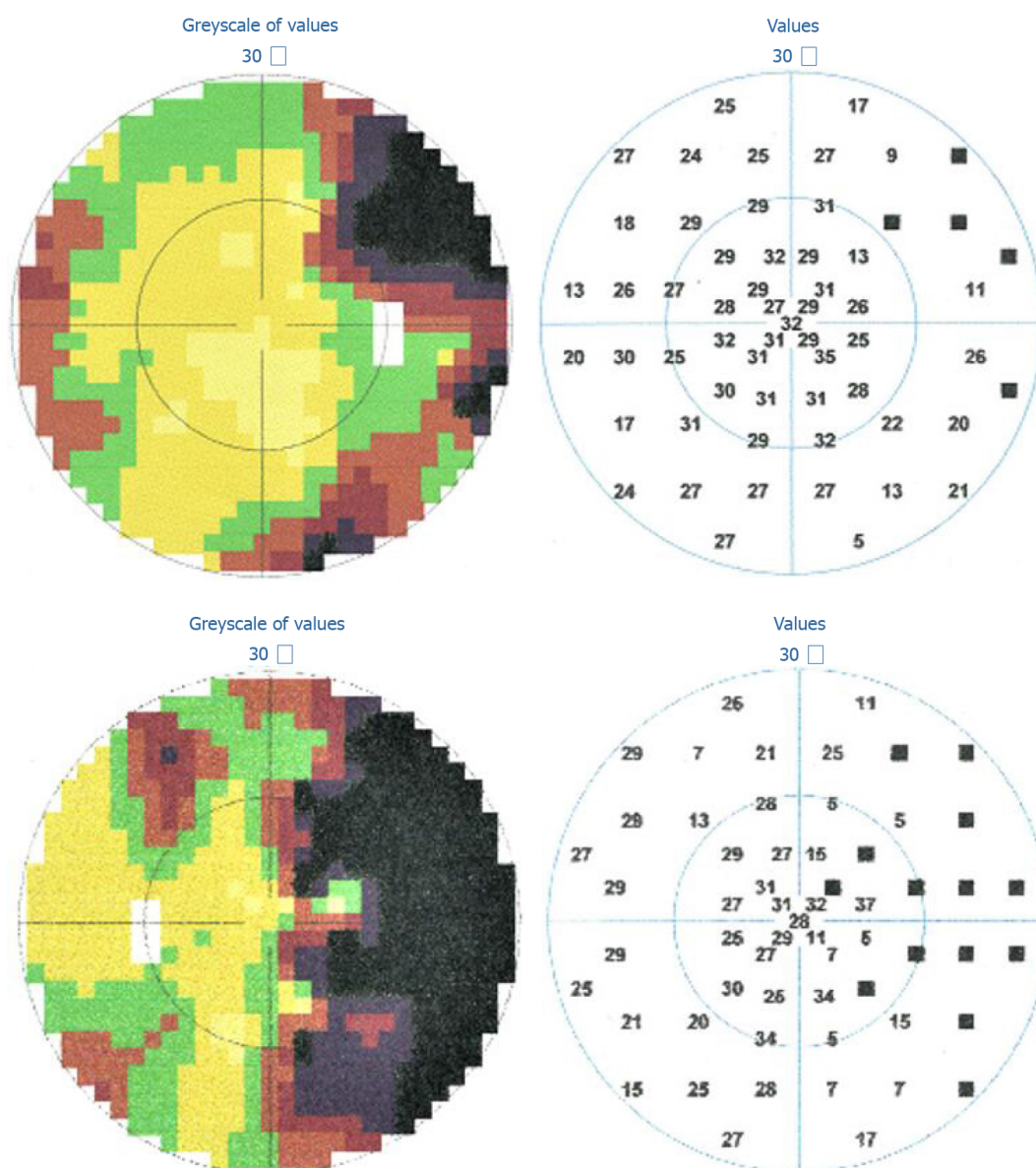


Figure 1 Visual field over the central 30 degrees showed a right homonymous hemianopia.

14.4% (range: 3.6%-6.0%). Other laboratory tests were unremarkable.

Imaging examinations

Cranial magnetic resonance imaging (MRI) showed abnormalities in the left occipital lobe with decreased T2 and fluid-attenuated inversion recovery (FLAIR) signals in the white matter, restricted diffusion, and corresponding low signal intensity in the apparent diffusion coefficient map (Figure 2). Magnetic resonance angiography imaging of the brain showed a mild stenosis of the right posterior cerebral artery, with arterial spin labeling showing decreased perfusion of the lesion (Figure 3). The patient's electroencephalogram (EEG) was mildly abnormal, showing slowing activities without spikes and sharp waves.

FINAL DIAGNOSIS

Hyperglycemic hemianopia was suspected based on the patient's symptoms, disease course, laboratory tests and cranial MRI.

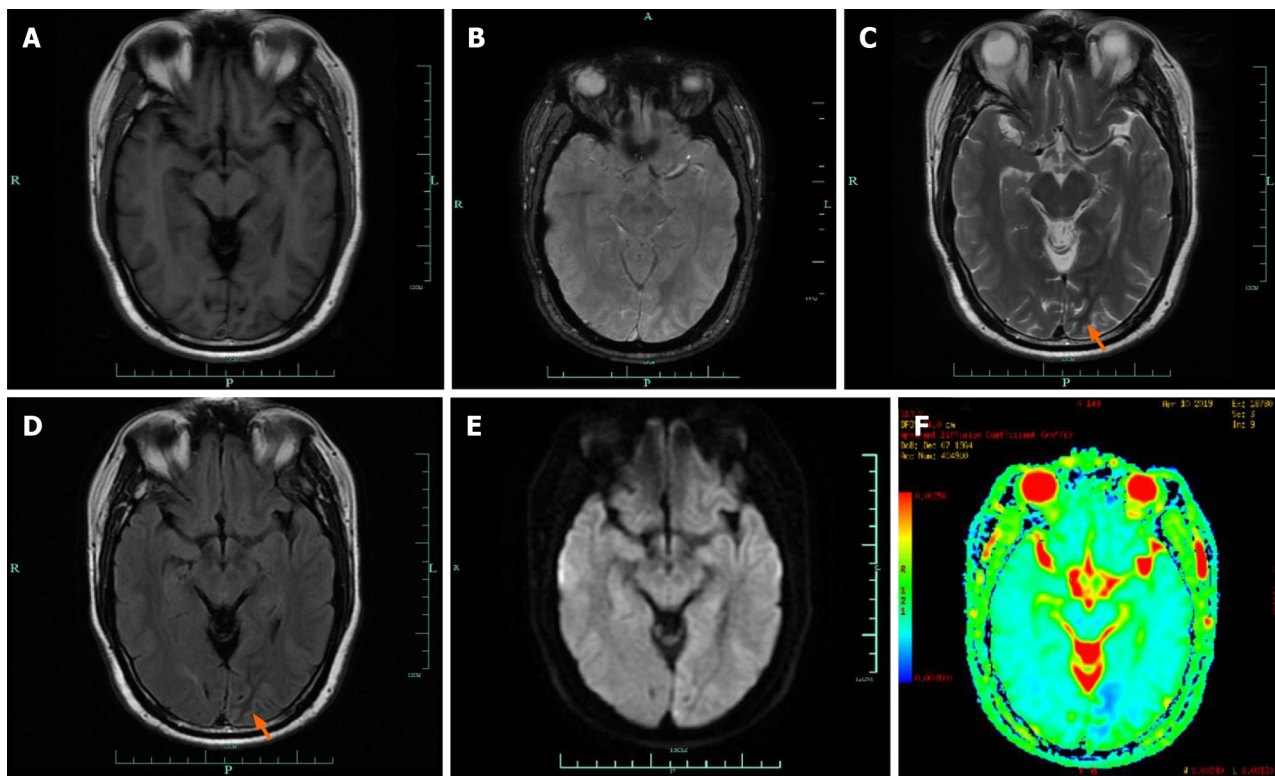


Figure 2 Magnetic resonance imaging showed low signal intensity in the apparent diffusion coefficient map. A: Magnetic resonance imaging of the brain demonstrating isointensity on T1 sequence; B: Susceptibility weighted imaging; C: Left occipital subcortical T2; D: Fluid-attenuated inversion recovery hypointensity (orange arrow); E: Restricted diffusion; and F: Low signal intensity of the ADC map.

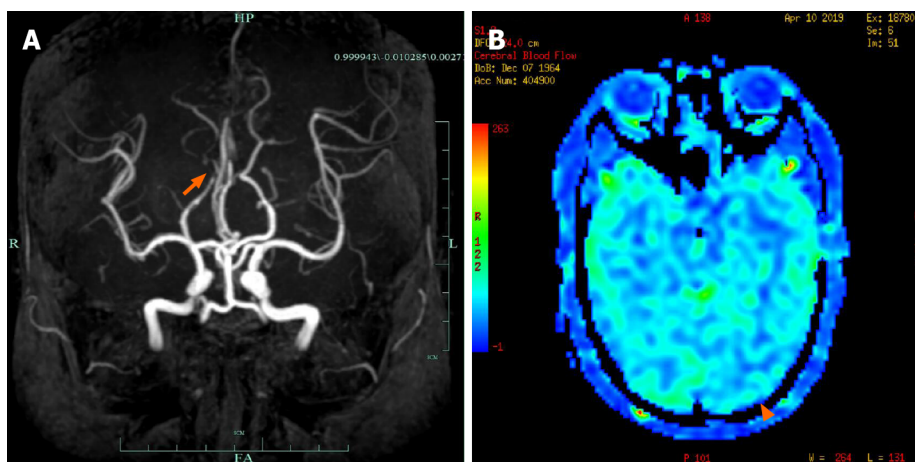


Figure 3 Magnetic resonance angiography imaging of the brain showed a mild stenosis. A: Magnetic resonance angiography demonstrating mild stenosis of the right posterior cerebral artery (orange arrow); and B: Arterial spin labeling showing decreased perfusion of the lesion (arrowhead).

TREATMENT

He responded to rehydration and low dose insulin without antiepileptic drugs (AEDs).

OUTCOME AND FOLLOW-UP

The patient remained in our hospital for two weeks, and his homonymous hemianopia was gradually relieved. The patient was discharged with tapering of the dose of insulin, which was finally replaced by dietary control.

DISCUSSION

In this study, we describe the case of a 54-year-old man with NKH combined with visual seizures and right homonymous hemianopia. Cranial MRI demonstrated abnormalities in the left occipital lobe, with decreased T2 signals in the white matter. He had good response to rehydration and a low-dose insulin regimen.

A search of the English language literature in the MEDLINE database (<https://www.ncbi.nlm.nih.gov>) yielded descriptions of 27 patients with NKH who satisfied the following criteria: (1) Patients had homonymous visual field defects with or without occipital epileptic seizures; and (2) Patients demonstrated neurologic symptoms that were not caused by comorbid neurologic disorders. Patients who presented with occipital seizures but no visual field defects were excluded from our review. As described in detail in our discussion, the neurologic symptoms, ophthalmologic complications and radiographic features of these patients are identical. **Table 1** summarizes the clinical, laboratory, and radiographic features of all 27 patients^[5,8-25] presenting with homonymous hemianopia, in addition to the data for the patient reported here.

Our patient did not have any symptoms of DM before admission. Previously known DM was reported in only 55.6% of the cohort of reviewed patients, indicating that visual field defects could be the first manifestation of hyperglycemia. Therefore, NKH should be considered as one of the causes of homonymous hemianopia, especially for patients without obvious cerebral vascular stenosis.

Our patient had homonymous hemianopia combined with typical visual seizures although his EEG was only mildly abnormal. In the 27 cases reviewed in the literature, most (85.2%) patients reported visual hallucinations, such as colored spots, flashing lights and fairly complex visions. Some patients also had concomitant focal motor seizures^[13-17,20,23,24], complex partial seizures^[15,25], generalized seizures^[13,20,25], nystagmus^[13,14,23-25], mental status changes^[13,16,24], and even deep stupor^[5]. Thus, although visual seizure is common in NKH patients with homonymous hemianopia, this symptom is often overlooked.

Our patient showed typical decreased T2 and FLAIR signals in the white matter, which was consistent with the findings in the 27 patients reviewed. Brain MRI scanning in 22 of these patients revealed occipital lesions in 77.3%, of which 63.6% were characterized by focal decreased T2 and FLAIR signals of the white matter. This characteristic differs from the MRI abnormalities of T2 and FLAIR hyperintensity involving gray or white matter observed in patients with status epilepticus^[26]. The etiology underlying T2 and FLAIR hypointensity remains unclear. Generally, T2 hypointensity results from the paramagnetic effect of free radicals or metals, such as iron^[27]. Excessive free radicals or iron accumulation within vulnerable white matter regions may have occurred in the hyperglycemic state. T2 and FLAIR hyperintensity across the cortex, gyral swelling or increased cortical thickness were also reported^[13-15,20-23]. Restricted diffusion was reported in 36.4% of the cohort patients^[13,19,21,23]. Most of the brain MRIs were reported to have normal non-contrast T1 images. Gadolinium-enhanced sequences were obtained in eight patients. Focal cortical contrast enhancement of the overlying cortex was observed in three patients^[13,15,21], and one showed subtle gadolinium enhancement of the right hippocampus^[23]. One patient showed leptomeningeal enhancement along the left parieto-occipital region^[24]. The MRI images of the three remaining patients were normal with contrast^[12,15,17]. Magnetic resonance angiography results in three patients demonstrated no vascular changes^[12,14,17], thus reinforcing the inconsistency between the symptoms and an ischemic etiology. For most of the patients, repeated MRI showed no residual abnormalities during follow-up, with subcortical hypointensity and enhancement resolved^[11,13-15,19,22-24], although a white matter volume loss was also described^[15,18]. These transient changes suggest a reversible pathology.

Three patients with magnetic resonance spectroscopy (MRS) scanning were reported, two of which showed decreased N-acetyl aspartate over the symptomatic occipital lobe^[14,21], suggesting reduced vital neuronal tissue. Guez *et al*^[19] reported the MRS pattern of a patient with a right occipital lesion, showing a significant increase in cerebral metabolites, although the MRS abnormalities improved after 3 wk^[19].

¹⁸F-fluorodeoxyglucose positron emission tomography was performed in two patients, showing occipital and temporal hypermetabolism on the lesion side^[23]. Tc-99m hexamethylpropylene amine oxime single-photon emission computed tomography (SPECT) was also carried out in some cases. Wang *et al*^[14] found left occipital perfusion increased during status epilepticus arising from the left occipital lobe, but slightly reduced compared with the right side 6 mo later^[14]. Hung *et al*^[20] reported a patient with partial left homonymous hemianopia who underwent SPECT

Table 1 Clinical, laboratory, radiographic and electroencephalogram features

	All patients (n = 27)	Our patient
Female-male ratio	1:2	-
Age at onset, yr, mean (± SD)	56 (± 14)	54
Range	28-83	-
Patients with previous known diabetes mellitus, %	55.6	No
Visual hallucination, %	85.2	Yes
Headache, %	44.4	No
Blood glucose, mg/dL, mean (± SD) (26/27 patients, one patient's blood glucose was recorded ≥ 1000)	468 (± 159)	645
Plasma osmotic pressure, mOsm/L, mean (± SD) (reported for 22/27 patients)	312 (± 24)	302.8
Brain MRI (reported for 22/27 patients)		
Normal, %	18.2	No
Occipital lobe lesion, %	77.3	Yes
Decreased T2 signal of the white matter, %	63.6	Yes
Gyrus hyperintensity, %	31.8	No
Gyrus swelling or increasing thickness over the cortex, %	27.3	No
Restricted diffusion, %	36.4	Yes
EEG (reported for 25/27 of patients)		
Normal, %	4	No
Slowing activity without epileptiform discharges, %	20	Yes
Epileptiform discharges, %	76	No
Patients with visual field returned to normal (reported for 25/27 of patients), %	96	Yes
Patients seizure-free, %	100	Yes

MRI: Magnetic resonance imaging; EEG: Electroencephalogram.

showing hyperperfusion in the right occipital lobe on hospital day 5, although visual disturbances were recovered by hospital day 7^[20]. Del Felice *et al*^[17] described a 50-year-old woman with a right homonymous hemianopia, with SPECT showing a non-significant hypocaptation over the posterior regions bilaterally during which no clinical seizure was reported^[17]. This patient also underwent continuous EEG-functional MRI monitoring, which showed a significant focal blood oxygenation level dependent activation in a single area related to the paroxysmal activity observed in the EEG. This area was identified in Brodmann area 18 (visual associations area), and a blood oxygenation level dependent occipital activation indicated a specific increase in metabolic demand^[28].

EEGs were performed in 25 cases, and epileptiform activities were recorded in 76% of these patients. Spikes, sharp waves, spike and wave discharge, decreased voltage and slow activities originating mainly from the affected posterior brain regions were described. In addition, seizures characterized by fast activities over the occipital regions with a frequency between 15 and 16 Hz were also reported^[16]. Occipital lesions appeared to be epileptogenic, consistent with visual hallucination. Among 10 patients followed up by EEG, 80% of the patients' results returned to normal; however, attenuation of the posterior dominant rhythm was described^[23]. Cerebral spinal fluid studies were carried out in 7 cases without significant abnormalities.

The main treatment for patients with hyperglycemic hemianopia is good glycemic control with insulin and rehydration. The inclusion of acute AEDs is not well established, as seizures resolved without AEDs in some cases^[5,8,9,12,13,15,16,19,22]. We did not prescribe AEDs for our patient, as his visual hallucination disappeared spontaneously. However, NKH-associated seizures can be refractory and resistant to AEDs^[14,17,19,23]. Reversal of neurologic symptoms probably depends on correction of the underlying hyperglycemia^[23]. Phenytoin should be avoided as it can exacerbate hyperglycemia by reducing insulin secretion^[4]. The prognosis of occipital seizure is good. Seizures

subsided and ceased in our patient and in all 27 patients in the literature review cohort. EEG recovery was reported in most cases without requirement for long-term antiepileptic therapy. Similarly, the normal visual field returned in our patient and the majority of the cohort patients. Homonymous hemianopia lasted days to months before remission.

Patients with homonymous hemianopia usually have associated lesions of the visual pathway posterior to the optic chiasm. Some patients are simply diagnosed with cerebral vascular accidents accompanied with uncontrolled diabetes. However, the reversibility of the neurological symptoms, signs, MRI and EEG abnormalities, points to a direct relationship between hyperglycemia and the disorder. All these transient changes favor an epileptic rather than an ischemic cause. Homonymous hemianopia may actually represent a postictal phenomenon similar to Todd's paralysis.

The pathophysiologic mechanism of homonymous hemianopia related to NKH remains controversial. Hyperglycemia sets up an osmotic gradient between the extracellular and intracellular compartments of the brain, leading to intracellular dehydration and dysfunction^[5]. However, the precise relationship between osmolality and seizure is unclear. In another hypothesis, depression of the Krebs cycle, resulting in enhancement of alternative pathways of energy metabolism including conversion of γ -aminobutyric acid (GABA) to succinic acid *via* the succinic semialdehyde pathway (GABA shunt). The GABA shunt supplies approximately 40% of the brain energy requirements^[4] and the resultant decrease in GABA precipitates seizures^[10].

CONCLUSION

In this study, we propose the association of homonymous hemianopia with NKH. We identified subcortical T2 and FLAIR hypointensity rather than hyperintensity as a characteristic feature of homonymous hemianopia associated with NKH. Prompt recognition of the underlying metabolic disturbance is important so that appropriate treatment can be initiated. Aggressive glycemic control and adequate hydration are crucial, as reversal of neurologic deficits depends primarily on the correction of hyperglycemia. NKH-associated seizures may be refractory in the acute phase, although long-term use of AEDs is not required.

ACKNOWLEDGEMENTS

We are thankful to the patient who agreed to participate in this study.

REFERENCES

- 1 **Bacanu G**, Anghelescu L, Mihailov E, Wilkomm I. [Hyperosmolar Diabetic Coma without Acidoketosis]. *Med Interna (Bucur)* 1965; **17**: 353-359 [PMID: [14325530](#)]
- 2 **Chung SJ**, Lee JH, Lee SA, No YJ, Im JH, Lee MC. Co-occurrence of seizure and chorea in a patient with nonketotic hyperglycemia. *Eur Neurol* 2005; **54**: 230-232 [PMID: [16401900](#) DOI: [10.1159/000090717](#)]
- 3 **Singh BM**, Strobos RJ. Epilepsia partialis continua associated with nonketotic hyperglycemia: clinical and biochemical profile of 21 patients. *Ann Neurol* 1980; **8**: 155-160 [PMID: [6775582](#) DOI: [10.1002/ana.410080205](#)]
- 4 **Guisado R**, Arieff AI. Neurologic manifestations of diabetic comas: correlation with biochemical alterations in the brain. *Metabolism* 1975; **24**: 665-679 [PMID: [805337](#) DOI: [10.1016/0026-0495\(75\)90146-8](#)]
- 5 **Maccario M**. Neurological dysfunction associated with nonketotic hyperglycemia. *Arch Neurol* 1968; **19**: 525-534 [PMID: [5684300](#) DOI: [10.1001/archneur.1968.00480050095009](#)]
- 6 **Maccario M**, Messis CP, Vastola EF. Focal seizures as a manifestation of hyperglycemia without ketoacidosis. A report of seven cases with review of the literature. *Neurology* 1965; **15**: 195-206 [PMID: [14262318](#) DOI: [10.1212/wnl.15.3.195](#)]
- 7 **Cochin JP**, Hannequin D, Delangre T, Guegan-Massardier E, Augustin P. [Continuous partial epilepsy disclosing diabetes mellitus]. *Rev Neurol (Paris)* 1994; **150**: 239-241 [PMID: [7863172](#)]
- 8 **Johnson SF**, Loge RV. Palinopsia due to nonketotic hyperglycemia. *West J Med* 1988; **148**: 331-332 [PMID: [3363966](#)]
- 9 **Duncan MB**, Jabbari B, Rosenberg ML. Gaze-evoked visual seizures in nonketotic hyperglycemia. *Epilepsia* 1991; **32**: 221-224 [PMID: [2004626](#) DOI: [10.1111/j.1528-1157.1991.tb05248.x](#)]
- 10 **Harden CL**, Rosenbaum DH, Daras M. Hyperglycemia presenting with occipital seizures. *Epilepsia*

- 1991; **32**: 215-220 [PMID: [2004625](#) DOI: [10.1111/j.1528-1157.1991.tb05247.x](#)]
- 11 **Seo DW**, Na DG, Na DL, Moon SY, Hong SB. Subcortical hypointensity in partial status epilepticus associated with nonketotic hyperglycemia. *J Neuroimaging* 2003; **13**: 259-263 [PMID: [12889174](#)]
- 12 **Freedman KA**, Polepalle S. Transient homonymous hemianopia and positive visual phenomena in nonketotic hyperglycemic patients. *Am J Ophthalmol* 2004; **137**: 1122-1124 [PMID: [15183801](#) DOI: [10.1016/j.ajo.2003.11.067](#)]
- 13 **Lavin PJ**. Hyperglycemic hemianopia: a reversible complication of non-ketotic hyperglycemia. *Neurology* 2005; **65**: 616-619 [PMID: [16116129](#) DOI: [10.1212/01.wnl.0000173064.80826.b8](#)]
- 14 **Wang CP**, Hsieh PF, Chen CC, Lin WY, Hu WH, Yang DY, Chang MH. Hyperglycemia with occipital seizures: images and visual evoked potentials. *Epilepsia* 2005; **46**: 1140-1144 [PMID: [16026568](#) DOI: [10.1111/j.1528-1167.2005.56404.x](#)]
- 15 **Raghavendra S**, Ashalatha R, Thomas SV, Kesavadas C. Focal neuronal loss, reversible subcortical focal T2 hypointensity in seizures with a nonketotic hyperglycemic hyperosmolar state. *Neuroradiology* 2007; **49**: 299-305 [PMID: [17200865](#) DOI: [10.1007/s00234-006-0189-6](#)]
- 16 **Moien-Afshari F**, Téllez-Zenteno JF. Occipital seizures induced by hyperglycemia: a case report and review of literature. *Seizure* 2009; **18**: 382-385 [PMID: [19138535](#) DOI: [10.1016/j.seizure.2008.12.001](#)]
- 17 **Del Felice A**, Zanoni T, Avesani M, Formaggio E, Storti S, Fiaschi A, Moretto G, Manganotti P. EEG-fMRI coregistration in non-ketotic hyperglycemic occipital seizures. *Epilepsy Res* 2009; **85**: 321-324 [PMID: [19446439](#) DOI: [10.1016/j.eplesyres.2009.03.025](#)]
- 18 **Mitchell JP**, Yancy A, Saint Louis L, Rosberger DF. Reversible hyperglycemic homonymous hemianopia. *J Natl Med Assoc* 2009; **101**: 373-376 [PMID: [19397231](#) DOI: [10.1016/s0027-9684\(15\)30888-9](#)]
- 19 **Guez A**, Obadia M, Lafitte F, Tin SN, Héran F, Gout O. Magnetic resonance spectroscopy findings in a case of hyperglycaemic hemianopia. *Rev Neurol (Paris)* 2010; **166**: 737-740 [PMID: [20219223](#) DOI: [10.1016/j.neurol.2009.12.010](#)]
- 20 **Hung WL**, Hsieh PF, Lee YC, Chang MH. Occipital lobe seizures related to marked elevation of hemoglobin A1C: report of two cases. *Seizure* 2010; **19**: 359-362 [PMID: [20558093](#) DOI: [10.1016/j.seizure.2010.05.006](#)]
- 21 **Chen CC**, Chai JW, Wu CH, Chen WS, Hung HC, Lee SK. Neuroimaging in seizure patients associated with nonketotic hyperglycemia. *Neuroradiol J* 2011; **24**: 215-220 [PMID: [24059610](#) DOI: [10.1177/197140091102400208](#)]
- 22 **Goto H**, Kumagai T, Momozaki N. MRI findings of occipital seizures in non-ketotic hyperglycemia. *Intern Med* 2011; **50**: 367-368 [PMID: [21325774](#) DOI: [10.2169/internalmedicine.50.4684](#)]
- 23 **Stayman A**, Abou-Khalil BW, Lavin P, Azar NJ. Homonymous hemianopia in nonketotic hyperglycemia is an ictal phenomenon. *Neurol Clin Pract* 2013; **3**: 392-397 [PMID: [29473606](#) DOI: [10.1212/CPJ.0b013e3182a7bb76](#)]
- 24 **Putta SL**, Weisholtz D, Milligan TA. Occipital seizures and subcortical T2 hypointensity in the setting of hyperglycemia. *Epilepsy Behav Case Rep* 2014; **2**: 96-99 [PMID: [25667880](#) DOI: [10.1016/j.ebcr.2014.01.001](#)]
- 25 **Nissa Z**, Siddiqi SA, Abdool SA. Occipital seizures and persistent homonymous hemianopia with T2 hypointensity on MRI in nonketotic hyperglycemia. *Epilepsy Behav Case Rep* 2016; **6**: 3-5 [PMID: [27358769](#) DOI: [10.1016/j.ebcr.2016.04.008](#)]
- 26 **Lansberg MG**, O'Brien MW, Norbash AM, Moseley ME, Morrell M, Albers GW. MRI abnormalities associated with partial status epilepticus. *Neurology* 1999; **52**: 1021-1027 [PMID: [10102423](#) DOI: [10.1212/wnl.52.5.1021](#)]
- 27 **Ida M**, Mizunuma K, Hata Y, Tada S. Subcortical low intensity in early cortical ischemia. *AJNR Am J Neuroradiol* 1994; **15**: 1387-1393 [PMID: [7526671](#)]
- 28 **Schomer DL**, Bonmassar G, Lazeyras F, Seeck M, Blum A, Anami K, Schwartz D, Belliveau JW, Ives J. EEG-Linked functional magnetic resonance imaging in epilepsy and cognitive neurophysiology. *J Clin Neurophysiol* 2000; **17**: 43-58 [PMID: [10709810](#) DOI: [10.1097/00004691-200001000-00005](#)]



Published by **Baishideng Publishing Group Inc**
7041 Koll Center Parkway, Suite 160, Pleasanton, CA 94566, USA

Telephone: +1-925-3991568

E-mail: bpgoffice@wjgnet.com

Help Desk: <https://www.f6publishing.com/helpdesk>

<https://www.wjgnet.com>

