

62160_Auto_Edited.docx

 Quotes Excluded
 Bibliography Excluded

 5%
 SIMILAR

Name of Journal: *World Journal of Clinical Cases*
Manuscript NO: 62160

Manuscript Type: CASE REPORT

Giant hemangioma of caudate lobe of liver with surgical treatment: A case report

 Wang XX *et al.* Giant hemangioma of caudate lobe of liver

Xin-Xin Wang, Bao-Long Dong, Biao Wu, Shi-Yong Chen, Yu He, Xiao-Jun Yang

Match Overview

1	Crossref 19 words Toshiya Shibata, Yoji Maetani, Fumie Ametani, Takeshi Kubo, Kyo Itoh, Junji Konishi. "Efficacy of Nonsurgical Treat...	1%
2	Crossref 18 words Yoshihiro Sakamoto, Norihiro Kokudo, Yoshikuni Kawaguchi, Keiichi Akita. "Clinical Anatomy of the Liver: Review of ...	1%
3	Internet 17 words crawled on 21-Oct-2020 www.wjgnet.com	1%
4	Crossref 14 words "Operative Techniques in Liver Resection", Springer Science and Business Media LLC, 2016	<1%
5	Crossref 14 words Xiaoping Yao, Weiping Zhou, Yi Wang, Mengchao Wu, Liang Jing. "Resection of giant hepatic cavernous hemangio ...	<1%
6	Internet 13 words crawled on 18-Mar-2020 link.springer.com	<1%

Giant hemangioma of caudate lobe of liver with surgical treatment:



ALL

IMAGES

VIDEOS

52,600 Results

Any time ▾

[\(PDF\) Clinics in Surgery Open Caudate Lobectomy for ...](#)

<https://www.researchgate.net/publication/333421848...>

Resection of the hemangioma located in the caudate lobe is a major challenge in current liver surgery. This study aimed to present our surgical technique for this condition.

[Surgical indication and strategy for liver hemangioma in ...](#)

<https://wjso.biomedcentral.com/articles/10.1186/s12957-020-01901-z> ▾

Jun 10, 2020 · Therefore, we collected and reviewed case files of patients diagnosed with liver hemangioma of caudate lobe and treated from January 1994 to July 2019 at five medical centers in...

Author: Wei Long Cai, Xiao Ming Ma, Xu Heng... Publish Year: 2020

[\[PDF\] Case Report Surgical Treatment of Giant Liver ...](#)

[https://jag.journalagent.com/sislietfaltip/pdfs/SETB_53_3_318_321\[A\].pdf](https://jag.journalagent.com/sislietfaltip/pdfs/SETB_53_3_318_321[A].pdf)

Surgical Treatment of Giant Liver Hemangioma, Case Report and Literature Review Address for correspondence: Gül Bora Makal, MD. Medicalpark Ankara Hastanesi, Ankara, Turkey Phone: +90 532...

[Surgical Management for Giant liver Hemangiomas Greater ...](#)

<https://www.ncbi.nlm.nih.gov/pmc/articles/PMC3140671>

May 02, 2011 · The characteristics of 14 patients with giant liver hemangiomas are shown in Table 1. The size of liver hemangioma in our subjects ranged from 20.1 to 28.4 cm. All cases were diagnose...

Cited by: 19 Author: Hui Jiang, Zheyu Chen, Pankaj Prasoon, ...

Publish Year: 2011

[Giant hepatic hemangioma case report: When is it time for ...](#)

<https://www.sciencedirect.com/science/article/pii/S2049080120302478>

Oct 01, 2020 · Surgical treatment of giant liver hemangioma larger than 10 cm: a single center's Experience with 86 patients Medicine (Baltim.) , 94 (34) (2015) , Article e1420 ,...

Author: Angelo Amico, Luca Mammino, Stefa... Publish Year: 2020

[Outcomes of surgery for giant hepatic hemangioma ...](#)

<https://europepmc.org/article/PMC/PMC8033692> ▾

Vassiou K, Rountas H, Liakou P, Arvanitis D, Fezoulidis I, Tepetes K. Embolization of a giant hepatic

Giant hemangioma of caudate lobe of liver with surgical treatment:



ALL

IMAGES

VIDEOS

53,100 Results

Any time ▾

Surgical indication and strategy for liver hemangioma in ...

<https://wjso.biomedcentral.com/articles/10.1186/s12957-020-01901-z> ▾

Jun 10, 2020 · According to reports domestic and overseas, in the meantime, isolated or combined caudate lobectomy is mainly the treatment of **liver hemangioma**, **hepatocellular carcinoma**...

Author: Wei Long Cai, Xiao Ming Ma, Xu He...

Publish Year: 2020

[PDF] Case Report Surgical Treatment of Giant Liver ...

[https://jag.journalagent.com/sislietfaltip/pdfs/SETB_53_3_318_321\[A\].pdf](https://jag.journalagent.com/sislietfaltip/pdfs/SETB_53_3_318_321[A].pdf)

We report a giant hemangioma successfully treated with surgical resection. We suggest that some patients, who have giant hemangioma, should go through surgical treatment even if they do not hav...

PEOPLE ALSO ASK

How to remove liver hemangioma? ▾

What is the classification of liver hemangioma? ▾

What to do if you have a large hemangioma? ▾

What is scintigraphy for hemangioma? ▾

Feedback

Surgical Management for Giant liver Hemangiomas Greater ...

<https://www.ncbi.nlm.nih.gov/pmc/articles/PMC3140671>

May 02, 2011 · Only **giant liver hemangiomas** may give rise to mechanical complaints requiring **surgical** intervention. And **giant liver hemangioma** was defined as the one with diameter greater...

Cited by: 19

Author: Hui Jiang, Zheyu Chen, Pankaj Prasoon...

Publish Year: 2011

ALL IMAGES VIDEOS MAPS NEWS SHOPPING

53,800 Results Any time

Surgical indication and strategy for liver hemangioma in ...

https://wjso.biomedcentral.com/articles/10.1186/s12957-020-01901-z

Jun 10, 2020 · According to reports domestic and overseas, in the meantime, isolated or combined caudate lobectomy is mainly the treatment of liver hemangioma, hepatocellular carcinoma (HCC),...

Author: Wei Long Cai, Xiao Ming Ma, Xu Heng S... Publish Year: 2020

Surgical Management for Giant liver Hemangiomas Greater ...

https://www.ncbi.nlm.nih.gov/pmc/articles/PMC3140671

May 02, 2011 · The characteristics of 14 patients with giant liver hemangiomas are shown in Table 1. The size of liver hemangioma in our subjects ranged from 20.1 to 28.4 cm. All cases were diagnosed as gia...

Cited by: 19 Author: Hui Jiang, Zheyu Chen, Pankaj Prasoon, Ho...

Publish Year: 2011

People also ask

- Is there surgery for liver hemangioma in caudate lobe?
- Is there such thing as a giant hepatic hemangioma?
- Which is the best treatment for liver hemangioma?
- Which is the most common benign hepatic tumor?

Feedback

Liver hemangioma - Diagnosis and treatment - Mayo Clinic

https://www.mayoclinic.org/diseases-conditions/...

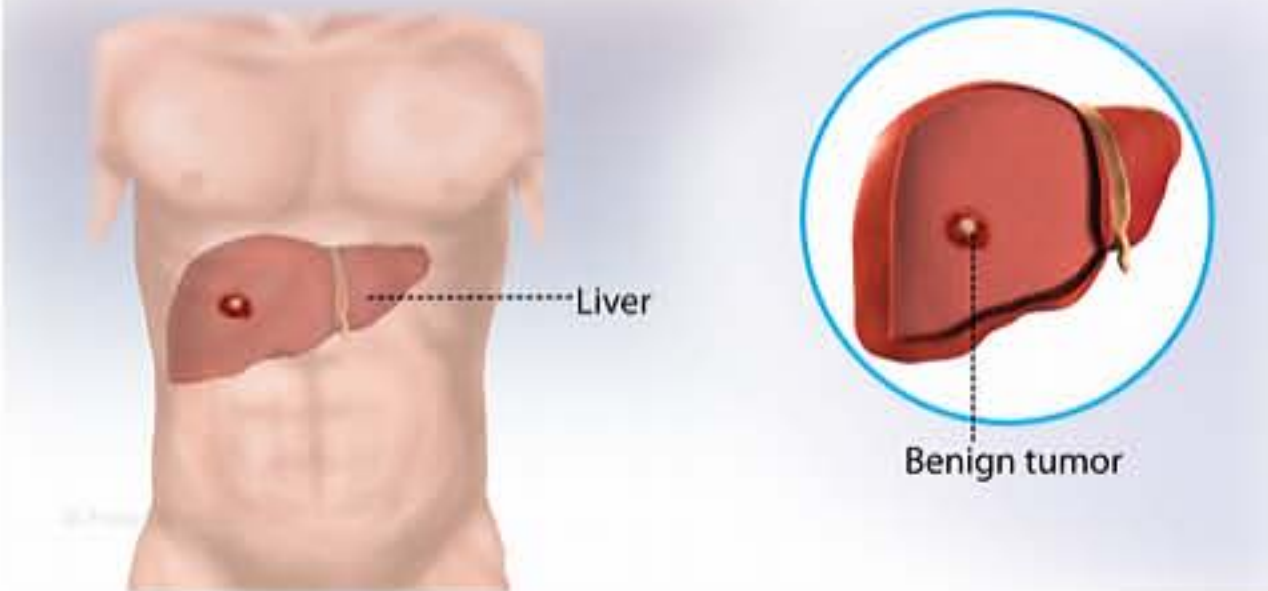
Diagnosis Treatment Clinical Trials Preparing For Your Appointment

Tests and procedures used to diagnose liver hemangiomas include: 1. Ultrasound,an imaging method that uses high-frequency sound waves to produce images of the liver 2. Computerized tomography (CT) scanning,which combines a series of X-ray images taken from different angles around your body and uses computer processing to create cross-sectional images (slices) of the liver 3. Magnetic resonance

Hemangioma of the Liver

Medical Condition

A non-cancerous tumor of the liver madeup of tangled blood vessels



A noncancerous liver mass composed of tangled blood vessels. This causes abdominal pain, nausea and vomiting.

- Very rare (Fewer than 20,000 cases per year in US)
- Not known to be contagious
- No vaccine available
- Requires lab test or imaging
- Treatable by a medical professional
- Can last several days or weeks

The causes are not clear. It is thought to be a congenital abnormality. The symptoms include pain in the abdomen, appetite loss, nausea and vomiting. In most cases liver hemangioma is not treated. This is because in most people it does not grow or is not large enough to be removed surgically. Treatment depends on location and size of the hemangioma. Treatment includes surgical removal of the tumor, artery ligation, liver transplant and radiotherapy.