


# World Journal of *Gastrointestinal Surgery*

*World J Gastrointest Surg* 2021 August 27; 13(8): 734-884



## Contents

Monthly Volume 13 Number 8 August 27, 2021

### REVIEW

- 734** Paradigm shift in gastrointestinal surgery – combating sarcopenia with prehabilitation: Multimodal review of clinical and scientific data  
*Koh FH, Chua JM, Tan JL, Foo FJ, Tan WJ, Sivarajah SS, Ho LML, Teh BT, Chew MH*

### MINIREVIEWS

- 756** Borderline resectable for colorectal liver metastases: Present status and future perspective  
*Kitano Y, Hayashi H, Matsumoto T, Kinoshita S, Sato H, Shiraishi Y, Nakao Y, Kaida T, Imai K, Yamashita YI, Baba H*
- 764** Rectovaginal fistula after low anterior resection: Prevention and management  
*Lohsiriwat V, Jitmongkarn R*
- 772** Advances in endoscopic therapy using grasping-type scissors forceps (with video)  
*Akahoshi K, Komori K, Akahoshi K, Tamura S, Osada S, Shiratsuchi Y, Kubokawa M*
- 788** Surgical complications in COVID-19 patients in the setting of moderate to severe disease  
*Gulinac M, Novakov IP, Antovic S, Velikova T*
- 796** Treatment for hepatocellular carcinoma with tumor thrombosis in the hepatic vein or inferior vena cava: A comprehensive review  
*Zhang ZY, Zhang EL, Zhang BX, Chen XP, Zhang W*
- 806** Multidisciplinary management of acute mesenteric ischemia: Surgery and endovascular intervention  
*Sakamoto T, Kubota T, Funakoshi H, Lefor AK*
- 814** Associating liver partition and portal vein ligation for staged hepatectomy in the treatment of colorectal cancer liver metastases  
*Wen XD, Xiao L*
- 822** Persistent bowel dysfunction after surgery for Hirschsprung's disease: A neuropathological perspective  
*Verkuil SJ, Friedmacher F, Harter PN, Rolle U, Broens PM*
- 834** Robotic transanal total mesorectal excision: Is the future now?  
*Sebastián-Tomás JC, Martínez-Pérez A, Martínez-López E, de'Angelis N, Gómez Ruiz M, García-Granero E*

### ORIGINAL ARTICLE

#### Retrospective Study

- 848** Reappraisal of surgical decision-making in patients with splenic sclerosing angiomatoid nodular transformation: Case series and literature review  
*Tseng H, Ho CM, Tien YW*

**Observational Study**

- 859** Impact of COVID-19 on presentation, management, and outcomes of acute care surgery for gallbladder disease and acute appendicitis

*Farber ON, Gomez GI, Titan AL, Fisher AT, Puntasecca CJ, Arana VT, Kempinsky A, Wise CE, Bessoff KE, Hawn MT, Korndorffer JR Jr, Forrester JD, Esquivel MM*

**META-ANALYSIS**

- 871** Genitourinary function and defecation after colorectal cancer surgery with low- and high-ligation of the inferior mesenteric artery: A meta-analysis

*Bai X, Zhang CD, Pei JP, Dai DQ*

**ABOUT COVER**

Editorial Board Member of *World Journal of Gastrointestinal Surgery*, Damiano Caputo, FACS, MD, Associate Professor, Surgeon, Department of General Surgery, Università Campus Bio-Medico di Roma, Rome 00128, Italy. d.caputo@unicampus.it

**AIMS AND SCOPE**

The primary aim of *World Journal of Gastrointestinal Surgery* (WJGS, *World J Gastrointest Surg*) is to provide scholars and readers from various fields of gastrointestinal surgery with a platform to publish high-quality basic and clinical research articles and communicate their research findings online.

WJGS mainly publishes articles reporting research results and findings obtained in the field of gastrointestinal surgery and covering a wide range of topics including biliary tract surgical procedures, biliopancreatic diversion, colectomy, esophagectomy, esophagostomy, pancreas transplantation, and pancreatectomy, etc.

**INDEXING/ABSTRACTING**

The WJGS is now abstracted and indexed in Science Citation Index Expanded (SCIE, also known as SciSearch®), Current Contents/Clinical Medicine, Journal Citation Reports/Science Edition, PubMed, and PubMed Central. The 2021 edition of Journal Citation Reports® cites the 2020 impact factor (IF) for WJGS as 2.582; IF without journal self cites: 2.564; 5-year IF: 3.378; Journal Citation Indicator: 0.53; Ranking: 97 among 212 journals in surgery; Quartile category: Q2; Ranking: 73 among 92 journals in gastroenterology and hepatology; and Quartile category: Q4.

**RESPONSIBLE EDITORS FOR THIS ISSUE**

Production Editor: Jia-Hui Li; Production Department Director: Xiang Li; Editorial Office Director: Ya-Juan Ma.

**NAME OF JOURNAL**

*World Journal of Gastrointestinal Surgery*

**ISSN**

ISSN 1948-9366 (online)

**LAUNCH DATE**

November 30, 2009

**FREQUENCY**

Monthly

**EDITORS-IN-CHIEF**

Shu-You Peng, Varut Lohsiriwat, Jin Gu

**EDITORIAL BOARD MEMBERS**

<https://www.wjgnet.com/1948-9366/editorialboard.htm>

**PUBLICATION DATE**

August 27, 2021

**COPYRIGHT**

© 2021 Baishideng Publishing Group Inc

**INSTRUCTIONS TO AUTHORS**

<https://www.wjgnet.com/bpg/gerinfo/204>

**GUIDELINES FOR ETHICS DOCUMENTS**

<https://www.wjgnet.com/bpg/gerinfo/287>

**GUIDELINES FOR NON-NATIVE SPEAKERS OF ENGLISH**

<https://www.wjgnet.com/bpg/gerinfo/240>

**PUBLICATION ETHICS**

<https://www.wjgnet.com/bpg/gerinfo/288>

**PUBLICATION MISCONDUCT**

<https://www.wjgnet.com/bpg/gerinfo/208>

**ARTICLE PROCESSING CHARGE**

<https://www.wjgnet.com/bpg/gerinfo/242>

**STEPS FOR SUBMITTING MANUSCRIPTS**

<https://www.wjgnet.com/bpg/gerinfo/239>

**ONLINE SUBMISSION**

<https://www.f6publishing.com>



## Treatment for hepatocellular carcinoma with tumor thrombosis in the hepatic vein or inferior vena cava: A comprehensive review

Zun-Yi Zhang, Er-Lei Zhang, Bi-Xiang Zhang, Xiao-Ping Chen, Wei Zhang

**ORCID number:** Zun-Yi Zhang 0000-0002-0370-1596; Er-Lei Zhang 0000-0002-7251-0275; Bi-Xiang Zhang 0000-0002-1609-7260; Xiao-Ping Chen 0000-0001-8636-0493; Wei Zhang 0000-0002-3380-1010.

**Author contributions:** Zhang ZY performed the majority of the writing and prepared the figures and tables; Zhang EL, Zhang BX, and Chen XP performed data and writing accusation; Zhang W designed the outline of this paper.

**Supported by** the National Natural Science Foundation of China, No. 81802767 and No. 81860117.

**Conflict-of-interest statement:** We declare that we have no financial and personal relationships with other people or organizations that can inappropriately influence our work, and there is no professional or other personal interest of any nature or kind in any product, service and/or company that could be construed as influencing the position presented in, or the review of, the manuscript entitled.

**Open-Access:** This article is an open-access article that was selected by an in-house editor and fully peer-reviewed by external reviewers. It is distributed in accordance with the Creative Commons Attribution NonCommercial (CC BY-NC 4.0)

**Zun-Yi Zhang, Er-Lei Zhang, Bi-Xiang Zhang, Xiao-Ping Chen, Wei Zhang,** Research Laboratory and Hepatic Surgery Center, Tongji Hospital, Tongji Medical College, Huazhong University of Science and Technology, Wuhan 434000, Hubei Province, China

**Corresponding author:** Wei Zhang, MD, Professor, Research Laboratory and Hepatic Surgery Center, Tongji Hospital, Tongji Medical College, Huazhong University of Science and Technology, No. 1095 Jiefang Road, Wuhan 434000, Hubei Province, China.

[weizhangtjh@hust.edu.cn](mailto:weizhangtjh@hust.edu.cn)

### Abstract

Hepatocellular carcinoma (HCC) is the most common type of liver cancer with a high mortality rate worldwide. The percentage of HCC patients with vascular invasion is high. However, tumor thrombus in the hepatic vein (HVTT) has a lower incidence than tumor thrombus in the portal vein (PVTT). Conventionally, HCC patients with HVTT are treated the same as HCC patients with PVTT and offered sorafenib or other systemic agents. However, according to recent studies, it is evident that HCC with HVTT shows different outcomes when classified into different subgroups. In this review, we discuss the recent progress and changes in treatment of HCC with HVTT.

**Key Words:** Hepatocellular carcinoma; Vascular invasion; Surgery; Transarterial chemoembolization

©The Author(s) 2021. Published by Baishideng Publishing Group Inc. All rights reserved.

**Core Tip:** Vascular invasion or tumor thrombus in hepatocellular carcinoma (HCC) patients is very common. Vascular invasion includes two different types, *i.e.*, tumor thrombosis in the portal vein (PVTT) or hepatic vein (HVTT). Compared with PVTT, HVTT is found with a lower incidence. Most of published studies are concentrated on HCC with PVTT. Recent studies have proved magnificent prognostic results in HCC patients with HVTT. Several classifications have been proposed to gauge the prognoses of HVTT. Although further investigations are needed, expanding treatment options including hepatectomy, radiotherapy, radioembolization, and systemic treatment are reported to improve the outcomes of patients with HVTT.



license, which permits others to distribute, remix, adapt, build upon this work non-commercially, and license their derivative works on different terms, provided the original work is properly cited and the use is non-commercial. See: <http://creativecommons.org/licenses/by-nc/4.0/>

**Manuscript source:** Invited manuscript

**Specialty type:** Gastroenterology and hepatology

**Country/Territory of origin:** China

**Peer-review report's scientific quality classification**

Grade A (Excellent): 0  
Grade B (Very good): 0  
Grade C (Good): C, C  
Grade D (Fair): 0  
Grade E (Poor): 0

**Received:** February 10, 2021

**Peer-review started:** February 10, 2021

**First decision:** March 30, 2021

**Revised:** April 12, 2021

**Accepted:** July 2, 2021

**Article in press:** July 2, 2021

**Published online:** August 27, 2021

**P-Reviewer:** Hou L

**S-Editor:** Zhang H

**L-Editor:** Wang TQ

**P-Editor:** Zhang YL



**Citation:** Zhang ZY, Zhang EL, Zhang BX, Chen XP, Zhang W. Treatment for hepatocellular carcinoma with tumor thrombosis in the hepatic vein or inferior vena cava: A comprehensive review. *World J Gastrointest Surg* 2021; 13(8): 796-805

**URL:** <https://www.wjgnet.com/1948-9366/full/v13/i8/796.htm>

**DOI:** <https://dx.doi.org/10.4240/wjgs.v13.i8.796>

## INTRODUCTION

Hepatocellular carcinoma (HCC) is the most common type of liver cancer with a high mortality rate worldwide. The percentage of HCC patients with vascular invasion at the time of initial HCC diagnosis is 10%-40% [1-3]. According to the American Association for the Study of Liver Disease/Barcelona Clinic for Liver Cancer (AASLD/BCLC) staging system and treatment guidelines, HCC associated with vascular invasion or bile duct invasion is regarded as an advanced stage. The only suggested treatment for such patients is systematic treatment, such as sorafenib or lenvatinib. However, the median survival time of these patients is very unsatisfactory. A larger tumor size, increased tumor number, higher tumor grade, worse Child-Pugh class, and higher serum alpha-fetoprotein are usually considered concomitant factors with tumor thrombosis. When these factors cooccur with tumor thrombi, the patients are usually reported to have a poor prognosis and a high recurrence rate even after R0 resection.

Due to recent advances in surgical techniques and perioperative management, liver resection combined with thrombectomy or radiation therapy has been used in selected HCC patients with tumor thrombus. In addition to curative-intent surgery, transarterial chemoembolization (TACE), external beam radiation, or combined treatment have also been adopted in HCC patients with vascular invasion. However, their treatment efficacy is still controversial.

Vascular invasion includes two different types, *i.e.*, tumor thrombosis in the portal vein (PVTT) or in the hepatic vein (HVTT) [4]. Depending on the different locations of the tumor thrombus, the complications caused by the tumor thrombus might be different. Intrahepatic metastasis and increased portal pressure are usually seen in HCC patients with PVTT. However, in HCC patients with HVTT, the most lethal complications might be the formation of a tumor thrombus in the inferior vena cava (IVC), intrapulmonary dissemination, pulmonary embolism, or even sudden death [4, 5]. Compared with HCC patients with PVTT, patients with only HVTT have different outcomes [6].

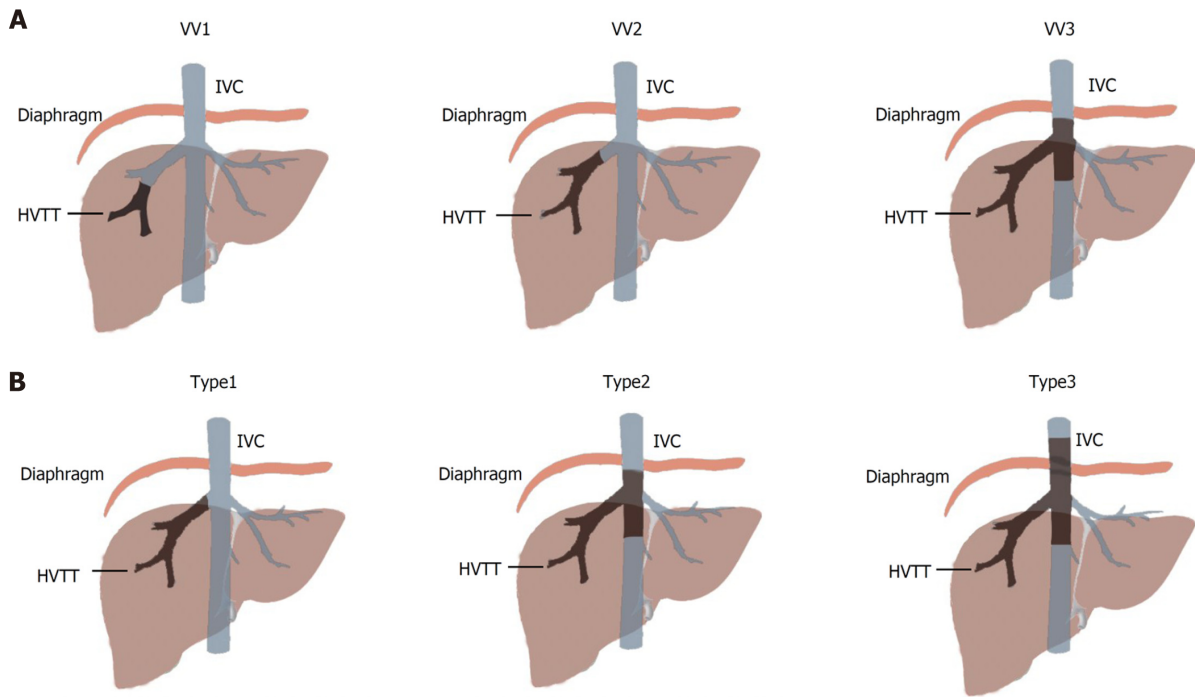
According to recent studies, several attempts have been made to develop alternative or combination treatments to improve the overall survival of patients with HCC with HVTT. In the present review, we aim to briefly describe the classification of HVTT and evaluate the available evidence for the efficiency of diverse treatment modalities.

## CLASSIFICATIONS OF HVTT

With recent improvements in surgical techniques or nonsurgical techniques (TACE and external beam radiation), treatment modalities for patients with tumor thrombi in the hepatic vein or IVC have shown varied results among different institutions. To devise the best treatment strategy, a universally accepted classification of HVTT or IVC tumor thrombosis is urgently needed.

In contrast to portal vein tumor thrombi, tumor thrombi in the hepatic vein/ IVC have a lower incidence. Classification systems have been proposed recently. Kokudo *et al* [6] proposed a classification system that classified HVTT into three different types: Peripheral hepatic vein (pHVTT, VV1), major hepatic vein (mHVTT, VV2), and IVC (VV3) (Figure 1A). According to Kokudo *et al* [4]'s study, the median survival times after resection in the VV1, VV2 and VV3 groups were 5.27 years, 3.95 years, and 1.39 years, respectively. However, in a subsequent study by Kokudo *et al* [4], after curative resection, the median survival time was similar between patients with HVTT in the peripheral hepatic vein and those with HVTT in the major hepatic vein (4.85 vs 4.67 years,  $P = 0.974$ ). Therefore, the prognostic value of classifying patients into VV1 and VV2 was limited.

Recently, Chen *et al* [7] proposed another classification system for HCC patients with HVTT. This new classification system was defined as follows: Type I, tumor



**Figure 1** Hepatic vein tumor thrombus staging and classification. A: Hepatic vein tumor thrombus staging according to Japanese Staging System; B: Classification proposed by Chen *et al*[7]. HVTT: Hepatic vein tumor thrombus; IVC: Inferior vena cava.

thrombosis involving the hepatic vein, including microvascular invasion; type II, tumor thrombosis involving the retrohepatic segment of the IVC; and type III, tumor thrombosis involving the supradiaphragmatic segment of the IVC[7] (Figure 1B). In this new classification system, type I HVTT includes Kokudo *et al*[4]'s VV1 and VV2 types. The VV3 type is divided into two types (type II and type III) by whether the tumor thrombosis involves the supradiaphragmatic segment of the IVC.

According to Chen *et al*[7]'s report, the time-dependent receiver operating characteristic curve area analysis of this new classification system showed better prediction of overall survival (OS) than the other staging systems. The 1-, 2-, and 3-year OS rates for types I to III HVTT were 79.5%, 58.6%, and 29.1%; 54.8%, 23.3%, and 13.8%; and 24.0%, 10.0%, and 2.1%, respectively[7]. Based on the studies published, Chen *et al*[7]'s classification for HVTT is more reasonable. Except for better prognostic value, Chen *et al*[7]'s classification also showed wider usage in practice, because tumor thrombus in peripheral hepatic veins, especially in secondary or tertiary hepatic vein, could be ignored sometimes in radiological examination.

## CURATIVE SURGERY

The survival rate is poor for HCC patients with macrovascular invasion. Surgical treatment is generally not suggested because the tumor cells might have spread throughout the whole body, and the survival time is only 2.7-4 mo after diagnosis[8]. Despite the poor prognosis of HCC patients with HVTT or IVC, liver resection combined with thrombectomy is still generally assumed to be a hazardous and complex procedure with a high morbidity of 40% and high mortality of 15%[9,10]. However, with improved techniques of total hepatic vascular exclusion (THVE) and better selection of patients, hepatectomy and thrombectomy can be performed with improved safety for resectable HCC patients with tumor thrombosis in the hepatic vein, the IVC, or even the right atrium (RA)[10-14].

The two common modes of surgery are hepatectomy combined with tumor thrombectomy and *en bloc* resection of the thrombus. Intraoperative ultrasound is necessary and should be performed to detect additional lesions as well as the tumor thrombus in the portal vein, hepatic vein, and IVC. According to most reports, for HCC patients with a peripheral hepatic vein thrombus, HVTT is usually confined to one hepatic lobe, and *en bloc* resection of the whole hepatic lobe might be sufficient[5, 7]. However, for HCC patients with tumor thrombi in the IVC or RA, effective control

of intraoperative hemorrhage might be more crucial and effective.

Before hepatectomy, the infrahepatic and suprahepatic IVC should be exposed and encircled with umbilical tape for THVE[15]. Before the initiation of THVE, test clamping of the IVC should be performed to check whether the hemodynamic instability could be sustained. Otherwise, a venous bypass should be conducted[10, 15]. If the tumor thrombus extends above the diaphragm, the supradiaphragmatic IVC should be exposed, encircled, and controlled with tape after a vertical incision is made in the diaphragm[16]. If the IVC tumor thrombus extends into the RA, extracorporeal circulation might be necessary[7,10,15].

During surgery, the liver should be handled gently to prevent the dissemination of tumor thrombi or pulmonary embolism, especially when the thrombus has a long and thin neck. Only after THVE is initiated could thrombectomy be conducted. If the tumor thrombus invades the wall of the IVC or RA, the tumor-involved wall should be resected together with the thrombus. Then, the wall of the IVC or RA should be repaired by direct continuous sutures or artificial grafting[10]. Typically, the exclusion duration is considered to be safe if it is less than 60 min. However, according to Elias's report, by alternating 15-20 min of vascular clamping with 5 min of release, the duration of exclusion could be extended to 120 min[5,17]. With the common combined presence of liver cirrhosis and hepatic steatosis in Asia, the duration of exclusion should be controlled within the prespecified duration[5]. However, it is not clear to what extent the exclusion duration should be controlled and this aspect should be discussed further[18].

To date, there is no worldwide consensus on the management of HCC associated with macroscopic vascular thrombi. Recently, an increasing number of studies have reported that surgical treatment can significantly prolong the survival of HCC patients with PVTT. However, there are few reports on the surgical treatment of HCC combined with HVTT (Table 1). This is probably because HVTT is relatively rare compared with PVTT and it requires more complicated surgical techniques. In 2012, Liu *et al*[5] reported a study with 65 HCC patients with tumor thrombi in the hepatic vein/IVC. After surgery, the median overall survival and recurrence-free survival reached 17 and 14 mo, respectively. In the following studies, although the patient number was still limited, selected patients with tumor thrombi in RA underwent hepatectomy combined with thrombectomy[10,15,19]. The median overall survival time was nearly the same as that in Liu's report. In 2014, Kokudo *et al*[6] reported a retrospective study that might be one of largest single-center series of HVTT with standardized surgical resection. A total of 187 patients with HVTT were treated. The median survival time of patients with pHVTT and mHVTT was prolonged to 5.27 and 3.95 years, respectively, with a difference that was not statistically significant. In patients with tumor thrombus in the IVC, the median overall survival time after surgery was 1.39 years, which was significantly shorter than that in the pHVTT and mHVTT groups.

The risk factors for a reduced overall survival of patients with HVTT after surgery include tumor thrombus in the IVC and R1/2 resection. Concerning the time to recurrence, Child-Pugh class B and the number of tumors were identified as risk factors. The presence of PVTT was found to have a high rate of coexistence in all of the above studies (Table 1); however, it was not identified as a risk factor for overall survival or disease-free survival[6,10,15]. In 2019, Chen *et al*[7] proposed a new classification for HCC with hepatic vein tumor thrombus. In this study, tumor diameter, albumin level, coexistence of PVTT, types of HVTT and treatment modality were risk factors for OS. Although the results showed little difference compared with Kokudo *et al*[4]'s study, the overall survival after hepatectomy and thrombectomy showed better results compared with earlier reports. Compared with other nonsurgical treatments, surgery and thrombectomy can provide a better prognosis in selected patients with tumor thrombi in the hepatic vein[4,7]. For patients with tumor thrombi in the IVC or RA, the overall survival showed similar results between surgery and nonsurgical treatment[4]. The surgical indications for HCC patients with tumor thrombi in the IVC or RA still need further discussion.

## TACE/HEPATIC ARTERIAL INFUSION CHEMOTHERAPY

According to the BCLC staging system, HCC patients with macrovascular invasion are considered to be at an advanced stage, and only sorafenib or conservative treatment is suggested[20]. For HCC patients with HVTT, due to the modest efficacy of sorafenib, lung metastasis, secondary Budd-Chiari syndrome, and even heart failure may occur,



**Table 1 Retrospective study published concentrating on surgical treatment for hepatocellular carcinoma patients with tumor thrombus in hepatic vein**

Ref.	Treatment	Location of tumor thrombus	Patient number	OS	Prognostic factors
Chen <i>et al</i> [7], 2020	Surgery, TACE, supportive treatment	HV, IVC	437	27.1 mo for type 1; 15 mo for type 2; 8 mo for type 3	HVTT classification, treatment modality, coexistence of PVTT, total bilirubin, tumor diameter
Kokudo <i>et al</i> [4], 2017	Surgical <i>vs</i> no surgical	HV, IVC	651 <i>vs</i> 615	4.47 yr <i>vs</i> 1.58 yr in pHVTT/mHVTT; 1.48 yr <i>vs</i> 0.84 yr in IVCTT	In pHVTT/mHVTT, PVTT, number of tumors, gastroesophageal varices, poor cell differentiation
Li <i>et al</i> [14], 2015	Hepatectomy <i>en bloc vs</i> hepatectomy combined with suction of tumor thrombus	HV or portal vein	28 <i>vs</i> 28	14.3 mo <i>vs</i> 10.4 mo	Preoperative AFP level, treatment choice
Kokudo <i>et al</i> [6], 2014	Hepatectomy combined with or without thrombectomy	HV, IVC	174	5.27 yr for pHVTT; 3.95 yr for mHVTT; 1.39 yr for IVCTT	Location of tumor thrombus, R1/2 resection
Wang <i>et al</i> [12], 2013	Hepatectomy and tumor thrombectomy <i>vs</i> TACE <i>vs</i> symptomatic treatment	IVC or RA	25 <i>vs</i> 20 <i>vs</i> 11	19 mo <i>vs</i> 4 mo <i>vs</i> 5 mo	Number of tumor nodules, treatment choice
Liu <i>et al</i> [5], 2012	Hepatectomy and tumor thrombectomy <i>vs</i> TACE + chemotherapy	RHV or IVC	65 <i>vs</i> 50	18 mo <i>vs</i> 7 mo	Not mentioned

TACE: Transarterial chemoembolization; RHA: Right hepatic vein; HV: Hepatic vein; IVC: Inferior vena cava; RA: Right atrium; pHVTT: Peripheral hepatic vein tumor thrombus; mHVTT: Major hepatic vein tumor thrombus; IVCTT: Inferior vena cava tumor thrombus.

and the prognosis is very poor[21,22]. To achieve a better outcome and less damage to liver function, several alternative nonsurgical treatments have been proposed. TACE and hepatic arterial infusion chemotherapy (HAIC) are two important nonsurgical treatments that should not be ignored.

TACE takes advantage of relatively selective arterial vascularization of hepatic tumors[23]. This technique is considered to be the primary treatment for HCC patients who are considered inoperable and without contraindications[24]. In the Asian guidelines for HCC[25,26], TACE could be applied in patients without main portal vein invasion. However, for patients with HVTT, the prognostic value of TACE is still unclear. The median overall survival was reported to be between 6.5 mo and 1.61 years in HCC patients with HVTT treated with TACE alone[4,19,22]. When compared with liver resection, most studies showed that patients with HVTT who underwent TACE have a worse prognosis[4,7,19]. Potential selection bias was sometimes suggested to account for this result. However, in Kokudo *et al* [4]'s study, after a 1:1 propensity match between the surgical group and the nonsurgical group, TACE still provided a worse overall survival and disease-free survival in any type of HCC patient with HVTT[4]. In addition, in a comparison of patients who underwent hepatic resection with those who attained a partial/complete response after TACE, no significant difference in prognosis was found between surgery and TACE[19]. Therefore, it may be possible to increase the efficacy of TACE with improved selection criteria and by combining different treatments.

HAIC has been reported to have substantial efficacy for advanced HCC[27,28]. However, most of the studies based on HAIC have mainly focused on PVTT[29-31]. 5-fluorouracil and systemic interferon or cisplatin have been reported to be some of the most effective combination chemotherapies for HCC with PVTT[32,33]. Several studies have shown a high response rate of 40% to 50% for advanced HCC[28,34]. Studies concentrated on HAIC treatment of HCC patients with HVTT are rare. According to Murakami *et al* [35]'s report, the intrahepatic response rate to HAIC was 30%, with a median survival time of 7.9 mo to 1.2 years[4]. This prognosis is still poor and nearly the same as that of patients treated with TACE. However, for HCC patients with HVTT who attained a partial/complete response from HAIC or sorafenib treatment, the median OS was extended to 26.1 mo. The median OS was limited to 10.4 mo among patients who showed no response[36]. When HAIC was combined with radiotherapy, the treatment effective rate for HVTT could be increased from 37% to 79% in a study with only a small sample size[35]. Although the number of studies focused on HAIC in HCC patients with HVTT is limited, HAIC was still shown to

improve the prognosis of HCC patients when combined with other treatments.

## RADIOTHERAPY

External beam radiation therapy (EBRT) for HCC was first introduced in the 1990s [37]. EBRT is not recommended as a first-line treatment for HCC with vascular invasion by some international consensuses, including BCLC [20]. This is probably because the liver is usually considered highly radiosensitive. It is challenging to deliver a sufficiently high dose of radiation without excessive hepatotoxicity. However, as a result of advances in EBRT, such as 3-D confocal radiation planning and breath control management, EBRT now plays an important role in the treatment of HCC [38,39]. In a recently published liver cancer staging system in China, radiation therapy was suggested as an effective treatment for patients with HVTT [26]. According to published studies, the median radiation dose ranged from 48 to 60 Gy [40]. Radiation therapy could target tumor thrombi only or both tumor thrombi and the main tumor lesion [41,42]. The reported median survival time ranged from 5.6-25.4 mo [41-43] and the response rate ranged from 39%-76.7% [41,42,44]. CTCAE grade 3 CTCAE or higher toxicity has rarely been reported. In a study with 11 patients, one pulmonary embolism case and one esophageal rupture case were reported at 1.6 and 3.7 mo after initiation of EBRT, respectively [42]. Because these studies were all retrospective studies, research bias could not be completely ruled out. Pulmonary embolism and esophageal rupture are both complications that could be encountered in HCC patients with HVTT. Therefore, whether these complications should be regarded as side effects of EBRT still needs further investigation.

## SYSTEMIC THERAPY

Compared with other cancer types, the usage of conventional cytotoxic chemotherapy, such as doxorubicin- or doxorubicin-based combinations, is still limited for HCC because of its significant toxicity [24]. In the liver cancer staging system in China, a combination of oxaliplatin and 5-fluorouracil and leucovorin, known as the FOLFOX4 regimen, has been proposed for the treatment of HCC patients with macrovascular invasion [26]. The application of FOLFOX4 in HCC patients with HVTT is limited. According to Liu's study, in HCC patients with HVTT, FOLFOX4 showed a median survival of 8 mo [5]. This result was not satisfactory. Compared with hepatectomy, FOLFOX4 did not seem to provide a longer overall survival time or recurrence-free survival [5].

Sorafenib is a multitargeted small molecule with specific activity against the vascular endothelial growth factor receptor. According to most international guidelines, such as the BCLC staging system, sorafenib has been suggested as the first-line treatment for HCC patients with macrovascular invasion [20,45]. When compared to placebo, sorafenib was proven to prolong the median overall survival by 2 mo in HCC patients with vascular invasion according to two Phase III clinical trials, SHARP and the Asian Pacific study [46,47]. According to the SHARP trial, the median survival in the subgroup with microvascular invasion was 8.1 mo with sorafenib and 4.9 mo with placebo [46]. However, to date, no prospective or well-designed retrospective studies have reported the use of sorafenib in the treatment of HCC patients with HVTT. Several recent retrospective studies from China demonstrated that sorafenib could reduce recurrence and prolong the survival rate in patients with vascular invasion after curative hepatectomy [45,48]. Therefore, sorafenib might be useful in decreasing the risk of recurrence in patients with HVTT when combined with other treatments. However, it still needs more investigation.

Lenvatinib is an oral multikinase inhibitor that targets VEGFR receptor 1-3, FGFR receptor 1-4, PDGF receptor  $\alpha$ , RET, and KIT [49]. Lenvatinib has recently become available as a new molecular targeted agent for the first-line treatment of unresectable HCC in Japan, the USA, the European Union, and Asia [50]. In the REFLECT trial, lenvatinib showed a comparable overall survival to sorafenib [49]. With regard to secondary endpoints of progression-free survival, time to progression, and the objective response rate, lenvatinib showed a clinically meaningful improvement compared with sorafenib in unresectable HCC. However, lenvatinib was only approved for applications in advanced HCC in 2017. The prognostic value of lenvatinib in HCC with HVTT is still unknown.

In contrast to other organs, the liver sustains an immunosuppressive milieu because of a series of regulatory mechanisms, including chronic hepatitis or HCC immune escape[51,52]. Therefore, conventional immunotherapies have limited effects on HCC. However, immunotherapy, such as checkpoint inhibitors (PD-1, PD-L1, and CTLA4), has been applied in HCC patients. A series of clinical trials on PD-1/PD-L1 inhibitors showed favorable results, which might start a new chapter on the treatment of advanced HCC[53]. As the data on immune checkpoint inhibitors in the treatment of HCC become more mature and reliable, their effectiveness in the treatment of HCC patients with HVTT can be better elucidated.

## CONCLUSION

According to recent studies, the management of HCC with HVTT is evolving. The treatment modalities include hepatectomy combined with thrombectomy, TACE, radiotherapy, and systematic therapy. Because of the rarity of HCC with HVTT, few studies have been conducted. Based on recent studies, selected HCC patients with HVTT seem to have a better prognosis than HCC patients with PVTT. According to the published data and the experience of our center, liver resection combined with thrombectomy could provide a better prognosis when compared with non-surgical treatment. However, most patients with major vascular invasion, especially IVC invasion, might have lost the opportunity for surgery, either because of extrahepatic metastasis or intrahepatic metastasis. As long as the tumor lesion is resectable and tumor thrombus is limited in the major hepatic vein, liver resection should be the first choice, especially in patients with good liver function. The invasion or tumor thrombus in the hepatic vein or IVC should never be a contraindication for surgery. Recently, targeted therapy and immunotherapy have been developed and used in advanced stage HCC and amazing results were detected. When combined with TACE or radiotherapy, the objective response rate could even be increased in selected advanced HCC patients. More and more cases were found about changing from unresectable state to resectable state after targeted therapy and immunotherapy combined with TACE or radiotherapy in our center. It might provide insight for treatments to HCC patients who are not suitable for resection. However, additional well-designed prospective or retrospective studies are needed to provide high-level evidence of the safety and efficacy of single or combined treatments.

## REFERENCES

- 1 **Forner A**, Llovet JM, Bruix J. Hepatocellular carcinoma. *Lancet* 2012; **379**: 1245-1255 [PMID: 22353262 DOI: 10.1016/S0140-6736(11)61347-0]
- 2 **Shi J**, Lai EC, Li N, Guo WX, Xue J, Lau WY, Wu MC, Cheng SQ. Surgical treatment of hepatocellular carcinoma with portal vein tumor thrombus. *Ann Surg Oncol* 2010; **17**: 2073-2080 [PMID: 20131013 DOI: 10.1245/s10434-010-0940-4]
- 3 **Chen XP**, Qiu FZ, Wu ZD, Zhang ZW, Huang ZY, Chen YF, Zhang BX, He SQ, Zhang WG. Effects of location and extension of portal vein tumor thrombus on long-term outcomes of surgical treatment for hepatocellular carcinoma. *Ann Surg Oncol* 2006; **13**: 940-946 [PMID: 16788755 DOI: 10.1245/ASO.2006.08.007]
- 4 **Kokudo T**, Hasegawa K, Matsuyama Y, Takayama T, Izumi N, Kadoya M, Kudo M, Kubo S, Sakamoto M, Nakashima O, Kumada T, Kokudo N; Liver Cancer Study Group of Japan. Liver resection for hepatocellular carcinoma associated with hepatic vein invasion: A Japanese nationwide survey. *Hepatology* 2017; **66**: 510-517 [PMID: 28437844 DOI: 10.1002/hep.29225]
- 5 **Liu J**, Wang Y, Zhang D, Liu B, Ou Q. Comparison of survival and quality of life of hepatectomy and thrombectomy using total hepatic vascular exclusion and chemotherapy alone in patients with hepatocellular carcinoma and tumor thrombi in the inferior vena cava and hepatic vein. *Eur J Gastroenterol Hepatol* 2012; **24**: 186-194 [PMID: 22081008 DOI: 10.1097/MEG.0b013e32834dda64]
- 6 **Kokudo T**, Hasegawa K, Yamamoto S, Shindoh J, Takemura N, Aoki T, Sakamoto Y, Makuuchi M, Sugawara Y, Kokudo N. Surgical treatment of hepatocellular carcinoma associated with hepatic vein tumor thrombosis. *J Hepatol* 2014; **61**: 583-588 [PMID: 24798618 DOI: 10.1016/j.jhep.2014.04.032]
- 7 **Chen ZH**, Wang K, Zhang XP, Feng JK, Chai ZT, Guo WX, Shi J, Wu MC, Lau WY, Cheng SQ. A new classification for hepatocellular carcinoma with hepatic vein tumor thrombus. *Hepatobiliary Surg Nutr* 2020; **9**: 717-728 [PMID: 33299827 DOI: 10.21037/hbsn.2019.10.07]
- 8 **Thomas MB**, Jaffe D, Choti MM, Belghiti J, Curley S, Fong Y, Gores G, Kerlan R, Merle P, O'Neil B, Poon R, Schwartz L, Tepper J, Yao F, Haller D, Mooney M, Venook A. Hepatocellular carcinoma: consensus recommendations of the National Cancer Institute Clinical Trials Planning Meeting. *J Clin*

- Oncol* 2010; **28**: 3994-4005 [PMID: 20679622 DOI: 10.1200/JCO.2010.28.7805]
- 9 **Chang JY**, Ka WS, Chao TY, Liu TW, Chuang TR, Chen LT. Hepatocellular carcinoma with intra-atrial tumor thrombi. A report of three cases responsive to thalidomide treatment and literature review. *Oncology* 2004; **67**: 320-326 [PMID: 15557794 DOI: 10.1159/000081333]
  - 10 **Wakayama K**, Kamiyama T, Yokoo H, Kakisaka T, Kamachi H, Tsuruga Y, Nakanishi K, Shimamura T, Todo S, Taketomi A. Surgical management of hepatocellular carcinoma with tumor thrombi in the inferior vena cava or right atrium. *World J Surg Oncol* 2013; **11**: 259 [PMID: 24093164 DOI: 10.1186/1477-7819-11-259]
  - 11 **Togo S**, Shimada H, Tanaka K, Masui H, Fujii S, Endo I, Sekido H. Management of malignant tumor with intracaval extension by selective clamping of IVC. *Hepatogastroenterology* 1996; **43**: 1165-1171 [PMID: 8908546]
  - 12 **Wang Y**, Chen H, Wu MC, Sun YF, Lin C, Jiang XQ, Wei GT. [Surgical treatment of hepatocellular carcinoma with tumor thrombus in the inferior vena cava]. *Zhonghua Wai Ke Za Zhi* 2003; **41**: 165-168 [PMID: 12887770]
  - 13 **Ohta M**, Nakanishi C, Kawagishi N, Hara Y, Maida K, Kashiwade T, Miyazawa K, Yoshida S, Miyagi S, Hayatsu Y, Kawamoto S, Matsuda Y, Okada Y, Saiki Y, Ohuchi N. Surgical resection of recurrent extrahepatic hepatocellular carcinoma with tumor thrombus extending into the right atrium under cardiopulmonary bypass: a case report and review of the literature. *Surg Case Rep* 2016; **2**: 110 [PMID: 27726114 DOI: 10.1186/s40792-016-0241-7]
  - 14 **Li SH**, Wang QX, Sun P, Li Q, Yang ZY, Shi M, Wei W, Guo RP. Surgical Strategy for Hepatocellular Carcinoma Patients with Portal/Hepatic Vein Tumor Thrombosis. *PLoS One* 2015; **10**: e0130021 [PMID: 26076461 DOI: 10.1371/journal.pone.0130021]
  - 15 **Wang Y**, Yuan L, Ge RL, Sun Y, Wei G. Survival benefit of surgical treatment for hepatocellular carcinoma with inferior vena cava/right atrium tumor thrombus: results of a retrospective cohort study. *Ann Surg Oncol* 2013; **20**: 914-922 [PMID: 22956071 DOI: 10.1245/s10434-012-2646-2]
  - 16 **Mizuno S**, Kato H, Azumi Y, Kishiwada M, Hamada T, Usui M, Sakurai H, Tabata M, Shimpo H, Isaji S. Total vascular hepatic exclusion for tumor resection: a new approach to the intrathoracic inferior vena cava through the abdominal cavity by cutting the diaphragm vertically without cutting the pericardium. *J Hepatobiliary Pancreat Sci* 2010; **17**: 197-202 [PMID: 20454910 DOI: 10.1007/s00534-009-0260-x]
  - 17 **Elias D**, Desruennes E, Lasser P. Prolonged intermittent clamping of the portal triad during hepatectomy. *Br J Surg* 1991; **78**: 42-44 [PMID: 1998862 DOI: 10.1002/bjs.1800780115]
  - 18 **Zhang EL**, Liang BY, Chen XP, Huang ZY. Severity of liver cirrhosis: a key role in the selection of surgical modality for Child-Pugh A hepatocellular carcinoma. *World J Surg Oncol* 2015; **13**: 148 [PMID: 25879526 DOI: 10.1186/s12957-015-0567-9]
  - 19 **Zhang YF**, Wei W, Guo ZX, Wang JH, Shi M, Guo RP. Hepatic resection versus transcatheter arterial chemoembolization for the treatment of hepatocellular carcinoma with hepatic vein tumor thrombus. *Jpn J Clin Oncol* 2015; **45**: 837-843 [PMID: 26079139 DOI: 10.1093/jjco/hyv089]
  - 20 **Llovet JM**, Brú C, Bruix J. Prognosis of hepatocellular carcinoma: the BCLC staging classification. *Semin Liver Dis* 1999; **19**: 329-338 [PMID: 10518312 DOI: 10.1055/s-2007-1007122]
  - 21 **Okada S**. How to manage hepatic vein tumour thrombus in hepatocellular carcinoma. *J Gastroenterol Hepatol* 2000; **15**: 346-348 [PMID: 10824876 DOI: 10.1046/j.1440-1746.2000.02151.x]
  - 22 **Wang Y**, Ma L, Yuan Z, Zheng J, Li W. Percutaneous thermal ablation combined with TACE versus TACE monotherapy in the treatment for liver cancer with hepatic vein tumor thrombus: A retrospective study. *PLoS One* 2018; **13**: e0201525 [PMID: 30063737 DOI: 10.1371/journal.pone.0201525]
  - 23 **Liu CL**, Fan ST. Nonresectional therapies for hepatocellular carcinoma. *Am J Surg* 1997; **173**: 358-365 [PMID: 9136797 DOI: 10.1016/S0002-9610(96)00384-4]
  - 24 **Chan SL**, Chong CC, Chan AW, Poon DM, Chok KS. Management of hepatocellular carcinoma with portal vein tumor thrombosis: Review and update at 2016. *World J Gastroenterol* 2016; **22**: 7289-7300 [PMID: 27621575 DOI: 10.3748/wjg.v22.i32.7289]
  - 25 **Kudo M**, Matsui O, Izumi N, Iijima H, Kadoya M, Imai Y, Okusaka T, Miyayama S, Tsuchiya K, Ueshima K, Hiraoka A, Ikeda M, Ogasawara S, Yamashita T, Minami T, Yamakado K; Liver Cancer Study Group of Japan. JSH Consensus-Based Clinical Practice Guidelines for the Management of Hepatocellular Carcinoma: 2014 Update by the Liver Cancer Study Group of Japan. *Liver Cancer* 2014; **3**: 458-468 [PMID: 26280007 DOI: 10.1159/000343875]
  - 26 **Xie DY**, Ren ZG, Zhou J, Fan J, Gao Q. 2019 Chinese clinical guidelines for the management of hepatocellular carcinoma: updates and insights. *Hepatobiliary Surg Nutr* 2020; **9**: 452-463 [PMID: 32832496 DOI: 10.21037/hbsn-20-480]
  - 27 **Chung YH**, Song IH, Song BC, Lee GC, Koh MS, Yoon HK, Lee YS, Sung KB, Suh DJ. Combined therapy consisting of intraarterial cisplatin infusion and systemic interferon-alpha for hepatocellular carcinoma patients with major portal vein thrombosis or distant metastasis. *Cancer* 2000; **88**: 1986-1991 [PMID: 10813709]
  - 28 **Ando E**, Tanaka M, Yamashita F, Kuromatsu R, Yutani S, Fukumori K, Sumie S, Yano Y, Okuda K, Sata M. Hepatic arterial infusion chemotherapy for advanced hepatocellular carcinoma with portal vein tumor thrombosis: analysis of 48 cases. *Cancer* 2002; **95**: 588-595 [PMID: 12209752 DOI: 10.1002/cncr.10694]
  - 29 **Liu M**, Shi J, Mou T, Wang Y, Wu Z, Shen A. Systematic review of hepatic arterial infusion chemotherapy versus sorafenib in patients with hepatocellular carcinoma with portal vein tumor



- thrombosis. *J Gastroenterol Hepatol* 2020; **35**: 1277-1287 [PMID: [32052876](#) DOI: [10.1111/jgh.15010](#)]
- 30 **Ahn YE**, Suh SJ, Yim HJ, Seo YS, Yoon EL, Kim TH, Lee YS, Yim SY, Kim HR, Kang SH, Jung YK, Kim JH, Yeon JE, Um SH, Byun KS. Comparison of Sorafenib versus Hepatic Arterial Infusion Chemotherapy-Based Treatment for Advanced Hepatocellular Carcinoma with Portal Vein Tumor Thrombosis. *Gut Liver* 2021; **15**: 284-294 [PMID: [32307975](#) DOI: [10.5009/gnl19367](#)]
  - 31 **Sung PS**, Yang K, Bae SH, Oh JS, Chun HJ, Nam HC, Jang JW, Choi JY, Yoon SK. Reduction of Intrahepatic Tumour by Hepatic Arterial Infusion Chemotherapy Prolongs Survival in Hepatocellular Carcinoma. *Anticancer Res* 2019; **39**: 3909-3916 [PMID: [31262920](#) DOI: [10.21873/anticancer.13542](#)]
  - 32 **Uka K**, Aikata H, Takaki S, Miki D, Kawaoka T, Jeong SC, Takahashi S, Toyota N, Ito K, Chayama K. Pretreatment predictor of response, time to progression, and survival to intraarterial 5-fluorouracil/interferon combination therapy in patients with advanced hepatocellular carcinoma. *J Gastroenterol* 2007; **42**: 845-853 [PMID: [17940838](#) DOI: [10.1007/s00535-007-2099-8](#)]
  - 33 **Uka K**, Aikata H, Takaki S, Miki D, Jeong SC, Hiramatsu A, Kodama H, Shirakawa H, Kawakami Y, Takahashi S, Toyota N, Ito K, Chayama K. Similar effects of recombinant interferon-alpha-2b and natural interferon-alpha when combined with intra-arterial 5-fluorouracil for the treatment of advanced hepatocellular carcinoma. *Liver Int* 2007; **27**: 1209-1216 [PMID: [17919232](#) DOI: [10.1111/j.1478-3231.2007.01554.x](#)]
  - 34 **Nouso K**, Miyahara K, Uchida D, Kuwaki K, Izumi N, Omata M, Ichida T, Kudo M, Ku Y, Kokudo N, Sakamoto M, Nakashima O, Takayama T, Matsui O, Matsuyama Y, Yamamoto K; Liver Cancer Study Group of Japan. Effect of hepatic arterial infusion chemotherapy of 5-fluorouracil and cisplatin for advanced hepatocellular carcinoma in the Nationwide Survey of Primary Liver Cancer in Japan. *Br J Cancer* 2013; **109**: 1904-1907 [PMID: [24008659](#) DOI: [10.1038/bjc.2013.542](#)]
  - 35 **Murakami E**, Aikata H, Miyaki D, Nagaoki Y, Katamura Y, Kawaoka T, Takaki S, Hiramatsu A, Waki K, Takahashi S, Kimura T, Kenjo M, Nagata Y, Ishikawa M, Kakizawa H, Awai K, Chayama K. Hepatic arterial infusion chemotherapy using 5-fluorouracil and systemic interferon- $\alpha$  for advanced hepatocellular carcinoma in combination with or without three-dimensional conformal radiotherapy to venous tumor thrombosis in hepatic vein or inferior vena cava. *Hepatol Res* 2012; **42**: 442-453 [PMID: [22176468](#) DOI: [10.1111/j.1872-034X.2011.00943.x](#)]
  - 36 **Kasai Y**, Hatano E, Seo S, Taura K, Yasuchika K, Okajima H, Kaido T, Uemoto S. Proposal of selection criteria for operative resection of hepatocellular carcinoma with inferior vena cava tumor thrombus incorporating hepatic arterial infusion chemotherapy. *Surgery* 2017; **162**: 742-751 [PMID: [28705491](#) DOI: [10.1016/j.surg.2017.05.011](#)]
  - 37 **Rim CH**, Seong J. Application of radiotherapy for hepatocellular carcinoma in current clinical practice guidelines. *Radiat Oncol J* 2016; **34**: 160-167 [PMID: [27730805](#) DOI: [10.3857/roj.2016.01970](#)]
  - 38 **Klein J**, Dawson LA. Hepatocellular carcinoma radiation therapy: review of evidence and future opportunities. *Int J Radiat Oncol Biol Phys* 2013; **87**: 22-32 [PMID: [23219567](#) DOI: [10.1016/j.ijrobp.2012.08.043](#)]
  - 39 **Dawson LA**. Overview: Where does radiation therapy fit in the spectrum of liver cancer local-regional therapies? *Semin Radiat Oncol* 2011; **21**: 241-246 [PMID: [21939852](#) DOI: [10.1016/j.semradonc.2011.05.009](#)]
  - 40 **Komatsu S**, Fukumoto T, Demizu Y, Miyawaki D, Terashima K, Niwa Y, Mima M, Fujii O, Sasaki R, Yamada I, Hori Y, Hishikawa Y, Abe M, Ku Y, Murakami M. The effectiveness of particle radiotherapy for hepatocellular carcinoma associated with inferior vena cava tumor thrombus. *J Gastroenterol* 2011; **46**: 913-920 [PMID: [21516295](#) DOI: [10.1007/s00535-011-0398-6](#)]
  - 41 **Duan F**, Yu W, Wang Y, Liu FY, Song P, Wang ZJ, Yan JY, Yuan K, Wang MQ. Trans-arterial chemoembolization and external beam radiation therapy for treatment of hepatocellular carcinoma with a tumor thrombus in the inferior vena cava and right atrium. *Cancer Imaging* 2015; **15**: 7 [PMID: [26007646](#) DOI: [10.1186/s40644-015-0043-3](#)]
  - 42 **Igaki H**, Nakagawa K, Shiraishi K, Shiina S, Kokudo N, Terahara A, Yamashita H, Sasano N, Omata M, Ohtomo K. Three-dimensional conformal radiotherapy for hepatocellular carcinoma with inferior vena cava invasion. *Jpn J Clin Oncol* 2008; **38**: 438-444 [PMID: [18495749](#) DOI: [10.1093/jjco/hyn038](#)]
  - 43 **Xi M**, Zhang L, Zhao L, Li QQ, Guo SP, Feng ZZ, Deng XW, Huang XY, Liu MZ. Effectiveness of stereotactic body radiotherapy for hepatocellular carcinoma with portal vein and/or inferior vena cava tumor thrombosis. *PLoS One* 2013; **8**: e63864 [PMID: [23737955](#) DOI: [10.1371/journal.pone.0063864](#)]
  - 44 **Hou JZ**, Zeng ZC, Zhang JY, Fan J, Zhou J, Zeng MS. Influence of tumor thrombus location on the outcome of external-beam radiation therapy in advanced hepatocellular carcinoma with macrovascular invasion. *Int J Radiat Oncol Biol Phys* 2012; **84**: 362-368 [PMID: [22381903](#) DOI: [10.1016/j.ijrobp.2011.12.024](#)]
  - 45 **Li J**, Hou Y, Cai XB, Liu B. Sorafenib after resection improves the outcome of BCLC stage C hepatocellular carcinoma. *World J Gastroenterol* 2016; **22**: 4034-4040 [PMID: [27099447](#) DOI: [10.3748/wjg.v22.i15.4034](#)]
  - 46 **Llovet JM**, Ricci S, Mazzaferro V, Hilgard P, Gane E, Blanc JF, de Oliveira AC, Santoro A, Raoul JL, Forner A, Schwartz M, Porta C, Zeuzem S, Bolondi L, Greten TF, Galle PR, Seitz JF, Borbath I, Häussinger D, Giannaris T, Shan M, Moscovici M, Voliotis D, Bruix J; SHARP Investigators Study Group. Sorafenib in advanced hepatocellular carcinoma. *N Engl J Med* 2008; **359**: 378-390 [PMID: [18738367](#) DOI: [10.1056/NEJMoa0706137](#)]

- 18650514 DOI: [10.1056/NEJMoa0708857](https://doi.org/10.1056/NEJMoa0708857)]
- 47 **Cheng AL**, Kang YK, Chen Z, Tsao CJ, Qin S, Kim JS, Luo R, Feng J, Ye S, Yang TS, Xu J, Sun Y, Liang H, Liu J, Wang J, Tak WY, Pan H, Burock K, Zou J, Voliotis D, Guan Z. Efficacy and safety of sorafenib in patients in the Asia-Pacific region with advanced hepatocellular carcinoma: a phase III randomised, double-blind, placebo-controlled trial. *Lancet Oncol* 2009; **10**: 25-34 [PMID: [19095497](https://pubmed.ncbi.nlm.nih.gov/19095497/) DOI: [10.1016/S1470-2045\(08\)70285-7](https://doi.org/10.1016/S1470-2045(08)70285-7)]
  - 48 **Huang Y**, Zhang Z, Zhou Y, Yang J, Hu K, Wang Z. Should we apply sorafenib in hepatocellular carcinoma patients with microvascular invasion after curative hepatectomy? *Onco Targets Ther* 2019; **12**: 541-548 [PMID: [30666133](https://pubmed.ncbi.nlm.nih.gov/30666133/) DOI: [10.2147/OTT.S187357](https://doi.org/10.2147/OTT.S187357)]
  - 49 **Kudo M**, Finn RS, Qin S, Han KH, Ikeda K, Piscaglia F, Baron A, Park JW, Han G, Jassem J, Blanc JF, Vogel A, Komov D, Evans TRJ, Lopez C, Dutkus C, Guo M, Saito K, Kraljevic S, Tamai T, Ren M, Cheng AL. Lenvatinib versus sorafenib in first-line treatment of patients with unresectable hepatocellular carcinoma: a randomised phase 3 non-inferiority trial. *Lancet* 2018; **391**: 1163-1173 [PMID: [29433850](https://pubmed.ncbi.nlm.nih.gov/29433850/) DOI: [10.1016/S0140-6736\(18\)30207-1](https://doi.org/10.1016/S0140-6736(18)30207-1)]
  - 50 **Kudo M**, Ueshima K, Chan S, Minami T, Chishina H, Aoki T, Takita M, Hagiwara S, Minami Y, Ida H, Takenaka M, Sakurai T, Watanabe T, Morita M, Ogawa C, Wada Y, Ikeda M, Ishii H, Izumi N, Nishida N. Lenvatinib as an Initial Treatment in Patients with Intermediate-Stage Hepatocellular Carcinoma Beyond Up-To-Seven Criteria and Child-Pugh A Liver Function: A Proof-Of-Concept Study. *Cancers (Basel)* 2019; **11** [PMID: [31370183](https://pubmed.ncbi.nlm.nih.gov/31370183/) DOI: [10.3390/cancers11081084](https://doi.org/10.3390/cancers11081084)]
  - 51 **Rao Q**, Li M, Xu W, Pang K, Guo X, Wang D, Liu J, Guo W, Zhang Z. Clinical benefits of PD-1/PD-L1 inhibitors in advanced hepatocellular carcinoma: a systematic review and meta-analysis. *Hepatol Int* 2020; **14**: 765-775 [PMID: [32572818](https://pubmed.ncbi.nlm.nih.gov/32572818/) DOI: [10.1007/s12072-020-10064-8](https://doi.org/10.1007/s12072-020-10064-8)]
  - 52 **Pardee AD**, Butterfield LH. Immunotherapy of hepatocellular carcinoma: Unique challenges and clinical opportunities. *Oncoimmunology* 2012; **1**: 48-55 [PMID: [22720211](https://pubmed.ncbi.nlm.nih.gov/22720211/) DOI: [10.4161/onci.1.1.18344](https://doi.org/10.4161/onci.1.1.18344)]
  - 53 **Kudo M**. Immune Checkpoint Inhibition in Hepatocellular Carcinoma: Basics and Ongoing Clinical Trials. *Oncology* 2017; **92** Suppl 1: 50-62 [PMID: [28147363](https://pubmed.ncbi.nlm.nih.gov/28147363/) DOI: [10.1159/000451016](https://doi.org/10.1159/000451016)]



Published by **Baishideng Publishing Group Inc**  
7041 Koll Center Parkway, Suite 160, Pleasanton, CA 94566, USA

**Telephone:** +1-925-3991568

**E-mail:** [bpgoffice@wjgnet.com](mailto:bpgoffice@wjgnet.com)

**Help Desk:** <https://www.f6publishing.com/helpdesk>

<https://www.wjgnet.com>

