

World Journal of *Clinical Cases*

World J Clin Cases 2024 January 26; 12(3): 466-670



Contents

Thrice Monthly Volume 12 Number 3 January 26, 2024

EDITORIAL

- 466 Is medical management useful in Moyamoya disease?
Muengtaweepongsa S, Panpattanakul V
- 474 Metabologenomics and network pharmacology to understand the molecular mechanism of cancer research
Tutar Y

ORIGINAL ARTICLE

Case Control Study

- 479 Significance of oxidative stress and antioxidant capacity tests as biomarkers of premature ovarian insufficiency: A case control study
Kakinuma K, Kakinuma T
- 488 Colorectal resections for malignancy: A pilot study comparing conventional *vs* freehand robot-assisted laparoscopic colectomy
Cawich SO, Plummer JM, Griffith S, Naraynsingh V

Retrospective Study

- 495 Ultrasound diagnosis of congenital Morgagni hernias: Ten years of experience at two Chinese centers
Shi HQ, Chen WJ, Yin Q, Zhang XH

Observational Study

- 503 Genetic investigation of the ubiquitin-protein ligase E3A gene as putative target in Angelman syndrome
Manoubi W, Mahdouani M, Hmida D, Kdissa A, Rouissi A, Turki I, Gueddiche N, Soyah N, Saad A, Bouwkamp C, Elgersma Y, Mougou-Zerelli S, Gribaa M

Prospective Study

- 517 Benefit in physical function and quality of life to nonsurgical treatment of varicose veins: Pilot study
Kim GM, Kim B, Jang M, Park JH, Bae M, Lee CW, Kim JW, Huh U

SYSTEMATIC REVIEWS

- 525 Emerging roles of microRNAs as diagnostics and potential therapeutic interest in type 2 diabetes mellitus
Shrivastav D, Singh DD

META-ANALYSIS

- 538 Impact of body mass index on adverse kidney events in diabetes mellitus patients: A systematic-review and meta-analysis
Wan JF, Chen Y, Yao TH, Wu YZ, Dai HZ

CASE REPORT

- 551** Epithelioid malignant peripheral nerve sheath tumor of the bladder and concomitant urothelial carcinoma: A case report
Ozden SB, Simsekoglu MF, Sertbudak I, Demirdag C, Gurses I
- 560** Simultaneous type III congenital esophageal atresia and patent ductus arteriosus in a low-weight patient: A case report
Ma YY, Chen JR, Yang SW, Wang SY, Cao X, Wu J
- 565** Marginal zone lymphoma with severe rashes: A case report
Bai SJ, Geng Y, Gao YN, Zhang CX, Mi Q, Zhang C, Yang JL, He SJ, Yan ZY, He JX
- 575** Inetetamab combined with pyrotinib and chemotherapy in the treatment of breast cancer brain metastasis: A case report
Dou QQ, Sun TT, Wang GQ, Tong WB
- 582** Adult rhabdomyosarcoma combined with acute myeloid leukemia: A case report
Zheng L, Zhang FJ
- 587** Special electromyographic features in a child with paramyotonia congenita: A case report and review of literature
Yi H, Liu CX, Ye SX, Liu YL
- 596** Removal of a guide-wire sliding into abdominal cavity *via* transgastric natural orifice transluminal endoscopic surgery: A case report
Chen SJ, Zhang DY, Lv YT, Bai FH
- 601** Polyneuropathy, organomegaly, endocrinopathy, M-protein, skin changes syndrome with dilated cardiomyopathy: A case report
Li JR, Feng LY, Li JW, Liao Y, Liu FQ
- 607** Ischemic colitis induced by a platelet-raising capsule: A case report
Wang CL, Si ZK, Liu GH, Chen C, Zhao H, Li L
- 616** Brain abscess from oral microbiota approached by metagenomic next-generation sequencing: A case report and review of literature
Zhu XM, Dong CX, Xie L, Liu HX, Hu HQ
- 623** Carrimycin in the treatment of acute promyelocytic leukemia combined with pulmonary tuberculosis: A case report
Yang FY, Shao L, Su J, Zhang ZM
- 630** Rare esophageal carcinoma-primary adenoid cystic carcinoma of the esophagus: A case report
Geng LD, Li J, Yuan L, Du XB
- 637** Early selective enteral feeding in treatment of acute pancreatitis: A case report
Kashintsev AA, Anisimov SV, Nadeeva A, Proutski V

- 643** Pathological diagnosis and immunohistochemical analysis of giant retrosternal goiter in the elderly: A case report
Meng YC, Wu LS, Li N, Li HW, Zhao J, Yan J, Li XQ, Li P, Wei JQ
- 650** Cerebral syphilitic gumma misdiagnosed as brain abscess: A case report
Mu LK, Cheng LF, Ye J, Zhao MY, Wang JL
- 657** Primary anaplastic lymphoma kinase-positive large B-cell lymphoma of the left bulbar conjunctiva: A case report
Guo XH, Li CB, Cao HH, Yang GY
- 665** Porocarcinoma in a palm reconstructed with a full thickness skin graft: A case report
Lim SB, Kwon KY, Kim H, Lim SY, Koh IC

ABOUT COVER

Peer Reviewer of *World Journal of Clinical Cases*, Kazuhiro Katada, MD, PhD, Assistant Professor, Molecular Gastroenterology and Hepatology, Graduate School of Medical Science, Kyoto Prefectural University of Medicine, Kyoto 6028566, Japan. katada@koto.kpu-m.ac.jp

AIMS AND SCOPE

The primary aim of *World Journal of Clinical Cases* (WJCC, *World J Clin Cases*) is to provide scholars and readers from various fields of clinical medicine with a platform to publish high-quality clinical research articles and communicate their research findings online.

WJCC mainly publishes articles reporting research results and findings obtained in the field of clinical medicine and covering a wide range of topics, including case control studies, retrospective cohort studies, retrospective studies, clinical trials studies, observational studies, prospective studies, randomized controlled trials, randomized clinical trials, systematic reviews, meta-analysis, and case reports.

INDEXING/ABSTRACTING

The WJCC is now abstracted and indexed in Science Citation Index Expanded (SCIE, also known as SciSearch®), Journal Citation Reports/Science Edition, Current Contents®/Clinical Medicine, PubMed, PubMed Central, Reference Citation Analysis, China Science and Technology Journal Database, and Superstar Journals Database. The 2023 Edition of Journal Citation Reports® cites the 2022 impact factor (IF) for WJCC as 1.1; IF without journal self cites: 1.1; 5-year IF: 1.3; Journal Citation Indicator: 0.26; Ranking: 133 among 167 journals in medicine, general and internal; and Quartile category: Q4.

RESPONSIBLE EDITORS FOR THIS ISSUE

Production Editor: Zi-Hang Xu, Production Department Director: Xiang Li, Editorial Office Director: Jin-Lei Wang.

NAME OF JOURNAL

World Journal of Clinical Cases

ISSN

ISSN 2307-8960 (online)

LAUNCH DATE

April 16, 2013

FREQUENCY

Thrice Monthly

EDITORS-IN-CHIEF

Bao-Gan Peng, Salim Surani, Jerzy Tadeusz Chudek, George Kontogeorgos, Maurizio Serati

EDITORIAL BOARD MEMBERS

<https://www.wjgnet.com/2307-8960/editorialboard.htm>

PUBLICATION DATE

January 26, 2024

COPYRIGHT

© 2024 Baishideng Publishing Group Inc

INSTRUCTIONS TO AUTHORS

<https://www.wjgnet.com/bpg/gerinfo/204>

GUIDELINES FOR ETHICS DOCUMENTS

<https://www.wjgnet.com/bpg/GerInfo/287>

GUIDELINES FOR NON-NATIVE SPEAKERS OF ENGLISH

<https://www.wjgnet.com/bpg/gerinfo/240>

PUBLICATION ETHICS

<https://www.wjgnet.com/bpg/GerInfo/288>

PUBLICATION MISCONDUCT

<https://www.wjgnet.com/bpg/gerinfo/208>

ARTICLE PROCESSING CHARGE

<https://www.wjgnet.com/bpg/gerinfo/242>

STEPS FOR SUBMITTING MANUSCRIPTS

<https://www.wjgnet.com/bpg/GerInfo/239>

ONLINE SUBMISSION

<https://www.f6publishing.com>



Ischemic colitis induced by a platelet-raising capsule: A case report

Chen-Lu Wang, Ze-Kun Si, Guo-Hong Liu, Chen Chen, Hui Zhao, Lei Li

Specialty type: Medicine, research and experimental

Provenance and peer review: Unsolicited article; Externally peer reviewed.

Peer-review model: Single blind

Peer-review report's scientific quality classification

Grade A (Excellent): 0
Grade B (Very good): B
Grade C (Good): 0
Grade D (Fair): 0
Grade E (Poor): 0

P-Reviewer: Rezus E, Romania

Received: October 12, 2023

Peer-review started: October 12, 2023

First decision: December 6, 2023

Revised: December 9, 2023

Accepted: January 4, 2024

Article in press: January 4, 2024

Published online: January 26, 2024



Chen-Lu Wang, Ze-Kun Si, Lei Li, The Affiliated Hospital of Shandong Second Medical University, School of Clinical Medicine, Shandong Second Medical University, Weifang 261000, Shandong Province, China

Guo-Hong Liu, Chen Chen, Hui Zhao, Department of Gastroenterology, The Affiliated Hospital of Shandong Second Medical University, Weifang 261000, Shandong Province, China

Corresponding author: Lei Li, Doctor, Chief Physician, Affiliated Hospital of Shandong Second Medical University, School of Clinical Medicine, Shandong Second Medical University, No. 2428 Yuhe Road, Kuiwen District, Weifang 261000, Shandong Province, China.
htlilei@163.com

Abstract

BACKGROUND

Ischemic colitis (IC) is also known as colon ischemia and is caused by colon vascular occlusion or nonocclusion, which results in a reduced blood supply to the colon and is not significant enough to maintain the metabolic function of cells, leading to intestinal wall ischemia. Its main symptoms include abdominal pain, diarrhea, and bloody stool. In severe cases, intestinal gangrene, peritonitis, intestinal stenosis and even intestinal obstruction may occur. IC induced by long-term use of certain special drugs is relatively rare in clinical practice. This article describes the clinical diagnosis and treatment of a typical case and provides a new treatment idea for the treatment of IC.

CASE SUMMARY

The patient was admitted to the hospital with "abdominal pain for half a month and bloody stool with mucous and pus for 3 d" and was diagnosed with "IC". Symptomatic and supportive treatment, such as antibiotics (levofloxacin), acid inhibition and stomach protection, fluid replenishment, and intravenous nutrition, was given. The patient's colonic ulcers were considered to be related to the oral administration of platelet (PLT)-raising capsules; the patient was asked to stop PLT-raising drugs for selective review *via* colonoscopy, and antibiotics and mesalazine enteric-coated tablets were stopped. Under the guidance of hematology consultation, 60 mg of methylprednisolone was given in combination with PLT infusion to increase the PLT. After treatment, the patient's condition stabilized, the patient's stool turned yellow, the patient's symptoms improved, and the patient was allowed to leave the hospital.

CONCLUSION

PLT-raising capsules can lead to IC, so clinicians should have a full understanding of the application of these drugs in the treatment of various causes of thrombocyt-

openia, weigh the advantages and disadvantages, and observe patients closely.

Key Words: Platelet-raising capsule; Ischemic colitis; Drug-related; Colonic ulcer; Case report

©The Author(s) 2024. Published by Baishideng Publishing Group Inc. All rights reserved.

Core Tip: Ischemic colitis (IC) caused by a platelet (PLT)-raising capsule is relatively rare in the clinic. We reported the clinical diagnosis and treatment of a patient with IC caused by the use of a PLT-raising capsule and summarized the clinical diagnosis and treatment characteristics of these patients by reviewing the relevant literature.

Citation: Wang CL, Si ZK, Liu GH, Chen C, Zhao H, Li L. Ischemic colitis induced by a platelet-raising capsule: A case report. *World J Clin Cases* 2024; 12(3): 607-615

URL: <https://www.wjgnet.com/2307-8960/full/v12/i3/607.htm>

DOI: <https://dx.doi.org/10.12998/wjcc.v12.i3.607>

INTRODUCTION

Ischemic colitis (IC) is also known as colon ischemia (CI) and is caused by colon vascular occlusion or nonocclusion, which results in a reduced blood supply to the colon; this process is not significant enough to maintain the metabolic function of cells, leading to intestinal wall ischemia[1]. Its main symptoms include abdominal pain, diarrhea, and bloody stool. In severe cases, intestinal gangrene, peritonitis, intestinal stenosis and even intestinal obstruction may occur[2,3]. The pathogenesis of this disease has not been extensively studied, but increased clotting ability has been recognized as an important factor in the pathogenesis of IC[4]. People older than 60 years (especially women) who suffer from certain underlying diseases, such as cardiovascular and cerebrovascular diseases, diabetes, and shock, are the most prone to colon IC. The lesions can involve any segment of the colon, among which the left half of the colon, such as the sigmoid colon, descending colon and spleen region, is the most common site of lesions. This is because the region south of the sigmoid colon is the "watershed region" of the colonic blood supply, where vascular dysplasia may easily cause ischemia. In addition, the left half of the colon is supplied by the inferior mesenteric artery, which is at an acute angle to the abdominal aorta and affects blood perfusion. The rectum is supplied by both the inferior mesenteric artery and the rectal artery, and ischemia is rare. Therefore, the IC lesions were mainly in the left colon, and most of them were of the first pass type. The disease is relatively mild and can be cured after conservative medical treatment, so the prognosis is favorable[5-7]. Once ischemia improves, the patient's condition can recover in a relatively short time, and this condition can be distinguished from other types of enteritis[5-7], such as infectious colitis, inflammatory bowel disease, pseudomembranous enteritis, diverticulitis, colon cancer, and acute mesenteric ischemia. Clinically, ischemic colitis can be divided into gangrene and nongangrene. The latter can also be subdivided into transient and chronic types.

Treatment for IC usually includes fasting, gastrointestinal decompression, intravenous nutritional support, improved circulation, fluid resuscitation, empirical use of antibiotics and other symptomatic supportive treatments, and attention should be given to the treatment of the primary disease. Most patients will experience improvements in clinical symptoms within 1 to 2 d, and patients with complications may require surgery. However, IC induced by long-term use of certain special drugs is relatively rare in clinical practice. This article describes the clinical diagnosis and treatment of a typical case and provides a new treatment idea for the treatment of ischemic colitis.

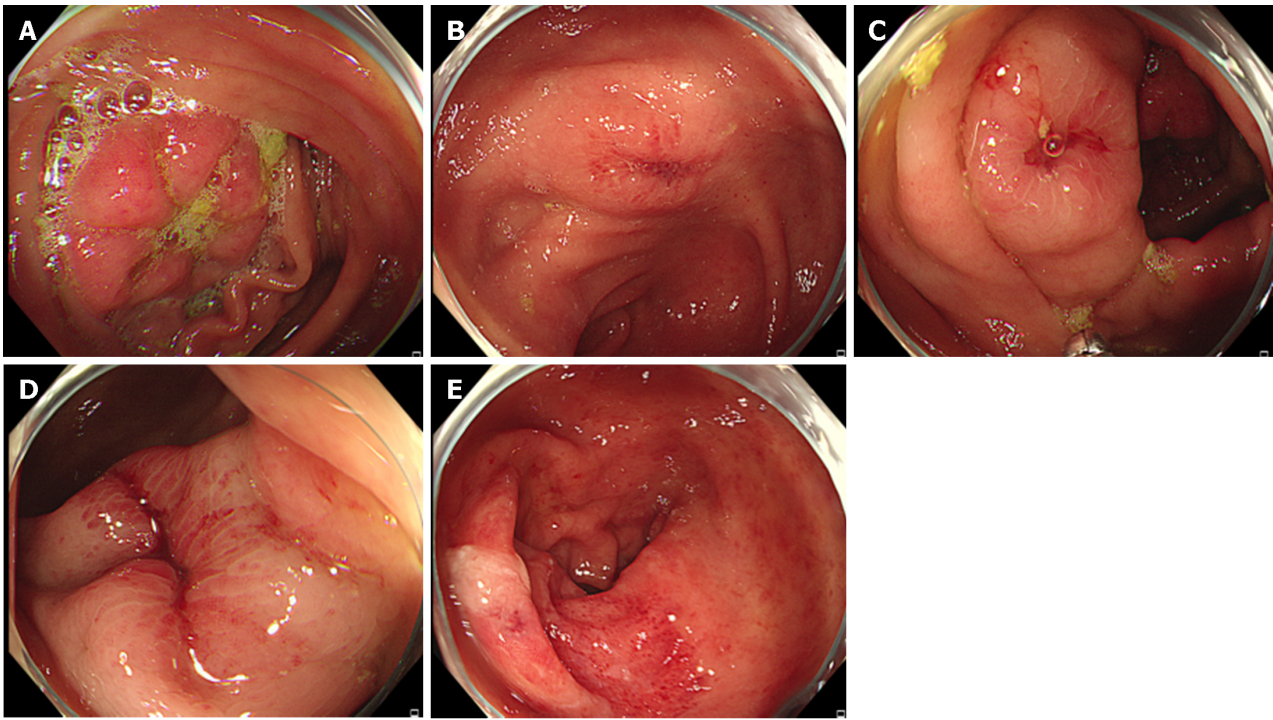
CASE PRESENTATION

Chief complaints

Abdominal pain for half a month and bloody stool with mucous and pus for 3 d.

History of present illness

Half a month prior, the patient had abdominal pain, mainly located in the lower abdomen, which was paroxysmal. Abdominal pain was felt before the patient passed stool and was relieved after passing stool. The stool was yellow and loose and was passed 7 times a day. Twelve days prior, the patient visited the outpatient department of our hospital for further diagnosis and treatment and was treated with oral "cefixime". The frequency of stool was reduced to 2 times per day, and the abdominal pain did not significantly improve. Three days prior, the patient developed bloody stool with pus and mucous 2-3 times a day and still had paroxysmal abdominal pain, no nausea, vomiting, acid reflux, heartburn, fear of cold, fever, arthralgia, dry mouth, and dry eyes. The patient visited the outpatient department of our hospital on June 28, 2021. Gastroenteroscopy revealed chronic nonatrophic gastritis with erosion, duodenal bulbitis, and multiple colonic ulcers (Figure 1).



DOI: 10.12998/wjcc.v12.i3.607 Copyright ©The Author(s) 2024.

Figure 1 Shows the colonoscopy of 2021-06-28. A: Flaky mucosal hyperemia and edema were observed in ileocecal region, accompanied by ulcer formation; B: The ascending colon is scattered with ulcers and surrounding mucous membrane flaky hyperemia and edema; C: The ascending colon is scattered with ulcers and surrounding mucous membrane flaky hyperemia and edema; D: A 3 cm long longitudinal ulcer was observed 65 cm from the anal margin, and the surrounding mucosa was hyperemia, edema and erosion; E: Rectum mucosa hyperemia edema, vascular texture blurred, multiple erosion and shallow ulcer formation.

History of past illness

The patient had a history of "primary immune thrombocytopenia (ITP)" for more than 3 years and was treated with drugs such as "caffeic acid tablets and platelet (PLT)-raising capsules". Three years prior, the patient was admitted to the Department of Gastroenterology of our hospital because of "abdominal pain and blood in the stool for 12 h". The whole-abdomen computed tomography (CT) scan showed the following: (1) Thickening and edema of the colon wall and possible inflammatory changes, which were recommended to be further examined if necessary in combination with clinical evaluation; (2) calcification of the right lobe of the liver; and (3) a small amount of fluid was present in the abdominal cavity. Mesenteric CT angiography (CTA) showed the following: (1) No obvious abnormalities in the mesenteric arteries or veins; (2) changes in the colon wall consistent with ischemic enteritis, which was recommended to be interpreted within a clinical context; and (3) a possible small amount of ascites. Gastroscopy showed chronic superficial gastritis. Colonoscopy revealed multiple colonic ulcers pending investigation. Colonoscopic pathology revealed the following: (1) (Descending colon) Mucosal chronic inflammation with multiple ulcers; (2) (ileocecal region) mucosal chronic inflammation with ulcers; and (3) (transverse colon) Mucosal chronic inflammation with ulcers. Also, acid-fast staining was (-). Symptomatic and supportive treatments, such as hemostasis, fluid rehydration, antibiotics, improvements in blood supply and regulation of the intestinal flora, were given. There was no reexamination *via* colonoscopy after discharge. The patient had previously undergone "gastric polyp" excision more than 10 years prior. The patient had "E viral hepatitis" for 3 years and was denied a history of hypertension, coronary heart disease, or diabetes. The patient had no history of tuberculosis or other infectious diseases and had a history of close contact. The patient's vaccination history was unknown. The patient had a history of blood transfusions. The patient had a trauma history. The patient denied any drug or food allergies.

Personal and family history

Personal history: The patient was born in their original place, lived a long time in Shandong, and denied a history of contact with epidemic areas, infected water, special chemicals or radiation. The patient had a history of smoking and drinking. **Marriage and childbearing history:** The patient was married at the age of 22, with a healthy spouse and one son. **Family history:** Healthy parents, 1 brother and 1 sister, all healthy. The patient had a history of genetic disease, infectious disease or similar diseases.

Physical examination

The physical exam was as follows: Temperature 36.2 °C, pulse: 97 beats/min, respiratory rate 18 breath cycles/min, blood pressure 110/90 mmHg, the patient is conscious, with normal mental status. The patient had no yellow staining of sclera, no palpebral conjunctival pallor, and no obvious abnormalities on cardiopulmonary physical examination. The patient

Table 1 Summary of laboratory results of patient

Date	Liver function lipid blood	kidney function glucose electrolyte	Blood routine	Coagulation function four +D dimer	PPD test	Antinuclear antibody
2021-06-29	Total bilirubin 22.3 $\mu\text{mol/L}$, direct bilirubin 7 $\mu\text{mol/L}$, high-density lipoprotein cholesterol 1.99 mmol/L , low-density lipoprotein cholesterol 3.57 mmol/L		Lymphocyte percentage 18.5%, neutrophil percentage 76.4%, platelet count $68 \times 10^9/\text{L}$	D-dimer 0.81 mg/L		
2021-07-03					Negative	Negative
2021-07-06			Lymphocyte percentage 11%, neutrophil percentage 83.5%, absolute lymphocyte value $0.8 \times 10^9/\text{L}$, platelet count $23 \times 10^9/\text{L}$			
2021-07-08			Platelet count was $12 \times 10^9/\text{L}$			
2021-07-12			Absolute monocyte value $0.8 \times 10^9/\text{L}$, red blood cells $4.22 \times 10^{12}/\text{L}$, hemoglobin 126 g/L , the mean hemoglobin concentration was 312 g/L , and the platelet count was $199 \times 10^9/\text{L}$			
2021-07-14			Platelet count $230 \times 10^9/\text{L}$			
2021-07-20			Platelet count was $81 \times 10^9/\text{L}$			
2021-07-23			Platelet count was $82 \times 10^9/\text{L}$			

PPD: Pure protein derivative.

had a flat and soft abdomen, no abdominal varicose veins and gastrointestinal type, and no tenderness or rebound pain. The liver and spleen were not palpable under the ribs, the patient had no masses, the patient had a negative Mofey's sign, there was no pain upon percussion in the areas of the liver and kidney, there were no voiced mobile sounds, and the bowel sounds were 4 times/min. No purpura or ecchymosis was observed.

Laboratory examinations

Total bilirubin was 22.3 $\mu\text{mol/L}$, direct bilirubin was 7 $\mu\text{mol/L}$, high-density lipoprotein cholesterol was 1.99 mmol/L , and low-density lipoprotein cholesterol was 3.57 mmol/L . Routine blood tests showed the following: +Hypersensitive C-reactive protein: Lymphocyte percentage 18.5%, neutrophil percentage 76.4%, and PLT count $68 \times 10^9/\text{L}$. Coagulation function was 4 + D-dimer: D-dimer 0.81 mg/L . The patient's Pure protein derivative (PPD) test was negative, and the patient's antinuclear antibody was negative (Table 1).

Imaging examinations

Pathology showed the following: (1) Chronic inflammation of the mucosa with superficial ulceration and eosinophils infiltrating the lamina propria; (2) (in the proximal ileocecal part of the ascending colon) mucosal chronic inflammation accompanied by acute inflammation, with scattered eosinophils infiltrating the lamina propria; (3) chronic mucosal inflammation accompanied by acute inflammation and superficial ulceration, with scattered eosinophils infiltrating the lamina propria; and (4) chronic inflammation of the mucosa (30 cm from the anus) 2021-06-28; (Table 2 and Figure 2A).

FINAL DIAGNOSIS

(1) IC was caused by PLT-raising capsule; (2) Colonic ulcers; (3) Colonic polyps; (4) Chronic nonatrophic gastritis with erosion; (5) Duodenoculitis; and (6) Primary ITP.

TREATMENT

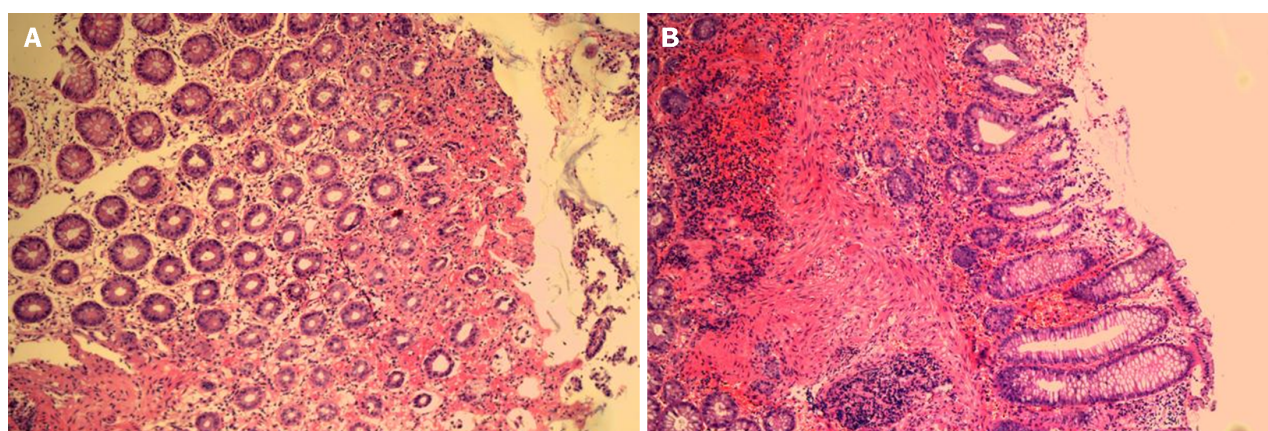
After admission, symptomatic and supportive treatments such as antibiotics (levofloxacin), acid inhibition and stomach protection, fluid replenishment, and intravenous nutrition were given.

The cause of the patient's multiple recurrent intestinal ulcers was unknown, and the pathology suggested ulcer formation with eosinophil infiltration. Eosinophilic gastroenteritis was further ruled out, and inflammatory bowel disease

Table 2 Summary of imaging examination results of patient

Date	Whole abdomen CT	Mesenteric CTA	Gastroscopy	Colonoscopy	Pathology
2018	Thickening and edema of the colon wall, and possible inflammatory changes, to be furthered examined if necessary, in combination with clinical evaluation; Calcification of right lobe of liver; Small amount of fluid in abdominal cavity	No obvious abnormalities in mesenteric arteries and veins; Colon wall changes, consistent with ischemic enteritis, to be interpreted within clinical context; Small amount of ascites?	Chronic superficial gastritis	Multiple colonic ulcers pending investigation	(Descending colon) mucosal chronic inflammation with multiple ulcers; (ileocecal region) mucosal chronic inflammation with ulcers; (transverse colon) mucosal chronic inflammation with ulcers. Added: Acid-fast staining (-)
2021-06-28			Chronic non-atrophic gastritis with erosion, duodenal bulbitis	Multiple colonic ulcers	Chronic inflammation of mucosa with superficial ulceration and eosinophils infiltrating the lamina propria; (in the proximal ileocecal part of the ascending colon) mucosal chronic inflammation accompanied by acute inflammation, with scattered eosinophils infiltrating the lamina propria; (65 cm from anus) chronic mucosal inflammation accompanied by acute inflammation and superficial ulceration, with scattered eosinophils infiltrating the lamina propria; chronic inflammation of mucosa (30 cm from anus)
2021-07-19				Colonic ulcer; Endoscopic forceps removal of colonic polyps	Tubular adenoma (50 cm from anal margin); Acute and chronic inflammation of mucosa with erosion (proximal ileocecal part of ascending colon)
2022-08-01				No obvious abnormality	

CTA: Computed tomography angiography; CT: Computed tomography.



DOI: 10.12998/wjcc.v12.i3.607 Copyright ©The Author(s) 2024.

Figure 2 Pathology results. A: Chronic mucosal inflammation accompanied by acute inflammation and superficial ulceration, with scattered eosinophils infiltrating the lamina propria. The hepatic encephalopathy (HE) dye $\times 40$ (2021-06-28); B: Acute and chronic inflammation of the mucosa with erosions (proximal ileocecal part of the ascending colon) was observed. The HE dye $\times 40$ (2021-07-19).

and other diseases were further ruled out. The patient was engaged in fox breeding, so it was necessary to further exclude the possibility of special types of infection. On July 3, 2021, the patient still had bloody stool with pus and mucous once a day, the patient's PPD test was negative, and the patient's antinuclear antibody test was negative. Mesalazine enteric-coated tablets were used for anti-inflammatory treatment, and Yunnan Baiyao was given orally for hemostasis. On July 7, 2021, the patient complained of 2-3 stools/d; the patient's stool was watery and had mucus, pus and blood; and the patient had no other discomfort. Blood routine review + reticulocyte count revealed the following: Lymphocyte percentage, 11%; neutrophil percentage, 83.5%; absolute lymphocyte count, $0.8 \times 10^9/L$; and PLT count, $23 \times 10^9/L$. The PLT count was significantly low, and caffeic acid tablets and PLT-raising capsules were given for PLT-raising therapy. The patient had watery stool, the number of stools was increased, and oral montmorillonite powder was given to stop the diarrhea. The patient had multiple intestinal ulcers. We considered whether the "primary ITP" was related to intestinal ulcers. The possibility of multiple intestinal ulcers caused by ITP was unlikely to be considered during hematology consultation. On July, 2021, our department has organized discussions on these difficult cases. According to the

Department of Immunology and Rheumatology, the patient's pathology suggested eosinophilia, which was caused by many factors, such as eosinophil granulomatous vasculitis. The patient had a normal eosinophil count and a normal blood profile, and lung (-), skin (-), and rheumatic disease results were not considered. The imaging department considered the patient's CT images to be unclear, the intestinal filling was not good, there were no enlarged lymph nodes, there was no fatty infiltration and no transmural inflammation, and there were no specific manifestations. Pathology revealed that the patient's acid-fast test was negative, with no specific manifestations. The Department of Infectious disease said the patient had no evidence of infection (no fever, normal blood routine, negative bacterial culture, low immunoglobulin E, or uncommon parasitic infections). The chief physician advised the patient to receive ITP, oral PLT capsule treatment, and treatment with a PLT capsule containing green Dai, which can cause intestinal ulcers. Many hematological diseases are complicated by intestinal ulcers, and ITP can manifest as immune system-related ulcers. Treatment: The drug was stopped, and low-dose hormone therapy was given. At present, the patient's colonic ulcer was considered to be related to the oral administration of PLT-raising capsules, the patient was asked to stop PLT-raising drugs for selective review *via* colonoscopy, and antibiotics and mesalazine enteric-coated tablets were stopped. Under the guidance of hematology consultation, 60 mg of methylprednisolone was given in combination with PLT infusion to promote PLT therapy.

On July 9, 2021, the patient had no additional blood in her stool but did have pain and discomfort in her lower abdomen. Scattered hemorrhagic spots could be observed on the skin. July 12, 2021, the patient had no abdominal pain or abdominal distension, and the patient passed stool once a day with no mucus, pus or blood. Routine blood test results revealed the following: Absolute monocyte count = $0.8 \times 10^9/L$, red blood cell count = $4.22 \times 10^{12}/L$, hemoglobin = 126 g/L, mean hemoglobin concentration = 312 g/L, and PLT count = $199 \times 10^9/L$. After treatment, the patient's symptoms were relieved, and there was no additional blood in the stool; the patient's PLT count was greater than before, and the patient's hormone concentration was reduced to 40 mg qd. On July 9, 2021, routine blood analysis revealed a PLT count of $230 \times 10^9/L$. The patient's PLT count increased significantly after hormone treatment. No hematochezia was found after discontinuation of the PLT-raising capsule, and the dose of hormone was reduced to 20 mg qd.

OUTCOME AND FOLLOW-UP

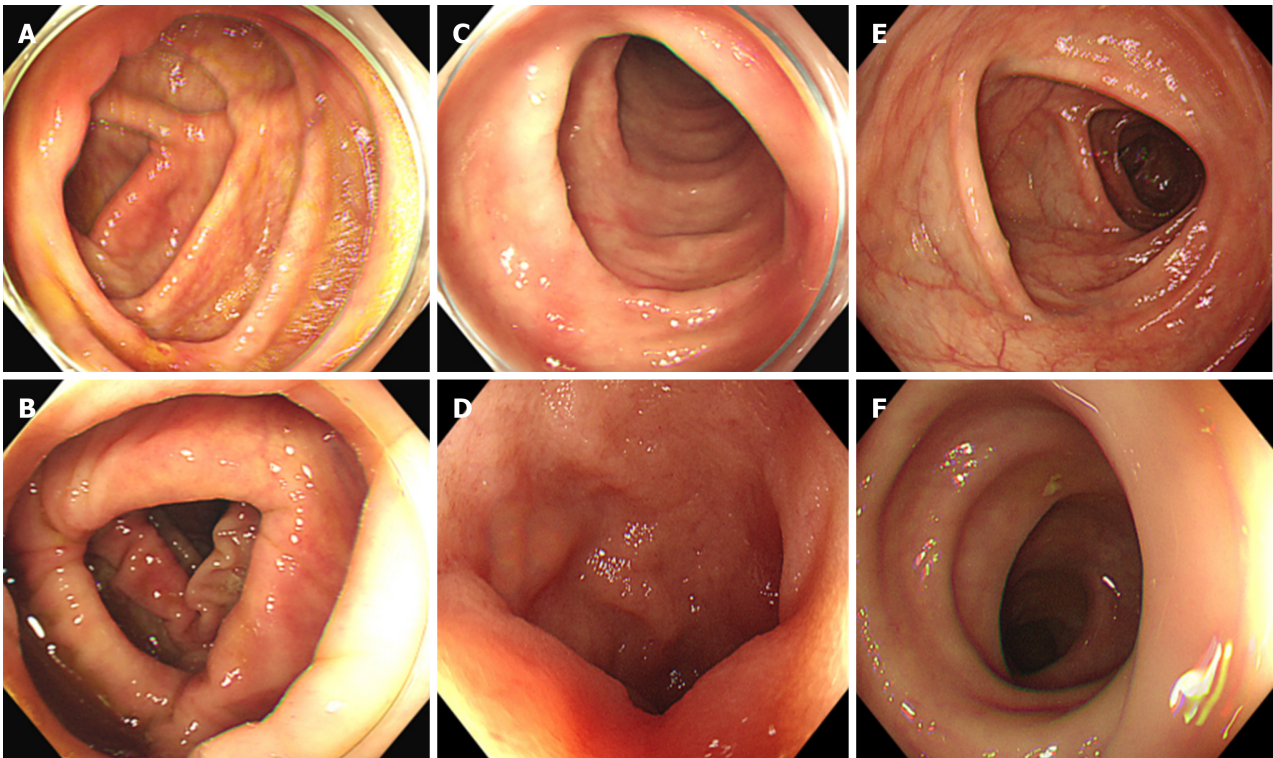
Endoscopic biopsy showed the following results: (1) Tubular adenoma (50 cm from the anal margin); and (2) acute and chronic inflammation of the mucosa with erosions (proximal ileocecal part of the ascending colon) was observed (2021-07-19; [Figure 2B](#)). On July 19, 2021, review colonoscopy showed the following: Colonic ulcer; endoscopic forceps removal of colonic polyps ([Figure 3A-C](#)). Reexamination colonoscopy of the patient showed significant improvement in the severity of the colonic ulcer, which was considered to be associated with the PLT-raising capsule. The patient's symptoms improved after symptomatic treatment, such as acid inhibition, nutritional support, hemostasis, PLT infusion, and hormone therapy, and the patient's PLT count was greater than before. The patient was discharged. The patient was told to have the tests for blood routine and coagulation function rechecked 3 d after discharge, to return to the hematology department, to adjust the hormone dosage under the guidance of specialists, and to not reduce or stop the medication without consulting with the doctor. The patient was monitored for any changes in stool color, her gastroenteroscopy was reviewed regularly, and she had follow up for her discomfort.

After discharge, the patient did not use a PLT-raising capsule again and had no abdominal pain, diarrhea, blood in the stool or other symptoms. On August 1, 2022, a review of the colonoscopy of the patient at our hospital showed no obvious abnormalities ([Figure 3D-F](#)).

DISCUSSION

The onset of this patient was acute, with abdominal pain, diarrhea, and hematochezia. Colonoscopy revealed multiple ulcers in the colon. The clinical symptoms improved rapidly after the discontinuation of the PLT-raising capsule, while continued use of the drug led to worsening of the disease. The patient had a similar history 3 years prior, and whole-abdominal CT showed thickening and edema of the colon wall. Inflammatory changes were considered. Mesenteric CTA showed: (1) No obvious abnormalities in the mesenteric arteries or veins; and (2) changes in the colon and intestinal wall were consistent with ischemic enteritis. Colonoscopy revealed multiple ulcers in the colon. It was reported that ischemic colitis occurs in patients vaccinated with a second dose of the coronavirus disease 2019 inactivated vaccine[8]. The patient presented with abdominal pain after vaccine injection. It was considered whether this difference was related to vaccination. However, the patient had a similar medical history 3 years prior to admission, the patient's clinical symptoms improved rapidly after the discontinuation of the PLT-raising capsule, and the patient did not use a PLT-raising capsule again after discharge. Reexamination *via* colonoscopy at our hospital on August 1, 2022 showed no obvious abnormalities. Considering the above factors, a diagnosis of IC caused by a PLT-raising capsule was established.

Drug-related IC can occur due to the use of disease-causing drugs, and the clinical symptoms and auxiliary findings are consistent with the characteristics of ischemic lesions in the colon[9]. Clinical symptoms can rapidly improve after the discontinuation of pathogenic drugs, while continuous use of these drugs leads to continuous progression of the disease, which is a unique clinical feature of drug-related IC. Recent studies have shown that the incidence of right colon lesions in patients receiving drug-related IC is greater than that in patients receiving IC[10]. Thus, patients with drug-related IC may have a greater incidence of general abdominal pain or right abdominal pain than patients with IC, which primarily occurs on the left side.



DOI: 10.12998/wjcc.v12.i3.607 Copyright ©The Author(s) 2024.

Figure 3 The colonoscopy changes after treatment. A: There was an ulcer formed in the proximal ileocecal part of the ascending colon, about 0.6 cm in size, covered with white moss, and surrounding mucosa hyperemia and edema on 2021-07-19; B: No significant abnormalities were observed in the colorectal by endoscopy on 2021-07-19; C: No significant abnormalities were observed in the colorectal by endoscopy on 2021-07-19; D: No significant abnormalities were observed in the colorectal by endoscopy on 2022-08-01; E: No significant abnormalities were observed in the colorectal by endoscopy on 2022-08-01; F: No significant abnormalities were observed in the colorectal by endoscopy on 2022-08-01.

In terms of diagnosis, laboratory tests revealed elevated peripheral white blood cells, decreased hemoglobin to varying degrees, elevated blood amylase, elevated D-dimer, elevated lactate dehydrogenase, and decreased serum HCO_3^- levels. Stool cultures of *Salmonella*, *Campylobacter Shigae* and *Escherichia*, the latter of which has been implicated in causing CI, should be performed; parasitic or viral infections such as cytomegalovirus should also be ruled out[4]. Plain abdominal radiographs may reveal nonspecific findings, such as thumb marks, inflatable rings, thickening of the intestinal wall, and intestinal failure; these findings are effective for ruling out colon infarction and intestinal perforation. Abdominal CT can indicate the location of the diseased intestinal segment and the extent of involvement and can also reveal complications such as concomitant disease and perforation. The main manifestations are intestinal wall thickening, blurring of the peritoneal fat space, and occasional intestinal wall gas[11]. CT angiography is of little significance in the diagnosis of IC because IC is a nonocclusive and transient ischemic injury of small vessels. Because it cannot show tertiary blood vessels, it is of little clinical significance. Colonoscopy is considered the gold standard for the diagnosis of IC. Under the microscope, intestinal mucosal congestion, edema, ecchymosis, and submucosal bleeding were observed, the mucosa was dark red, the vascular network disappeared, and some mucosal necrosis occurred, followed by mucosal detachment and ulcer formation. The boundary between the lesion site and the normal intestinal segment was clear. Under the microscope, the bleeding nodules were the characteristic manifestations of IC and were caused by submucosal bleeding or edema[11]. Colonoscopy should be avoided when patients show signs of peritonitis. When an endoscopist finds gangrene, he or she should directly terminate the colonoscopy and perform emergency surgery[12]. Histopathological analysis revealed a large number of fibrinous thrombi and hemosiderin-containing cells in the submucosa. Compared with those in patients with IC, the incidence of eosinophilic infiltration in patients with drug-related IC was greater, and the incidence of ulcers and necrosis was lower.

The patient received an oral PLT-raising capsule to treat the ITP. According to traditional Chinese medicine, blood stasis, blood heat and qi deficiency are the main causes of ITP. Clearing heat, cooling blood and promoting blood stasis are the main principles for treating this disease. It clears heat, detoxifies, disperses stasis, eliminates spots, cools blood and stops bleeding. The main drug used to treat PLT-raising capsules is indigo naturalis, a pigment produced from the stems and leaves of Indigo, *Persicaria tinctoria*, and *Indigofera tinctoria*. Its main ingredients are indigo and indirubin. Modern pharmacological studies show that the active components indigo, indirubin and indigo can effectively inhibit the activity of bacteria and regulate immune function. Forsythia can have anti-inflammatory and antibacterial effects, reduce capillary permeability, and inhibit allergic reactions in the body. Studies have shown that PLT-raising capsules can not only reduce inflammation, inhibit bacteria and regulate the body's immune function but also increase the PLT and improve coagulation function. Studies[13,14] have shown that traditional Chinese medicines containing indigo naturalis components (such as Compound Qingdai Pill and PLT-raising capsules) can cause IC. The pathogenesis of IC induced by

Indigo naturalis may be related to the following factors: (1) Indigo naturalis stimulates colon mucosa and damages the colonic mucosa; (2) indigo naturalis can cause diarrhea, and severe diarrhea can lead to a reduced systemic effective circulating blood volume, increased intestinal pressure, vasospasm, *etc.*, resulting in insufficient blood supply to the colon wall; and (3) indigo naturalis has the effect of cooling blood and stopping bleeding and has obvious procoagulant effects, which can lead to intravascular cellulose thrombosis and blocking blood vessels, thus causing ischemic necrosis of the colonic mucosa[13-16]. Elderly patients may have intestinal arteriosclerosis, and the use of Qingdai is more likely to induce ischemic lesions[15].

ITP-induced bleeding refers to thrombocytopenia in the peripheral blood that results in skin, mucosa, and even internal bleeding, but spontaneous bleeding usually occurs when the PLT count is lower than $20 \times 10^9/L$. The gastrointestinal bleeding of this patient was not accompanied by skin petechiae or ecchymosis, which was inconsistent with the clinical characteristics of intestinal bleeding caused by ITP. In addition, when the patient had blood in the stool and was taking Chinese medicine containing Qingdai, the symptoms improved, and the patient did not experience recurrence after stopping the drug, suggesting that the patient's digestive tract lesions were closely related to the use of the drugs. However, it remains to be studied whether patients with ITP-based lesions have synergistic effects with Qingdai to further increase the risk of intestinal ischemia.

When patients develop drug-induced IC, disease-causing drugs should be stopped immediately, and similar treatments should be used for other causes of IC[17,18]. The treatment of IC is related to the severity of the patient's condition[1,19]. For severe patients, intravenous infusion, optimal hemodynamic status, intestinal rest, empirical use of antibiotics and avoidance of vasoconstrictor therapy were adopted, and most patients experienced improvement in clinical symptoms within 1-2 d. Patients with complications may need surgical intervention[18]. Medical treatment: Most patients with acute mild to moderate IC can receive conservative medical treatment, including routine fasting, gastrointestinal decompression, intravenous nutritional support, fluid resuscitation, and vasoactive drugs, such as papaverine and *Salvia miltiorosa*, to improve circulation. Attention should be given to treating the primary disease early, and symptomatic treatment should be administered at the same time[20,21]. Prophylactic anticoagulation is recommended, but therapeutic anticoagulation is not recommended[22]. In the treatment regimen, empiric intravenous infusion of broad-spectrum antibiotics covering colonic bacteria can minimize the risk of mucosal damage, bacterial translocation and even sepsis[12]. Antianaerobic antibiotics, fluoroquinolones, aminoglycosides or third-generation cephalosporins are recommended for moderate to severe IC[1]. Surgical treatment is required when diffuse peritonitis, perforation, circulatory instability due to persistent bleeding, or repeated blood transfusions occur.

In conclusion, although traditional Chinese medicine containing Indigo naturalis is an effective drug for the clinical treatment of ITP, patients should be reminded to observe digestive tract symptoms and stool characteristics during its treatment. If abdominal pain, diarrhea, or blood in the stool are present, the clinician should consider the possibility of ischemic colitis, it should be recommended that the patient discontinue the drug immediately, and aggressive treatment should be prescribed to prevent serious complications. If a patient has had such an adverse reaction to previous medication, it is best not to use the drug again.

CONCLUSION

The patient developed IC after taking PLT-raising capsules; however, the symptoms improved rapidly after drug withdrawal, and there was no recurrence during follow-up, indicating that the occurrence of IC in the patient was closely related to the use of the PLT-raising capsules. PLT-raising capsules can lead to IC, so clinicians should have a full understanding of the application of these drugs in the treatment of various causes of thrombocytopenia, weigh the advantages and disadvantages, and observe closely. Once abdominal pain, diarrhea, or blood in the stool occur, the drug should be stopped immediately, active treatment should be administered, and further use of the pathogenic drug should be avoided.

FOOTNOTES

Author contributions: Li L is responsible for proposing and presenting the case and organizing the writing of the article; Wang CL was mainly responsible for drafting the manuscript; Si ZK and Liu GH were responsible for collecting the data; Chen C and Zhao H are in charge of organizing the figures and tables.

Informed consent statement: Informed written consent was obtained from the patient for publication of this report and any accompanying images.

Conflict-of-interest statement: The authors declare that they have no conflict of interest.

CARE Checklist (2016) statement: The authors have read the CARE Checklist (2016), and the manuscript was prepared and revised according to the CARE Checklist (2016).

Open-Access: This article is an open-access article that was selected by an in-house editor and fully peer-reviewed by external reviewers. It is distributed in accordance with the Creative Commons Attribution NonCommercial (CC BY-NC 4.0) license, which permits others to distribute, remix, adapt, build upon this work non-commercially, and license their derivative works on different terms, provided the

original work is properly cited and the use is non-commercial. See: <https://creativecommons.org/licenses/by-nc/4.0/>

Country/Territory of origin: China

ORCID number: Chen-Lu Wang 0009-0006-8577-5068; Ze-Kun Si 0009-0009-8428-4154; Guo-Hong Liu 0000-0002-0641-9203; Chen Chen 0009-0004-5889-0760; Hui Zhao 0009-0004-8337-125X; Lei Li 0000-0003-3687-7333.

S-Editor: Qu XL

L-Editor: A

P-Editor: Chen YX

REFERENCES

- 1 **Brandt LJ**, Feuerstadt P, Longstreth GF, Boley SJ; American College of Gastroenterology. ACG clinical guideline: epidemiology, risk factors, patterns of presentation, diagnosis, and management of colon ischemia (CI). *Am J Gastroenterol* 2015; **110**: 18-44; quiz 45 [PMID: 2559486 DOI: 10.1038/ajg.2014.395]
- 2 **Chen ZW**, Yao F, Hu BW, Cao CX. Risk factors of ischemic colitis. *Zhejiang Yixue* 2019; **41**: 1426-1427
- 3 **Deng YB**, Liu YL, He DX. Research progress of ischemic colitis. *Zhongguo Linchuang Yanjiu* 2018; **31**: 701-704 [DOI: 10.13429/j.cnki.cjcr.2018.05.035]
- 4 **Theodoropoulou A**, Koutroubaki IE. Ischemic colitis: clinical practice in diagnosis and treatment. *World J Gastroenterol* 2008; **14**: 7302-7308 [PMID: 19109863 DOI: 10.3748/wjg.14.7302]
- 5 **Ruan SL**, Gu XJ, Guan QB. Domestic literature analysis of epidemiology and clinical features of ischemic colitis. *Zhonghua Laonian Yixue Zazhi* 2015; **34**: 565-569
- 6 **Chinese Expert Recommendations for the Diagnosis and Treatment of Ischemic Bowel Disease Writing Group**; Chinese Geriatric Society of the Chinese Medical Association; Editorial Board of the Chinese Journal of Geriatrics. Chinese Expert Advice on the Diagnosis and Treatment of ischemic bowel disease in the elderly. *Zhonghua Laonian Yixue Zazhi* 2011; **30**: 1-6 [DOI: 10.3760/cma.j.issn.0254-9026.2011.01.001]
- 7 **Zhang LX**, Chen FY. Focus on the diagnosis and treatment of ischemic colitis. *Shijie Huaren Xiaohua Zazhi* 2016; **24**: 3647-3656 [DOI: 10.11569]
- 8 **Cui MH**, Hou XL, Liu JY. Ischemic colitis after receiving the second dose of a COVID-19 inactivated vaccine: A case report. *World J Clin Cases* 2022; **10**: 3866-3871
- 9 **Li Y**, Zu M, Ding SG. Advances in the study of drug-associated ischaemic colitis. *Weichangbingxue He Ganbingxue Zazhi* 2022; **31**: 5-8
- 10 **Brechmann T**, Günther K, Neid M, Schmiegel W, Tannapfel A. Triggers of histologically suspected drug-induced colitis. *World J Gastroenterol* 2019; **25**: 967-979 [PMID: 30833802 DOI: 10.3748/wjg.v25.i8.967]
- 11 **Wu J**, Tian ZB, Xu YH, Ding XL, Wang XW, Ren LL. A case of heavy ischaemic colitis due to platelet-raising capsules and review of the literature. *Shijie Huaren Xiaohua Zazhi* 2017; **25**: 3000-3004
- 12 **Doulberis M**, Panagopoulos P, Scherz S, Dellaporta E, Kouklakis G. Update on ischemic colitis: from etiopathology to treatment including patients of intensive care unit. *Scand J Gastroenterol* 2016; **51**: 893-902 [PMID: 27152750 DOI: 10.3109/00365521.2016.1162325]
- 13 **Song ZJ**, Cao KS, Zhu YF, Yang MY. A case of ischaemic colitis caused by Compound Qingdai pill. *Xinyao Yu Linchuang* 1991; **126**
- 14 **Wang CH**, Jin D, Zhang HY, Cai JT, Du Q. A case of ischaemic enteritis caused by platelet-raising capsules. *Zhonghua Xiaohua Zazhi* 2014; **704**-705
- 15 **Zhang L**, Duan LP, Yang WH, Lv YM, Lin SR. Clinical characteristics and possible pathogenic mechanisms of haematochezia caused by traditional Chinese medicines containing qingdai ingredients. *Weichangbingxue He Ganbingxue Zazhi* 2004; **13**: 161-164
- 16 **SuoBJ**, Zhou LY, Ding SG, Lv YM, Gu F, Lin SR, Zheng YA. Endoscopic and clinical characterisation of qingdai-associated ischaemic colonic mucosal injury. *Zhonghua Neike Zazhi* 2011; **50**: 646-649
- 17 **Hamdeh S**, Micic D, Hanauer S. Drug-Induced Colitis. *Clin Gastroenterol Hepatol* 2021; **19**: 1759-1779 [PMID: 32360808 DOI: 10.1016/j.cgh.2020.04.069]
- 18 **Jessurun J**. The Differential Diagnosis of Acute Colitis: Clues to a Specific Diagnosis. *Surg Pathol Clin* 2017; **10**: 863-885 [PMID: 29103537 DOI: 10.1016/j.path.2017.07.008]
- 19 **Wang J**, Huang JA. Progress in the early diagnosis and treatment of ischaemic colitis. *Linchuang Neike Zazhi* 2019; **36**: 440-443
- 20 **Yin MY**, Xu CF. Analysis of the clinical characteristics of 50 patients with ischaemic colitis. *Weichangbingxue He Ganbingxue Zazhi* 2020; **29**: 305-308
- 21 **Zhang CY**, Wang S, Wu JW, Sun BB, Sun B, Zhang X. Clinical analysis of ischaemic colitis with literature review. *Zhongguo Linchuang Yisheng Zazhi* 2019; **47**: 1196-1198
- 22 **Trotter JM**, Hunt L, Peter MB. Ischaemic colitis. *BM* 355: i6600 [PMID: 28007701 DOI: 10.1136/bmj.i6600]



Published by **Baishideng Publishing Group Inc**
7041 Koll Center Parkway, Suite 160, Pleasanton, CA 94566, USA

Telephone: +1-925-3991568

E-mail: office@baishideng.com

Help Desk: <https://www.f6publishing.com/helpdesk>

<https://www.wjgnet.com>

