



Retrospective Study

Analysis of the causes of primary revision after unicompartmental knee arthroplasty: A case series

Jin-Long Zhao, Xiao Jin, He-Tao Huang, Wei-Yi Yang, Jia-Hui Li, Ming-Hui Luo, Jun Liu, Jian-Ke Pan

Specialty type: Medicine, research and experimental

Provenance and peer review: Unsolicited article; Externally peer reviewed.

Peer-review model: Single blind

Peer-review report's scientific quality classification

Grade A (Excellent): 0
Grade B (Very good): B
Grade C (Good): 0
Grade D (Fair): 0
Grade E (Poor): 0

P-Reviewer: Ng BW, Malaysia

Received: October 5, 2023

Peer-review started: October 5, 2023

First decision: January 9, 2024

Revised: February 2, 2024

Accepted: February 26, 2024

Article in press: February 26, 2024

Published online: March 26, 2024



Jin-Long Zhao, The Second Clinical Medical College, Guangzhou University of Chinese Medicine, Guangzhou 510405, Guangdong Province, China

Xiao Jin, Department of Chinese Medicine, The First Affiliated Hospital, Jinan University, Guangzhou 510630, Guangdong Province, China

He-Tao Huang, The Second School of Clinical Medical Sciences, Guangzhou University of Chinese Medicine, Guangdong Academy of Traditional Chinese Medicine, Guangzhou 510405, Guangdong Province, China

Wei-Yi Yang, Ming-Hui Luo, Jian-Ke Pan, The Second Affiliated Hospital, Guangzhou University of Chinese Medicine (Guangdong Provincial Hospital of Chinese Medicine), Guangzhou 510120, Guangdong Province, China

Jia-Hui Li, The Affiliated TCM Hospital, Guangzhou Medical University, Guangzhou 510405, Guangdong Province, China

Jun Liu, The Research Team on Bone and Joint Degeneration and Injury, Guangdong Provincial Academy of Chinese Medical Sciences, Guangzhou 510405, Guangdong Province, China

Corresponding author: Jian-Ke Pan, PhD, Chief Doctor, The Second Affiliated Hospital, Guangzhou University of Chinese Medicine (Guangdong Provincial Hospital of Chinese Medicine), No. 111 Dade Road, Yuexiu District, Guangzhou 510120, Guangdong Province, China. szypanjianke@yeah.net

Abstract

BACKGROUND

Unicompartmental knee arthroplasty (UKA) has great advantages in the treatment of unicompartmental knee osteoarthritis, but its revision rate is higher than that of total knee arthroplasty.

AIM

To summarize and analyse the causes of revision after UKA.

METHODS

This is a retrospective case series study in which the reasons for the first revision after UKA are summarized. We analysed the clinical symptoms, medical histories, laboratory test results, imaging examination results and treatment processes of the patients who underwent revision and summarized the reasons for primary

revision after UKA.

RESULTS

A total of 13 patients, including 3 males and 10 females, underwent revision surgery after UKA. The average age of the included patients was 67.62 years. The prosthesis was used for 3 d to 72 months. The main reasons for revision after UKA were improper suturing of the surgical opening (1 patient), osteophytes (2 patients), intra-articular loose bodies (2 patients), tibial prosthesis loosening (2 patients), rheumatoid arthritis (1 patient), gasket dislocation (3 patients), anterior cruciate ligament injury (1 patient), and medial collateral ligament injury with residual bone cement (1 patient).

CONCLUSION

The causes of primary revision after UKA were gasket dislocation, osteophytes, intra-articular loose bodies and tibial prosthesis loosening. Avoidance of these factors may greatly reduce the rate of revision after UKA, improve patient satisfaction and reduce medical burden.

Key Words: Unicompartmental knee arthroplasty; Total knee arthroplasty; Causes; Revision; Case series

©The Author(s) 2024. Published by Baishideng Publishing Group Inc. All rights reserved.

Core Tip: Despite the many advantages of unicompartmental knee arthroplasty (UKA), the long-term survival rate of implants and the rate of UKA revision remain controversial. Therefore, clarifying the reasons that may cause UKA revision can further reduce the revision rate of UKA surgery. We found that the main reasons for the initial revision of UKA were gasket dislocation, osteophytes, intra-articular loose bodies and tibial prosthesis loosening. Avoiding these factors may greatly reduce the revision rate after UKA surgery, improve patient satisfaction, and reduce medical burden.

Citation: Zhao JL, Jin X, Huang HT, Yang WY, Li JH, Luo MH, Liu J, Pan JK. Analysis of the causes of primary revision after unicompartmental knee arthroplasty: A case series. *World J Clin Cases* 2024; 12(9): 1560-1568

URL: <https://www.wjgnet.com/2307-8960/full/v12/i9/1560.htm>

DOI: <https://dx.doi.org/10.12998/wjcc.v12.i9.1560>

INTRODUCTION

Joint arthroplasty, such as total knee arthroplasty (TKA) or unicompartmental knee arthroplasty (UKA), is often used to treat end-stage unicompartmental knee osteoarthritis[1,2]. Compared with patients who undergo TKA, those who undergo UKA have smaller surgical wounds, recover faster postoperatively, have less blood loss, are more likely to have the anterior and posterior cruciate ligament preserved, as well as proprioception, a lower osteotomy rate, a shorter hospital stay, and lower costs[3-5]. Although UKA has many advantages, the long-term prosthesis survival rate and rate of revision after UKA are still controversial[6,7]. Many existing studies show that the rate of revision after UKA is much higher than that after TKA, and the main reason is aseptic loosening[8,9]. In this context, exploring and summarizing the causes that may lead to revision after UKA would be conducive to further reducing the UKA revision rate, which is highly valuable for orthopaedic surgeons and patients.

Although the rate of revision after UKA is higher than that after TKA, the total number of revisions after UKA is still relatively low; therefore, summarizing the causes of revision among UKA patients is necessary. By reviewing and analysing the causes of revision after UKA, we established references for the early detection of risk factors for revision in clinical practice and for formulating surgical strategies and rehabilitation programmes.

MATERIALS AND METHODS

Design and inclusion criteria

This was a retrospective case series study in which the reasons for primary revision after UKA were summarized. The inclusion criteria were as follows: (1) Indications for revision after UKA in the Department of Orthopaedics of Guangdong Provincial Hospital of Traditional Chinese Medicine from November 2016 to December 2020; and (2) First revision treatment after UKA (same side) (patients who underwent revision after the primary revision were not included). There were no restrictions regarding age, weight, race, activity or surgical materials used for UKA.

Data extraction and cause analysis

We used the electronic medical records system to extract and analyse the baseline data of the included patients, such as age, sex, surgical side and prosthesis use time. In addition, we comprehensively analysed the reasons for revision after

UKA among the included patients according to their medical histories, imaging data, physical and chemical test results, intraoperative conditions and pathological results. We also followed up on the recovery of the included patients after revision.

Data analysis

We used SPSS 25.0 software for the statistical analysis of the counts and descriptive statistics. The measurement data are expressed as the mean \pm SD.

Ethical approval

This retrospective case series study was approved by the Ethics Committee of Guangdong Provincial Hospital of Traditional Chinese Medicine, No. YE2021-370-01.

RESULTS

Characteristics of 13 patients

From November 2016 to December 2020, a total of 13 patients (13 knees), 3 males (23.08%) and 10 females (76.92%), underwent primary revision after UKA in our hospital (Table 1). The minimum age of the 13 patients included was 59 years, the maximum age was 76 years, and the average age was 67.62 years (standard deviation 5.88 years). There were 5 (38.46%) and 8 (61.54%) left and right knees, respectively, that underwent revision surgery after UKA. The prosthesis was used for 3 d to 72 months. The main causes of revision in 13 patients were improper suturing of the surgical opening (1 patient), osteophytes (2 patients), articular cavity free bodies (2 patients), tibial prosthesis loosening (2 patients), rheumatoid arthritis (RA) (1 patient), pad dislocation (3 patients), anterior cruciate ligament (ACL) injury (1 patient), and medial collateral ligament injury with residual bone cement (1 patient). As of February 2021, we have followed up all 13 patients who underwent revision surgery after UKA for at least half a year, and all patients have achieved good joint function.

Causes of revision after UKA in 13 patients

Improper suture: Patient 1, a 61-year-old female, underwent right-knee mobile-bearing UKA. She sought medical help because her right knee was red, swollen, hot and painful for 3 d. The lower part of the surgical opening of the right knee in Patient 1 was ulcerated and exuded, and the ulceration was round, measuring 0.5 cm \times 0.5 cm. After the patient was admitted to the hospital, wound secretions and joint fluids were immediately collected for bacterial culture. No obvious abnormalities were found in the joint fluid test, and X-ray showed that the prosthesis was in a good position. Based on the above medical history and examination results, we ruled out intra-articular infection and decided to administer debridement treatment. During the operation, we found that the lower part of the original incision in the right knee had obvious inflammatory hyperplasia and subcutaneous soft tissue necrosis, and the wound was not connected to the joint cavity. Tissues near the surgical opening were sent for pathological examination. We thoroughly debrided the necrotic incision during the operation. Postoperative pathology revealed hyperplasia of fibres and small vessels and infiltration of lymphocytes and neutrophils in the local area in the subcutaneous tissue of the right knee, which was consistent with inflammatory changes and multinuclear giant cell reactions. No bacteria were found in the preoperative wound secretion, joint fluid or intraoperative joint fluid culture. Based on the UKA surgical records of the patient and what we observed during the revision, we found that the original surgeon used bidirectional barbed suture, which is not suitable for suturing subcutaneous tissue. We believe that the application of knot-free sutures is the reason for the revision after UKA in Patient 1 (Figure 1).

Osteophytes: Patient 2, a 69-year-old male, underwent mobile-bearing UKA. He was admitted to the hospital because of pain in the upper lateral region of the right knee 4 months after UKA. Before revision, X-ray imaging revealed osteophytes on the lateral condyle of the right knee. We used a small incision to remove the osteophyte from the lateral condyle of the right knee. Postoperative X-ray showed that the osteophytes of the lateral condyle of the right knee had been removed (Supplementary Figure 1).

Patient 3, a 67-year-old male, underwent right-knee mobile-bearing UKA. He was admitted to the hospital due to postoperative pain in the right knee for 5 months. This patient underwent right-knee UKA at an external hospital 5 months prior and continued to experience medial anterior pain in the right knee after UKA. X-ray imaging showed that the tibial prosthesis was placed excessively inwards. Dual computed tomography (CT) showed osteophytes in front of the femoral prosthesis, and we confirmed this in the revision. During the knee joint activity test during revision, we found that the osteophyte collided with the tibial platform and that the bone cement at the lower front of the tibial platform prosthesis was broken, which seriously affected the stability of the tibial platform prosthesis. We cleaned the osteophytes, removed the tibial platform prosthesis, renovated it, and finally installed a new tibial platform prosthesis (Figure 2).

Intra-articular loose body: Two patients needed revision because of the presence of a free body in the joint cavity, and the clinical symptoms of both patients were obvious interlocking symptoms. We performed an arthroscopic downstream extracorporeal surgery.

Patient 4, a 59-year-old female, underwent mobile-bearing UKA of the left knee. She was hospitalized due to pain and locked symptoms for 1 month on the medial side of the left knee. After preoperative imaging and surgical exploration, we confirmed that the mass was free of residual bone cement.

Table 1 Characteristics of the 13 included patients

Case	Sex	Age (yr)	Side of knee	Year of revision	Duration of prosthesis	Cause for UKA revision	Outcome of UKA revision
Patient 1	Female	61	Right	2017	1 month	Improper suture	Cured
Patient 2	Male	69	Right	2018	4 months	Osteophyte	Cured
Patient 3	Male	67	Right	2017	5 months	Osteophyte	Cured
Patient 4	Female	59	Left	2018	20 months	Intra-articular loose body	Cured
Patient 5	Female	70	Left	2020	36 months	Intra-articular loose body	Cured
Patient 6	Male	75	Right	2018	8 months	Tibial prosthesis loosening	Cured
Patient 7	Female	70	Left	2018	23 months	Tibial prosthesis loosening	Cured
Patient 8	Female	76	Right	2017	72 months	Rheumatoid arthritis	Cured
Patient 9	Female	76	Right	2018	15 months	ACL injury	Cured
Patient 10	Female	63	Right	2019	7 months	Gasket dislocation	Cured
Patient 11	Female	63	Right	2016	48 months	Gasket dislocation	Cured
Patient 12	Female	69	Left	2018	10 months	Gasket dislocation	Cured
Patient 13	Female	61	Left	2018	3 d	Medial collateral ligament injury and bone cement residue	Cured

UKA: Unicompartmental knee arthroplasty.

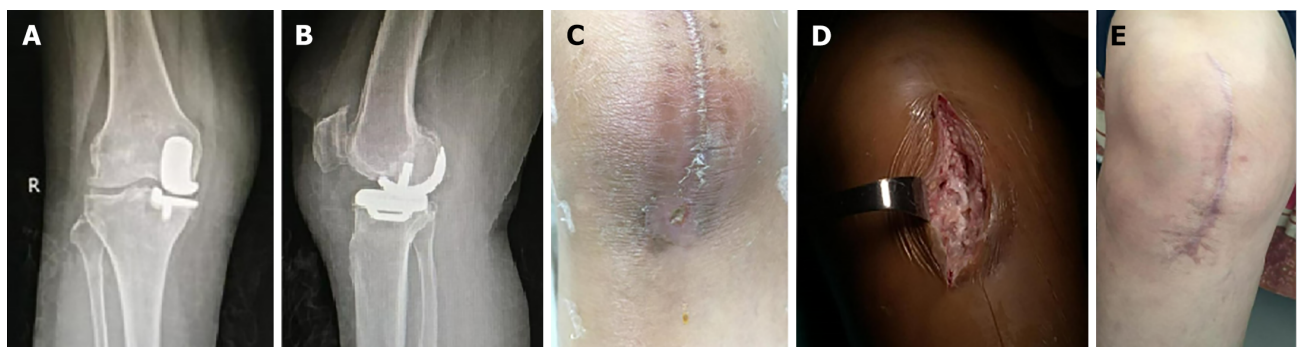


Figure 1 Treatment process (right knee) for Patient 1. A: Anteroposterior X-ray before revision; B: Lateral X-ray before revision; C: Surgical opening before revision; D: Incision for revision; E: The incision healed well after revision.

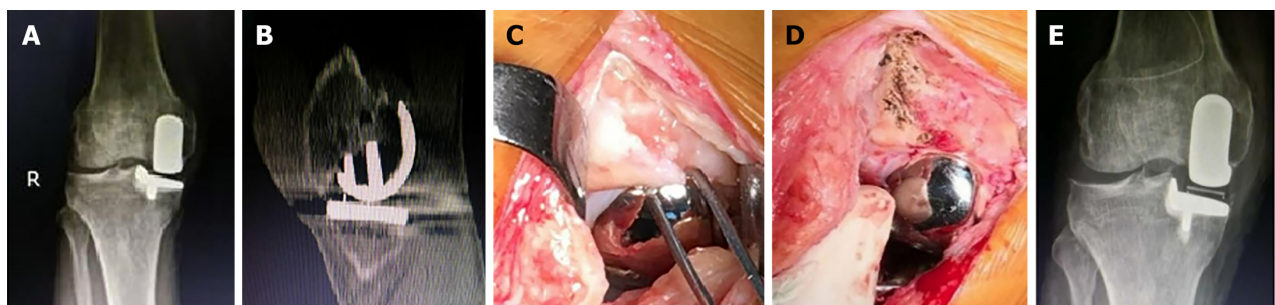


Figure 2 Treatment process (right knee) for Patient 3. A: Anteroposterior X-ray before revision; B: Dual computed tomography image showing osteophytes in front of the femoral prosthesis; C: Osteophytes in front of the femoral prosthesis; D: Excision of osteophytes; E: Anteroposterior X-ray after revision.

Patient 5, a 70-year-old female, underwent fixed-bearing UKA. The patient was hospitalized due to swelling and pain in the left knee for 2 years. Dual CT showed that there was a bone-free body between the tibial prosthesis and the femoral prosthesis (Figure 3).

Tibial prosthesis loosening: Two patients underwent fixed-bore UKA. The tibial platform prosthesis became loose, so we revised the operation to TKA.

Patient 6, a 75-year-old male, was admitted to the hospital due to walking pain for 8 months after right-knee UKA. X-ray imaging revealed an interface under the tibial platform prosthesis, and compared with the previous X-ray after UKA, we found a change in the tibial prosthesis position. The tibial plateau was easily removed with forceps during the operation (Figure 4).

Patient 7, a 70-year-old female, sought medical help because of weakness in the medial side of the left knee for 16 months. The X-ray and intraoperative conditions were similar to those of Patient 6.

RA: Patient 8, a 76-year-old female, underwent mobile-bearing UKA of the right knee. She sought medical help because of swelling and pain in the right knee and ankle for one year after UKA. The patient had undergone right-knee UKA 6 years prior and recovered well after the operation. Afterwards, she suffered from repeated swelling and pain in the right knee and ankle for one year. The rheumatoid antibody test confirmed RA, and a large amount of inflammatory synovium in the suprapatellar bursa and cartilage degeneration damage in the lateral compartment of the knee joint were observed during the revision. The prosthesis was easily and completely removed during the operation, and the knee joint was rebuilt during TKA (Figure 5).

ACL injury: Patient 9, a 76-year-old female, underwent fixed-bearing UKA of the right knee. She sought medical help because of postoperative pain in the right knee and limited mobility. Imaging before UKA indicated that the patient's right knee ACL was broken. X-ray imaging revealed that the right-knee tibia was moved forward, so fixed-bearing UKA was performed. Half a year after UKA, the patient developed instability of the knee joint and repeated pain, and the X-ray showed that the right-knee tibia had moved forward significantly. Following the patient's wishes, TKA was performed after conservative treatment failed (Figure 6).

Gasket dislocation: Three patients underwent mobile-bearing UKA.

Patient 10, a 63-year-old female, developed knee joint pain and limited activity 7 months after right-knee UKA. The X-ray image indicated that the gasket was dislocated forward. We performed knee flexion and extension tests with the original 3-mm pad. At the buckling position, the 3-mm gasket became loose, the 4-mm gasket was under proper tension, and the 5-mm gasket was too tight. The 3-mm gasket was in good condition, the 4-mm gasket was slightly tight, and the 5-mm gasket was very tight and straight. After the above tests, we replaced the gasket with a 4-mm gasket (Supplementary Figure 2).

Patient 11, a 63-year-old female, suffered from pain in the right knee and walking instability after UKA, which persisted for 4 months. The X-ray images indicated that the gasket was dislocated both backwards and downwards. We tested the range of motion of the knee joint and the position of the spacer during the revision, and the results showed that the uneven flexion extension space and poor placement of the femoral prosthesis led to a poor trajectory of the spacer. Finally, the case was revised to TKA (Supplementary Figure 3).

Patient 12, a 69-year-old female, underwent one-stage double-knee UKA at another hospital. She suffered from dislocation of the right knee pad half a year after UKA and returned to the external hospital for revision by TKA. Two months later, the patient had another anterior dislocation of the left knee pad. We compared the postoperative X-ray data of the patient with those of a patients whose prosthesis was placed in the Oxford Monocondyle Course[10] and found that the patient's bilateral femoral prostheses were close to the femur without overhang, which indicated residual osteophytes behind the femur and that the selected femoral prostheses were small. We found two problems at the same time during the operation: first, when the knee joint was in extreme flexion, the pad was moved forward, indicating that there was a rear impact; second, there were residual osteophytes of the femoral medial condyle, leading to the operator's incorrect assessment of the left and right diameters of the femoral medial condyle, and the femoral prosthesis being placed inwards, causing poor tracking of the spacer when the knee joint moved. We completely removed the osteophytes and placed the femoral prosthesis laterally. In addition, we replaced a larger femoral prosthesis and thickened pads (Figure 7).

Injury to the medial collateral ligament and residual bone cement: Patient 13, a 61-year-old female, underwent mobile-bearing UKA of her left knee. The patient was unable to walk and had pain in his left knee. Patient 13 underwent reoperation due to postoperative genu valgus with medial collateral ligament injury and residual bone cement. X-ray showed that the vertical osteotomy of the tibia was inwards, there was more medial suspension of the tibial prosthesis, and there was remaining bone cement. Physical examination revealed grade II damage to the medial collateral ligament. We performed bone cement cleaning+medial collateral ligament repair+shim (small 1) revision 3 d after UKA (Figure 8). This patients underwent revision due to the inexperience of the operator and technical failure.

DISCUSSION

In this study, we summarized the causes of 13 cases of revision after UKA, which we believe can provide a valuable reference for orthopaedic surgeons evaluating patient conditions and selecting surgical methods. Owing to the large advantages of UKA for the treatment of unicompartmental knee osteoarthritis, it is extremely important to reduce or even

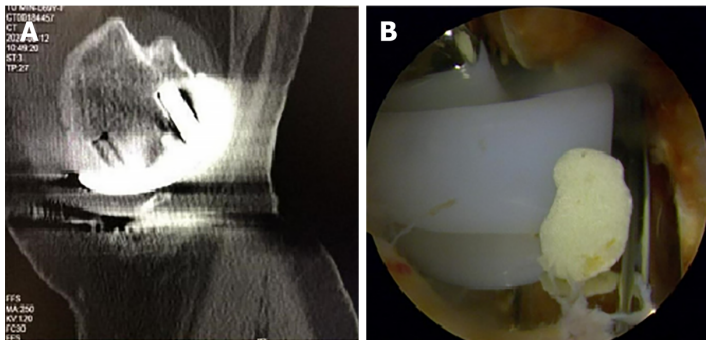


Figure 3 Treatment process (left knee) for Patient 5. A: Dual computed tomography image showing that there was a bone-free body between the tibial prosthesis and the femoral prosthesis; B: Residual bone cement was found during arthroscopic exploration.

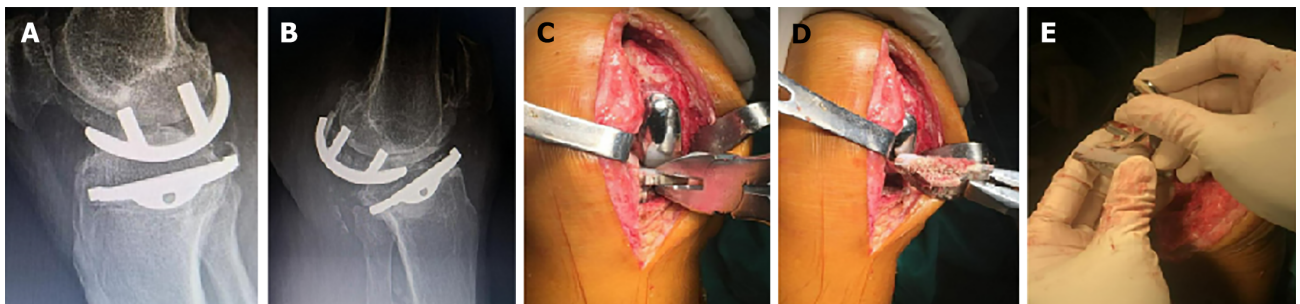


Figure 4 Treatment process (right knee) for Patient 6. A: Anteroposterior X-ray before revision; B: Lateral X-ray before revision; C: The tibial prosthesis was loose; D: The tibial prosthesis was easily removed during revision; E: The femoral prosthesis was removed and modified for total knee arthroplasty.

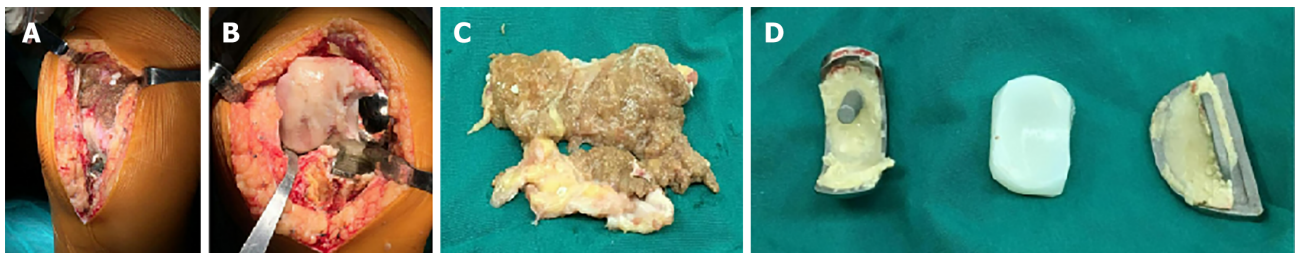


Figure 5 Treatment process (right knee) for Patient 8. A: A large amount of inflammatory synovium in the suprapatellar bursa was observed during revision; B: The lateral femoral condyle cartilage was injured; C: Synovial tissue; D: Oxford movable platform single condyle prosthesis.

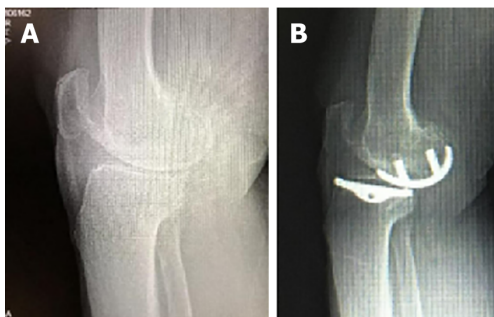


Figure 6 Treatment process (right knee) for Patient 9. A: Lateral X-ray before unicompartmental knee arthroplasty (UKA); B: Lateral X-ray in the weight-bearing position after UKA.

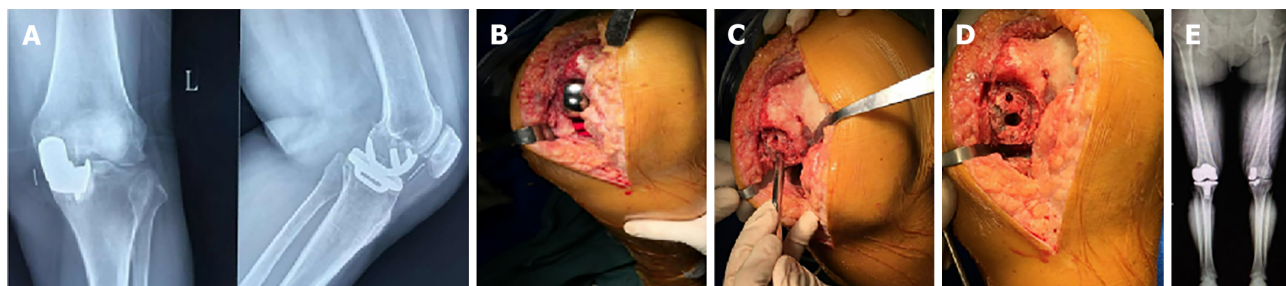


Figure 7 Treatment process (left knee) for Patient 12. A: Before revision, X-ray showed that the gasket was dislocated; B: The spacer was moved forward under extreme knee flexion; C: The centre of the femoral prosthesis was inwards; D: Prosthesis displacement; E: X-ray after revision.

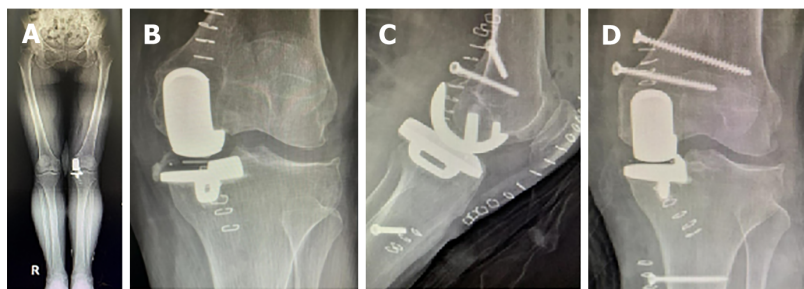

Figure 8 Treatment process (left knee) for Patient 13. A: X-ray image showing genu valgus after Unicompartmental knee arthroplasty (UKA); B: X-ray showing residual bone cement after UKA; C: Repair of the medial collateral ligament; D: X-ray anteroposterior films after revision.

eliminate the risk of revision after UKA. Circumventing the risk factors leading to revision after UKA summarized in this study may be beneficial for selecting UKA for the treatment of unicompartmental knee osteoarthritis and achieving better clinical outcomes.

In this study, gasket dislocation (3/13) was the main cause of revision after UKA. Compared with fixed-bearing prostheses, movable prostheses are more prone to dislocation. The 3 patients with spacer dislocation included in this study were all treated with mobile-bearing UKA. Pad dislocation occurs in 0.9% to 4.0% of cases[11], almost all of which occur in movable platform-type single condyle prostheses. We believe that the most common cause of iatrogenic gasket dislocation is insufficient gasket containment, which is often related to surgical errors. We believe that it is very important to fully evaluate and select the correct thickness of the shims and appropriate prostheses before or during UKA. For the treatment of dislocation of the pad after UKA, the operator needs to fully evaluate the position of the femoral and tibial prosthesis components, the balance of the knee joint space, and the state of the soft tissue and accurately determine the cause of dislocation to select the replacement pad model or revision. According to the results of the revision of Patient 12, we believe that the technical focus should be on the selection of a femoral prosthesis, which should be greater than or equal to the original prosthesis.

The proportion of UKA revisions caused by osteophytes, articular cavity free bodies and tibial prosthesis loosening was 15.35%. We believe that osteophytes, bone cement or bone residue caused by technical reasons should be considered by bone surgeons. The presence of osteophytes and an intra-articular loose body is likely to cause an impact between the prosthesis and the bone structure, which may lead to loosening of the prosthesis, fracture around the prosthesis, dislocation of the pad, degeneration or tearing of the cruciate ligament[12-14]. Therefore, the operator should be familiar with the technical needs of UKA. During the operation, the osteophyte and bone cement residue at risk of impact should be completely removed, and the hyperplastic synovium of the joint should be removed if necessary. When osteophytes or loose bodies in the joint cavity are found early after UKA without causing serious impact, we believe that cleaning up the hyperplastic osteophytes, synovium, and residual or fallen bone cement under arthroscopy is appropriate, which was also verified in our follow-up. If severe impact complications occur, orthopaedic surgeons should choose to perform pad replacement, single condylar prosthesis replacement or TKA revision according to the type of complication.

There were 1 case of improper suture, 1 case of RA, 1 case of ACL injury, and 1 case of medial collateral ligament injury with residual bone cement. Generally, UKA results in a smaller incision and less soft tissue damage, and the infection risk associated with UKA is lower than that associated with TKA. Therefore, UKA should be performed under strict aseptic conditions, and standardized surgical suturing procedures should be upheld. The medial collateral ligament and the ACL are important for maintaining joint stability and participating in flexion and extension activities, and their functional integrity is one of the necessary conditions for selecting UKA. Therefore, we carefully evaluated the function of the lateral collateral ligament and the ACL before the operation, especially the location and direction of the vertical osteotomy of the tibial plateau. The orthopaedic surgeon should focus on protecting the medial collateral ligament during horizontal osteotomy, which can reduce the risk of such complications. For patients with a family history of RA or who are considered susceptible patients, orthopaedic surgeons should fully communicate with patients before surgery and conduct corresponding RA screening tests, which may help reduce the rate of UKA revision due to RA. For elderly

patients and those who are at high risk of RA, we think that TKA may be a more suitable choice.

This was a retrospective case study. The main defects of this study design are memory bias and nonresponse bias. Second, because a small number of patients were included, the representativeness of the data was poor. Therefore, the conclusions of this study should be considered in light of the above limitations.

CONCLUSION

This study revealed that the causes of revision after UKA were mainly gasket dislocation, osteophytes, intra-articular loose bodies and tibial prosthesis loosening. Circumventing these factors may greatly reduce the rate of UKA revision, improve patient satisfaction and reduce medical burden. In addition, UKA is critical for comprehensively and objectively assessing the knee ligament status and RA risk of patients to subsequently select the appropriate surgical method (UKA or TKA).

ARTICLE HIGHLIGHTS

Research background

Unicompartmental knee arthroplasty (UKA) has great advantages in the treatment of unicompartmental knee osteoarthritis, but its revision rate is higher than that of total knee arthroplasty.

Research motivation

Providing a reference for orthopaedic surgeons to reduce the revision rate and improve patient satisfaction.

Research objectives

The study aims to summarize and analyse the causes of revision after UKA.

Research methods

This is a retrospective case series summarizing the reasons for the first revision after UKA in the Department of Orthopedics of Guangdong Provincial Hospital of Traditional Chinese Medicine from November 2016 to December 2020. We analysed data on the clinical symptoms, medical history, laboratory tests, imaging examinations and treatment process of the revision cases and summarized the reasons for primary revision after UKA among all cases.

Research results

Thirteen patients, including 3 males and 10 females, underwent revision surgery after UKA. The average age of the included patients was 67.62 years. The main reasons for revision after UKA were improper suturing of the surgical opening, osteophytes, intra-articular loose bodies, tibial prosthesis loosening, rheumatoid arthritis, gasket dislocation, anterior cruciate ligament injury, and medial collateral ligament injury with residual bone cement.

Research conclusions

The causes of primary revision after UKA were gasket dislocation, osteophytes, intra-articular loose bodies and tibial prosthesis loosening.

Research perspectives

Avoidance of these factors found in this study may greatly reduce the rate of revision after UKA, improve patient satisfaction and reduce medical burden.

FOOTNOTES

Co-first authors: Jin-Long Zhao and Xiao Jin.

Co-corresponding authors: Jun Liu and Jian-Ke Pan.

Author contributions: Material preparation, data collection, and analysis were performed by Jin X, Yang WY, Huang HT, Li JH and Luo MH; The first draft of the manuscript was written by Zhao JL, Liu J, and Pan JK; and all authors commented on previous versions of the manuscript; All authors contributed to the study conception and design, read and approved the final manuscript.

Supported by National Natural Science Foundation of China, No. 82004386; and Guangdong Basic and Applied Basic Research Foundation, No. 2022A1515011700.

Institutional review board statement: This study was approved by the Ethics Committee of Guangdong Provincial Hospital of Traditional Chinese Medicine (YE2021-370-01).

Informed consent statement: For this type of study informed consent is not required.

Conflict-of-interest statement: The author(s) declared no potential conflicts of interest with respect to the research, authorship, and/or publication of this article.

Data sharing statement: Data underlying this article are available from the corresponding author upon reasonable request.

Open-Access: This article is an open-access article that was selected by an in-house editor and fully peer-reviewed by external reviewers. It is distributed in accordance with the Creative Commons Attribution NonCommercial (CC BY-NC 4.0) license, which permits others to distribute, remix, adapt, build upon this work non-commercially, and license their derivative works on different terms, provided the original work is properly cited and the use is non-commercial. See: <https://creativecommons.org/licenses/by-nc/4.0/>

Country/Territory of origin: China

ORCID number: Wei-Yi Yang 0000-0001-8657-2269; Ming-Hui Luo 0000-0001-6831-6317; Jun Liu 0000-0002-1943-3880; Jian-Ke Pan 0000-0002-4596-6111.

S-Editor: Fan JR

L-Editor: A

P-Editor: Chen YX

REFERENCES

- 1 Casper DS, Fleischman AN, Papas PV, Grossman J, Scuderi GR, Lonner JH. Unicompartmental Knee Arthroplasty Provides Significantly Greater Improvement in Function than Total Knee Arthroplasty Despite Equivalent Satisfaction for Isolated Medial Compartment Osteoarthritis. *J Arthroplasty* 2019; **34**: 1611-1616 [PMID: 31031160 DOI: 10.1016/j.arth.2019.04.005]
- 2 Kievit AJ, Kuijer PPFM, de Haan LJ, Koenraadt KLM, Kerkhoffs GMMJ, Schaafroth MU, van Geenen RCI. Patients return to work sooner after unicompartmental knee arthroplasty than after total knee arthroplasty. *Knee Surg Sports Traumatol Arthrosc* 2020; **28**: 2905-2916 [PMID: 31471724 DOI: 10.1007/s00167-019-05667-0]
- 3 Haffar A, Ali R, Mehta N, Patel A, Fricka KB, Della Valle CJ, Gerlinger TL, Krueger CA, Lonner JH. Prior Anterior Cruciate Ligament Reconstruction Does Not Compromise the Functional Outcomes of Medial Unicompartmental Knee Arthroplasty Although Revision for Progressive Arthritis May Occur Earlier. *J Arthroplasty* 2022; **37**: 238-242 [PMID: 34699914 DOI: 10.1016/j.arth.2021.10.008]
- 4 Janssen SJ, van Oost I, Breugem SJM, van Geenen RCI. A structured evaluation of the symptomatic medial Oxford unicompartmental knee arthroplasty (UKA). *EFORT Open Rev* 2021; **6**: 850-860 [PMID: 34760285 DOI: 10.1302/2058-5241.6.200105]
- 5 Yang G, Jiao X, Li Q, Li Z, An S, Feng M, Gao G, Huang J, Cao G. Hybrid Oxford unicompartmental knee arthroplasty has lower residual cement extrusion than cemented arthroplasty in treating end-stage unicompartmental knee osteoarthritis. *BMC Musculoskelet Disord* 2021; **22**: 833 [PMID: 34587940 DOI: 10.1186/s12891-021-04720-9]
- 6 Lyons MC, MacDonald SJ, Somerville LE, Naudie DD, McCalden RW. Unicompartmental versus total knee arthroplasty database analysis: is there a winner? *Clin Orthop Relat Res* 2012; **470**: 84-90 [PMID: 22038173 DOI: 10.1007/s11999-011-2144-z]
- 7 Lombardi AV Jr, Kolich MT, Berend KR, Morris MJ, Crawford DA, Adams JB. Revision of Unicompartmental Knee Arthroplasty to Total Knee Arthroplasty: Is It as Good as a Primary Result? *J Arthroplasty* 2018; **33**: S105-S108 [PMID: 29691172 DOI: 10.1016/j.arth.2018.03.023]
- 8 Ma J, Yan Y, Wang W, Wang B, Yue D, Guo W. Lower early revision rates after uncemented Oxford Unicompartmental Knee Arthroplasty (UKA) than cemented Oxford UKA: A meta-analysis. *Orthop Traumatol Surg Res* 2021; **107**: 102802 [PMID: 33429085 DOI: 10.1016/j.otsr.2021.102802]
- 9 Arias-de la Torre J, Valderas JM, Evans JP, Martín V, Molina AJ, Muñoz L, Pons-Cabrafiga M, Espallargues M; Catalan Arthroplasty Register Steering Committee (RACat). Differences in Risk of Revision and Mortality Between Total and Unicompartmental Knee Arthroplasty. The Influence of Hospital Volume. *J Arthroplasty* 2019; **34**: 865-871 [PMID: 30772112 DOI: 10.1016/j.arth.2019.01.046]
- 10 Mukherjee K, Pandit H, Dodd CA, Ostlere S, Murray DW. The Oxford unicompartmental knee arthroplasty: a radiological perspective. *Clin Radiol* 2008; **63**: 1169-1176 [PMID: 18774366 DOI: 10.1016/j.crad.2007.12.017]
- 11 Saragaglia D, Estour G, Nemer C, Colle PE. Revision of 33 unicompartmental knee prostheses using total knee arthroplasty: strategy and results. *Int Orthop* 2009; **33**: 969-974 [PMID: 18563411 DOI: 10.1007/s00264-008-0585-0]
- 12 Cregar WM, Goodloe JB, Lu Y, Gerlinger TL. Increased Operative Time Impacts Rates of Short-Term Complications After Unicompartmental Knee Arthroplasty. *J Arthroplasty* 2021; **36**: 488-494 [PMID: 32921548 DOI: 10.1016/j.arth.2020.08.032]
- 13 Ji JH, Park SE, Song IS, Kang H, Ha JY, Jeong JJ. Complications of medial unicompartmental knee arthroplasty. *Clin Orthop Surg* 2014; **6**: 365-372 [PMID: 25436058 DOI: 10.4055/cios.2014.6.4.365]
- 14 Siedlecki C, Beaufils P, Lemaire B, Pujol N. Complications and cost of single-stage vs. two-stage bilateral unicompartmental knee arthroplasty: A case-control study. *Orthop Traumatol Surg Res* 2018; **104**: 949-953 [PMID: 29626655 DOI: 10.1016/j.otsr.2018.01.021]



Published by **Baishideng Publishing Group Inc**
7041 Koll Center Parkway, Suite 160, Pleasanton, CA 94566, USA

Telephone: +1-925-3991568

E-mail: office@baishideng.com

Help Desk: <https://www.f6publishing.com/helpdesk>

<https://www.wjgnet.com>

